

Case report

Open Access

## Amniotic membrane transplantation for wound dehiscence after deep lamellar keratoplasty: a case report

Tetsuya Kawakita\*<sup>1,2</sup>, Tamaki Sumi<sup>1</sup>, Murat Dogru<sup>1,2</sup>, Kazuo Tsubota<sup>2</sup> and Jun Shimazaki<sup>1</sup>

Address: <sup>1</sup>Department of Ophthalmology, Tokyo Dental College Ichikawa General Hospital, Chiba, Japan, 272-8513 and <sup>2</sup>Department of Ophthalmology, Keio University, Tokyo, Japan, 160-8582

Email: Tetsuya Kawakita\* - [kawatetsu@gmail.com](mailto:kawatetsu@gmail.com); Tamaki Sumi - [ocularsurface@gmail.com](mailto:ocularsurface@gmail.com); Murat Dogru - [muratodooru@yahoo.com](mailto:muratodooru@yahoo.com); Kazuo Tsubota - [tsubota@sc.itc.keio.ac.jp](mailto:tsubota@sc.itc.keio.ac.jp); Jun Shimazaki - [jun@eyebank.or.jp](mailto:jun@eyebank.or.jp)

\* Corresponding author

Published: 13 June 2007

Received: 18 March 2007

*Journal of Medical Case Reports* 2007, **1**:28 doi:10.1186/1752-1947-1-28

Accepted: 13 June 2007

This article is available from: <http://www.jmedicalcasereports.com/content/1/1/28>

© 2007 Kawakita et al; licensee BioMed Central Ltd.

This is an Open Access article distributed under the terms of the Creative Commons Attribution License (<http://creativecommons.org/licenses/by/2.0>), which permits unrestricted use, distribution, and reproduction in any medium, provided the original work is properly cited.

### Abstract

**Purpose:** To report amniotic membrane (AM) transplantation in a patient with wound dehiscence 5 months after deep lamellar keratoplasty (DLKP)

**Methods:** The patient was an 84-year-old Japanese man who had undergone right DLKP 5 months earlier for central corneal scarring due to recurrent stromal herpetic keratitis. He developed wound dehiscence with corneal stromal melting due to recurrence of stromal herpes in both the donor and recipient sites. "AM roll-in filling technique" and AM patching were performed.

**Results:** Following AM transplantation, stromal inflammation subsided and complete epithelialization occurred within 10 days of surgery.

At 8 months postoperatively, biomicroscopy revealed stable wound apposition or stromal gain. Following AM transplantation, stromal inflammation subsided and complete epithelialization was achieved within 10 days after surgery.

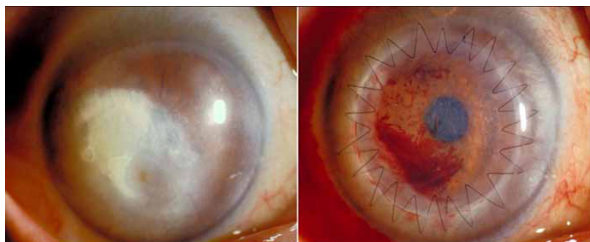
**Conclusion:** AM transplantation may offer an effective treatment modality for herpetic corneal wound dehiscence after DLKP.

### Background

AM transplantation has been reported to be an effective ocular surface reconstruction procedure in the treatment of corneal erosions, central or peripheral ulcers and perforations, as such membranes can decrease inflammation, promote corneal epithelialization and provide corneal stromal substrate.[1,2] We report AM transplantation in a patient with wound dehiscence 5 months after deep lamellar keratoplasty (DLKP).

### Case presentation

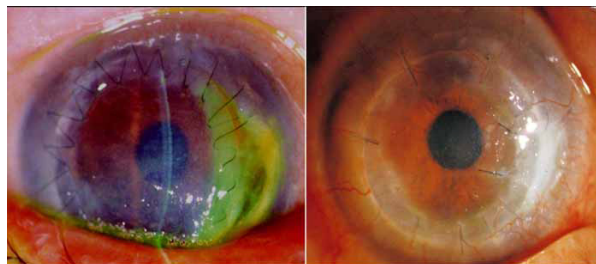
An 84-year-old Japanese man was referred to our hospital for keratoplasty due to central corneal opacity and peripheral corneal neovascularization with lipid deposition in the right eye (Figure 1A). His medical history showed that laboratory culture and serological tests had revealed recurrent herpetic keratitis in that eye. At his initial visit, the best corrected visual acuities (BCVA) were 12/200 OD and 20/20 OS.



**Figure 1**  
**Left, preoperative appearance showing lipid deposition covering pupil.** Right, postoperative appearance 2 weeks after DLKP. There is blood in the interface between graft and host.

DLKP with single running 10-0 nylon sutures was performed (Figure 1, right). Complete graft epithelization was achieved within 5 days. In addition to 0.1% topical dexamethasone qid (Sanbethasone®, Santen) and levofloxacin eyedrops qid (Cravit®, Santen) for 5 months, the patient was prescribed 1000 mg/day oral acyclovir (Zovirax®, Glaxo Smith Kline), to be commenced the day prior to the operation and continued for 10 days to prevent herpetic recurrence.

The corneal graft remained in good condition with recovery of BCVA to 20/100 until the fifth postoperative month, at which time the patient was readmitted with decreased vision and right ocular pain. Examination revealed stromal herpetic keratitis, stromal melting and wound dehiscence with descemetocoele at between 2 and 4 o'clock to the donor-recipient apposition site. (Figure 2, left) The anterior chamber was shallow, and incarceration of the iris was observed. The patient was prescribed 1000 mg peroral acyclovir and ointment five times a day. Due to the development of corneal perforation and unavailability of donor corneal tissue, running sutures were replaced with interrupted sutures, and frozen AM trimmed to fit the site was transplanted with a "roll-in filling technique", i.e., roll-in AM was used to provide wound apposition without sutures, while a second AM patch was used to cover the melting area with interrupted sutures. (Figure 2, right, AMT indicated by arrow). Preservative-free hyaluronate and topical antibiotic eye drops were prescribed qid. Acyclovir ointment was prescribed five times a day for 3 months. Following AM transplantation, stromal inflammation subsided and complete epithelization was achieved within 10 days of surgery. At 8 months postoperatively, biomicroscopy revealed stable wound apposition and stromal gain.



**Figure 2**  
**Left, postoperative appearance 5 months after DLKP showing ulceration, stromal melting, wound dehiscence and iris incarceration.** Right, postoperative appearance 2 weeks after AMT.

## Discussion

Postkeratoplasty oral acyclovir prophylaxis has been reported to prevent recurrences. In our opinion, the wound perforation seen here was a result of insufficient prophylaxis with recurrence. AM transplantation has been widely reported to be an efficient procedure for central and peripheral corneal erosion, ulceration and perforations. The beneficial effects of this approach result from the presence of a rich extracellular matrix and collagen which provide a stromal substrate as in our case and anti-inflammatory properties arising from entrapment of inflammatory cells, the presence of various growth factors, inhibition of proteinase activity, and decrease of lipid peroxidation.[3] AM patch has also been reported to be effective in acute ulcerative and necrotizing herpetic stromal keratitis[4] due to reduction of gelatinolytic activity of MMP-9 and increased expression of TIMP-1.[5] These properties may have been responsible for the effective suppression of herpetic inflammation seen in this particular case.

AM has been commonly used to repair areas of corneal stromal loss by multilayered AM, but which technique is difficult to apply for wound dehiscence because of shape of stromal loss. Our modified "AM roll-in filling technique" can provide compact and dense spacer for such stromal loss site. We have reported the successful application of AM in wound dehiscence and herpetic stromal melting after DLKP. We have also demonstrated the usefulness of the "AM roll-in filling technique" for such patients. Due to availability of corneal donor, this technique could be used as a first choice in such situation.

## Abbreviations

AM; amniotic membrane, AMT; amniotic membrane transplantation, BCVA; the best corrected visual acuities,

DLKP; deep lamellar keratoplasty, MMP; matrix metalloproteinase, TIMP; tissue inhibitor of metalloproteinase

### Competing interests

The author(s) declare that they have no competing interests.

### Authors' contributions

TK: Analysis and interpretation, writing the draft manuscript

TS: Data collection, provision of patient materials

MD: Provision of patient material, critical revision of the article

KT: Provision of materials and resources

JS: Conception and design, analysis and interpretation

All of the authors read and approved the final manuscript.

### Acknowledgements

The authors have no proprietary interests in any of the products mentioned in this paper. Presented at the 2005 Chiba Ophthalmologists Consultation Meeting, September 2005, Chiba, Japan. Written patient consent was received for the manuscript to be published.

### References

1. Kim JC, Tseng SC: **Transplantation of preserved human amniotic membrane for surface reconstruction in severely damaged rabbit corneas.** *Cornea* 1995, **14**:473-84.
2. Hanada K, Shimazaki J, Shimmura S, Tsubota K: **Multilayered amniotic membrane transplantation for severe ulceration of the cornea and sclera.** 2001, **131**:324-331.
3. Shimmura S, Shimazaki J, Ohashi Y, Tsubota K: **Antiinflammatory effects of amniotic membrane transplantation in ocular surface disorders.** *Cornea* 2001, **20**:408-13.
4. Heiligenhaus A, Li H, Hernandez Galindo EE, Koch JM, Steuhl KP, Meller D: **Management of acute ulcerative and necrotising herpes simplex and zoster keratitis with amniotic membrane transplantation.** *Br J Ophthalmol* 2003, **87**:1215-19.
5. Heiligenhaus A, Li HF, Yang Y, Wasmuth S, Steuhl KP, Bauer D: **Transplantation of amniotic membrane in murine herpes stromal keratitis modulates matrix metalloproteinases in the cornea.** *Invest Ophthalmol Vis Sci* 2005, **46**:407.

Publish with **BioMed Central** and every scientist can read your work free of charge

"BioMed Central will be the most significant development for disseminating the results of biomedical research in our lifetime."

Sir Paul Nurse, Cancer Research UK

Your research papers will be:

- available free of charge to the entire biomedical community
- peer reviewed and published immediately upon acceptance
- cited in PubMed and archived on PubMed Central
- yours — you keep the copyright

Submit your manuscript here:  
[http://www.biomedcentral.com/info/publishing\\_adv.asp](http://www.biomedcentral.com/info/publishing_adv.asp)

