

# *Immunohistochemical Localization of Prekeratin Filaments in Benign and Malignant Cells in Effusions*

## *Comparison With Intermediate Filament Distribution by Electron Microscopy*

HARRIETTE J. KAHN, MD, WEDAD HANNA, MD,  
HERMAN YEGER, and REUBEN BAUMAL, MD

*From the Departments of Pathology, Women's College Hospital and the Hospital for Sick Children, Toronto, Ontario, Canada*

---

An immunoperoxidase technique employing antibody to prekeratin was used to study distribution and pattern of staining of prekeratin filaments in cytological smears obtained from 42 specimens of pleural and peritoneal effusions (27 benign, 15 malignant). The smears were either air-dried or ethanol-fixed. Both benign and malignant mesothelial cells showed distinctive peripheral or perinuclear staining patterns which differed from the characteristic arborizing pattern in adenocarcinoma cells. The ultrastructure of these 2 cell types studied in 27 body fluids (12 benign, 15 malignant) and in 13

malignant tumors (3 mesotheliomas, 10 adenocarcinomas) showed a distinctive localization of intermediate filaments which corresponded to and could explain the pattern of staining obtained using the immunoperoxidase technique. The immunohistochemical and ultrastructural findings appeared characteristic for benign and malignant mesothelial cells as well as for adenocarcinoma cells, and could be used as markers to differentiate mesothelial tumors and reactive mesothelial cells from adenocarcinomas. (*Am J Pathol* 1982, 109:206-214)

---

DIFFERENTIATION of malignant mesothelioma and metastatic adenocarcinoma by routine light microscopy is often difficult with the use of tissue sections prepared from surgically resected specimens or smears of cytologic preparations obtained from effusions.<sup>1-4</sup> For this reason, transmission electron microscopy has been employed as a possible method to aid in distinguishing these 2 types of neoplasm. Ultrastructural features of mesothelioma in tissue sections<sup>5,6</sup> and of cells in pleural or peritoneal fluids<sup>6-8</sup> have been reported, including the presence of tonofilaments within the cytoplasm of these cells. Ultrastructural features of adenocarcinoma cells obtained from various sites have also been described, including the presence of intermediate filaments within tumor cells.<sup>9</sup> However, at the ultrastructural level, the different classes of intermediate filaments cannot be distinguished from one another, except when prekeratin filaments form desmosomal attachments or become aggregated to form tonofilaments.

The intermediate filament prekeratin has been demonstrated by immunohistochemical methods in

tissue sections of normal epithelium,<sup>10</sup> in mesotheliomas,<sup>11</sup> and in adenocarcinomas.<sup>11-13</sup> In addition, prekeratin filaments have been demonstrated in cultured cells<sup>14-16</sup> and in dissociated epithelial cells from various animals.<sup>17</sup> The possibility exists that prekeratin filaments may be detected in human cells present in cytologic effusions and that this may be of diagnostic value in surgical pathology.

In the present study, we have characterized the distribution and pattern of prekeratin filaments in benign and malignant mesothelial cells (of mesodermal origin) and in adenocarcinoma cells (of ectodermal or endodermal origin), using an immunoperoxidase technique. We have compared these immunohistochemical results with ultrastructural features of these two types of cells to assess whether immunohistochemistry is useful in the differential diagnosis of

---

Accepted for publication June 23, 1982.

Address reprint requests to Dr. H. Kahn, Women's College Hospital, Department of Pathology, 76 Grenville Street, Toronto, Ontario, Canada M5S 1B2.

malignant mesothelioma, reactive mesothelial cells, and metastatic adenocarcinoma.

### Materials and Methods

All cases of mesothelioma (4) and adenocarcinoma (15) included in the present study were confirmed at the time of surgery or autopsy with the use of clinical, gross, and microscopic criteria. In the case of the mesotheliomas, the lungs were encased by tumor in the surgical specimens. Histologically, these tumors were biphasic and showed malignant spindle cell and epithelial components. In addition, no adenocarcinoma was found elsewhere.

Forty-two pleural and peritoneal effusions (27 benign and 15 malignant) submitted to Women's College Hospital, Toronto, were used prospectively for the preparation of smears. The smears were fixed in ethanol and stained for routine diagnosis with the Papanicolaou stain. If sufficient material was available, additional smears were either ethanol-fixed or air-dried prior to immunoperoxidase staining with an antiserum to prekeratin. In a retrospective approach, coverslips were removed from Papanicolaou-stained smears of effusions by the immersion of slides in xylene, and the immunoperoxidase technique was then applied.

Touch preparations of normal squamous and columnar epithelial cells from cervix were similarly fixed and stained for comparison with the cells in the effusions.

Prekeratin was prepared from human plantar scrapings by the method of Sun and Green.<sup>15</sup> Two major bands (mol wt 45,000 and 60,000) were identified by sodium dodecyl sulfate polyacrylamide gel electrophoresis. New Zealand white rabbits were immunized subcutaneously with 0.3 mg of the prekeratin preparation in complete Freund's adjuvant. Boosters were administered every 2 weeks, and the animals were bled subsequently. The antisera collected were tested for specificity by immunodiffusion against prekeratin, embryonic lung fibroblasts, and vimentin and were found to precipitate only the prekeratin preparation. The prekeratin antiserum reacted positively with the prekeratin filament network in rat kangaroo (PtK2) cells.

For immunoperoxidase staining, modifications of the method of Sternberger et al<sup>18</sup> were employed. Slides of smears were placed in absolute ethanol for 30 minutes and hydrated in graded ethanol concentrations to water. They were then treated with 0.5% hydrogen peroxide and washed in phosphate-buffered saline (140 mM NaCl, 3 mM KCl, 0.15 mM KH<sub>2</sub>PO<sub>4</sub>, 8 mM Na<sub>2</sub> HPO<sub>4</sub> · 7H<sub>2</sub>O, pH 7.4) (PBS).

Normal swine serum was then applied at a dilution of 1:20 for 10 minutes. After a further wash in PBS, antiserum to human prekeratin at a 1:80 dilution was applied for 30 minutes at room temperature in a humidified chamber. Swine anti-rabbit immunoglobulin antiserum at a 1:20 dilution was then applied for 30 minutes at room temperature. The slides were then washed in PBS and incubated with a horseradish peroxidase-rabbit anti-horseradish peroxidase reagent (PAP, Dako, Copenhagen) at a 1:30 dilution for 30 minutes at room temperature. They were then treated with a solution of fresh 3,3'-diaminobenzidine tetrahydrochloride (Sigma, St. Louis) 10 mg/ml and 30% hydrogen peroxide in 0.05 M Tris HCl, pH 7.6, for 1-5 minutes at room temperature, to visualize the brown color indicative of peroxidase activity. Finally, the smears were counterstained with hematoxylin, dehydrated in graded ethanol concentrations, and cleared in xylene; coverslips were then mounted. As a positive control, sections of normal skin were stained with the prekeratin antiserum. As a negative control, preimmune rabbit serum was used instead of the prekeratin antiserum.

For ultrastructural study of effusions, 27 fluids (12 benign and 15 malignant) were centrifuged and the pellets were fixed in universal fixative (4% neutral buffered formalin and 1% glutaraldehyde), postfixed in 1% osmium tetroxide, dehydrated in graded ethanols, and embedded in Epon. Tissues from 3 malignant mesotheliomas and 10 adenocarcinomas were similarly fixed and embedded. Sections 1 μ thick were stained with toluidine blue. Thin sections were stained with uranyl acetate and lead citrate and were examined with a Philips 300 electron microscope.

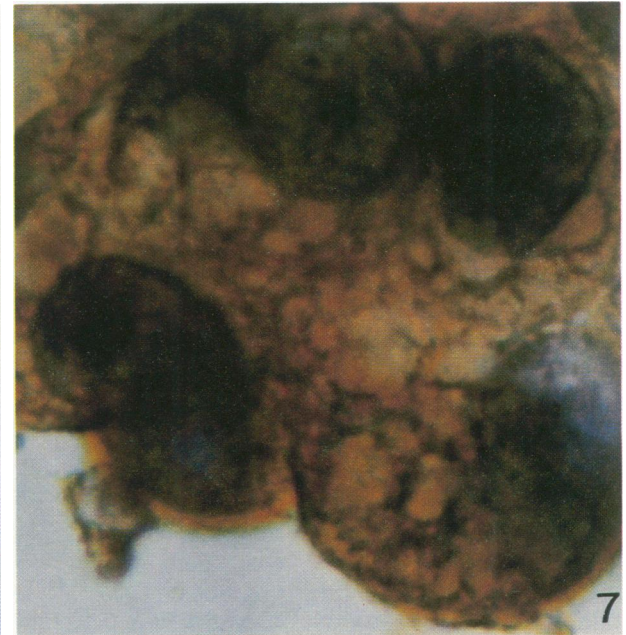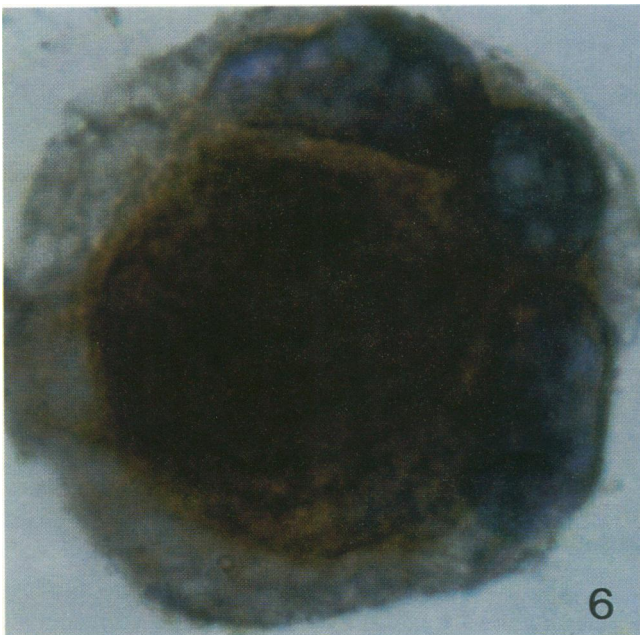
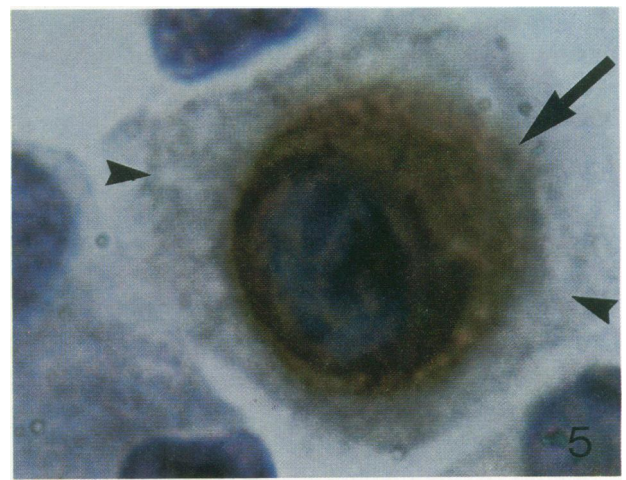
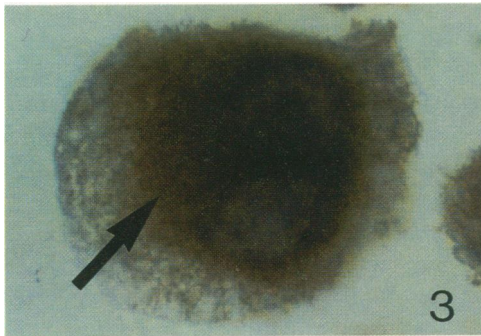
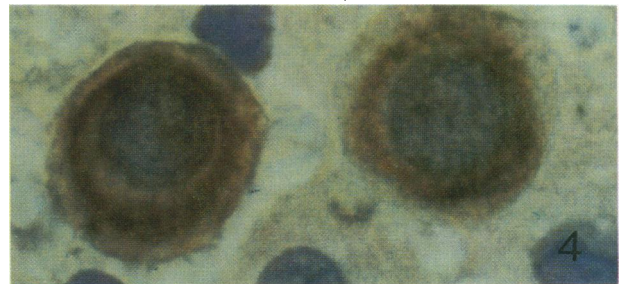
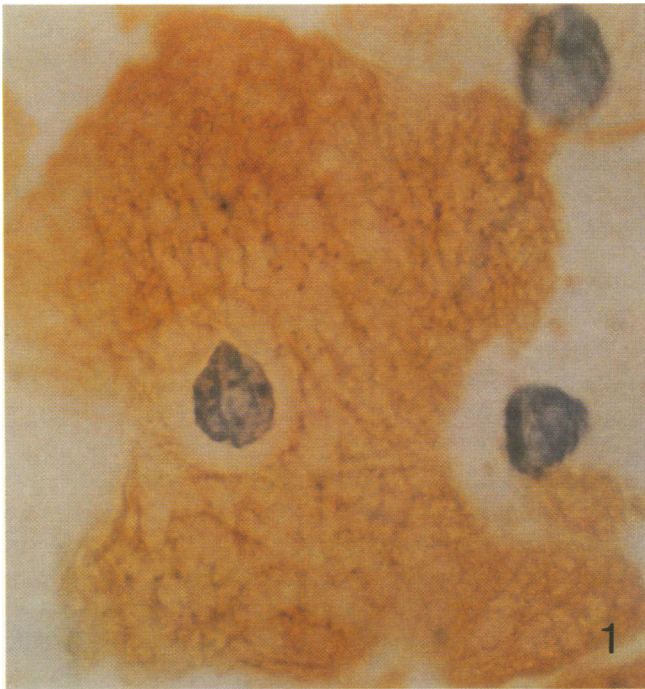
### Results

#### Immunohistochemical Examination of Touch Preparations of Normal Epithelial Cells

When normal squamous and columnar epithelial cells were examined by immunohistochemistry with the prekeratin antiserum, an arborizing or weblike pattern of distribution of prekeratin filaments was seen throughout the cell cytoplasm, with both air-dried and ethanol-fixed preparations (Figure 1).

#### Immunohistochemical Examination of Cells in Effusions

Of the 42 fluids, 27 were benign and contained mesothelial cells, histiocytes, lymphocytes, neutrophils, or a combination of these. Fifteen fluids were



from patients with malignancies (3 malignant mesotheliomas, 1 lymphoma, and 11 adenocarcinomas (ovary, breast, lung, and colon) (Table 1).

When smears prepared from 27 benign fluids were air-dried, there was positive staining by antibody to prekeratin around the periphery of the cytoplasm of over 90% of mesothelial cells, including both mononuclear and multinucleate cells. The perinuclear regions showed no staining (Figure 2). When smears from a similar fluids were fixed in ethanol and then stained with this antibody, a different pattern was observed. Positive staining for prekeratin filaments was now perinuclear in over 90% of both benign and reactive mesothelial cells, with focal accentuation of staining adjacent to one side of the nucleus (Figure 3). Only occasional mesothelial cells showed a peripheral distribution of prekeratin filaments in ethanol-fixed material or a perinuclear distribution in air-dried material. In addition, with both preparations, some cells showed a pattern intermediate between the peripheral and perinuclear distributions (Figure 4).

Smears prepared from 15 malignant fluids were also examined. In the case of the 3 malignant mesotheliomas, only ethanol-fixed smears were available. The malignant mesothelial cells showed a perinuclear pattern with focal accentuation, as seen with benign mesothelial cells fixed in ethanol. Cytologic features of malignancy were easily seen in the nuclei of these cells (Figure 5 and 6). The cytoplasm of lymphoid cells from the single lymphoma (poorly differentiated lymphocytic) did not react with the antibody to prekeratin. In 10 of the adenocarcinomas, an arborizing or weblike pattern of filaments, distributed irregularly throughout the cytoplasm, was seen following treatment with antibody to prekeratin, with the use of both the air-dried and ethanol-fixed material (Figure 7). There was no perinuclear accentuation of the staining pattern. In occasional cell clusters, accentuation suggestive of desmosomes was seen at cell junctions. In one adenocarcinoma involving an ovary and fallopian tube, a mixed pattern was present in the malignant cells, which consisted of perinuclear staining with focal accentuation in some

Table 1—Pattern and Distribution of Prekeratin Filaments in Benign and Malignant Cells in Effusions as Determined by Immunoperoxidase Staining With Anti-Prekeratin Antibody

Type of cell	Type of fixation	
	Air-drying	Ethanol
Benign Mesothelial	Peripheral ring: no perinuclear condensation	Perinuclear with focal accentuation
Malignant Mesothelial	Not done	Perinuclear with focal accentuation
Lymphoid	Negative	Negative
Adenocarcinoma	Arborizing pattern throughout the cytoplasm	Arborizing pattern throughout the cytoplasm

cells and an arborizing pattern throughout the cytoplasm in others. Thus, these tumor cells showed features of both adenocarcinoma and mesothelioma cells. Benign mesothelial cells from all fluids from patients with malignancies showed either the peripheral ring or perinuclear pattern of distribution of prekeratin filaments, depending on whether the fluids were air-dried or ethanol-fixed.

None of the neutrophils or lymphocytes in the benign or malignant fluids reacted with the antibody to prekeratin. Histiocytes showed either no staining or only pale, diffuse cytoplasmic staining, which was much weaker than that seen in mesothelial cells.

### Electron-Microscopic Examination of Cells in Effusions

Of the 27 fluids examined ultrastructurally, 12 were benign and 15 malignant (Table 2). In the electron microscope, benign fluids were seen to contain mesothelial cells that were round or oval, with short microvilli projecting from their surfaces. The nuclear chromatin was uniformly distributed, and an occasional nucleolus was observed. The cytoplasm contained numerous organelles, including mitochondria, smooth and rough endoplasmic reticulum, and ribosomes. Intermediate filaments, which were aggregated to form tonofilaments, were also prominent

←  
**Figures 1-7**—Immunoperoxidase staining of normal epithelial cells, mesothelial cells, and adenocarcinoma cells using antibody to prekeratin. All of the slides were counterstained with hematoxylin. **Figure 1**—Normal squamous cell, alcohol-fixed, showing brown, weblike pattern of prekeratin filaments distributed irregularly throughout the cytoplasm. ( $\times 2000$ ) **Figure 2**—Benign mesothelial cells, air-dried, showing a brown ring (*arrow*) at the periphery of the cytoplasm. The nucleus has a benign appearance. ( $\times 2000$ ) **Figure 3**—Benign binucleate mesothelial cell, alcohol-fixed, showing a perinuclear location of prekeratin filaments with focal accentuation (*arrow*) adjacent to one side of the nucleus. ( $\times 2000$ ) **Figure 4**—Benign mesothelial cells, air-dried, showing the brown ring midway between the cell periphery and nucleus. ( $\times 2000$ ) **Figure 5**—Malignant mesothelial cell, showing a perinuclear distribution of prekeratin filaments, with focal accentuation adjacent to the nucleus (*arrow*). The rest of the cytoplasm is unstained (*arrowheads*). ( $\times 2000$ ) **Figure 6**—A multinucleated, malignant mesothelial cell, showing focal accentuation of prekeratin filaments adjacent to the nucleus. The nuclei are irregular, with prominent nucleoli. ( $\times 2000$ ) **Figure 7**—Adenocarcinoma cells in a cluster, showing an arborizing or weblike pattern distributed irregularly throughout the cytoplasm. The nuclei show features of malignancy. ( $\times 2000$ ) (With a photographic reduction of 8%)

Table 2—Pattern and Distribution of Intermediate Filaments in Benign and Malignant Cells in Effusions and Tissue Sections as Determined by Transmission Electron Microscopy

Type of cell	Ultrastructural pattern of intermediate filaments
<b>Benign</b>	
Mesothelial	Aggregated intermediate filaments form concentric perinuclear ring with focal accentuation; they are not seen at the cell periphery
<b>Malignant</b>	
Mesothelial	Same as benign
Lymphoid	Occasional, random intermediate filaments, which correspond to vimentin
Adenocarcinoma	Intermediate filaments arranged randomly throughout the cytoplasm

in the cytoplasm. They formed a concentric perinuclear ring, with a focal area of accentuation adjacent to the nucleus, and were not noted at the periphery of the cells (Figure 8). In mesothelial cells in which the plane of section did not traverse the nucleus, bundles of intermediate filaments, which had condensed into tonofilaments, were seen in the center of the cell. Smears prepared from fluids in which the mesothelial cells formed clusters showed a similar distribution of intermediate filaments. Tight junctions and desmosomes were seen.

On the 15 malignant fluids examined by electron microscopy, 1 was from a malignant mesothelioma, 1 was from a lymphoma, and 13 were from adenocarcinomas. The mesothelial cells from the single case of malignant mesothelioma were mainly in clusters, consisting of a few cells separated by lacunae and bordered by bushy, slender microvilli that also projected from the cell surface. These cells were joined together by desmosomes. Occasional intracellular luminae were noted. In addition to various cytoplasmic organelles, these mesothelial cells contained intermediate filaments arranged in aggregates and forming a concentric perinuclear ring with focal juxtanuclear accentuation. Desmosome-associated tonofilaments were also noted. The pattern of distribution of intermediate filaments was similar to that seen in benign mesothelial cells. Cells from the case of malignant lymphoma showed irregular nuclei with prominent nucleoli. Their cytoplasm was scanty and contained only occasional intermediate filaments, which have been shown in previous immunofluorescence studies to consist of vimentin.<sup>13</sup>

The tumor cells constituting the adenocarcinomas had variable ultrastructures. They were arranged in clusters, which formed either solid sheets or acini around a central lumen. Their nuclei were often indented and possessed one or more irregular nucleoli.

Organelles in the cytoplasm included abnormally shaped mitochondria, dilated smooth and rough endoplasmic reticulum, mucous vacuoles, and intermediate filaments. In 12 of the adenocarcinomas, the intermediate filaments were arranged randomly as nonaggregated, short filaments spread throughout the cytoplasm (Figure 9A and B), although occasionally they formed a perinuclear whorl. These filaments did not become aggregated to form tonofilaments, as was the case in mesothelial cells.

Most of the adenocarcinoma cells possessed short, club-shaped microvilli, which projected from the cell surface (Figure 9A). However, tall, bushy microvilli, similar to those seen in the malignant mesothelioma cells, were noted in some adenocarcinomas. In one fluid, from a case of adenocarcinoma in which a mixed pattern was demonstrated by immunoperoxidase staining using antibody to prekeratin, the malignant cells also showed a mixed pattern by electron microscopy (ie, some cells demonstrated a concentric perinuclear ring with aggregation of intermediate filaments into tonofilaments, characteristic of mesothelial cells, whereas others showed a random distribution of filaments throughout the cytoplasm, characteristic of adenocarcinoma cells).

Histiocytes contained intermediate filaments in their cytoplasm that were often arranged into ag-

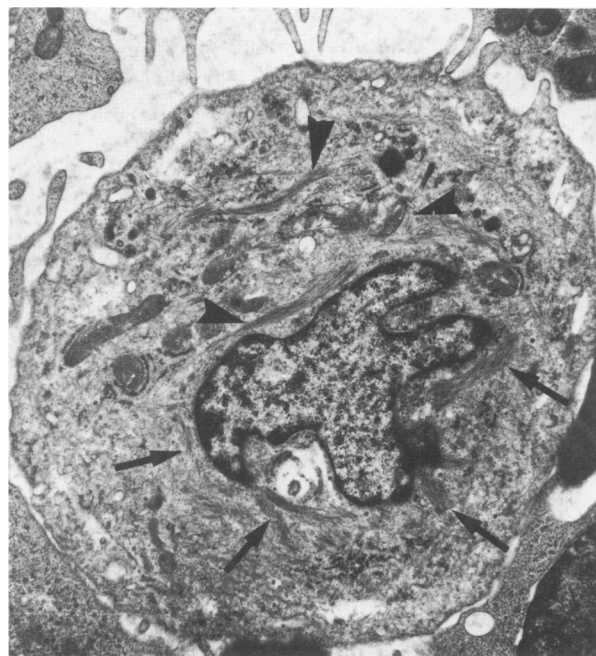
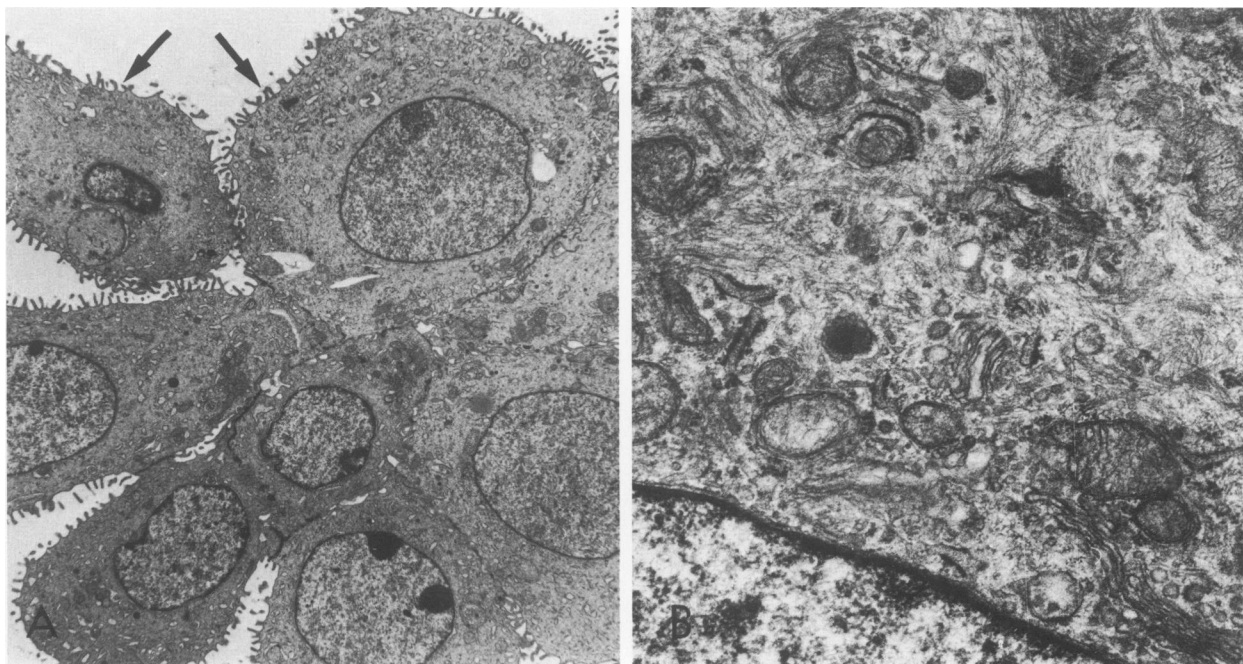


Figure 8—Electron micrograph of a benign mesothelial cell in an effusion. Intermediate filaments are aggregated into tonofilaments, forming an interrupted concentric perinuclear ring (arrows) with a focal area of accentuation adjacent to the nucleus (arrowheads). ( $\times 10,000$ )



**Figure 9A**—Cluster of adenocarcinoma cells showing short, club-shaped microvilli (arrows) projecting from the surface. ( $\times 3000$ ) **B**—Random arrangement of intermediate filaments in the cytoplasm of an adenocarcinoma cell. ( $\times 27,000$ )

gregates or concentric whorls around the nucleus; but, unlike the filaments seen in mesothelial cells, they did not form tonofilaments. Previously we found that these intermediate filaments stained positively with anti-vimentin antiserum, and thus they represent vimentin (unpublished observation).

No intermediate filaments were noted in lymphocytes in either benign or malignant fluids.

#### Electron-Microscopic Examination of Tissues

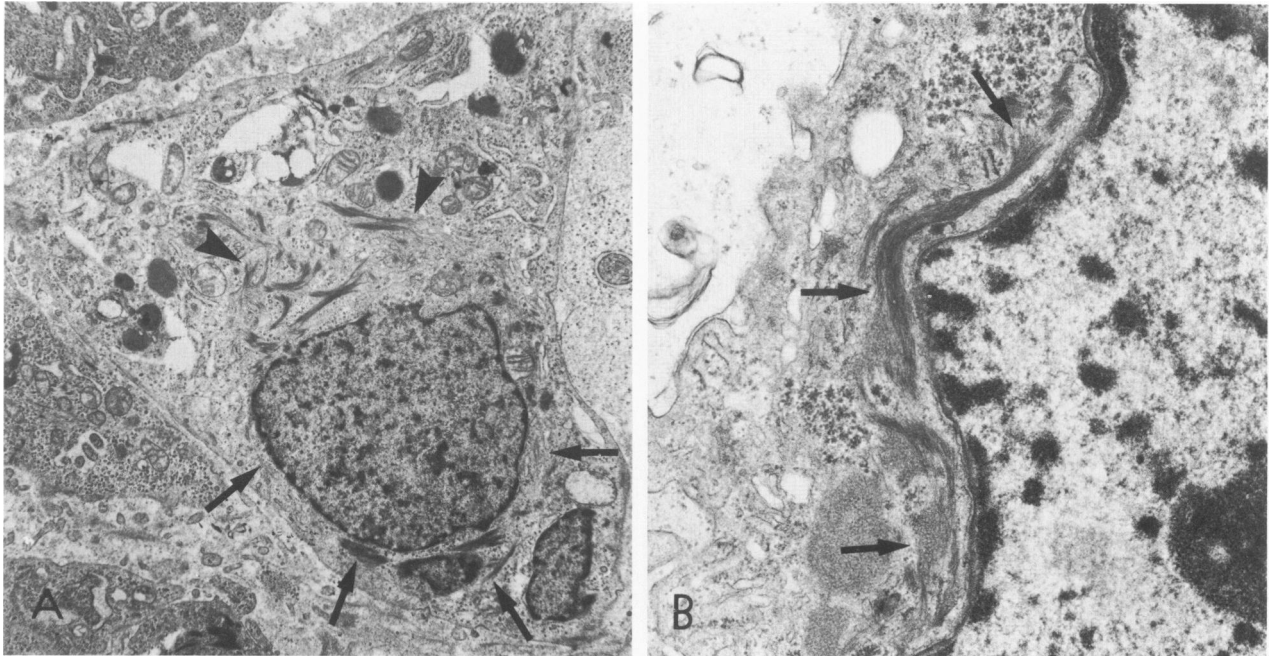
The distribution of intermediate filaments was studied in tissues from 3 malignant mesotheliomas and 10 adenocarcinomas (breast, lung, ovary, and colon). Tumor cells in the malignant mesotheliomas (Figure 10A and B) and adenocarcinomas showed the same pattern of intermediate filaments as that seen in the benign and malignant mesothelial and adenocarcinoma cells in fluids, except for one infiltrating duct carcinoma of the breast, which showed some aggregation of intermediate filaments into randomly arranged tonofilaments.

#### Discussion

Clinical (a history of exposure to asbestos and exclusion of an adenocarcinoma elsewhere) and pathologic features (gross appearance of tumor as well as histologic appearance) and histochemical examina-

tion (the presence of hyaluronic acid in the cytoplasm of tumor cells) are useful in making a diagnosis of malignant mesothelioma. Wang<sup>5</sup> described the ultrastructural features of the epithelial form of mesothelioma in tissue sections and stressed the presence of tall, slender, and bushy microvilli in tumor cells. Although the microvilli in most adenocarcinoma cells are short and club-shaped, they are occasionally long and bushy, so that this cannot be considered an absolute diagnostic criterion for mesothelioma. Legrand and Pariente<sup>7</sup> described the ultrastructure of malignant cells obtained from pleural fluid in a case of malignant mesothelioma, while Suzuki et al<sup>6</sup> described the fine structure of malignant mesothelioma cells in tissue sections and compared them with the fine structure of tumor cells in peritoneal fluid. Although Legrand and Pariente<sup>7</sup> and Suzuki et al<sup>6</sup> commented on the presence of intermediate filaments and tonofilaments in tumor cells, they did not discuss the pattern or distribution in cell cytoplasm. However, Domagala and Woyke<sup>8</sup> and Murad<sup>19</sup> did observe that intermediate filaments were distributed around the nuclei of mesothelial cells in effusions.

Several studies have been performed in which immunologic markers were used to aid in the diagnosis of malignant mesothelioma and adenocarcinoma. Secretory component has been demonstrated immunohistochemically in both types of tumor and is not useful in distinguishing them.<sup>20</sup> Carcinoembry-



**Figure 10A** — Electron microscopy of a malignant mesothelial cell in tissue from a case of malignant mesothelioma. Intermediate filaments aggregated into tonofilaments form an interrupted perinuclear concentric ring (arrows) with a focal area of condensation adjacent to the nucleus (arrowheads). ( $\times 6000$ ) **B** — High-power magnification of a malignant mesothelioma cell in tissue from a case of malignant mesothelioma, demonstrating a perinuclear arrangement of intermediate filaments, which are focally aggregated to form tonofilaments (arrows). ( $\times 27,720$ )

onic antigenlike material has been demonstrated in adenocarcinoma of the lung but not in mesothelioma.<sup>21</sup> Singh et al<sup>22</sup> demonstrated that antimethelial antibodies differentiated 2 cases of malignant mesothelioma from adenocarcinoma, using indirect immunofluorescence staining. However, benign mesothelial cells also stained positively and had to be differentiated from malignant mesothelioma cells with the use of other cytologic criteria. Coleman et al<sup>23</sup> showed a qualitative difference in the expression of epithelial membrane antigen on mesothelial and adenocarcinoma cells in effusions. Studies have not previously been performed on the ability of antibody to prekeratin to differentiate mesothelial and adenocarcinoma cells.

Intermediate filaments of the prekeratin type have been demonstrated in tissue sections of normal epithelial cells, both ectodermal and endodermal, and their malignant counterparts, by immunofluorescence and immunoperoxidase techniques. Using immunoperoxidase staining on formalin-fixed, paraffin-embedded tissue, Schlegel et al<sup>10</sup> demonstrated prekeratin filaments in tissue sections containing normal epidermis; epidermal appendages; cervical, vaginal, and breast epithelia; pancreatic and salivary gland ducts; and basal layers of endocervical and prostatic glands. Staining varied in intensity from weakly to strongly positive, and no pattern could be seen in the

distribution of the prekeratin filaments. Schlegel et al<sup>11</sup> also described the presence of prekeratin filaments in tissue sections of tumors derived from epithelium, including basal and squamous cell carcinoma of the skin, mesothelioma, transitional cell carcinoma, squamous cell carcinoma of the cervix, and adenocarcinoma of the pancreas. They reported weak staining for prekeratin in adenocarcinoma of the breast and lung. However, in these studies the tissues were not incubated with proteolytic enzymes.

Sieinski et al<sup>12</sup> studied whether prekeratin filaments were present in Bouin's-fixed, paraffin-embedded tissue sections, using an indirect immunofluorescence technique. They showed weak positive staining of a variety of adenocarcinomas derived from colon, lung, and breast and metastatic adenocarcinomas of unknown origin. No pattern of staining was seen within the cell cytoplasm.

Gabbiani et al<sup>13</sup> also studied a variety of tumors, including adenocarcinomas, by an indirect immunofluorescence technique, using cryostat-cut, frozen tissue sections. They demonstrated positive staining of adenocarcinomas of colon, rectum, and prostate. However, staining was less intense than with squamous cell carcinomas. They also obtained strong staining for prekeratin in ductal and lobular breast carcinomas, in contrast to the weak staining obtained by Schlegel et al.<sup>11</sup> These differences may well have

been due to the different methods of fixation and immunostaining used in these studies.

Franke et al,<sup>14,16</sup> using immunofluorescence microscopy, reported that prekeratin filaments were distributed in a complex meshwork in PtK2 rat kangaroo cells, mouse kidney epithelium, mouse epidermis, cow mammary gland epithelium, and human HeLa cells cultured *in vitro*. They also described a meshwork of prekeratin filaments forming an arborizing arrangement in dissociated epithelial cells from the bladder, trachea, and intestine of the rat and cow.<sup>17</sup> No perinuclear or peripheral cytoplasmic distribution of prekeratin filaments was described.

In the present study, we have characterized the pattern and distribution of prekeratin filaments in touch preparations of normal epithelial cells and smears prepared from effusions. We have also studied ultrastructurally the distribution of intermediate filaments in cells in effusions and tissue sections.

The perinuclear pattern of distribution of prekeratin filaments in benign mesothelial cells fixed in ethanol and stained using an immunoperoxidase reaction with antibody to prekeratin was different from the peripheral ring distribution seen in the same cells fixed by air-drying. An occasional transitional pattern from these two extremes was noted with both types of fixation. We hypothesize that rapid fixation of the smears in ethanol immobilized cytoplasmic organelles and intermediate filaments. Consequently, a perinuclear distribution of prekeratin filaments, with focal perinuclear accentuation, is seen in both benign and malignant mesothelial cells. In contrast, with air-drying, the cytoplasm expands and prekeratin filaments move to a peripheral position in the cell. Hence, the peripheral ring pattern seen in benign mesothelial cells is likely artifactual. This suggestion is confirmed by ultrastructural studies of mesothelial cells, in which intermediate filaments were found to form a concentric perinuclear ring with a focal area of accentuation (Figure 8). No peripheral distribution of prekeratin filaments was observed in the cells with the use of electron microscopy. The fact that mesothelial cells showed either a perinuclear or peripheral distribution of prekeratin filaments was useful as an aid in differentiating mesothelial from adenocarcinoma cells. In the latter, immunoperoxidase staining with antibody to prekeratin showed a totally different pattern (arborizing throughout the cytoplasm), similar to that described by Franke et al in cultured human HeLa and cow mammary cells.<sup>14,16</sup>

A weblike pattern was demonstrated in normal epithelial cells, both columnar cells and squames, using our methods of fixation and immunoperoxidase staining. Although one may argue that mucin vacuoles

were present in the columnar cells, and that this led to distortion of the filament pattern, nevertheless, a similar pattern was seen in the squamous cells, which did not demonstrate any vacuolar degeneration.

The distorted weblike pattern of filaments was also seen in mucin producing adenocarcinomas, where vacuoles were prominent. In other adenocarcinomas, no vacuolization was seen by light microscopy or ultrastructurally. Nevertheless, a weblike pattern was also seen in these tumors. Thus, it would appear that all adenocarcinomas showed the same distribution of prekeratin filaments. Although occasional mesothelial cells were vacuolated, and this could distort the pattern of filaments in them, nevertheless, the majority of mesothelial cells did not contain vacuoles. The fact that the pattern and distribution of prekeratin filaments in mesothelial cells differed from that in adenocarcinoma cells may be related to the derivation of mesothelial cells from mesoderm, whereas adenocarcinomas are either ectodermal or endodermal in origin.

The distribution of prekeratin filaments in adenocarcinoma cells correlated well with their electron-microscopic appearance. Thin aggregates of intermediate filaments were seen by electron microscopy to be arranged randomly throughout the cytoplasm, often attached to desmosomes. This corresponded to the fibrillar meshwork of prekeratin filaments seen by immunoperoxidase staining in these cells. Even in adenocarcinomas that showed condensation of intermediate filaments around the nucleus, the filaments were fine and were not aggregated into tonofilaments. These intermediate filaments were similar to those seen in the perinuclear region of histiocytes, except that the filaments in histiocytes were more continuous and did not show the interrupted pattern characteristic of adenocarcinoma cells. Moreover, histiocytes either stained negatively with antibody to prekeratin or were only weakly positive. Intermediate filaments in histiocytes were found to be of the vimentin type (unpublished observation). Weak positive staining of histiocytes could be due to ingestion of prekeratin filaments from degenerating epithelial cells.

Ghadially<sup>9</sup> has suggested that the accumulation of intermediate filaments in the cytoplasm of tumor cells is a sign of degeneration or impending necrosis. However, this does not explain the difference in location or pattern of intermediate filaments noted in mesothelial and adenocarcinoma cells, unless it is assumed that one degenerates more easily than the other. Moreover, similar patterns of intermediate filaments were noted in tissues and effusions, further emphasizing that the results obtained with the latter



were not artifactual. The juxtacellular filamentous aggregates in a papillary adenocarcinoma of the endometrium noted by Hameed and Morgan<sup>24</sup> do not appear to be similar to the pattern seen in mesothelial cells in the present study.

Benign and malignant mesothelial cells could not be distinguished from each other by ethanol fixation of immunostained smears. However, in both benign and malignant mesothelial cells, the pattern and distribution of prekeratin filaments (as assessed immunohistochemically) and intermediate filaments (as assessed ultrastructurally) were entirely different from those in adenocarcinoma cells. Thus, the pattern and distribution of prekeratin and intermediate filaments appear to be useful diagnostic criteria for differentiating reactive mesothelial cells and mesothelial tumors from adenocarcinomas.

### References

1. McCaughey WTE: Criteria for diagnosis of diffuse mesothelial tumors. *Ann NY Acad Sci* 1965, 132:603-613
2. Naylor B: The exfoliative cytology of diffuse malignant mesothelioma. *J Pathol Bacteriol* 1963, 86:293-298
3. Roberts GH, Campbell GM: Exfoliative cytology of diffuse mesothelioma. *J Clin Pathol* 1972, 25:577-582
4. Kannerstein M, Churg J: Peritoneal mesothelioma. *Hum Pathol* 1977, 8:83-94
5. Wang NS: Electron microscopy in the diagnosis of pleural mesotheliomas. *Cancer* 1973, 71:1046-1054
6. Suzuki Y, Churg J, Kannerstein M: Ultrastructure of human malignant diffuse mesothelioma. *Am J Pathol* 1976, 85:241-262
7. Legrand M, Pariente R: Ultrastructural study of pleural fluid in mesothelioma. *Thorax* 1974, 29:164-171
8. Domagala W, Woyke S: Transmission and scanning electron microscopic studies of cells in effusions. *Acta Cytol (Baltimore)* 1975, 19:214-224
9. Ghadially FN: Diagnostic electron microscopy of tumours. London, Butterworths, 1980, pp 120-121
10. Schlegel R, Banks-Schlegel S, Pinkus GS: Immunohistochemical localization of keratin in normal human tissues. *Lab Invest* 1980, 42:91-96
11. Schlegel R, Banks-Schlegel S, McLeod JA, Pinkus GS: Immunoperoxidase localization of keratin in human neoplasms: A preliminary survey. *Am J Pathol* 1980, 101: 41-49
12. Sieinski W, Dorset B, Ioachim HL: Identification of prekeratin by immunofluorescence staining in the differential diagnosis of tumours. *Hum Pathol* 1981, 12:452-457
13. Gabbiani G, Kapanci Y, Barazzone P, Franke WW: Immunohistochemical identification of intermediate-sized filaments in human neoplastic cells: A diagnostic aid for the surgical pathologist. *Am J Pathol* 1981, 104: 206-216
14. Franke WW, Weber K, Osborn M, Schmid E, Freudenstein C: Antibody to prekeratin. Decoration of tonofilament-like arrays in various cells of epithelial character. *Exp Cell Res* 1978, 116:429-445
15. Sun TT, Green H: Immunofluorescent staining of keratin fibers in cultured cells. *Cell* 1978, 14:469-476
16. Franke WW, Schmid E, Osborn M, Weber K: Different intermediate-sized filaments distinguished by immunofluorescence microscopy. *Proc Natl Acad Sci USA* 1978, 75:5034-5038
17. Franke WW, Appelhans B, Schmid E, Freudenstein C, Osborn M, Weber K: Identification and characterization of epithelial cells in mammalian tissues by immunofluorescence microscopy using antibodies to prekeratin. *Differentiation* 1979, 15:7-25
18. Sternberger LA, Hardy PH Jr, Cuculis JJ, Meyer HG: The unlabelled antibody enzyme method of immunohistochemistry: Preparation and properties of soluble antigen-antibody complex (horse-radish peroxidase-anti-horse radish peroxidase) and its use in identification of spirochetes. *J Histochem Cytochem* 1970, 18: 315-333
19. Murad TM: Electron microscopic studies of cells in pleural and peritoneal effusions. *Acta Cytol (Baltimore)* 1973, 17:401-409
20. Ernst CS, Brooks JJ: Immunoperoxidase localization of secretory component in reactive mesothelium and mesotheliomas. *J Histochem Cytochem* 1981, 29:1102-1104
21. Wang NS, Huang SN, Gold P: Absence of carcinoembryonic antigen-like material in mesothelioma: An immunohistochemical differentiation from other lung cancers. *Cancer* 1979, 44:937-943
22. Singh G, Whiteside TL, Dekker A: Immunodiagnosis of mesothelioma: Use of antimesothelial cell serum in an indirect immunofluorescence assay. *Cancer* 1979, 43:2288-2296
23. Coleman DV, To A, Ormerod MG, Dearnaley DP: Immunoperoxidase staining in tumour marker distribution studies in cytologic specimens. *Acta Cytol (Baltimore)* 1981, 25:205-206
24. Hameed K, Morgan DA: Papillary adenocarcinoma of endometrium with psammoma bodies: Histology and fine structure. *Cancer* 1972, 29:1326-1335

### Acknowledgments

The authors wish to thank Susan Azam, Olga Chaban, and Winnie Wellstead for their excellent technical assistance.