

## ANIMAL MODEL OF HUMAN DISEASE

# *Lymphocytic Thyroiditis*

## *Autoimmune Thyroiditis in Rats Induced by Thymectomy and Irradiation*

W. J. PENHALE, PhD, BVSc, MRCVS, Dip Bact,  
and S. ANSAR AHMED, BSc, BVSc,

*Division of Veterinary Biology, School of Veterinary Studies,  
Murdoch University, Murdoch, Western Australia*

### **Biologic Features**

Pathologic changes in the thyroid glands can be regularly induced in certain strains of rat by early thymectomy (21 days of age) and sublethal irradiation ( $4 \times 250$  rad).<sup>1,2</sup> No such changes were found in untreated or sham thymectomized controls (Figure 1). Evidence to indicate that this effect is of autoimmune origin includes the histologic appearance of the lesion and the detection of persistent high titers of antibodies to thyroid components.<sup>1,2</sup> The lesion is characterized by severe infiltration of mononuclear and plasma cells with destruction of the follicular architecture. (Figure 2). Total destruction of thyroid follicles is not uncommonly observed. The irradiation treatment has been shown to be neither an initiator nor a potentiator of the lesions in the thyroids.<sup>1,3</sup> The thymectomy and irradiation schedule (Tx-X) have appreciable effects on the immune system; rats are lymphopenic, are T-cell-depleted, and have reduced spleen weight with low recovery of splenocytes; and there is also an increased proportion of immunoglobulin-bearing cells within peripheral lymph nodes.<sup>4</sup>

The immunopathologic change initiated by Tx-X treatment is believed to be the consequence of selective elimination of natural autoregulatory suppressor T cells which are radiation-sensitive. Reconstitution of Tx-X-treated rats shortly after irradiation with normal lymphoid cells, particularly of lymph node origin, abrogated the development of the disease.<sup>4</sup> This substantiates the inference that the thyroid changes are a result of selective depletion of auto-

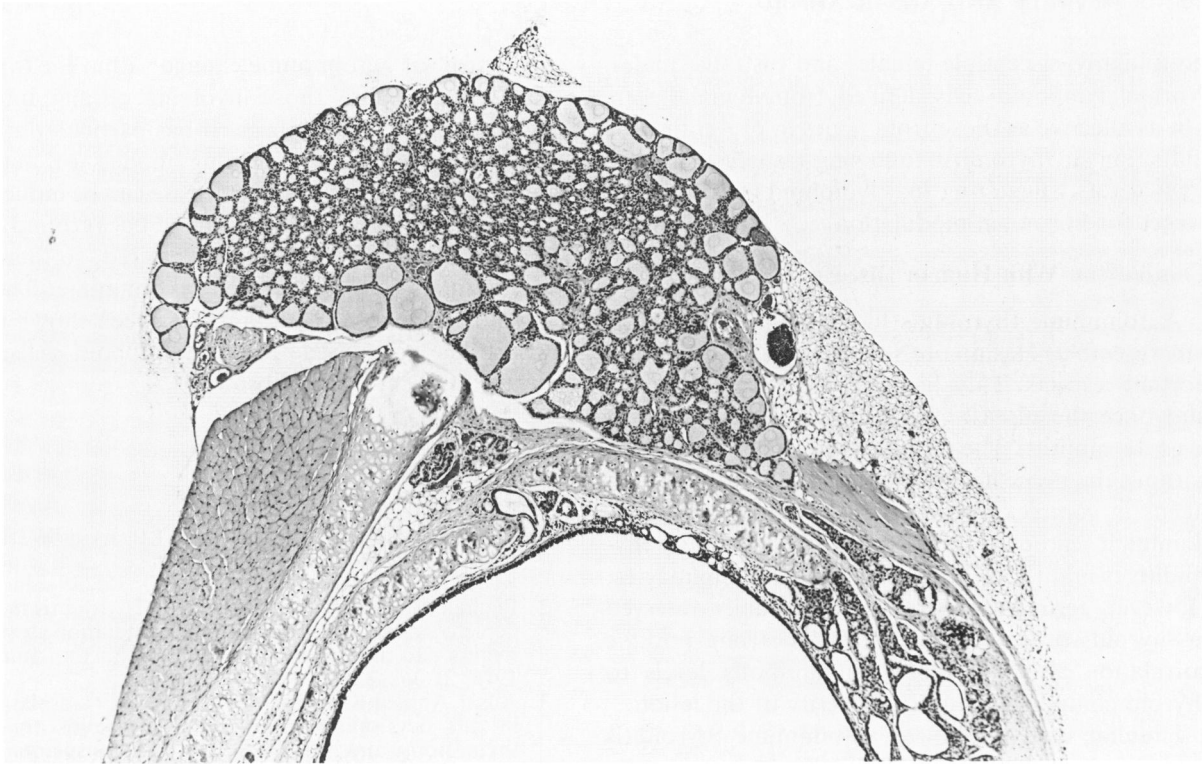
regulatory T cells. The suppressor T-cell-depleted state is reflected in the ability of Tx-X-treated rats to be better responders than normal control rats to a variety of antigens.<sup>5</sup> This deficit was confirmed by the failure of Tx-X-derived lymphocytes to prevent the development of thyroiditis following transfer to Tx-X counterparts.

Marked strain differences in susceptibility to the induction of autoimmune thyroiditis by this means was observed, indicating genetic influences were important in the expression of the disease. Although this influence was confirmed by cross-breeding studies, no association was found with the major histocompatible complex.<sup>6</sup>

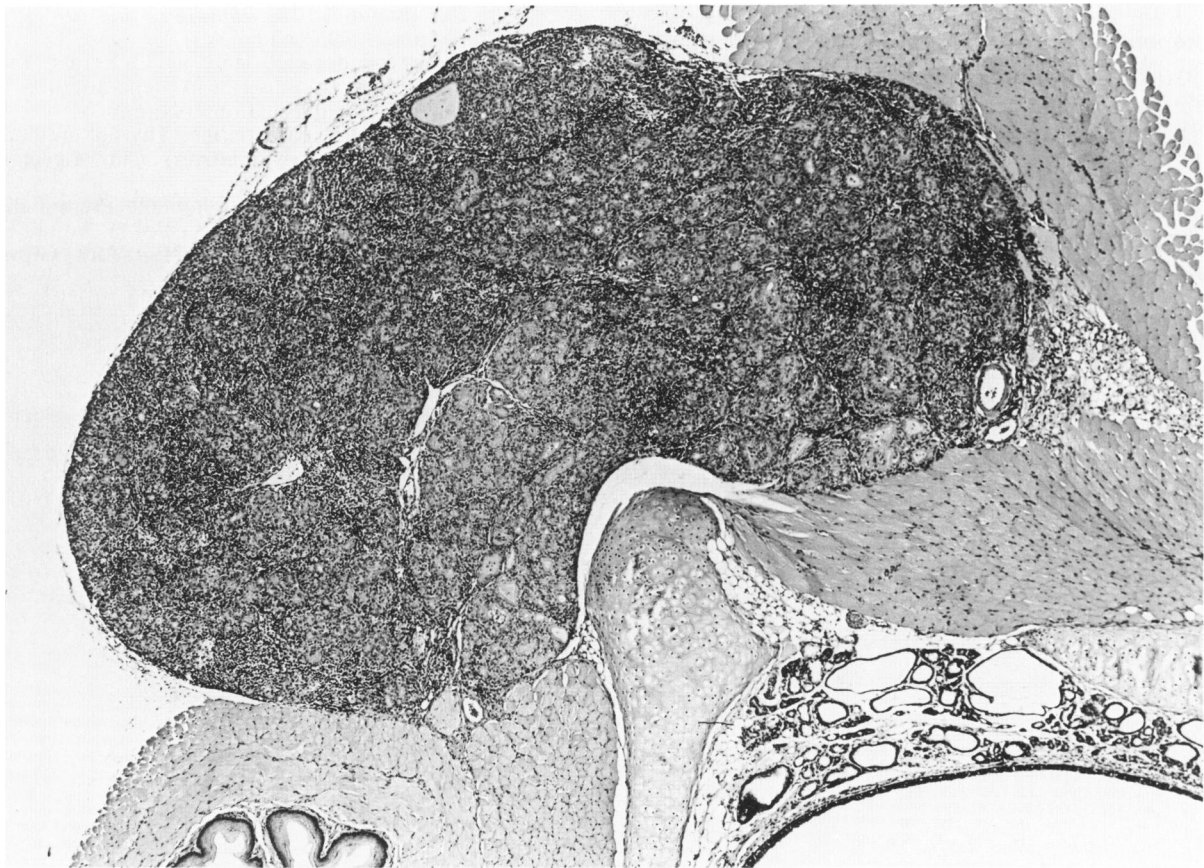
Sex also has profound influence on the development of the disease. Female Tx-X rats had a much greater incidence of the disease than males (four-fold). Gonadectomy, particularly in males, strikingly enhanced the development of the disease (from 14% to 70%) indicating a modulatory influence of sex hormones rather than a sex-linked genetic effect. Furthermore, testosterone treatment reduced or prevented the development of autoimmune thyroiditis in

---

Publication sponsored by the Registry of Comparative Pathology of the Armed Forces Institute of Pathology and supported by Public Health Service Grant RR-00301 from the Division of Research Resources, National Institutes of Health, under the auspices of Universities Associated for Research and Education in Pathology, Inc. Address reprint requests to Associate Professor W. J. Penhale, School of Veterinary Studies, Murdoch University, Murdoch 6150, Western Australia.



**Figure 1**—H&E-stained section of the thyroid gland of a normal female PVG/c rat. ( $\times 48$ )



**Figure 2**—H&E-stained section of the thyroid gland of a thymectomized and irradiated female PVG/c rat. There is enlargement, severe lymphocytic infiltration, and loss of follicular architecture. ( $\times 48$ )

both highly susceptible females and castrated males. Normal lymphoid cells derived from females were not as effective as those from males in preventing the induction of thyroiditis following transfer to Tx-X-treated rats, suggesting that lymphoid cells were the target for hormonal modulation.

### Comparison With Human Disease

Autoimmune thyroiditis induced in Tx-X-treated rats resembles Hashimoto's thyroiditis in several important respects. This disease is of a chronic nature; and once the disease is established, persists for at least 18 months. The lesion develops spontaneously without the necessity for immunization with autoantigens in complex adjuvants. Furthermore, the predominant feature of the lesion as in Hashimoto's thyroiditis is infiltration with mainly small lymphocytes. However, germinal centers were not usually observed in thyroids of Tx-X-treated rats. A strong positive correlation also exists between antibody levels to thyroid components and the severity of the lesion.

Familial susceptibility to autoimmune thyroiditis in man is well recognized.<sup>7</sup> Similarly, genetic factors (non-MHC-related) play a role in the autoimmune susceptibility in Tx-X-treated rats.

Finally, middle-aged women have a greater preponderance of Hashimoto's thyroiditis than men (hypercellular variant—female/male ratio—30:1; fibrous variant female/male 4:1).<sup>8</sup> A similar sex-related pattern occurs in Tx-X-treated rats.

### Usefulness of the Model

This model is a convenient one in which to investigate the basic mechanisms underlying the de-

velopment of autoimmune change within the thyroid gland, particularly those involving cellular interactions and genetic influences. It has particular advantages over naturally occurring models of autoimmune thyroiditis, in that the disease can be induced in normal animals of defined genetic background. The disease can be manipulated as required, so that normal animals can be rendered autoimmune. The expression of this autoimmunity has been shown to be susceptible to modulation by lymphoid cells, antigens, and steroid sex hormones.

### References

1. Penhale WJ, Farmer A, McKenna RP, Irvine WJ: Spontaneous thyroiditis in thymectomized and irradiated wistar rats. *Clin Exp Immunol* 1973, 15:225-236
2. Penhale WJ, Farmer A, Irvine WJ: Thyroiditis in T-cell depleted rats: Influence of strain, radiation dose, adjuvants and antilymphocyte serum. *Clin Exp Immunol* 1975, 21:362-375
3. Ansar Ahmed S, Penhale WJ: Thyroid transplantation in rats developing autoimmune thyroiditis following thymectomy and irradiation: Thyroid transplantation in thyroiditis. *Clin Exp Immunol* 1981, 45:480-486
4. Penhale WJ, Irvine WJ, Inglis JR, Farmer A: Thyroiditis in T-cell depleted rats: Suppression of the autoallergic response by reconstitution with normal lymphoid cells. *Clin Exp Immunol* 1976, 25:6-16
5. Ansar Ahmed S, Penhale WJ: Evidence for natural suppressor cell depleted state in Tx-X rats: Immune response studies. (Manuscript in preparation)
6. Penhale WJ: Unpublished observations
7. Hall R, Dingle PR, Roberts DF: Thyroid antibodies, a study of first degree relatives. *Clin Genet* 1975, 3:319-324
8. Doniach D, Roitt IM: Autoimmune thyroid disease, *Textbook of Immunopathology*. Vol II. Edited by PA Miescher, HJ Müller-Eberhard. New York, Grune and Stratton, 1976, pp 715-734