

Pathologic and Virologic Study of Fatal Lassa Fever in Man

DAVID H. WALKER, MD,
JOSEPH B. McCORMICK, MD,
KARL M. JOHNSON, MD,
PATRICIA A. WEBB, MD
GEORGE KOMBA-KONO, MD,
LUANNE H. ELLIOTT, MS,
and JARED J. GARDNER, MD

From the Department of Pathology, University of North Carolina School of Medicine, Chapel Hill, North Carolina; the Viral Diseases Division, Center for Infectious Diseases, Center for Disease Control, Atlanta, Georgia; the U.S. Army Medical Research Institute of Infectious Diseases, Fort Detrick, Frederick, Maryland; and the Ministry of Health, Kenema, Sierra Leone, West Africa

Postmortem examination of 21 virologically documented cases of Lassa fever, including 6 complete autopsies, was performed as part of a field study of community-acquired Lassa fever in Sierra Leone. The most consistently observed lesions were hepatocellular, adrenal, and splenic necrosis and adrenal cytoplasmic inclusions. Neither these lesions, nor other milder and less constantly observed lesions such as myocarditis, renal tubular injury, and interstitial pneumonia, appeared severe enough to explain the cause of death in

Lassa fever. The central nervous system (CNS) contained no specific lesions. Viral titrations demonstrated high viral content in liver, lung, spleen, kidney, heart, placenta, and mammary gland. Clinical laboratory data included elevation of hepatic enzymes, creatine phosphokinase (CPK), and blood urea nitrogen (BUN). Because of the paucity of pathologic lesions in spite of widely disseminated viral infection, further investigation of humoral inflammatory mechanisms is indicated. (Am J Pathol 1982, 107:349-356)

LASSA FEVER was first recognized in 1969 in an outbreak of 3 cases involving missionary nurses in Nigeria.¹ The etiologic agent was demonstrated to be a virus serologically and taxonomically related to lymphocytic choriomeningitis virus and other arenaviruses.²⁻⁵ Although subsequent studies have shown the reservoir to be persistently infected, rodents of the species *Mastomys natalensis*^{6,7} and have documented endemic disease with a relatively low mortality rate,⁸⁻¹⁰ the pathogenesis of Lassa fever is still not known. Previous reports of the pathologic lesions in Lassa fever have included histopathologic studies of relatively complete autopsies of four cases and of only the liver in an additional four cases.¹¹⁻¹⁴ Some organs such as the brain which had been examined only once, were particularly lacking in microscopic evaluation. Most reported cases have been either nosocomial or laboratory acquired. We report our observations in 6 complete autopsies, 15 cases with postmortem biopsies of tissues other than liver, and 7 fetuses of infected women. Clinical laboratory data and virologic titers of the organs are presented. This autopsy study was performed as a portion of a long-term clinical and laboratory investigation of community-acquired Lassa fever in Sierra Leone.¹⁵

Materials and Methods

Complete postmortem examination was performed in 6 cases of human Lassa fever occurring between 1976 and 1980 as community-acquired infections in Sierra Leone. Tissues were examined from 7 fetuses from women infected with Lassa virus. Postmortem biopsies were collected in an additional 18 patients. All patients were documented to have Lassa fever by viral isolation from either pre-mortem blood or post-mortem tissues. The results of histopathologic study of 16 hepatic biopsies are included in a separate clinicopathologic evaluation of the hepatic disease.¹⁶ Biopsies were done on tissue other than liver in 15 cases. Thus, this investigation is based on interpretation of microscopic sections of postfetal tissues from the following organs and numbers of cases: skeletal muscle, 15; kidney, 9; spleen, 8; liver, lung, and pancreas, 6; heart, 5; small intestine, 4; adrenal, brain,

Supported in part by a contract from the Center for Disease Control.

Accepted for publication January 22, 1982.

Address reprint requests to David H. Walker, MD, Department of Pathology, University of North Carolina School of Medicine, Chapel Hill, NC 27514.

stomach, lymph node, ovary, skin, and uterus, 3; colon and placenta, 2; breast, 1.

Tissues were fixed in neutral-buffered 4% formaldehyde, embedded in paraffin, and sectioned at 6 μ . Sections were stained with hematoxylin and eosin. Selected tissues were stained by phosphotungstic acid hematoxylin (PTAH) for fibrin, phloxine tartrazine for viral inclusions, and orcein for hepatitis B viral carrier state.

Assays for Lassa virus were carried out with Vero 76 cells derived from African green monkey kidney. Vero 76 cells were inoculated into roller bottles and cultured in Eagle's minimum essential medium (EMEM) with 10% fetal calf serum (FCS) with 2 μ g/ml of amphotericin, 100 μ g/ml of penicillin, and 50 μ g/ml of streptomycin. Cells were incubated at 37 C. Monolayers were trypsinized after 24–48 hours, and 1 ml containing approximately 1.2×10^5 cells was inoculated into each screw-capped tissue culture tube. The cultures were incubated at 37 C, and when confluent the cultures were maintained the EMEM with 2% FCS and antibiotics as above.

Tissue was prepared for virus assay by trituration of a 1-g fragment in mortar and pestle with alundum and 9 ml of 0.75% bovine albumin-phosphate-buffered saline (BAPBS). The suspension was centrifuged for 10 minutes at 5 C and 2000 rpm in a Beckman J-21 centrifuge. The supernatant was considered as a 10^{-1} dilution of the tissue. Serial tenfold dilutions of specimens with 10^{-7} as the highest dilution were made in 0.75% BAPBS containing antibiotics as noted. A volume of 0.1 ml of each dilution was inoculated into each of two 16 \times 125-mm screw-capped tissue-culture tubes with 0.9 ml of EMEM. This procedure was performed in the maximum containment laboratory (MCL) at the Center for Disease Control (CDC). The tubes were incubated for 8 days at 37 C. Tubes were assayed for virus content by evaluation of cytopathic effect and by the reverse passive hemagglutination test (RPH).¹⁷

Control titration of the Josiah strain of Lassa virus from a large frozen pool of infected Vero 76 cells ($10^{7.5}$ TCID₅₀/ml) was carried out for each group of tissue titrations. Tubes at the highest dilution with viral antigen as measured by RPH were used to define the end point of virus growth.

Results

Illustrative Case Report (Case 6)

A 24-year-old female native of Sierra Leone delivered a full-term infant at home 10 days prior to the onset of fever. Five days after onset of fever she collapsed at home and was taken to the hospital. On ar-

rival she was conscious but had a blood pressure of 70/50 mm Hg. She reported symptoms of fever, sore throat, headache, malaise, chest pain, and marked flank pain. Physical examination revealed purulent pharyngitis, bilateral conjunctival hemorrhages, and generalized abdominal tenderness. The patient continued to have high fever and intermittent periods of disorientation. She died on the fourth day after hospitalization. Her child subsequently died in her village of a febrile illness.

Virology and Clinical Laboratory Studies

Viral content of the organs which were titrated, and clinical laboratory data, including serum hepatic enzymes, creatine kinase, blood urea nitrogen, and amylase, are presented in Table 1.

Gross Observations

No conspicuous pathologic lesions, other than occasional randomly distributed petechiae, were noted macroscopically.

Microscopic Observations

Few histopathologic lesions were observed regularly except in the liver, spleen, and adrenals. Hepatic lesions usually observed were hepatocellular necrosis, mononuclear phagocytic reaction, and focal hepatocellular cytoplasmic degeneration (Table 2). Unusual features were mitoses (2 cases), centrilobular necrosis (1 case), erythrophagocytosis by Kupffer cells (1 case), fatty metamorphosis (1 case), ground-glass hepatocytes containing hepatitis B virus surface antigen (1 case), and healing granulomas (2 cases). Hepatic necrosis, excluding ischemic centrilobular necrosis, involved a variable proportion of hepatocytes (1–40%) and occurred in a random distribution, both as foci of contiguous cells and as necrosis of individual hepatocytes. Necrosis was either of the desiccation, acidophilic type or of the coagulative type. Some nuclei were fading by lysis; others were pyknotic. Mononuclear phagocytes were observed in contact with and phagocytosing some of the necrotic hepatocytes. This reaction varied from mild to moderate from case to case and varied from absent to moderate from one necrotic focus to another in the same case. However, there was a tendency toward homogeneity of severity of involvement in a particular patient. Focal cytoplasmic degeneration consisted of well-demarcated, spherical, eosinophilic, cytoplasmic structures. These inclusions were observed within many hepatocytes that were otherwise normal as well as within an occasional pathologically altered liver cell.

Splenic necrosis was noted in all 8 cases. In 7 cases, the predominant distribution of necrosis was identifiable as in the marginal zone of the periarteriolar lym-

Table 1—Organ Viral Titers* and Selected Clinical Laboratory Data

Case	Blood	Liver	Spleen	Lung	Kidney	Adrenal	Others	AST†	ALT‡	CPK§	BUN	Amylase¶
1	6.5	0	—	—	—	—	—	1124	131	1604	15	270
2	≥5.0	0	0	—	3.5	—	PI-6.5	2688	305	208	67	30
3	6.1	—	—	—	—	—	—	—	—	—	—	—
4	≥2.9	—	—	—	—	—	—	965	—	—	—	—
5	5.6	2.5	—	—	4.6	—	BM-4.6	3966	1455	4568	76	—
6	5.5	6.0	5.5	6.5	6.0	4.0	MG-7.0, O-6.0, H-5.5, LN-4.5, Pa-4.0, SG-3.5	—	—	—	—	—
9	5.1	0	—	—	—	—	—	2336	299	297	66	1120
10	7.0	6.5	3.5	—	6.5	—	—	—	441	—	—	—
11	6.6	—	—	—	—	—	—	1641	183	611	41	68
12	5.6	—	—	—	—	—	PI-4.6	8	258	305	54	—
13	—	—	—	—	—	—	—	56	37	45	8	38
14	6.1	9.0	9.0	9.0	7.0	—	H-6.5, B-4.5, Pa-4.5	—	—	—	—	—
15	8.1	8.5	7.0	6.5	6.5	6.5	PI-8.0, Pa-6.5, H-6.0, B-5.5	—	—	—	—	—
16	0	0	—	—	4.5	—	—	—	—	—	—	—
17	4.6	—	—	—	—	—	—	687	94	>10,000	74	1325
20	5.1	6.5	—	—	—	—	—	—	—	—	—	—
Fetus 1	—	0	2.0	—	4.0	—	T-0	—	—	—	—	—
Fetus 2	—	0	0	—	0	—	H,Pa,T,PI-0	—	—	—	—	—
Fetus 3	3.5	—	4.8	3.8	3.0	—	PI-7.5	—	—	—	—	—

(No postmortem viral or premortem clinical laboratory data available on cases 7, 8, 18, 19, and 21.)

No viral data available on fetuses 4–7.

B, brain; BM, bone marrow; H, heart; LN, lymph node; MG, mammary gland; O, ovary; Pa, pancreas; PI, placenta, SG, salivary gland; T, thymus.

* Reciprocal log median tissue culture infectious dilution.

† Serum aspartate aminotransferase (SGOT) (normal range 7–27 U/l).

‡ Serum alanine aminotransferase (SGPT) (normal range 8–30 U/l).

§ Serum creatine kinase (normal range 20–130 U/l).

|| Blood urea nitrogen (normal range 8–20 mg/dl).

¶ Serum amylase (normal range 67–104 U/l).

phocytic sheath. In addition to eosinophilic debris of necrotic cells, fibrin was identified in the marginal zone by PTAH stain (Figure 1). In 1 case, multifocal microinfarcts were associated with sickled erythrocytes. Splenic venous subendothelium was infiltrated

by lymphocytes and other mononuclear cells in all 8 cases.

In all 3 cases in which the adrenal glands were examined, prominent cytoplasmic inclusions were present in cells near the junction of zona reticularis and

Table 2—Histopathologic Observations and Interpretation of Liver from Autopsy Cases of Lassa Fever

Case	Necrosis*	Reaction†	Mitoses‡	Focal cytoplasmic degeneration§	Sickling	Schisto¶	Erythrophagocytosis	Cholestasis	Fatty Change**	Interpretation
6	1	M++	0	+	0	0	0	0	0	Active cellular injury
7	10	M++	++	+	0	0	0	0	0	2° Lassa hepatitis††
8	<1‡‡	M+	+	+	0	0	+	0	0	
14	25	M+	0	+	0	0	0	0	0	Peak of severe Lassa hepatitis§§
15	40	M++	0	+	0	0	0	0	0	
19	15	NE	NE	NE	NE	NE	NE	NE	+	Severe autolysis

* Percentage Lassa hepatic necrosis.

† Host reaction to Lassa hepatic necrosis; M = macrophage; P = polymorphonuclear leukocyte; 0, absent; +, mild; ++, moderate.

‡ Mitoses; 0, absent; +, rare; ++, few; +++, moderate.

§ Focal cytoplasmic degeneration; 0, absent; +, present.

|| Sickled erythrocytes.

¶ Schistosome ova.

** Fatty metamorphosis; 0, absent; +, mild; ++, moderate.

†† Criteria are presence of focal cytoplasmic degeneration and <20% necrosis.

‡‡ Centrilobular necrosis involves an additional 20% of liver.

§§ Criteria are presence of >20% necrosis, Lassa hepatitis type.

NE, not evaluated.

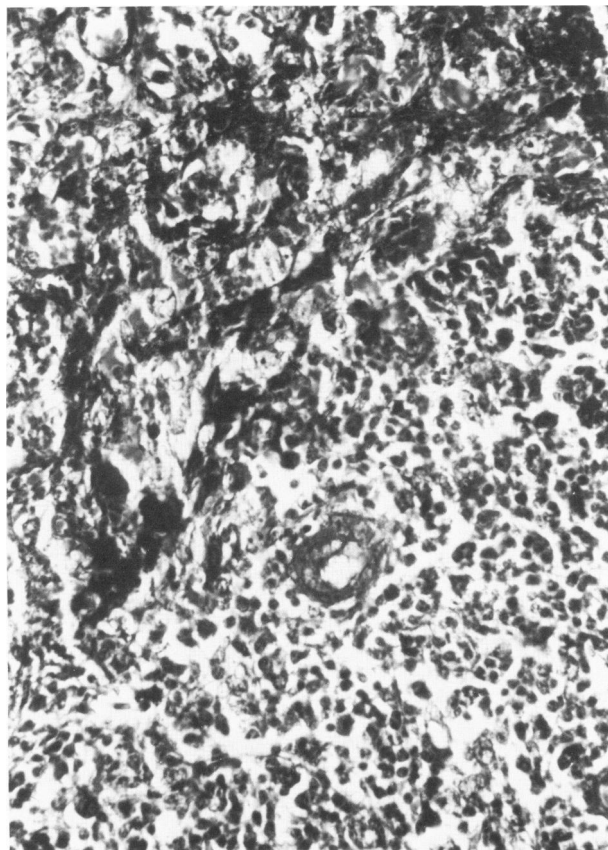


Figure 1—Fibrin and necrotic cells are present in the marginal zone of a splenic periarteriolar lymphocytic sheath in a patient with Lassa fever. (Phosphotungstic acid-hematoxylin, $\times 350$)

medulla (Figure 2). The inclusion-bearing cells appeared to be adrenocortical cells of the zona reticularis in most instances. Some inclusions, however, appeared to be in cells of the adrenal medulla. The inclusions were multiple, spherical, hyaline, and acidophilic both by hematoxylin-eosin and phloxine tartrazine stains. They varied in diameter from 3 to 15 μ . Moreover, multifocal adrenocortical cellular necrosis was present in all 3 cases (Figure 3). The necrosis bore no regular topographic relation to the inclusion-bearing cells, but rather was most prominent in the zona fasciculata. Necrosis was often associated with focal inflammatory reaction and occasionally with adjacent adrenocortical mitosis. In no instance did fewer than 90% of the cells of adrenal cortex appear viable.

Lesions in other organs were inconstant and possibly not due to Lassa infection. Careful examination of brain, pancreas, ovary, uterus, placenta, and breast demonstrated no specific pathologic alterations. Mild interstitial mononuclear myocarditis without myocardial fiber necrosis (Figure 4), alveolar edema with capillary congestion and mild interstitial

pneumonitis, lymph nodal sinus histiocytosis with mitoses, gastrointestinal mucosal petechiae, renal tubular injury, and interstitial nephritis were present in some but not all cases examined. Segments of scattered nephrons were lined by tubular cells containing numerous hyaline cytoplasmic droplets resembling resorbed protein. Some kidneys contained irregularly distributed cortical tubules lined by thin simple squamous epithelium. In one biopsy, lumina of tubules contained multinucleate cells apparently of tubular cell origin (Figure 5). In another biopsy, tubular cell necrosis occurred in a focus of lymphoreticular infiltrate that contained not only small lymphocytes, but also large mononuclear cells compatible with transformed lymphocytes (Figure 6). Intravascular fibrin thrombi were not observed. Acute nonviral complications such as nosocomial bacterial infections or pulmonary oxygen toxicity were not identified.

In five of the fetal necropsies, tissue preservation was sufficient to allow evaluation for pathologic lesions. Two fetuses were too severely autolyzed for

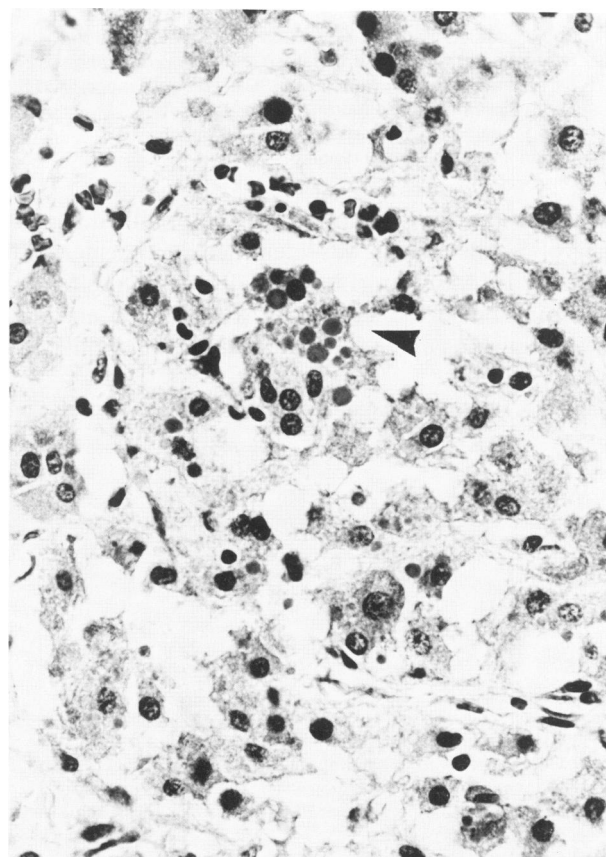
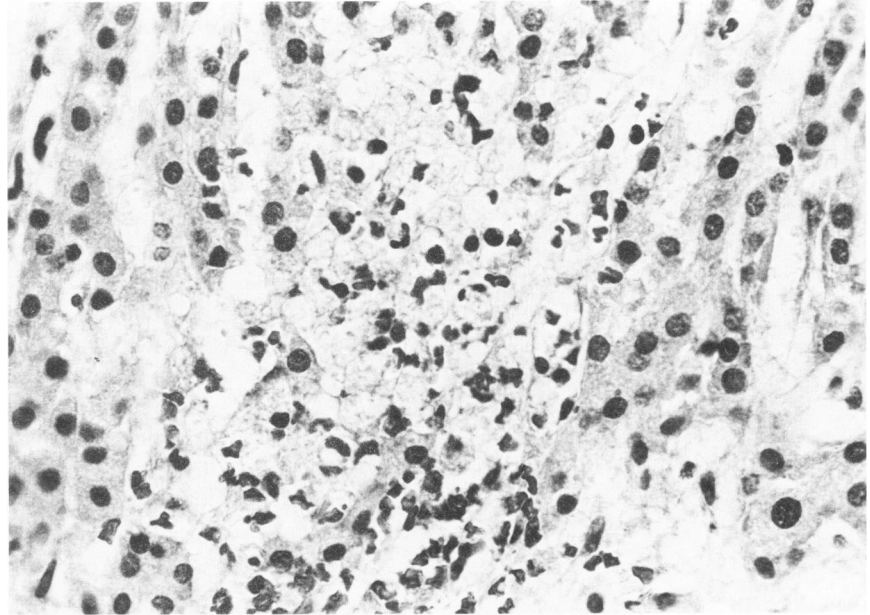


Figure 2—Cells near the junction of the adrenal cortex and medulla in a patient with Lassa fever contain numerous hyaline, eosinophilic, cytoplasmic inclusions (arrow). (Lendrum's phloxine tartrazine, $\times 440$)

Figure 3—Focal adrenocortical necrosis with moderate inflammatory cell reaction is seen in this patient with Lassa fever. (Lendrum's phloxine tartrazine. $\times 440$)



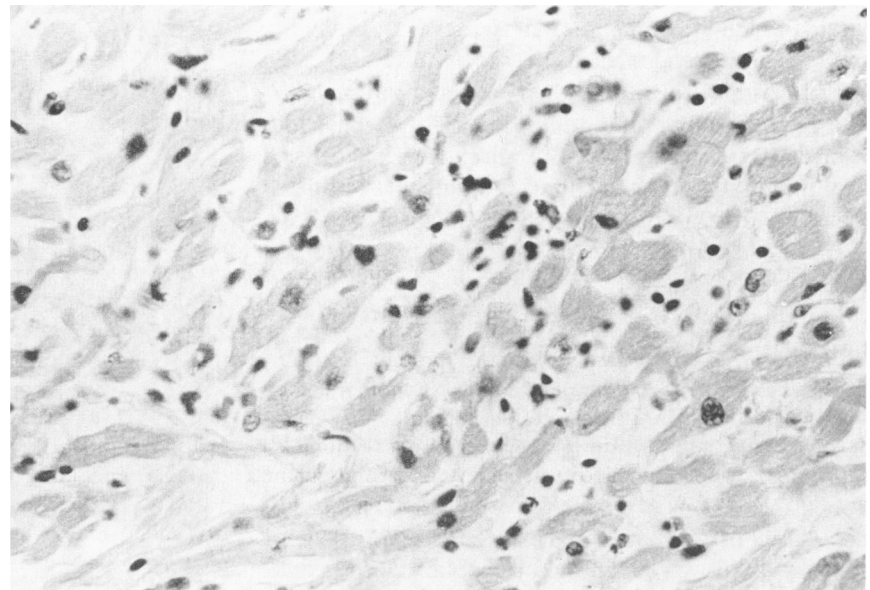
detailed microscopic study. No microscopic lesions were identified.

Discussion

Careful investigation of fatal human Lassa fever showed correlations of viral tropism, pathologic lesions, and clinical laboratory abnormalities. Organ titers indicate that in man Lassa virus is hepatotropic, lymphoreticulotropic, nephrotropic, pneumotropic, and myocardiotropic. These sites often have pathologic lesions including hepatocellular necrosis, splenic

ic necrosis, renal tubular injury, interstitial nephritis, mild interstitial pneumonia, and mild myocarditis in Lassa fever. Moreover, elevations in serum aspartate aminotransferase (AST) and serum alanine aminotransferase (ALT) indicate that hepatocellular injury may occur during the course of the illness. Increased concentration of blood urea nitrogen and proteinuria are associated with severe Lassa fever^{9,18} and may be due to renal hypoperfusion or to a direct nephropathologic effect of the virus. Evidence for unusual renal tubular lesions such as tubular syncytial cells suggests that Lassa virus may play a role in renal in-

Figure 4—Myocardium from a patient with Lassa fever shows mild interstitial myocarditis without necrosis. (H&E, $\times 350$)



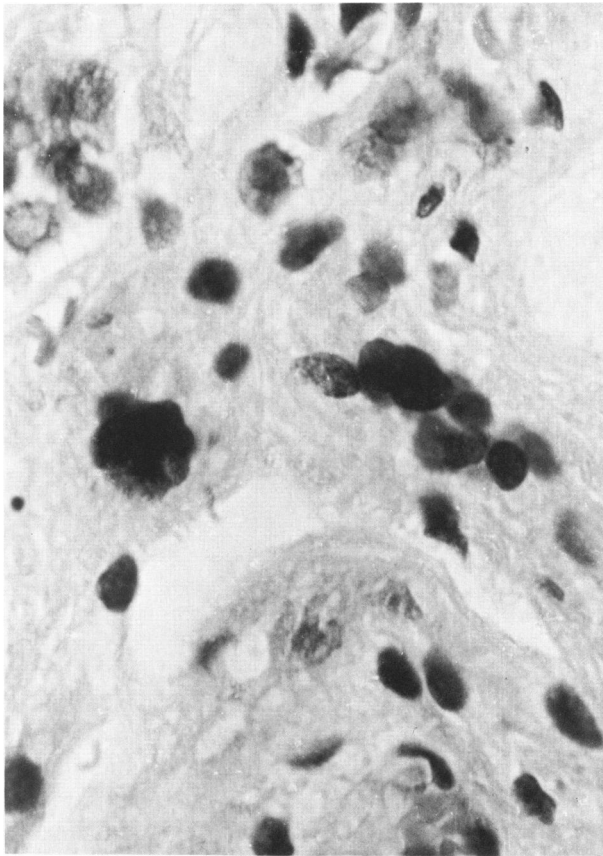


Figure 5—Two multinucleate cells in the renal parenchyma of a patient with Lassa fever appear to be in a tubular location. (H & E, $\times 880$)

jury. Moreover, necrosis of the marginal zone of the splenic periarteriolar lymphocytic sheath in human Lassa fever correlates not only with high splenic viral titers but also with the splenic distribution of arenaviral antigen in other animal species.^{19,20} Likewise, multifocal adrenocortical necrosis correlates with high adrenal viral titers in experimental animals²¹⁻²³ and moderate titers in humans and with the distribution of Lassa viral antigen in adrenocortical cells of experimentally infected rhesus monkeys.²³ No assessment of adrenal function has been reported; however, the extent of the lesions would not suggest adrenal insufficiency.

On the other hand, many organs failed to show lesions despite the presence of Lassa virus in titers higher than those in blood. No lesions were detected in the central nervous system after an exhaustive search. Minimal-to-mild lesions were noted in skeletal muscle and myocardium, even though creatine kinase (CPK) was often markedly elevated. Likewise, no lesions of the pancreas, gastrointestinal tract, or salivary gland were identified to explain observed instances of elevated serum amylase. The lungs, which

had been reported previously to show mild interstitial pneumonia, contained high titers of virus in this series.^{11,14} However, they did not contain severe pathologic lesions. The extremely high organ titers of placenta and mammary gland in this autopsy study suggest that these organs are important sites for viral replication. The resulting viral burden may account for the severity often seen in pregnant women with Lassa fever. Consideration must be given to therapeutic abortion when Lassa fever is diagnosed in the pregnant woman.

In general, the observed pathologic lesions were neither extensive enough nor present in an anatomic location to explain the mechanism of death in Lassa fever patients. The organ with the most extensive lesions, the liver, never showed more than 40% cellular necrosis, and in two cases, 1% or fewer of the cells were necrotic. All other lesions were either too sporadic in occurrence or limited in severity or extent to account for the clinical course. Although virus was isolated from two of the fetuses, no pathologic lesions were found. One could hypothesize that the fetal wastage was due to maternal vascular collapse

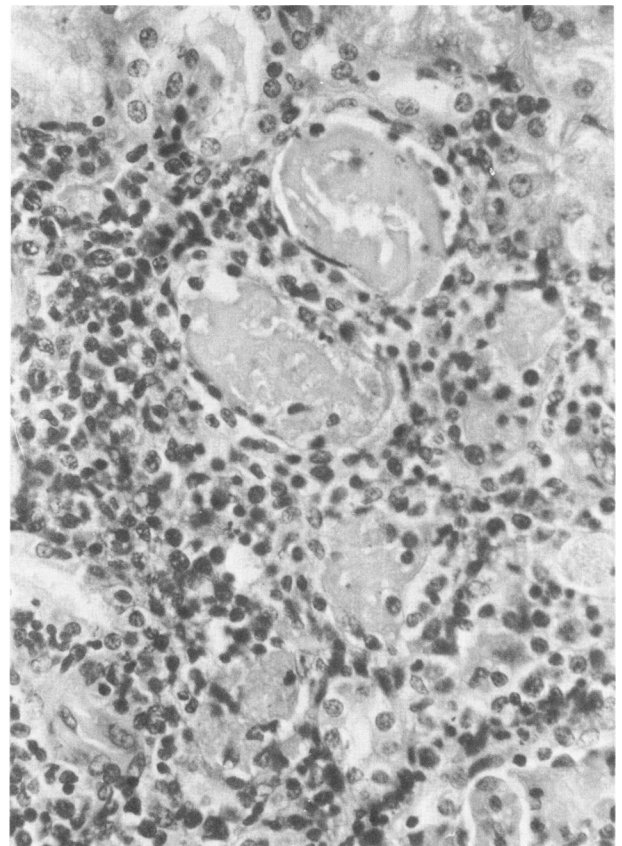


Figure 6—A cluster of necrotic tubules in the renal cortex of a patient with Lassa fever is surrounded by mononuclear inflammatory cells. (H & E, $\times 560$)

except that several were abortuses from mothers who did not show overt signs of vascular collapse. The placenta was also noted to have high viral titer indicative of viral replication; yet significant pathologic lesions were not observed. Clearly, the mechanism of death in Lassa fever is unknown.

The search for pathogenic mechanisms in Lassa fever requires evaluation of new hypotheses besides massive cellular necrosis, vascular thrombosis, hemorrhage, and leukocytic injury to tissues, lesions which are not present in sufficient quantity to account for the pathogenesis of Lassa fever. In fact, Lassa fever is pathologically not a hemorrhagic fever. Future investigations must evaluate such humoral mechanisms as inflammatory mediators (the kinin-kallikrein system, prostaglandins, and others) and acute complement activation (C3a and C5a anaphylotoxins). Activation of serum complement has been reported in infection with Junin virus, the etiologic agent of another severe arenaviral disease, Argentine hemorrhagic fever.²⁴

Comparison of human Lassa fever and experimental Lassa virus infection of nonhuman primates reveals that viral titers and/or pathologic lesions are concordant in liver, spleen, lung, kidney, adrenal, heart, and ovary. In no organ that was examined in both humans and monkeys were there more severe lesions and higher organ titers in humans. Although there are high viral titers in human placenta and mammary gland, these organs have not been examined in rhesus or squirrel monkeys. In contrast, many lesions have been observed in monkeys but not in humans. Viral infection and lesions of the CNS and systemic and pulmonary arteritis are the most important effects of Lassa virus infection in monkeys that have had no counterpart demonstrated in humans. Moreover, Lassa virus replicated to a higher titer in the pancreas, bone marrow, and lymph node than in the blood in some of the monkeys but never in humans. Data on human eyes and intestines are lacking for comparison with the uveitis and high viral titers in gastrointestinal tissues of rhesus monkeys. The broader organotropism and more severe pathologic lesions in experimentally infected monkeys serve to warn against overinterpreting studies of pathogenesis, treatment, or prevention in these animal models.

Although the hepatic lesions observed in human arenaviral diseases have been demonstrated to exhibit a considerable degree of similarity, the extrahepatic lesions have received little attention. The present study reports sufficient data to allow for comparison of the pathologic lesions of Lassa fever with those previously reported for Argentine hemorrhagic fever,²⁵ Bolivian hemorrhagic fever,²⁶ and lympho-

Table 3—A Comparison of Extrahepatic Lesions Reported in Human Arenaviral Infections

Lesion	Lassa fever*	AHF	BHF	LCM
Splenic necrosis	11/12 (8/8)	0/12	0/8	—
Renal lesions	7/13 (6/9)	6/12	2/8	—
Adrenal necrosis	3/6 (3/3)	0/12	—	—
Adrenal inclusions	3/6 (3/3)	0/12	—	—
Myocarditis	3/9 (3/5)	4/12	—	0/1
Interstitial pneumonia	4/10 (2/6)	4/12	6/6	3/3
Myositis	5/15 (5/15)	—	—	—
Encephalitis	0/4 (0/3)	5/12	6/6	2/3

* Cases with lesion/total cases with histopathology reported^{1-11,14}; proportion from this report in parentheses.

AHF, Argentine hemorrhagic fever²⁵; BHF, Bolivian hemorrhagic fever²⁶; LCM, lymphocytic choriomeningitis.^{27,28}

cytic choriomeningitis^{27,28} (Table 3). The major differences are the presence of splenic necrosis in Lassa fever but not in the South American hemorrhagic fevers and the observation of encephalitis in Bolivian hemorrhagic fever, lymphocytic choriomeningitis, and Argentine hemorrhagic fever but not in the 4 cases of Lassa fever that have been examined neuropathologically. Our observation of necrosis and cytoplasmic inclusions in the adrenal gland is unique and awaits confirmation and further study of their pathogenesis. If these lesions are shown to be caused by Lassa virus infection, they may offer a histopathologic means of distinguishing these diseases. Of more practical significance is the histopathologic evaluation of pathologic lesions in Africa leading to the differential diagnosis of Lassa fever, Marburg disease, and Ebola virus hemorrhagic fever. All three involve focal hepatic necrosis and acidophilic necrosis. Marburg disease has been reported to cause adrenal necrosis, encephalitis, and lymphoid necrosis; the histopathology of Ebola virus hemorrhagic fever has been studied inadequately. The ultimate diagnosis must be achieved by isolation and identification of the etiologic agent or by identification of the specific viral antigens in infected tissue.

References

1. Frame JD, Baldwin JM Jr, Gocke DJ, Troup JM: Lassa fever, a new virus disease of man from West Africa: I. Clinical description and pathological findings. *Am J Trop Med Hyg* 1970, 19:670-676
2. Buckley SM, Casals J: Lassa fever, a new virus disease of man from West Africa: III. Isolation and characterization of the virus. *Am J Trop Med Hyg* 1970, 19:680-691
3. Spier RW, Wood O, Liebhaver H, Buckley SM: Lassa fever, a new virus disease of man from West Africa: IV. Electron microscopy of Vero cell cultures infected with Lassa virus. *Am J Trop Med Hyg* 1970, 19:692-694
4. Wulff H, Lange JV, Webb PA: Interrelationships

- among arenaviruses measured by indirect immunofluorescence. *Intervirology* 1978, 9:344-350
5. Rowe WP, Murphy FA, Bergold GH, Casals J, Hotchin J, Johnson KM, Lehman-Grube F, Mims CA, Traub E, Webb PA: Arenoviruses: Proposed name for a newly defined virus group. *J Virol* 1970, 5:651-652
 6. Monath TP, Newhouse VF, Kemp GE, Setzer HW, Cacciapuoti A: Lassa virus isolation from *Mastomys natalensis* rodents during an epidemic in Sierra Leone. *Science* 1974, 185:263-265
 7. Murphy FA, Walker DH: Arenaviruses: Persistent infection and viral survival in reservoir hosts, *Viruses and Environment*, New York, Academic Press, 1978, pp 155-180
 8. Fraser DW, Campbell CC, Monath TP, Goff PA, Gregg MB: Lassa fever in the Eastern Province of Sierra Leone, 1970-1972: I. Epidemiologic studies. *Am J Trop Med Hyg* 1974, 23:1131-1139
 9. McCormick JB, Webb PA, King I, Johnson KM, Smith E: Lassa fever: A clinical investigation (Manuscript in preparation)
 10. McCormick JB, Webb PA, Johnson KM, Kargbo-Reffel F, Smith E: Lassa virus infection patterns in rural villages (Manuscript in preparation)
 11. Edington GM, White HA: The pathology of Lassa fever. *Trans R Soc Trop Med Hyg* 1972, 66:381-389
 12. Sarrat H, Camain R, Baum J, Robin Y: Diagnostic histopathologique des hepatites dues au virus Lassa. *Bull Soc Pathol* 1972, 5:642-650
 13. Winn WC, Monath TP, Murphy FA, Whitfield SG: Lassa virus hepatitis: Observations on a fatal case from the 1972 Sierra Leone epidemic. *Arch Pathol* 1975, 99:599-604
 14. Winn WC Jr, Walker DH: The pathology of human Lassa fever. *Bull WHO* 1975, 52:535-545
 15. McCormick JB, Johnson KM: Lassa fever: Historical review and contemporary investigation, *Ebola Virus Haemorrhagic Fever*. Edited by SR Pattyn. Amsterdam, Elsevier/North Holland Biomedical Press, 1978, pp 279-285
 16. McCormick JB, Walker DH, King IJ, Webb PA: The liver pathology of Lassa fever: A morphologic and biochemical study (Manuscript in preparation)
 17. Goldwasser RA, Elliott LH, Johnson KM: Preparation and use of erythrocyte-globulin conjugates to Lassa virus in reversed passive hemagglutination and inhibition. *J Clin Microbiol* 1980, 11:593-599
 18. Monath TP, Mertens PE, Patton R, Moser CR, Baum JJ, Pinneo L, Gary GW, Kissling RE: A hospital epidemic of Lassa fever in Zorzor, Liberia, March-April, 1972. *Am J Trop Med Hyg* 1973, 22:773-779
 19. Murphy FA, Winn WC Jr, Walker DH, Flemister MR, Whitfield SG: Early lymphoreticular viral tropism and antigen persistence: Tamiami virus infection in the cotton rat. *Lab Invest* 1976, 34:125-140
 20. Mims CA: Immunofluorescence study of the carrier state and mechanism of vertical transmission in lymphocytic choriomeningitis virus infection in mice. *J Pathol Bacteriol* 1966, 91:395-402
 21. Walker DH, Wulff H, Murphy FA: Experimental Lassa virus infection in the squirrel monkey. *Am J Pathol* 1975, 80:261-272
 22. Walker DH, Wulff H, Lange JV, Murphy FA: Comparative pathology of Lassa virus infection in monkeys, guinea pigs, and *Mastomys natalensis*. *Bull WHO* 1975, 52:523-534
 23. Jahrling PB, Hesse RA, Eddy GA, Johnson KM, Callis RT, Stephen EL: Lassa virus infection of rhesus monkeys: Pathogenesis and treatment of ribavirin. *J Infect Dis* 1980, 141:580-589
 24. Rimoldi MT, De Bracco MMDE: *In vitro* inactivation of complement by a serum factor present in Junin-virus infected guinea pigs. *Immunology* 1980, 39:159-164
 25. Elsner B, Schwarz E, Mando OG, Maiztegui J, Vilches A: Pathology of 12 fatal cases of Argentine hemorrhagic fever. *Am J Trop Med Hyg* 1973, 22:229-236
 26. Child PL, MacKenzie RB, Valverde LR, Johnson KM: Bolivian hemorrhagic fever: A pathologic description. *Arch Pathol* 1967, 83:434-445
 27. Smadel JE, Green RH, Paltauf RM, Gonzales TA: Lymphocytic choriomeningitis: Two human fatalities following an unusual febrile illness. *Proc Soc Exp Biol Med* 1942, 49:683-686
 28. Warkel RL, Rinaldi CF, Bancroft WH, Cardiff RD, Holmes GE, Wilsnack RE: Fatal acute meningoencephalitis due to lymphocytic choriomeningitis virus. *Neurology* 1973, 23:198-203

Acknowledgments

The authors wish to thank Ms. Jeanine Henderson for expert histochemical assistance and Mrs. Jennie Lu Hollander for secretarial assistance in preparation of the manuscript.