

# *Uptake of Polyvinyl Alcohol by Macrophages in the Glomerular Mesangium of Rats*

## *Histologic and Functional Studies*

R. BERND STERZEL, MD,  
GEORG M. EISENBACH, MD,  
MARCEL W. SEILER, MD  
and JOHN R. HOYER, MD

*From the Department of Medicine, Veterans Administration Medical Center, Yale University School of Medicine, West Haven, Connecticut; Department of Medicine, Medical School Hannover, Federal Republic of Germany; Department of Pathology, Veterans Administration Medical Center-Harvard Medical School, West Roxbury; and Department of Pediatrics, UCLA School of Medicine and Harbor-UCLA Medical Center, Torrance, California*

Rats received daily subcutaneous injections of the synthetic polysaccharide polyvinyl alcohol (PVA) for 1–28 days. The amount of PVA localized in the glomerular mesangium increased progressively during this time. By 28 days, all glomeruli showed extensive intracellular mesangial sequestrations of PVA, causing marked widening of mesangial areas, while the peripheral capillary loops were unaltered. Overall glomerular hypercellularity was mild to moderate, occurring mainly in areas of PVA deposition. Follow-up studies after 6, 12, 26, and 40 weeks revealed partial reduction of glomerular PVA masses. The PVA deposits were frequently associated with nonspecific esterase (NSE)-positive cells. The number of NSE-positive cells per glomerular tuft section increased from 0.1 in controls, to 2.1, 4.0, and 4.5 after 3, 14, and 28 days of PVA treatment, respectively. Similarly, glomerular counts for Ia-antigen-bearing cells rose from 2.1 in controls to

4.8 on Day 3 and showed further increases at later time periods with confluent staining of clusters of Ia-positive cells. In glomeruli, Ia-bearing cells were mainly noted in PVA-positive mesangial areas. These results indicate that PVA is taken up in the glomerulus primarily by cells that are NSE- and Ia-antigen-positive, suggesting that these cells are activated blood-borne monocyte-macrophages that sequester this polysaccharide.

Clearance studies revealed that the glomerular filtration rate and effective renal plasma flow remained normal after 4 weeks of PVA injections. PVA-treated rats showed only mild elevations of urinary protein excretion. These findings indicate that confinement of marked structural and cellular alterations to the mesangium, even including the presence of infiltrating monocyte-macrophages, is compatible with absent or minimal dysfunction of the glomerular ultrafilter. (*Am J Pathol* 1983, 111:247–257)

UPTAKE and processing of circulating macromolecules by the glomerular mesangium has been demonstrated by numerous investigators.<sup>1–3</sup> The probes have included exogenous proteins<sup>4–6</sup> as well as non-proteinaceous tracers such as colloidal carbon,<sup>7</sup> iron dextran,<sup>8</sup> and polysaccharides.<sup>9,10</sup> Recent studies have shown that the internalization of tracers may involve not only the intrinsic smooth-muscle-type mesangial cells but also bone-marrow-derived phagocytes.<sup>3,4</sup> These appear to include monocyte-macrophages acutely recruited from the circulation<sup>4</sup> and Ia-antigen-bearing cells that are resident in the mesangium.<sup>11,12</sup> Studies of experimental glomerulonephritis in rodents and rabbits have shown that infiltrating

monocyte-macrophages not only function as scavenger cells, clearing deposits and debris from the glomerulus, but may also contribute to the damage of the glomerular basement membrane (GBM) and promote a proliferative response of glomerular cells (reviewed by Cotran<sup>13</sup>). Evidence for activity of mon-

Supported by Research Funds of the Veterans Administration and the National Institutes of Health (AM 27122). Presented in part at the Fourteenth Annual Meeting of the American Society of Nephrology, Washington, D.C., 1981.

Address reprint requests to R.B. Sterzel, M.D., Department of Medicine, VA Medical Center, Yale University School of Medicine, West Haven, CT 06516.

ocyte-macrophages in the mediation of immune glomerulonephritis was obtained in models that are characterized by the localization of immune globulins to the peripheral capillary loop, initiating marked morphologic and functional perturbations of the glomerulus.<sup>14-17</sup> In human and experimental glomerular diseases with immune deposits confined to the mesangium, the glomerular lesions and functional abnormalities are usually much less severe,<sup>18-20</sup> and it has been suggested that this is related to the lack of prominent participation of monocyte-macrophages.<sup>20,21</sup>

Polyvinyl alcohols (PVA) are synthetic macromolecular polysaccharides that have been used in rats and rabbits as exogenous probes localizing in various organs, including the liver, spleen, heart, and kidneys.<sup>9,22-24</sup> PVA, with a molecular weight of approximately 72,000, localizes preferentially in the glomerular mesangium.<sup>10,25,26</sup> The gradual accumulation of PVA results in marked widening and moderate hypercellularity of the centrilobular regions of the glomerular tuft. Our recent ultrastructural analysis has demonstrated that the uptake of PVA involves predominantly cells having the ultrastructural characteristics of macrophages.<sup>27</sup> This observation led us to examine in detail the time course of the mesangial processing of PVA and the nature of the endocytic cells, employing light microscopy, immunofluorescent staining for Ia antigen, as well as histochemical demonstration of monocyte-macrophages by positive staining for nonspecific esterase (NSE). These findings were correlated with the functional status of the kidneys, as examined by clearance methods and by serial measurements of urinary protein excretion. These studies show that mesangial PVA is taken up predominantly by cells that are positive for NSE as well as for Ia antigen, suggesting that they are activated blood-borne monocyte-macrophages. The results further indicate that marked PVA accumulation and the associated prominent presence of monocyte-macrophages within the mesangium may take place without major functional abnormalities of the glomerular capillary filter.

## Materials and Methods

### Experimental Design

A total of 54 male Sprague-Dawley rats, weighing initially 100 g, received daily injections into the subcutis of the neck of 50 mg PVA (Merck-Schuchardt, Hohenbrunn, West Germany), suspended in 1 ml of 0.9% NaCl, as described previously.<sup>10</sup> We have noted that Lewis rats treated with the identical regimen show morphologically comparable findings of glo-

merular PVA deposits<sup>27</sup> as revealed by the present studies of Sprague-Dawley rats. Age-matched rats were given injected 0.9% NaCl only. The animals had free access to a standard laboratory rat food and water. PVA-treated rats and controls were sacrificed in groups of 4 to 6 animals 1, 3, 7, 14, 21, and 28 days after the beginning of the 4-week course of treatment. Selected animals were observed after completion of the course, and renal tissue was obtained for Congo red staining by open renal biopsy or at sacrifice after 6, 8, 11, 14, 26, and 40 weeks after the start of PVA injections.

### Tissue Processing

Portions of renal tissue were obtained from anesthetized rats, fixed in Bouin's solution, embedded in paraffin, sectioned at 4  $\mu$ , and stained with Congo red. The extent of Congo-red-positive deposits of PVA in glomeruli was evaluated semiquantitatively on a scale of 0 to 4+. Portions of liver, spleen, lung, and heart were secured from 2 rats after 7, 14, and 28 days of PVA treatment for Congo red staining.

Second samples of renal tissue were obtained from rats during the 4-week treatment course, fixed in buffered formalin acetone, pH 6.6, washed in Holt's sucrose gum acacia buffer for 24 hours, and then snap-frozen. Cryostat sections, 5  $\mu$  thick, were stained for NSE with  $\alpha$ -naphthol butyrate as substrate, following a modification of the method of Yam et al.,<sup>28</sup> as described previously.<sup>20</sup> Mean counts of esterase-positive cells in glomerular tufts from a minimum of 50 glomeruli per rat were determined. Sodium fluoride (1  $\mu$ g/ml) was added to the incubation medium used on parallel sections for testing for inhibition of the histochemical reaction as typically seen with monocyte-macrophages. Preliminary studies showed that extracellular PVA aggregates in subcutaneous neck tissue did not stain for NSE.

A third portion of renal tissue was snap-frozen in liquid N<sub>2</sub> and stored at -80 C before immunofluorescence studies were performed for examination of the presence of Ia-antigen-bearing cells in glomeruli. Six to eight-micron-thick frozen sections were incubated with mouse-derived monoclonal antibody directed against rat Ia antigen (Accurate Chemicals, Westbury, NY), followed by fluorescent-conjugated rabbit anti-mouse IgG (Accurate Chemicals), which was absorbed with rat IgG coupled to Sepharose 4B prior to staining. The anti-rat Ia antibody preparation (OX 6 MAS 043 c) has been studied in detail by McMaster and Williams, showing binding to rat Ia antigens which correlate with the Ia-specificity 17 or 18 in the mouse.<sup>29</sup> This antibody stains individual

cells in glomeruli as well as in the renal and hepatic interstitium, as described elsewhere.<sup>30</sup> Identical results were obtained with the use of mouse monoclonal IgG against rat Ia, analogous to the mouse Ia-specificity 9 (OX 4 MAS 029, Accurate Chemicals),<sup>31</sup> and mouse antibody against mouse Ia 1,2,3,7 (kindly provided by Dr. J.G. Ray, National Institutes of Health, Bethesda, Md) (R. B. Sterzel, M. Perfetto, unpublished observations). Incubation of sections with mouse IgG instead of anti-Ia antibody caused no fluorescence or only mild background fluorescence of renal tissue. The presence of mesangial PVA deposits in relation to Ia-positive cells was evaluated by phase-contrast microscopy. Frozen sections were also examined by indirect immunofluorescence microscopy for the presence of rat IgG and C3, as described previously.<sup>20</sup>

For transmission electron microscopy, cortical tissue was immersion-fixed in paraformaldehyde-glutaraldehyde fixative and processed as described elsewhere.<sup>31</sup>

#### Additional Studies

Blood smears of preparations of 2 PVA-treated rats and 2 control rats were obtained at the time of sacrifice and evaluated for counts of white blood cells and NSE-positive cells. At the same time, the proportion of Ia-antigen-bearing cells was determined in the mononuclear cell fraction obtained from peripheral blood by the Ficoll-Hypaque gradient density centrifugation technique.<sup>32</sup> Indirect immunofluorescence of Ia antigen of cell suspensions was performed with the use of the antibody preparations described above. In addition, counts of Ia-antigen-bearing cells harvested from the peritoneum were obtained from rats 4 days after a single intraperitoneal injection of either 1 ml of the 5% PVA solution, 3% thioglycollate, or 0.9% NaCl. One part of the harvested cells was stained in suspension. The other portion was plated in minimal essential medium and 5% fetal calf serum for glass adherence. After 3 hours of incubation at 37 C, followed by thorough washing with Hanks' balanced salt solution, the adherent cells were stained for Ia antigen. All cell culture media were obtained from Microbiological Associates, Walkersville, Maryland.

#### Functional Studies

Body weight and hematocrit were determined in all of the rats before sacrifice. Clearance experiments, including measurements of the systolic arterial blood pressure, were performed in a group of 17 PVA-

Table 1—Functional Results From Rats After 4 Weeks of PVA Administration

	PVA (n = 17)	Controls (n = 20)	P
C <sub>inulin</sub> (ml/min/100 g body weight)	0.80 ± 0.29	0.80 ± 0.25	NS
C <sub>PAH</sub> (ml/min/100 g body weight)	2.70 ± 0.92	2.60 ± 0.91	NS
FF	0.30 ± 0.09	0.31 ± 0.07	NS
EPAH (%)	78.0 ± 10.0*	73.7 ± 15.2†	NS
Kidney weight (g)	1.59 ± 0.10	1.46 ± 0.12	<0.01
Body weight (g)	246.5 ± 15.2	249.9 ± 16.1	NS
Systolic blood pressure (mm Hg)	120.2 ± 9.8	120.2 ± 12.0	NS
Hematocrit (%)	42.1 ± 1.9	49.3 ± 2.4	NS

\* n = 11.

† n = 16.

treated rats and 20 control rats upon completion of the 4-week treatment course. We used clearances of <sup>3</sup>H-methoxy inulin to determine glomerular filtration rate (GFR) and clearances of para-amino hippurate (PAH) for measuring effective renal plasma flow (RPF), employing standard clearance techniques, as described previously.<sup>33</sup> Urinary excretion of total protein was determined by the Biuret method in groups of 12 rats 1, 2, 3, 4, and 5 weeks after the start of PVA treatment and in age-matched control rats.<sup>10</sup> Urine was collected over 24 hours in metabolic cages.

#### Statistical Methods

The results are expressed as the mean ± one standard deviation (SD). Student's unpaired *t*-test was used for comparison of the results of different groups. A probability of 5% was considered the significance level.

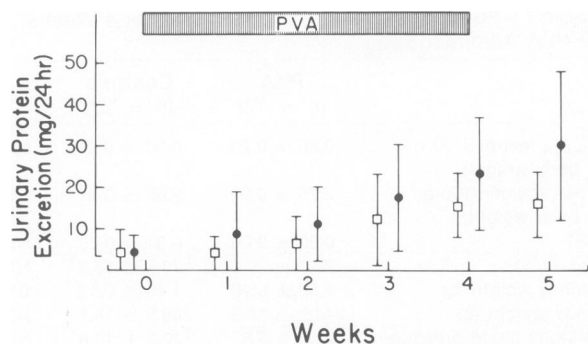
### Results

#### General Findings

All rats tolerated the PVA injections well. Throughout the 4-week study period, the means of body weights and hematocrit values of PVA-treated rats did not differ significantly from results obtained in age-matched control rats (Table 1).

#### Functional Studies

The mean total proteinuria of PVA-treated animals was slightly higher than in control animals, the differences barely reaching statistical significance after 1 and 5 weeks of treatment (Figure 1). The ranges of protein excretion were rather wide, with some animals excreting normal amounts and others excreting more than three times as much.



**Figure 1**—Time course of urinary protein excretion of rats treated with daily injections of polyvinyl alcohol (PVA) (●) and of saline-treated control animals (□). Each data point represents the mean ( $\pm 1$  SD) obtained from 6 or more animals. Significant differences ( $P < 0.05$ ) between the groups were present only after 1 and 5 weeks.

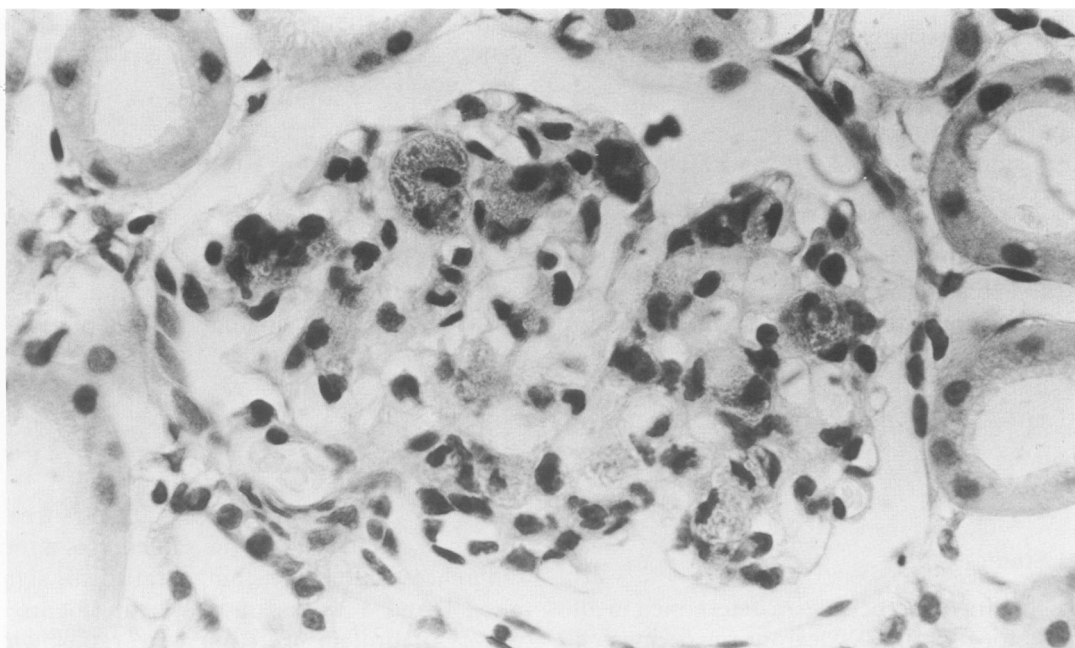
The results of the clearance experiments (Table 1) did not show any significant differences of GFR or effective RPF between PVA-treated rats and controls. The mean kidney weight of the PVA group was higher than in control animals ( $P < 0.01$ ).

#### Light-Microscopic Findings

At high magnification ( $\times 1200$ ), glomerular deposits of PVA were first noted after 3 days of treatment. In Congo-red-stained sections, small red droplets of PVA were located in mesangial areas of ap-

proximately 50% of glomeruli. By 7 and 14 days the deposition was more generalized, and essentially all of the glomeruli showed clustered droplets of PVA surrounding increased numbers of mesangial cell nuclei and widening of the mesangium in the majority of lobules (Figure 2). By 4 weeks, the size of the PVA aggregates and mesangial hypercellularity had increased further, occasionally forming large mesangial masses of Congo-red material, which often enclosed several cells. In some glomeruli the mesangial widening was very marked, resulting in gross distortion of the tuft architecture and compression of capillary lumens. Remarkably, the changes always appeared to be limited to the axial portions of the glomerular lobules, leaving the peripheral capillary loops largely intact. The amount and distribution of PVA in glomeruli had not changed appreciably by 2 and 7 weeks after completion of the 4-week course of treatment (Figure 3). In the rats examined after 26 and 40 weeks it was noted that the glomerular PVA deposits were somewhat less extensive. At the same time, sclerotic changes were observed in some glomeruli with large accumulations of PVA.

Interstitial deposits of Congo-red-positive PVA were not seen before the fourth week, when small amounts were occasionally noted between cortical tubules, sometimes in proximity to glomeruli. However, major accumulation of PVA was not observed at the vascular pole of glomeruli at any time (Figure



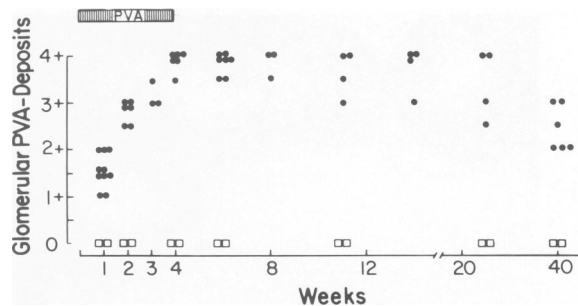
**Figure 2**—Congo-red-stained glomerulus from a rat after 2 weeks of PVA administration showing widespread centrilobular PVA deposits (scored 3+) associated with mesangial widening and segmental hypercellularity. No PVA is noticeable at the glomerular hilum (lower left corner). ( $\times 700$ )

2). The macula densa area of the distal tubule remained Congo-red-negative throughout the experiment. PVA was not seen within tubules.

Congo-red staining of extrarenal tissues after 1–4 weeks of PVA treatment revealed mild to moderate PVA uptake in phagocytic cells of liver, spleen, and lungs; whereas there were no or few Congo-red-positive cells in the heart muscle. At no time were the PVA deposits in these organs nearly as conspicuous as in the glomeruli.

**Nonspecific Esterase Staining**

In all rats, proximal tubular cells and interstitial histiocytes stained strongly dark red. Glomeruli of control rats showed very rare cells that stained for NSE ( $0.1 \pm 0.1$  cells per glomerular tuft section). The mean glomerular counts of PVA-treated rats are listed in Table 2. The number of esterase-positive cells progressively increased with duration of PVA administration (Figures 4). The observed esterase activity was strongly inhibited by addition of sodium fluoride to the incubation medium. Not all the cells in the mesangium which appeared to contain PVA droplets demonstrated intensive esterase staining. For example, after 7 days of PVA treatment, when PVA droplets were found in the mesangium of most lobules, the range of clearly esterase-positive cells was 1–6 per glomerulus, indicating that cells associated with PVA deposits were more abundant than strongly esterase-positive cells. However, in addition to the NSE-positive cells included in the counts recorded in Table 2, larger accumulations of PVA associated with clusters of nuclei frequently showed a definite reddish tinge, a finding not seen in normal controls. This pattern was also inhibitable by sodium fluoride.



**Figure 3**—Time course of semiquantitative grading of glomerular Congo-red-positive PVA deposits in rats during and after the 4-week course of PVA administration (●) and in saline-treated controls (□). Each symbol represents the average scoring for one animal.

**Glomerular Immunofluorescence**

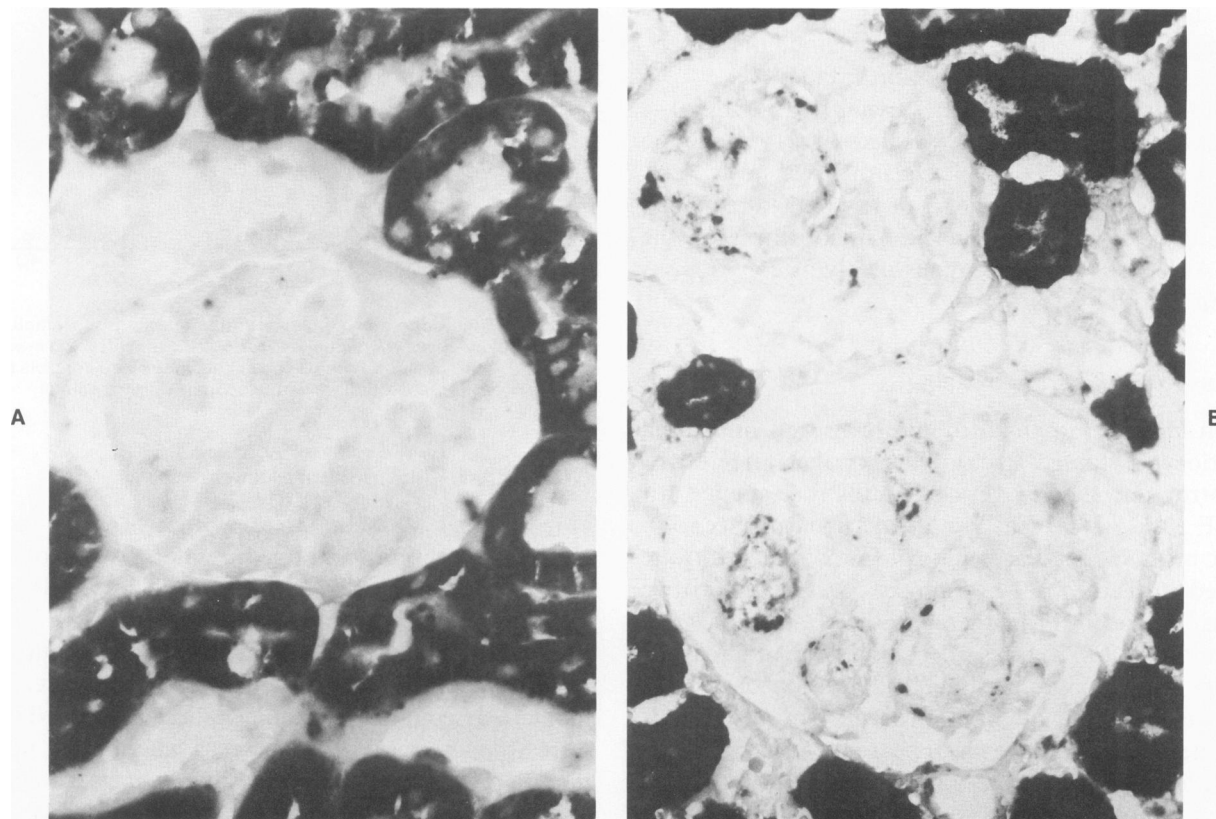
In kidneys of saline-treated control rats, most glomerular sections contained a small number of Ia-positive cells (Figure 5A; Table 2). These cells appeared to be located in centrilobular and stalk areas of the tuft, as judged by simultaneous phase-contrast microscopy. PVA-treated rats showed increased glomerular counts of Ia-antigen-bearing cells. They were frequently localized in areas where PVA nodules were clearly observed by phase-contrast microscopy (Figures 5B and C). From Day 7 to Day 28, clusters of Ia-positive, PVA-containing cells were noted in lobules of most glomeruli; creating a confluent network of fluorescence staining for Ia antigen. In a proportion of PVA-containing cell clusters Ia-staining was faint or not appreciable. Sections from rats treated with PVA for 1–4 weeks showed also occasional clusters of round Ia-positive cells in the cortical interstitium, usually in a periglomerular or perivascular location. Phase-contrast microscopy, however, did not reveal evidence of PVA granules in these areas.

**Table 2**—Counts of Glomerular Cells That Stain for Nonspecific Esterase and for Ia-Antigen\*

	Control	Days of PVA treatment					
		1	3	7	14	21	28
<i>Esterase-positive cells</i>							
Mean	0.1	1.1	3.2	3.2	4.0	4.2	4.5
Range	0–1	0–4	0–5	1–6	1–8	1–10	2–12
n	12	4	4	6	4	4	6
<i>Ia-positive cells</i>							
Mean	1.8	2.2	4.8	>5†	>5†	NT	>5†
Range	0–5	0–6	2–8				
n	6	4	3	6	3		6

\* Values represent counts of positive cells per glomerular section. Data were obtained from 30–50 glomerular cross-sections of all sizes; “n” denotes number of studied animals. NT, not tested.

† No precise cell count given because of confluent staining for Ia of cell clusters in glomeruli. The number and extent of clusters increased with time.



**Figure 4** — Renal tissues stained for nonspecific esterase. **A** — Glomerulus from saline-treated control rat without esterase-positive cells. **B** — Glomeruli from rat after 3 weeks of PVA administration showing multiple esterase-positive cells associated with areas of PVA deposition. ( $\times 500$ )

Immunofluorescence for rat IgG and C3 was not demonstrated in glomeruli of PVA-treated rats or of control animals during the 4-week study period.

### Electron Microscopy

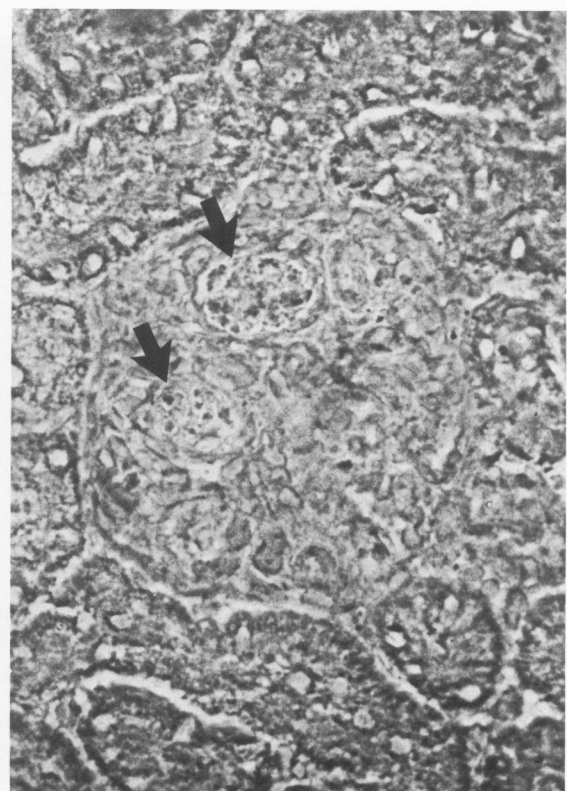
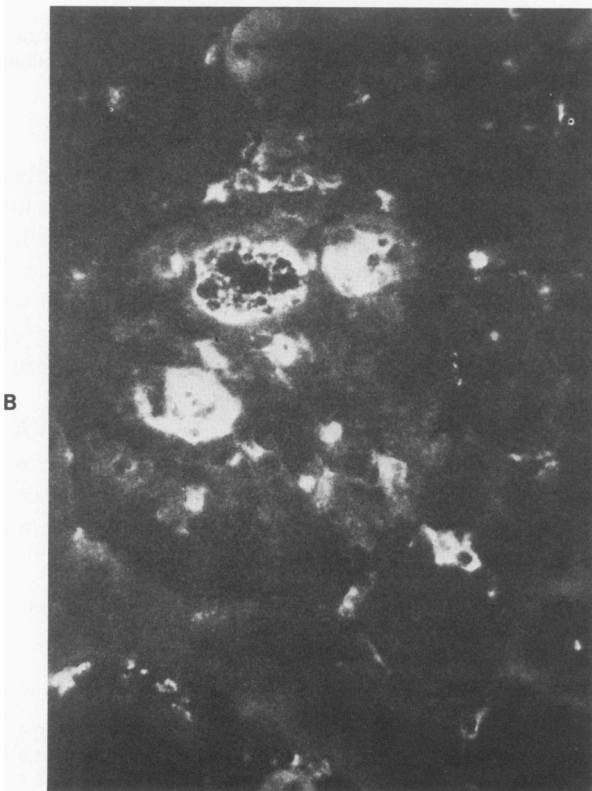
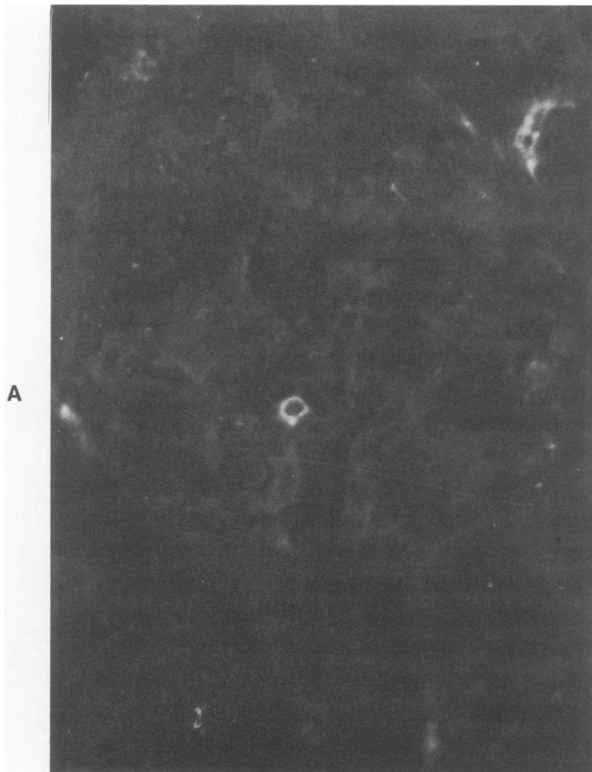
By electron microscopy, PVA was first detected focally in the mesangial matrix as early as 24 hours following a single subcutaneous injection. Later, increasing quantities of PVA were found within phagolysosomes of cells with morphologic attributes of macrophages which could be differentiated from intrinsic stellate mesangial cells and endothelial cells. Only small amounts of PVA were present within the latter two cell types. By 2 weeks, the mesangial macrophages underwent epithelioid cellular differentiation, and their accumulation in mesangial spaces resulted in the formation of microgranulomas. While the mesangial expansion caused considerable distortion of the normal glomerular architecture, the glomerular capillary walls showed no appreciable changes of the epithelial foot processes or alterations within the glomerular basement membrane (Figure

6). A detailed ultrastructural description of the PVA-induced glomerular lesions is given elsewhere.<sup>31</sup>

### Additional Results

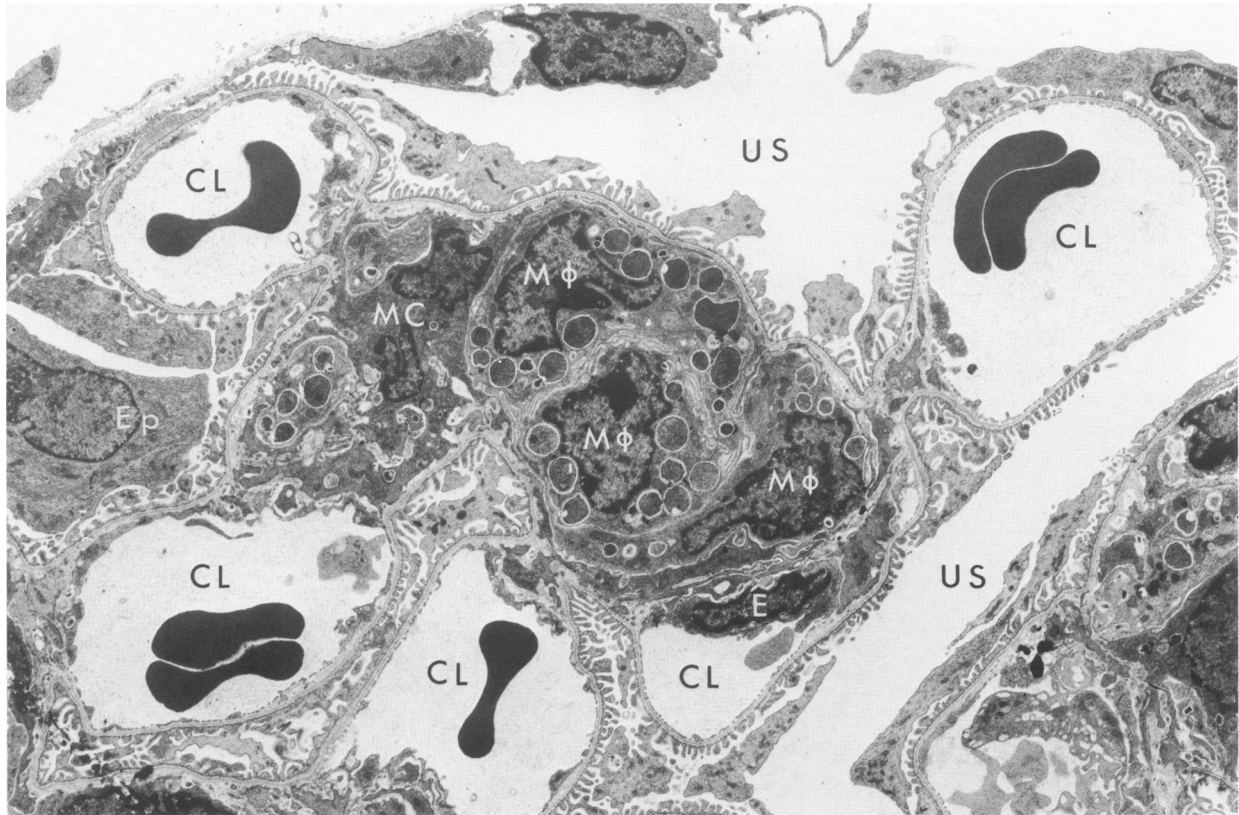
During the 4-week course of treatment, the total and differential white blood cell counts of PVA-treated rats did not show significant differences from control animals. The proportions of monocytic cells of PVA rats and controls were also similar in blood smears and in the mononuclear cell layer from the Ficoll-Hypaque density gradient. The fraction of all Ia-antigen-positive cells in the mononuclear cell layer were  $13.3 \pm 1.8\%$  in control animals. Beginning at Day 7, the values for PVA rats were clearly higher, ranging between 16% and 27%.

The proportions of Ia-positive peritoneal mononuclear cells 4 days after a single intraperitoneal injection of PVA are listed in Table 3. PVA administration caused a pronounced increase of Ia-antigen-bearing peritoneal macrophages over treatment with thioglycollate or saline. This rise was particularly marked in glass-adherent cells.



**Figure 5**—Immunofluorescence micrographs of frozen kidney sections stained for Ia antigen. **A**—Staining of Ia-positive cell in glomerulus from control rat. ( $\times 500$ ) **B**—Glomerulus from a rat treated for 2 weeks with PVA containing several individual Ia-positive cells as well as clusters of cells staining for Ia. ( $\times 450$ ) **C**—Phase-contrast micrograph of identical glomerulus demonstrating coarse PVA nodules (*arrows*) in areas of Ia-positivity shown in **B**.





**Figure 6**—Low-power electron micrograph of rat glomerulus obtained 3 weeks after initial PVA injection. Large amounts of PVA are present within phagolysosomes of mesangial macrophages ( $M\phi$ ) in the expanded mesangial region. Occasional small vacuoles containing PVA are also present in stellate mesangial cells ( $Mc$ ). Peripheral capillary walls display normal morphologic features. *E*, endothelial cell; *Ep*, epithelial cell; *CL*, capillary, lumen; *US*, urinary space. ( $\times 3600$ )

### Discussion

The present results confirm previous findings showing that repeated subcutaneous administrations of PVA lead to accumulation of this polysaccharide in the glomerular mesangium.<sup>10,25,26</sup> There was relatively inconspicuous PVA deposition in the mononuclear phagocytic system of liver, spleen, and lungs. This is in contrast to the observations of other workers who have studied the organ uptake of PVA types of different sizes and physicochemical properties.<sup>9,22-24</sup> While it is likely that such characteristics are important for the distribution of PVA deposits, the precise reasons for the predominant glomerular localization of the PVA type employed in the present study have not been established.

In comparison with the prompt deposition and internalization of PVA in the mesangium, the removal of this material from glomeruli appears to be a very slow process requiring months for an appreciable reduction of the Congo-red deposits. Although the kinetics of the mesangial turnover of PVA cannot be assessed on the basis of the present findings, it is ap-

parent that PVA is sequestered in large phagolysosomes of cells in the mesangium and that there is little loss by exocytosis or leakage from these cells. Ultrastructural analysis has shown that the persistence of PVA within mesangial phagocytes is associated with the formation of small granulomas containing epithelioid cells and multinucleated cells in glomerular tufts.<sup>31</sup>

Since the amounts of Congo-red-positive PVA in the cortical interstitium appeared to increase with time, it is possible that small amounts of the mesangial PVA, not appreciable by light microscopy, were

**Table 3**—Proportions of Ia-Antigen-bearing Peritoneal Mononuclear Cells\*

	Before glass adherence	After glass adherence
0.9% NaCl (3)	4.5 $\pm$ 3.5	1.5 $\pm$ 0.9
3% Thioglycollate (3)	10.4 $\pm$ 2.6	2.8 $\pm$ 1.0
5% PVA (4)	22.6 $\pm$ 4.6	18.4 $\pm$ 8.4

\* The peritoneal cells were harvested 4 days after intraperitoneal administration of the agents. Numbers of studied rats are given in parentheses.



removed from glomeruli via the stalk and vascular pole into the adjacent interstitial spaces, as has been suggested to occur with other tracers such as iron dextran<sup>8</sup> or colloidal carbon.<sup>7</sup> Further morphometric investigations are required for analysis of the glomerular versus the vascular and tubular contributions to the formation of interstitial PVA deposits.

A prominent finding of this study is the association of mesangial PVA deposits with cells staining positively for NSE and for Ia antigen. Glomeruli of age-matched saline-treated control rats contain but a very small number of cells with these features. NSE-positive cells represent, most likely, blood-derived monocyte-macrophages which have reached the glomerular tufts.<sup>17-20</sup> A comparatively larger number of Ia-antigen-bearing, NSE-negative cells, which are resident within the mesangial space, has been identified in rat glomeruli.<sup>11,12,30,34</sup> These specialized cells are bone-marrow-derived and capable of presenting antigens to lymphocytes.<sup>11,12</sup> With regard to their endocytic properties, they appear to be heterogeneous, in that only a proportion of the mesangial Ia-positive cells has been shown to be phagocytic *in vivo*<sup>11,30,34</sup> and *in vitro*.<sup>11,12</sup> The finding that most of these cells do not stain for NSE (Table 2) distinguishes them from circulating monocytes and peritoneal macrophages. It is uncertain at present whether these cells are akin to Ia-positive, NSE-negative, and not uniformly phagocytic dendritic cells of the spleen and other tissues.<sup>34-36</sup>

In the normal rat only a small proportion of monocyte-macrophages show Ia-antigen positivity,<sup>37,38</sup> a finding confirmed in this study. The expression of Ia antigen on monocyte-macrophages can be greatly enhanced by various stimuli, including phagocytosis.<sup>37,38</sup> The present results indicate that systemic as well as intraperitoneal administration of PVA increases the fraction of Ia-positive monocyte-macrophages. A similar process of Ia-antigen expression appears to take place in the mesangium when NSE-positive, blood-derived monocyte-macrophages internalize PVA.

While it is possible that resident Ia-positive, NSE-negative mesangial cells may also have participated in the uptake of PVA, several points argue against a major contribution of these cells. Although simultaneous identification of Ia and NSE-positive cells associated with glomerular PVA deposits has not yet been accomplished, the counts of cells characterized by either feature increased roughly in parallel, suggesting, but not proving, that many cells stained for both and represented activated macrophages. In addition, the areas of largest PVA accumulation frequently involved groups of Ia-positive cells. This cell increase would imply either multiplication of resident

Ia-positive cells or recruitment of new cells. Proliferation of analogous, Ia-antigen-bearing cells in other peripheral tissues has not been described, to our knowledge, and it has been considered that such cells may be end-forms derived from proliferating bone-marrow precursors.<sup>39</sup> Finally, the very striking cellular uptake of PVA does not appear to be consistent with the nonuniform phagocytic activity of Ia-positive resident mesangial cells found for other tracers, such as ferritin,<sup>30</sup> carbon particles,<sup>34</sup> heterologous IgG, and latex beads.<sup>11</sup> At present, it is not possible to distinguish unequivocally infiltrating activated monocyte-macrophages from Ia-positive resident mesangial cells in tissue sections. Further studies are needed for analysis of morphologic and functional features as well as the mechanisms of recruitment and the turnover of both cell types in the mesangium. The model of glomerular PVA accumulation and the use of PVA in the examination of the responses of these cells *in vitro* appear well suited for such experiments.

The present observations demonstrate that the PVA-induced histologic lesion of the glomerulus is limited to the mesangial structures. Despite the very pronounced mesangial widening and the segmental hypercellularity, the glomerular capillary loops remained unaffected, showing intact glomerular basement membranes and maintained epithelial cell foot processes. The morphologic integrity of the capillary wall, which constitutes the glomerular ultrafiltration barrier, is in keeping with the finding that after 4 weeks of PVA treatment, functional parameters of the glomeruli such as renal plasma flow, glomerular filtration rate, and filtration fraction remained normal, and the urinary protein excretion was only mildly elevated. These findings are particularly remarkable in view of the striking increase of phagocytes in the glomeruli. The confinement of the lesions and of the localization of activated monocyte-macrophages to the mesangial space evidently is not associated with major functional perturbations of the glomeruli. This is in contrast to severe functional abnormalities caused by monocyte-macrophages that infiltrate the glomeruli when immune deposits are localized in the peripheral capillary loops, as seen in experimental models of anti-glomerular basement membrane nephritis and in certain types of immune-complex-mediated glomerular disease.<sup>13-16</sup> It is presently unknown whether the extent of the glomerular injury in these different situations is primarily related to the location of the infiltrating monocyte-macrophages or to the degree of the effector activity of these cells mediating more or less damage of the glomerular structures.

The present work points out that mesangial deposit disease, even with prominent participation of infiltrating monocyte-macrophages, is tolerated by the glomerulus without prompt and conspicuous loss of filtration function. It remains to be seen, however, whether alterations of the mesangium for more protracted periods of time may lead to a chronic impairment of mesangial function. Since these are thought to include the unclogging and reconditioning of the glomerular ultrafilter,<sup>2,3,21</sup> chronic mesangial accumulation of PVA may ultimately interfere with the normal maintenance of other glomerular structures and functions. Studies in this regard are currently in progress.

### References

- Latta H, Maunsbach AB, Madden SC: The centrolobular region of the renal glomerulus studied by electron microscopy. *J Ultrastruct Res* 1960, 4:455-472
- Farquhar MG, Palade GE. Functional evidence for the existence of a third cell type in the renal glomerulus. *J Cell Biol* 1962, 13:55-87
- Michael AF, Keane WF, Raij L, Vernier RL, Mauer SM: The glomerular mesangium. *Kidney Int* 1980, 17:141-154
- Striker GE, Mannik M, Tung MY: Role of marrow-derived monocytes and mesangial cells in removal of immune complexes from renal glomeruli. *J Exp Med* 1979, 149:127
- Lee S, Vernier RL: Immunoelectron microscopy of the glomerular mesangial uptake and transport of aggregated human albumin in the mouse. *Lab Invest* 1980, 42:44-58
- Mancilla-Jimenez R, Bellon B, Kuhn J, Belair MF, Rouchon M, Druet P, Bariety J: Phagocytosis of heat-aggregated immunoglobulins by mesangial cells: An immunoperoxidase and acid phosphatase study. *Lab Invest* 1982, 46:243-253
- Elema JD, Hoyer J, Vernier RL: The glomerular mesangium: Uptake and transport of intravenously injected colloidal carbon in the rat. *Kidney Int* 1976, 9:395-406
- Leiper JM, Thomson D, MacDonald MK: Uptake and transport of Imposil by the glomerular mesangium in the mouse. *Lab Invest* 1977, 37:526-533
- Pardo V, Shapiro AP: Ultrastructural glomerular lesions produced by synthetic polysaccharides. *Lab Invest* 1966, 15:617-628
- Sterzel RB, Krause PH, Kregeler M: Experimental changes in the mesangial capacity to handle glomerular immune deposits in rats. *Contrib Nephrol* 1976, 2:66-75
- Schreiner GF, Kiely J-M, Cotran RS, Unanue ER: Characterization of resident glomerular cells in the rat expressing Ia-determinants and manifesting genetically restricted interactions with lymphocytes. *J Clin Invest* 1981, 68:920-931
- Schreiner GF, Cotran RS, Unanue ER: The localization and origin of the Ia-bearing cells of the rat glomerulus (Abstr). *Kidney Int* 1982, 21:205
- Cotran RS: Monocytes, proliferation and glomerulonephritis (Editorial). *J Lab Clin Med* 1978, 92:837-840
- Shigematsu H, Shishido H, Sano M, Kobayashi Y, Kondo Y, Okabayashi A: Participation of monocytes in transient glomerular hypercellularity in acute glomerulonephritis of experimental animals and man. *Contrib Nephrol* 1976, 2:41-47
- Schreiner GF, Cotran RS, Pardo V, Unanue ER: A mononuclear cell component in experimental immunological glomerulonephritis. *J Exp Med* 1978, 147:369-384
- Holdsworth SR, Neale TJ, Wilson CB: Abrogation of macrophage-dependent injury in experimental glomerulonephritis in the rabbit. Use of antimacrophage serum. *J Clin Invest* 1981, 68:686
- Sterzel RB, Pabst R: The temporal relationship between glomerular cell proliferation and monocyte infiltration in experimental glomerulonephritis. *Virchows Arch [Cell Pathol]* 1982, 38:337-350
- Magil AB, Wadsworth MB, Loewen M: Monocytes and human renal glomerular disease. *Lab Invest* 1981, 44:27-33
- Monga G, Mazzucco G, di Belgiojoso GB, Busnach G: Monocyte infiltration and glomerular hypercellularity in human acute and persistent glomerulonephritis. *Lab Invest* 1981, 44:381-387
- Sterzel RB, Ehrich JHH, Lucia H, Thomson D, Kashgarian M: Mesangial disposal of glomerular immune deposits in acute malarial glomerulonephritis. *Lab Invest* 1982, 46:209-214
- Burkholder PM: Functions and pathophysiology of the glomerular mesangium (Editorial). *Lab Invest* 1982, 46:239-241
- Hueper WC: Organic lesions produced by polyvinyl alcohol in rats and rabbits. *Arch Pathol* 1939, 28:510-531
- Hall CE, Hall O: Polyvinyl alcohol: relationship of physicochemical properties to hypertension and other pathophysiological sequelae. *Lab Invest* 1963, 12:721-736
- Hall CE, Hall O: Macromolecular hypertension and associated pathologic changes resulting from treatment with polyvinyl alcohol. *Am J Pathol* 1962, 41:247-253
- Kuhn K, Sterzel RB, Stolte H, Reale E: Mesangial cells in different vertebrate kidneys: a thin section and freeze fracture study. *Contrib Nephrol* 1976, 2:9-16
- Mauer SM, Numata M, Sutherland DER: The effects of polyvinyl alcohol on the uptake and processing of colloidal carbon by the glomerular mesangium in rats. *Lab Invest* 1979, 41:475-482
- Seiler MW, Sterzel RB, Hoyer JR: Ultrastructure of mesangial cellular changes induced by polyvinyl alcohol (Abstr). *Kidney Int* 1982, 21:205
- Yam LT, Li CY, Crosby WH: Cytochemical identification of monocytes and granulocytes. *Am J Clin Pathol* 1971, 55:283-290
- McMaster WR, Williams AF: Identification of Ia-glycoproteins in rat thymus and purification from rat spleen. *Europ J Immunol* 1979, 9:426-433
- Sterzel RB, Perfetto M, Biemesderfer D, Kashgarian M: Disposal of ferritin in the glomerular mesangium of rats. *Kidney Int* (In press)
- Seiler MW, Hoyer JR, Sterzel RB: Role of macrophages in the glomerular mesangial uptake of polyvinyl alcohol in rats. *Lab Invest* (In press)
- Oppenheim JJ, Scheckter B: Lymphocyte transformation. *Manual of Clinical Immunology*. Edited by NR Rose, H Friedman. American Society for Microbiology, Washington, D.C., 1976, 81-94
- Eisenbach GM, Van Liew JB, Boylan JW, Manz N, Muir P: Effect of angiotensin on the filtration of protein in the rat kidney: A micropuncture study. *Kidney Int* 1975, 8:80-87

34. Hart NJ, Fabre JW: Demonstration and characterization of Ia-positive dendritic cells in the interstitial connective tissue of rat heart and other tissues, but not brain. *J Exp Med* 1981, 154:347-361
35. Steinman RM, Kaplan G, Witmer MD, Cohn ZA: Identification of a novel cell type in peripheral lymphoid organs in mice: V. Purification of splenic dendritic cells, new surface markers and maintenance in vitro. *J Exp Med* 1979, 149:1-16
36. Klinckert WEF, LaBadie JH, Bowers WE: Accessory and stimulating properties of dendritic cells and macrophages isolated from various rat tissues. *J Exp Med* 1982, 156:1-19
37. Humphrey JH, Grennan D: Different macrophage populations distinguished by means of fluorescent polysaccharides: Recognition and properties of marginal-zone macrophages. *Eur J Immunol* 1981, 11:221-228
38. Calamai BG, Beller DL, Unanue FR: Regulation of macrophage populations: IV. Modulation of Ia expression in bone-marrow derived macrophages. *J Immunol* 1982, 128:1692-1694
39. Van Voorhis WC, Hair LS, Steinman RM, Kaplan G: Human dendritic cells: Enrichment and characterization from peripheral blood. *J Exp Med* 1982, 155:1172-1187

### Acknowledgments

The authors gratefully acknowledge the contribution of Mr. Juergen Linnenkamp to the initial functional studies, the excellent technical assistance of Mrs. Mary Perfetto, the patient secretarial help of Mrs. Mary Murray and Mrs. Deborah Beauvais, and the helpful comments on the manuscript by Dr. Michael Kashgarian.