

The Rapid Induction of Liver Cell Death in Rats Fed a Choline-Deficient Methionine-Low Diet

AMIYA K. GHOSHAL, PhD
MIRIAM AHLUWALIA, BSc, and
EMMANUEL FARBER, MD, PhD

From the Departments of Pathology and Biochemistry, University of Toronto, Toronto, Ontario, Canada

This study was undertaken to test the hypothesis that the basis for the cell proliferation seen in the livers of rats fed a choline-deficient methionine-low (CMD) diet is regeneration following hepatocyte cell death and necrosis. Exposure of rats to a CMD diet for 2 weeks was found to induce liver cell loss and necrosis as monitored by three different approaches: 1) histologic exami-

nation, 2) serum sorbitol dehydrogenase assay, and 3) measurement of the total radioactivity in liver DNA prelabeled during a prior period of regeneration. These observations suggest that the basis for liver cell proliferation in rats fed a CMD diet probably resides in the cell loss and necrosis induced in the liver by the deficient diet. (*Am J Pathol* 1983; 113:309-314)

IT HAS BEEN KNOWN for a long time that feeding rats a diet deficient in choline and low in methionine rapidly induces a fatty liver that is often associated with the ultimate development of cirrhosis. Extensive histologic studies of this model revealed death of hepatocytes in close association with extensive lipid accumulation and the development of fatty cysts.¹ However, no quantitative studies of the extent of any liver cell loss were published.

More recent studies since 1969 have shown that rats fed a diet deficient in choline and methionine (CMD) for as short a period as 1-2 weeks, show persistent liver cell proliferation.²⁻⁴ The liver cell proliferation was not correlated with fatty cysts by these authors and no mechanism was demonstrated.

The feeding of a CMD diet to rats has been shown to have a profound effect in promoting and accelerating liver cancer development in association with the administration of ethionine, diethylnitrosamine, and 2-acetylaminofluorene or azaserine,⁵⁻¹⁰ as well as with aflatoxin B₁.¹¹ In addition, the feeding of a CMD diet

for 1 or 2 weeks has been found to substitute for partial hepatectomy (PH) in the initiation of liver carcinogenesis.^{12,33} Thus, the hepatic mitogenic effects of feeding a CMD diet to rats may well play an important role in several steps in the carcinogenic process in the liver.

However, the basis for the increased cell proliferation is not known. Hepatocytes can be stimulated to proliferate in at least two ways: 1) by several compounds that have a "primary mitogenic" effect without evident preceding cell death¹³⁻¹⁵ or 2) as a response to liver cell death.^{16,17}

Supported by research grants from the National Cancer Institute of Canada, the Medical Research Council of Canada (MT-5994), and Health and Welfare, Canada (NHRDP).

Accepted for publication June 20, 1983.

Address reprint requests to Dr. A. K. Ghoshal, Department of Pathology, University of Toronto, Medical Sciences Building, Toronto, Ontario, Canada M5S 1A8.

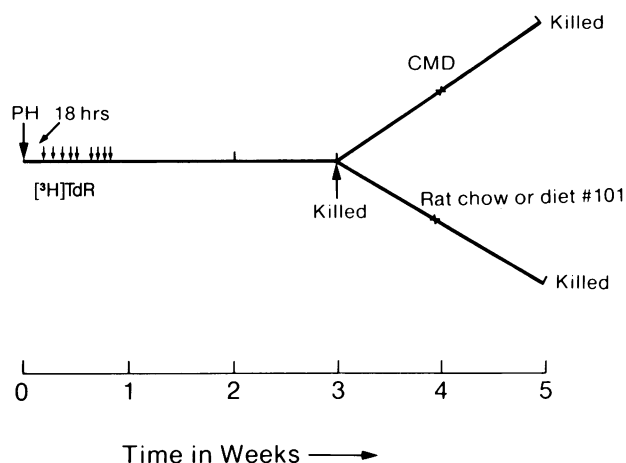


Figure 1—Diagrammatic representation of the design of the experimental protocols (See the text for details).

Because cell proliferation is a key step in initiation of liver cell cancer development with chemicals,¹⁸⁻²⁰ and because liver cell death can provide the basis for such cell proliferation,²¹ it was considered important to determine the degree of cell death by the feeding of a CMD diet for 2 weeks. Using three approaches, histologic observation, serum enzyme determination (sorbitol dehydrogenase, one of the most sensitive indicators for liver cell necrosis in the rat²²) and preservation of prelabeled DNA in the whole liver, it is concluded that feeding a CMD diet to Fischer 344

Table 1—Choline-Methionine-Deficient Diet

Ingredient	gm/kg
Alcohol-extracted peanut meal	120.0
Soy protein isolate	80.0
Fiber	10.0
Corn starch	100.0
Dextrin	100.0
Sucrose	383.0
Casein, vitamin free	10.0
L-Cystine	2.0
AIN-76 salt mix	35.0
AIN-76 vitamin mix	10.0
Corn oil	50.0
Primex (hydrogenated vegetable oil)	100.0
	1000.0

Total choline and methionine content of this diet: choline chloride, 50 mg/kg food; methionine, 300 mg/kg food.

rats rapidly induces liver cell death and that this is likely to be at least one underlying mechanism for the increased hepatocyte proliferation seen with this dietary deficiency.

Materials and Methods

Animals

Male Fischer 344 rats (Charles River Breeding Laboratories, Detroit, Mich), 4-5 weeks of age and

Table 2—Induction of Liver Cell Death by Feeding CMD Diet

Treatment	Terminal body weight (g)	Liver weight (g)	DNA		Total protein mg/total liver	Sorbitol dehydrogenase U/l serum
			dpm/total liver $\times 10^3$	mg/total liver		
Experiment 1						
Zero time (Group 1)	185 \pm 18*	6.19 \pm 0.9	12,282 \pm 1894	10.28 \pm 1.32	828 \pm 193	ND
<i>P</i> value (between 2 and 1†)		NS	NS	<0.05	NS	
After 2 weeks control‡ diet (Group 2)	202 \pm 1.7	6.63 \pm 0.2	12,417 \pm 2927	14.55 \pm 1.62	805 \pm 63	ND
<i>P</i> value (between 3 and 2)		<0.001	<0.05	NS	<0.025	
After 2 weeks CMD diet (Group 3)	233 \pm 6	14.21 \pm 0.5	7,291 \pm 185	15.12 \pm 0.76	1595 \pm 236	ND
<i>P</i> value (between 1 and 3)		<0.001	<0.025	<0.01	<0.05	
Experiment 2						
Zero time (Group 1)	195 \pm 3.5	7.78 \pm 0.24	18,789 \pm 2040	13.76 \pm 0.23	1475 \pm 26	0.7 \pm 0.27
<i>P</i> value (between 2 and 1†)		NS	NS	<0.025	NS	NS
After 2 weeks control‡ diet (Group 2)	207 \pm 4.6	7.86 \pm 0.32	18,328 \pm 1945	18.44 \pm 1.49	1617 \pm 81	1.3 \pm 0.4
<i>P</i> value (between 3 and 2)		<0.001	<0.005	NS	<0.005	<0.005
After 2 weeks CMD diet (Group 3)	234 \pm 6.6	13.63 \pm 0.35	7,792 \pm 1745	20.61 \pm 1.66	2123 \pm 119	14.8 \pm 3.7
<i>P</i> value (between 1 and 3)		<0.001	<0.005	<0.005	<0.001	<0.01

NS, not significant; ND, not done.

* Results are expressed as the average of 3-5 rats \pm SE.

† Student *t* test for differences between means at the 95% confidence level.

‡ In Experiment 1, the control diet used was a high protein (26%) diet (No. 101), and in Experiment 2 Rodent Laboratory Chow (No. 5001) was used.

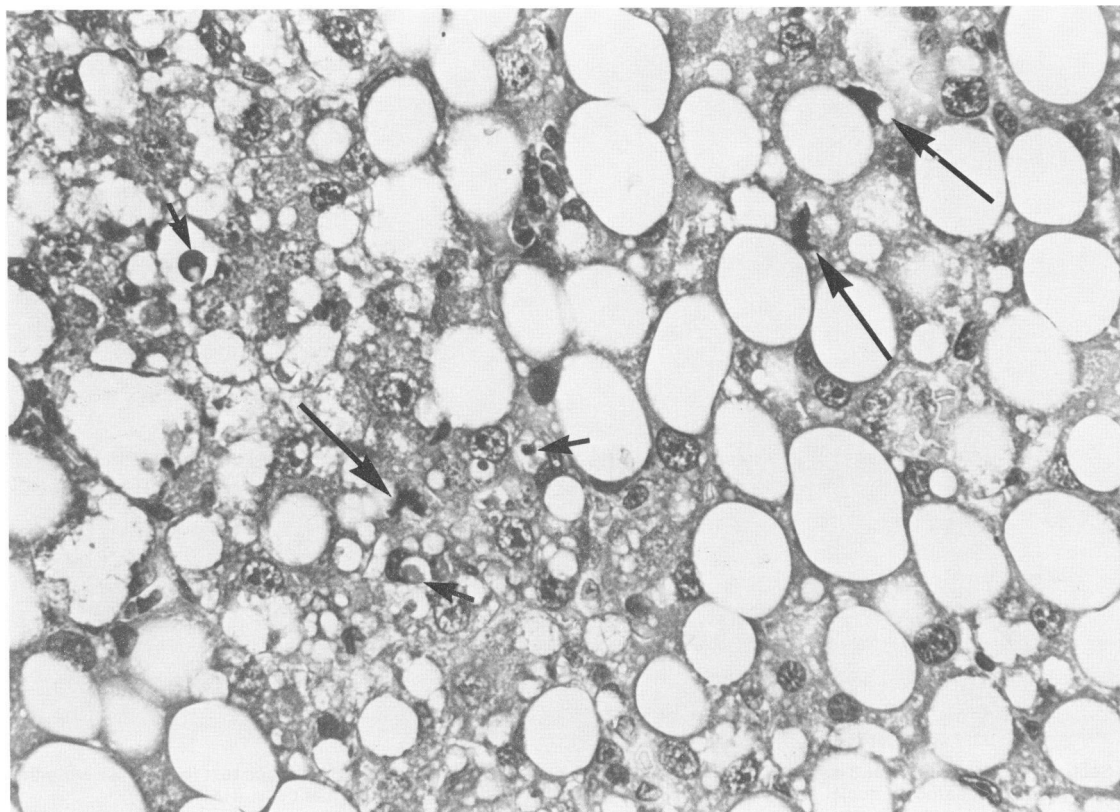


Figure 2—Section of a liver from a rat fed the CMD diet for 2 weeks (from Week 3 to Week 5). Note the extensive fatty change in the majority of hepatocytes, the mitotic figures (*long arrows*), and focal necrosis (*short arrows*). (H&E, $\times 300$)

weighing 100–110 g, were used. On arrival, the animals were acclimatized to a daily cycle of alternating 12-hour periods of light and darkness for 1 week before the start of the experiment. They were given food and water *ad libitum*.

Experimental Design

Fourteen rats were partially hepatectomized.²³ Beginning 16 hours later (Figure 1), each rat was given 9 injections of ³H-thymidine (methyl-³H-thymidine, 84 Ci/mmol, New England Nuclear, Lachine, Quebec) of 50 μ Ci each at 4-hour intervals, 5 on the first day and 4 on the second day. The animals were allowed to recover completely for a 21-day period, during which the liver can return to a nonproliferating state. At that time, 4 rats were killed under light ether anesthesia, and the remaining 10 rats were divided into two groups of 5. One group was given the CMD diet (Table 1), and the other group was given a high-protein basal diet (No. 101) for another 2 weeks, when all the 10 rats were killed. This experiment was repeated once, using the Purina Rodent Laboratory

Chow (No. 5001) in place of the basal diet No. 101. Animals on a choline-supplemented (CS) diet were not used for comparison. Because animals on a CS diet do not show any cell proliferation, do not substitute for PH in the initiation of hepatic carcinogenesis,^{12,33} and do not show any liver changes when compared with animals on Rodent Laboratory Chow or on the basal diet, and since the animals on each diet are compared with their own controls at 3 weeks (Figure 1), it was not considered necessary to include a group of animals on the CS diet in this study.

Histologic and Biochemical Analyses

The animals were killed under light ether anesthesia, and blood was taken from the inferior vena cava without an anticoagulant. Liver tissue was prepared for routine hematoxylin and eosin (H&E) staining after formalin fixation. Some sections were coated with Kodak NTB 3 emulsion and kept in a sealed desiccator for 3 weeks at 4 C for autoradiography. For biochemical analysis, a 10% homogenate in water was made. DNA was analyzed by Burton's method in

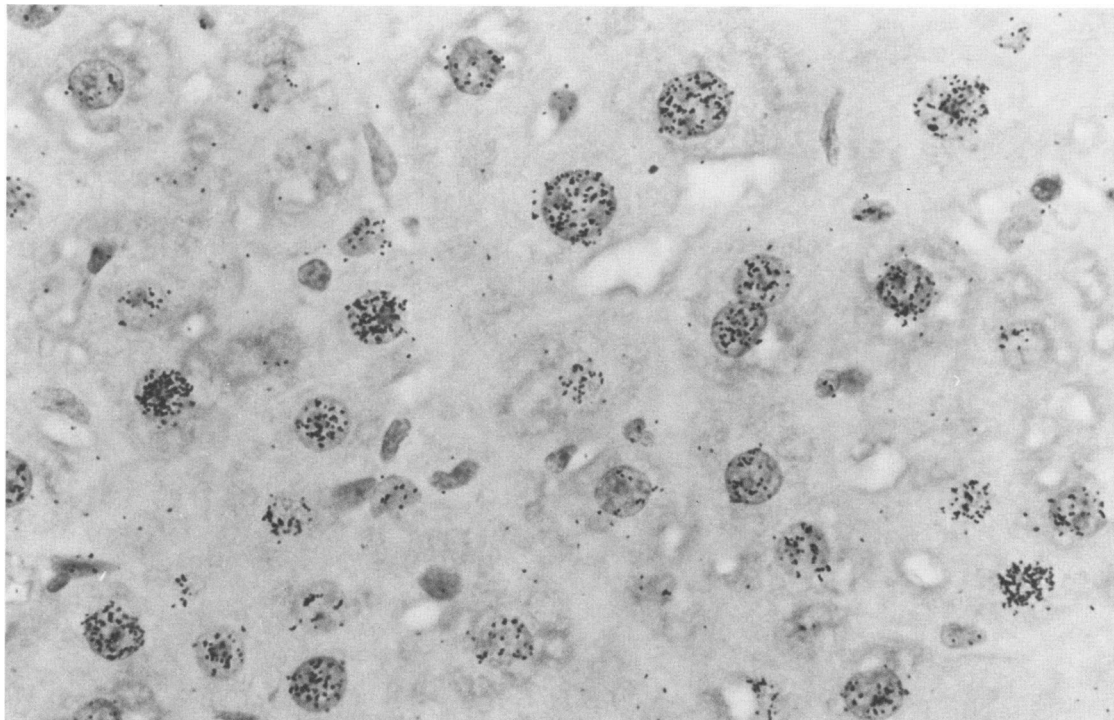


Figure 3—Section of a liver from a rat 3 weeks after PH and given ^3H -TdR beginning 16 hours after PH (see text for details). Note the almost uniform labeling of the hepatocyte nuclei and slight labeling of the nuclei of the nonparenchymal cells. (H&E, $\times 750$)

the total homogenate.²⁴ For radioactivity counting, 10% homogenized sample was precipitated with 1N perchloric acid (PCA), and the precipitate was washed 4 times with 1N PCA, ie, until the washing had only negligible background radioactivity. The washed precipitate was finally hydrolyzed at 70 C water bath with 1N PCA for 60 minutes, cooled, and centrifuged at 3500 rpm for 20 minutes. The clear supernatant was counted in duplicate in a liquid scintillation counter after mixing with 15 ml of Aquasol. Total protein was measured according to Lowry et al²⁵ in the 10% liver homogenate. Sorbitol dehydrogenase was measured in serum according to Gerlach and Hiby.²⁶

Results and Discussion

The results presented in Table 2 clearly indicate a considerable loss of prelabeled DNA (41% and 59%) in the rats exposed for 2 weeks to the CMD diet and no loss in the animals on Purina Rodent Chow or the basal No. 101 diet. The results are expressed as radioactivity per total liver rather than as specific activity of the DNA. Dilution by cell proliferation or by influx of inflammatory cells would, of course, have resulted

in a decrease in specific activity of the DNA but in no loss of radioactivity per total liver.

Histologic examination of the livers of the rats on the CMD diet revealed a fatty change with evident cell necrosis throughout (Figure 2). In examining between 20 and 30 sections of livers from animals in each group, we have found the presence of liver cell necrosis to be highly reproducible with every section from every animal on the CMD diet showing the changes. The easily identifiable necrotic cells usually did not show a large fatty vacuole but rather only minimal fatty change. Whether this is due to the release of the triglyceride during or after cell death from a cell that had a large fatty vacuole is not known. Also, the degree of hepatocyte necrosis is difficult to gauge because of the extensive triglyceride accumulation. The large increase in liver weight (5.82–6.09 g/100 g body weight as compared with a range of 3.28–3.99 for the controls) is no doubt due in the main to this accumulation. The 11.4-fold increase in the serum sorbitol dehydrogenase (Table 2) is consistent with the liver cell necrosis.

Thus, by three different criteria—histologic examination, serum enzymes, and loss of prelabeled DNA—the livers of the animals on CMD diet for 2

weeks showed a loss of integrity of about 50% of the hepatocytes.

As in previously published studies,²⁻⁴ the livers of the animals on CMD for 2 weeks contained many mitotic figures, averaging approximately 1-3 per high-power field (Figure 2). The livers at 3 weeks, at the time of initial exposure to the CMD or control diet, showed quite uniform labeling of hepatocyte nuclei with little labeling of the vascular lining cells or other nonparenchymal cells (Figure 3). These findings strengthen the likely hepatocyte nature of the bulk of the labeled DNA in the liver and of the prelabeled DNA lost from the liver in the animals fed the CMD diet.

An interesting observation was made in these experiments concerning the DNA. As seen in Table 2, the DNA content per liver at 5 weeks in the animals on CMD and on control diets was considerably increased over the values at 3 weeks after hepatectomy (34-49%). This is not unexpected in view of the report of Fisher and Fisher²⁷ that it takes about 4 weeks to achieve complete recovery following two-thirds hepatectomy. The increase in total liver protein in the animals on the CMD diet is noteworthy but remains unexplained.

It might be argued that the partial hepatectomy used to prelabel the DNA might alter the reaction of the liver to the CMD diet. This is made most unlikely by the observations that intact animals given the CMD diet for 2 or 3 weeks had histologic changes in their livers including fatty change, liver cell necrosis, and mitotic figures indistinguishable from the changes seen in this study. These animals were used in the study of the initiation of liver carcinogenesis with carcinogens in which exposure to CMD diet was used in place of partial hepatectomy.^{12,23}

The mechanism underlying the hepatocyte cell death in animals fed the CMD diet is not understood. Moderate accumulations of triglyceride in hepatocytes, as, for example, with ethionine or on feeding orotic acid, are not usually associated with cell death. Whether the larger accumulation of triglycerides *per se* in choline deficiency might lead to irreversible cell injury is not known. Because the choline-deficient methionine-low diet is associated with major alterations in methylation of many cell constituents including cell membranes,^{28,29} a plausible hypothesis would relate the cell death to disturbances in membrane structure (eg, lecithin, etc.), perhaps aggravated by the progressive accumulation and distortion of hepatocytes by the increase in triglycerides. Another attractive possibility is that the irreversible cell injury is a consequence of lipid peroxidation associated with the

steatosis resulting from the choline deficiency.³⁰ Lipid peroxidation is considered to be an important basis for the genesis of liver cell necrosis with some toxic agents.³¹

The results of this study offer considerable experimental evidence in favor of the hypothesis that hepatocyte proliferation seen in animals fed a CMD diet may be a consequence of cell loss rapidly induced by this dietary regimen. A similar conclusion was very recently reported by Giambarresi et al³² after the completion of this study. The biochemical basis for this phenomenon and the long-term consequence of chronic liver cell necrosis offer interesting aspects to be explored.

References

1. Hartroft WS: The sequence of pathologic events in the development of experimental fatty liver and cirrhosis. *Ann NY Acad Sci* 1953-54, 57:633-645
2. Newberne PM, Rogers AE: Aflatoxin B₁ carcinogenesis in lipotrope deficient rats. *Cancer Res* 1969, 29:1965-1972
3. Boss JM, Rosenmann E, Zajicek G: Alpha-fetoprotein and liver cell proliferation in rats fed choline-deficient diet. *Z Ernahrungswiss* 1976, 15:211-216
4. Abanobi SE, Lombardi B, Shinozuka H: Stimulation of DNA synthesis and cell proliferation in the liver of rats fed a choline-devoid diet and their suppression by phenobarbital. *Cancer Res* 1982, 42:412-415
5. Shinozuka H, Lombardi B, Sell S, Iammarino RM: Enhancement of DL-ethionine-induced liver carcinogenesis in rats fed a choline-devoid diet. *J Natl Cancer Inst* 1978, 61:813-817
6. Shinozuka H, Lombardi B, Sell S, Iammarino RM: Early histological and functional alterations of ethionine liver carcinogenesis in rats fed a choline-deficient diet. *Cancer Res* 1978, 38:1092-1098
7. Shinozuka H, Katyal SL, Lombardi B: Azaserine carcinogenesis: organ susceptibility change in rats fed a diet devoid of choline. *Int J Cancer* 1978, 22:36-39
8. Sells MA, Katyal SL, Sell S, Shinozuka H, Lombardi B: Induction of foci of altered, γ -glutamyltranspeptidase-positive hepatocytes in carcinogen-treated rats fed a choline-deficient diet. *Br J Cancer* 1979, 40:274-283
9. Lombardi B, Shinozuka H: Enhancement of 2-acetylaminofluorene liver carcinogenesis in rats fed a choline-devoid diet. *Int J Cancer* 1979, 23:565-570
10. Shinozuka H, Sells MA, Katyal SL, Sell S, Lombardi B: Effects of a choline-devoid diet in the emergence of γ -glutamyltranspeptidase-positive foci in the liver of carcinogen-treated rats. *Cancer Res* 1979, 39:2515-2521
11. Newberne PM, Rogers AE, Nauss KM: Choline, methionine and related factors in oncogenesis, *Nutritional Factors in the Induction and Maintenance of Malignancy*. Edited by CE Butterworth, M Hutchinson. New York, Academic Press. (In press)
12. Ghoshal AK: Choline-lipotrope deficient (CLD) diet as a mitogenic substitute for partial hepatectomy (PH) in the induction of resistant hepatocytes by carcinogens as a short term *in vivo* test. *Proc Am Assoc Cancer Res* 1982, 28:96
13. Shulte-Hermann R: Induction of liver growth by xenobiotic compounds and other stimuli. *CRC Crit Rev Toxicol* 1974, 3:97-158

14. Nachtomi E, Farber E: Ethylene dibromide as a mitogen for liver. *Lab Invest* 1978, 38:279-283
15. Schulte-Hermann R: Reactions of the liver to injury in adaptation, *Toxic Injury of the Liver*. Edited by E Farber, MM Fisher. New York, Marcel Dekker, 1979, pp 385-444
16. Post J, Hoffman J: Hepatic cell replication during growth and regeneration. *Prog Liver Disease* 1965, 2: 155-165
17. Becker FF: The normal hepatocyte in division: Regeneration of the mammalian liver. *Prog Liver Dis* 1970, 3:60-76
18. Craddock VM: Cell proliferation and experimental liver cancer, *Liver Cell Cancer*. Edited by HM Cameron, DS Linsell, GP Warwick. Amsterdam, Elsevier Scientific, 1976, pp 153-201
19. Cayama E, Tsuda H, Sarma DSR, Farber E: Initiation of chemical carcinogenesis requires cell proliferation. *Nature* 1978, 275:60-62
20. Columbano A, Rajalakshmi S, Sarma DSR: Requirement of cell proliferation for the initiation of liver carcinogenesis as assayed by three different procedures. *Cancer Res* 1981, 41:2079-2083
21. Ying TS, Sarma DSR, Farber E: Role of acute hepatic necrosis in the induction of early steps in liver carcinogenesis by diethylnitrosamine. *Cancer Res* 1981, 41: 2096-2102
22. Korsrud GO, Grice HC, McLaughlan M: Sensitivity of several serum enzymes in detecting carbon tetrachloride-induced liver damage in rats. *Toxicol Appl Pharmacol* 1972, 22:473-484
23. Higgins GM, Anderson RM: Experimental pathology of the liver: Restoration of the liver in the white rat after partial surgical removal. *Arch Pathol* 1931, 12: 186-202
24. Burton K: A study of the conditions and mechanism of the diphenylamine reaction for the colorimetric estimation of deoxyribonucleic acid. *Biochem J* 1956, 62:315-322
25. Lowry OH, Rosebrough NJ, Farr AL, Randall RJ: Protein measurement with the Folin phenol reagent. *J Biol Chem* 1951, 193:265-275
26. Gerlach U, Hiby W: Sorbitol dehydrogenase: Methods of enzymatic analysis. Edited by HU Bergmeyer, New York, Academic Press, 1974, pp 569-573
27. Fisher ER, Fisher B: Ultrastructural hepatic changes following partial hepatectomy and portacaval shunt in the rat. *Lab Invest* 1963, 12:929-942
28. Lombardi B: Effects of choline deficiency on rat hepatocytes. *Fed Proc* 1971, 30:139-142
29. Saito R, Estes LW, Lombardi B: Reduced response to phenobarbital by the liver of rats fed a choline-deficient diet. *Biochim Biophys Acta* 1975, 381:185-194
30. Ugazio G, Gabriel L, Burdino E: Osservazioni sperimentali sui lipidi accumulati nel fegato di ratto alimentato con dieta colinopriva. *Lo Sperimentale* 1967, 117: 1-17
31. Recknagel RO, Glende EA Jr, Waller RL, Lowrey K: Lipid peroxidation: Biochemistry, measurement, and significance in liver cell injury, *Toxicology of the Liver*. Edited by G Plaa, WR Hewitt. New York, Raven Press, 1982, pp 213-241
32. Giambarresi LI, Katyal SL, Lombardi B: Promotion of liver carcinogenesis in the rat by a choline-devoid diet: Role of liver cell necrosis and regeneration. *Br J Cancer* 1982, 46:825-829
33. Ghoshal AK, Farber E: The induction of resistant hepatocytes during initiation of liver carcinogenesis with chemicals in rats fed a choline deficient methionine low diet. *Carcinogenesis* 1983, 4:801-804