

STAPHYLOCOCCAL ENTEROTOXIN GASTROENTERITIS IN RHESUS MONKEYS

THOMAS H. KENT, M.D.

*From the Department of Experimental Pathology, Walter Reed Army Institute
of Research, Walter Reed Army Medical Center, Washington, D.C.*

The pathologic features of acute staphylococcal food poisoning have not been well described. The disease is rarely fatal in humans and most laboratory animals are much less susceptible than man to peroral challenge with staphylococcal enterotoxin.¹ The only clear description of a lesion attributable to enterotoxin in man is that of Palmer² who studied peroral biopsy specimens of gastric (body) mucosa in patients with staphylococcal food poisoning. He found mild alterations in the superficial part of the gastric mucosa 8 to 82 hours after the onset of symptoms. Warren, Jacobson, Mirany and van Prohaska³ produced a severe enteritis in dogs by the intrajejunal instillation of crude staphylococcal extract. The acute lesion described occurred with a dose that was fatal to some animals. The predominant reaction after repeated instillations of enterotoxin was lymphoid hyperplasia. Warren, Sugiyama and van Prohaska⁴ also described enterocolitis in chinchillas after repeated oral doses of enterotoxin. Next to man and chimpanzees, the monkey has been found to be the most susceptible laboratory animal to enterotoxin.^{1,5} The vomiting response of monkeys has become the standard method of assay.¹

The enterotoxin is an exotoxin produced by certain strains of *Staphylococcus aureus*. Two antigenic types designated "A" and "B" have been identified and purified, and other types probably exist.⁶ Enterotoxins A and B both induce vomiting in laboratory animals, but epidemiologically staphylococci producing the A toxin have been isolated more frequently in cases of food poisoning and staphylococci producing both enterotoxins have been more frequent in cases of enterocolitis.^{6,7} Schantz and associates⁸ have purified enterotoxin B to a high degree and have found it to be a simple protein of molecular weight 35,300.^{9,10}

In an attempt to simulate the conditions of human staphylococcal food poisoning the sequential changes induced in rhesus monkeys by a single oral dose of purified enterotoxin B were studied. The possibility that repeated doses of enterotoxin might produce chronic gastritis or enteritis prompted a preliminary study of the effects of daily enterotoxin administration in monkeys.

Accepted for publication, October 11, 1965.

MATERIAL AND METHODS

Purified staphylococcal enterotoxin B was supplied in lyophilized form by Dr. Edward J. Schantz, U.S. Army Biological Laboratories, Fort Detrick, Md. The 50 per cent effective dose (ED_{50}) to induce emesis in *Macaca mulatta* by the oral route was stated to be 0.9 μg per kg. The enterotoxin was diluted in 0.9 per cent NaCl just prior to use and administered by gastric tube in the morning before the daily food ration was offered.

Rhesus monkeys (*Macaca mulatta*) of both sexes weighing 2 to 3 kg were used. The animals were housed in separate cages and fed Purina® Monkey Chow and water *ad libitum*. The principles of laboratory animal care as promulgated by the National Society for Medical Research were observed. Many of the monkeys had been immunized by oral challenge with *Shigella-Escherichia coli* hybrids and subsequently challenged with virulent *Shigella* organisms 2 weeks prior to being used for the present experiment. Animals used in this experiment for enterotoxin challenge, however, had not exhibited signs of shigellosis.

Twenty-six monkeys, including the control animals in each experiment, were used to assess the normal histologic structure of the gastrointestinal tract. In order to exclude any changes due to shigellosis, the control group was chosen as follows: 2 had shigellosis and were killed 3 days after challenge; 10 were killed 2 days after challenge with hybrid *Shigella-E. coli* organisms; 8 immunized animals were killed more than 2 weeks after challenge with virulent *Shigella*, and 6 had not been used for *Shigella* experiments.

In the first acute experiment groups of 3 monkeys were killed 0, 1, 2, 4, 6, 8, 24, 48 and 72 hours after administration of 30 μg enterotoxin in 10 ml of saline by gastric tube. In the second acute experiment groups of 3 animals were killed 0, 2, 4, 8, 12, 24, 48 and 72 hours after administration of 150 μg enterotoxin in 20 ml of saline.

In the first chronic experiment 2 monkeys were given 30 μg of enterotoxin in 10 ml of saline and 2 monkeys were given 15 μg enterotoxin in 5 ml saline daily for 11 days. The animals were killed 4 hours after the last dose. In the second chronic experiment 6 monkeys were given 150 μg of enterotoxin in 5 ml of saline daily for 10 days and killed 24 hours after the last dose. In the third chronic experiment 6 monkeys were given 150 μg of enterotoxin in 50 ml of saline daily for 10 days, and 2 were killed at 8 hours and 4 at 24 hours after the last dose.

The animals were anesthetized with 2 to 3 ml pentobarbital sodium and killed by opening the chest cavity in the process of dissecting the stomach. Approximately 5 cm segments of upper jejunum, mid-small intestine and lower ileum were opened along the mesenteric border, pinned flat in a pan containing solid paraffin and immersed in 10 per cent formalin buffered with 2 per cent sodium acetate. The stomach with attached segments of esophagus and duodenum was opened along the greater curvature and pinned flat on paraffin. After fixation longitudinal strips of small intestine and continuous strips of stomach from the anterior wall, lesser curvature (including esophagus and duodenum), and posterior wall were trimmed for embedding (Fig. 1). Sections were also taken from lung, heart, cecum, transverse colon, liver, spleen, kidney, adrenal gland, pancreas and mesenteric lymph nodes. All sections were stained with hematoxylin and eosin. Selected sections were stained with periodic acid-Schiff (PAS) and alcian blue stains.

RESULTS

Acute Experiments with a Single Dose of Enterotoxin

Clinical Signs. With the 30 μg dose none of the monkeys appeared ill at 2 hours. Diarrhea and vomiting occurred in 1 animal killed at 4 hours,

and in 2 of each of the 3 animals killed at 6 and 8 hours. About one-half of the remaining animals exhibited diarrhea or vomiting. With 150 μg of enterotoxin 1 of the animals killed at 2 hours vomited, another had a loose stool containing mucus, and the third was not apparently ill. Of the remaining 18 monkeys that received 150 μg of enterotoxin 17 developed vomiting or diarrhea. Fifteen of 18 vomited and this usually occurred by 2½ hours after challenge. Twelve of 15 animals sacrificed after 4 hours developed diarrhea; this usually began 3 to 4 hours after challenge. The diarrhea was accompanied by the passage of mucus in many instances. At no time did any of the animals appear profoundly ill.

Gross Necropsy Findings. The gastric mucosa in rhesus monkeys exhibits 3 distinct zones here designated fundus, body and antrum (Fig. 1). In several animals killed 4 to 12 hours after administration of 30 or 150 μg of enterotoxin the upper stomach and antrum were hyperemic. One control animal with acute shigellosis had multiple hemorrhagic ulcers which were fairly sharply localized in the body of the stomach. Another control animal and 2 experimental animals had a granular red gastric body mucosa which represented the healing stage of ulcers. The small intestine exhibited no striking gross features. From 2 to 8 hours after challenge with 30 or 150 μg of enterotoxin there was often an increase in mucus in the lumen, especially in the ileum, and the wall of the small intestine was slightly congested and edematous. No gross changes were seen in the colonic wall except for the presence of Oesophagostomum parasites in all animals. The colonic content was pasty to liquid from 4 to 12 hours after challenge. Lymph nodes in the abdomen were prominent but did not differ from those in controls. No other gross lesions were observed.

Microscopic Observations. Stomach. The gastric mucosa in the rhesus monkey is slightly different from that of the human subject. Considerable confusion can arise if the stomach is not pinned out for fixation and if the sections are not carefully labeled as to location. The fundic mucosa (Fig. 2) differs from man in that parietal cells are absent except at the transition zone with the body mucosa.¹¹ The foveolae are long and the upper part of the glands contain mucous cells. Chronic inflammatory cells were present in the superficial fundic mucosa in mild to moderate numbers in 17 of 26 control monkeys (Fig. 2). The morphologic appearance of the body and antral mucosa (Figs. 3 and 4) was quite similar to that in man. There was slight chronic superficial gastritis in 6 controls and slight chronic antral gastritis in 7 controls. The cardiac region contained a few irregular mucous glands and lymphoid follicles.

There was considerable variation in the degree and distribution of gastric lesions after 30 or 150 μg of enterotoxin. With the 30 μg dose

there was an inverse relationship between the severity of gastric and small intestinal lesions which suggested that there was variation in gastric emptying. With the 150 μ g dose, which was given in a larger volume of saline, the small intestinal lesion was quite consistent among groups of 3 animals, and the gastric lesions tended to be less severe than those seen with the 30 μ g dose. This data also suggested that gastric emptying was an important factor in determining the site of the lesion.

The gastric lesions affected the antrum and fundus to a much greater degree than the area containing parietal cells (Figs. 5 to 8). The earliest reaction was an exudation of neutrophils. This was observed in 1 of 3 monkeys at 1 hour and 2 of 6 monkeys at 2 hours after enterotoxin administration. By 4 hours all 3 animals in each experiment had well developed gastritis. In this early lesion, especially in the fundus, neutrophils were present in the superficial lamina propria and epithelium; surface cells were distended with mucus, and the lumen contained a mucopurulent exudate (Fig. 5). At 6 to 8 hours, when the lesion was maximal, surface and deep gland cells of the fundus and antrum were depleted of mucus and neutrophils lay deeper in the lamina propria and in foveolae (Figs. 6 and 8). The maximal lesion in the body mucosa consisted of focal infiltrations of neutrophils in the superficial lamina propria and epithelium (Fig. 7). By 8 hours there was a decrease in neutrophils and an increase in macrophages in all areas.

The lesions present at 24, 48 and 72 hours were so inconstant within groups of 3 animals with the same treatment and time interval that it is difficult to present a clear picture of the healing process. In general, after 24 hours the inflammatory cells were predominantly of mononuclear type and the amount of mucus in surface cells and deep glands returned toward normal. Chronic antral inflammation, with small foci of acute inflammatory cells, persisted in about one-half of the monkeys to 72 hours. The degree of inflammation in the body and upper stomach tended to be much less severe at 24 hours and thereafter, so that it was difficult to tell whether this represented residual inflammation from the enterotoxin or inflammation present before challenge.

Healing ulcers similar to those in one control animal were seen in 2 monkeys killed at 24 and 72 hours. These lesions were of interest because of their contrast with those attributed to enterotoxin. The ulcerations were localized both grossly and microscopically to the area containing parietal cells and were characterized by loss of glandular epithelium and prominent hyperplasia of the surface mucus secreting epithelium. In contrast, the enterotoxin lesion tended to be localized to the antrum and fundus and was not characterized by a loss of glandular epithelium or by a great increase in mucus secreting cells.

Small Intestine. The small intestinal mucosa was quite uniform in appearance in all control animals including the 2 with colonic lesions of shigellosis (Fig. 9). Many rhesus monkeys with severe shigella-induced colonic lesions of shigellosis have been studied prior to the present experiments. A small percentage of the animals had mild inflammatory changes in the ileum but not in the jejunum. Small intestine lesions have not been observed in asymptomatic monkeys harboring *Shigella* or in monkeys fed *Shigella-E. coli* hybrids. The structure of the normal small intestinal mucosa is not greatly different from human small intestine and will not be further described.

The small intestine lesions after 150 μ g enterotoxin were very constant within groups of 3 animals killed at the same time interval except for 1 animal killed after 12 hours which had no reaction in either the intestine or stomach. The lesions produced by 30 μ g of enterotoxin were nearly as severe in some animals but were less constant in each group. The following description relates to animals receiving the larger dose except as mentioned. The inflammatory reaction was of decreasing severity from jejunum to ileum in all cases. Duodenal alterations corresponded to those in the jejunum, but they were more difficult to evaluate because of the normal irregularity of the villi in the duodenum.

The earliest change observed was at 1 hour in the jejunum of an animal given 30 μ g of enterotoxin and consisted of a few neutrophils in the tips of villi and increased basophilic debris in macrophages. At 2 hours the lumen of the jejunum contained a mucopurulent exudate, the villi were distended with acute inflammatory cells and the crypts were mildly elongated (Fig. 10). The surface epithelium appeared well preserved except for focal degeneration (Fig. 11). At 4 hours jejunal crypts extended as much as three-quarters of the way to the surface; the surface and crypt epithelium appeared cuboidal with loss of a distinct brush border in most areas, and the lamina propria was filled with neutrophils and macrophages containing debris (Figs. 12 and 13). Mitoses were more frequent than normal and some were present in the upper portions of elongated crypts. At 8 hours the crypts in the jejunum extended nearly to the surface in many areas and the epithelium remained abnormal (Fig. 14). By this time there were few neutrophils and the lamina propria appeared more compact. At 12 hours the villi of the jejunum appeared taller and epithelial cells were more columnar. By 24 hours the crypt length was about one-half the mucosal thickness; the epithelium was nearly normal; and there was much less inflammatory cell infiltrate in the lamina propria (Fig. 15). At 48 and 72 hours the mucosa exhibited progressive improvement with only slightly elongated crypts remaining as evidence of previous injury (Fig. 16). From 4 to 12

hours after challenge inflammatory cells were present about vessels in the submucosa of the jejunum. Congestion of blood and lymph vessels corresponded with the severity of the lesion. No thrombi were seen.

The ileum exhibited a much less severe reaction. At 2 hours there was slight exudation of leukocytes and increased numbers of macrophages containing basophilic debris in the tips of villi. At 4 and 8 hours the reaction was more severe with a striking increase in goblet cells and a mucopurulent exudate in the lumen (Fig. 17). The ileal crypts did not become greatly elongated and epithelial degeneration was slight except at the tips of villi. By 24 hours the ileum appeared normal.

Colon. A slight exudation of leukocytes and a depletion of mucus in surface cells was observed in the colonic mucosa of many animals at 6 and 8 hours after challenge.

Other Organs. Acute lymphadenitis in mesenteric lymph nodes was first seen at 4 hours, reached a peak at 8 to 12 hours, was diminished at 24 hours and was present in only 2 of 6 animals at 48 hours. No conspicuous changes were seen in other organs, although there appeared to be mild congestion in some and margination of leukocytes in sinusoids of the liver and capillaries of the lungs at the height of the intestinal lesion.

Chronic Experiments with Daily Doses of Enterotoxin

Three of 4 animals given 15 or 30 μg and all 12 animals given 150 μg of enterotoxin had vomiting or diarrhea on the first day. In the first 2 chronic experiments the animals had no vomiting or diarrhea after the second or subsequent doses of enterotoxin. In the third experiment in which 50 ml of saline was used as a diluent, 2 monkeys had continuous diarrhea, 2 had intermittent loose stools and 2 had no diarrhea after the first day. In 1 monkey given the larger dose in 5 ml of saline, enterotoxin was accidentally injected into the lungs. The animal died after an unknown number of hours. Necropsy revealed massive pulmonary edema with early inflammatory reaction. The gross necropsy findings in the remaining monkeys were not striking except for slight changes in the character of the gastric mucosa in some animals.

Microscopic Observations. Gastritis of a degree significantly greater than that observed in control animals was present in 3 of 4 animals given 15 or 30 μg of enterotoxin, in 3 of 5 animals given 150 μg in 5 ml of saline, and in 0 of 6 animals given 150 μg in 50 ml of saline. The antral mucosa was densely infiltrated with chronic inflammatory cells (Fig. 18). The reaction of the surface epithelium was variable with either a mild increase in mucus content or a decrease with mild degenerative changes. Acute inflammatory cells were present in animals sacrificed 4

hours after the last dose but were inconspicuous in animals sacrificed 24 hours after the last dose.

In most of the animals with gastritis there was a chronic superficial inflammatory infiltrate in the body of the stomach with focal deep extension. The areas of deeper involvement exhibited loss of parietal cells, dense chronic inflammatory cell infiltration and glands lined by an undifferentiated type of epithelium extending to the depth of the mucosa (Fig. 19). The fundic mucosa generally contained moderate numbers of chronic inflammatory cells, but this was not much greater than the infiltrate seen in some control animals.

The small intestine appeared normal in most of the animals receiving daily doses of enterotoxin. In 1 or 2 animals in each experimental group the jejunal crypts were elongated up to one-half the mucosal thickness and the lamina propria was slightly more cellular than normal (Fig. 20). Villus epithelial cells appeared tall even in animals sacrificed 4 and 8 hours after the last dose. In the third experiment 50 ml of saline was used as a diluent in an attempt to promote rapid gastric emptying, but this did not result in more severe damage to the small intestine.

DISCUSSION

In this study intragastric administration of purified enterotoxin B in rhesus monkeys produced an acute gastroenteritis which was well developed by 2 hours. The lesions reached a maximum at 4 to 8 hours, rapidly regressed and the mucosa became nearly normal by 72 hours. The time sequence and severity of the lesions correlated well with the onset of vomiting and diarrhea. With the larger dose, which was approximately 50 times the ED_{50} , clinical signs occurred earlier and more constantly and the small intestinal lesions produced were more constant than with the smaller dose which was approximately 10 times the ED_{50} . Although the response was more variable with the small dose, the clinical signs in each animal correlated well with the severity of the lesion in that animal. The variability in the emetic effect in monkeys to small doses of enterotoxin is well recognized.¹²

The gastric lesions were quite variable and did not correlate well with the dose of enterotoxin. This was probably due to variability in gastric emptying. The reason for the relative sparing of the area of the stomach containing parietal cells is not clear.

At the height of the reaction the jejunal mucosa exhibited long crypts and short villi giving an appearance similar to that in celiac disease. This type of lesion has also been observed in many other clinical and experimental disorders¹³ and appears to be a nonspecific reaction of small intestine to injury. Swanson and Thomassen¹⁴ have reviewed the theories

put forth to explain crypt lengthening and villus shortening. In the present study it has been shown that this type of lesion can be produced in as little as 4 hours and considerable recovery may occur at 24 hours after injury. A rapid rate of formation and healing of this type of lesion has also been observed in experimental shigellosis in guinea pigs.¹⁵ Although there may be several mechanisms for producing crypt lengthening and villus shortening, the present experiment suggests a sequence of events. The first reaction (2 hours) was swelling of the villi due to inflammatory cell infiltration and focal epithelial damage at the tips of villi. At this stage the crypts were only slightly elongated. The next step (4 hours) was characterized by more diffuse epithelial degeneration and sloughing and striking lengthening of crypts. At 6 and 8 hours the crypt:villus ratio was even greater. In general, the presence of long crypts was associated with cuboidal epithelium with indistinct brush borders and the presence of mitoses high in the crypts. The presence of mitoses here as early as 4 hours suggests that surface epithelium may have become crypt cells and divided. On the other hand, the presence of well developed villi was associated with tall epithelial cells with distinct brush borders. Reasoning from this sequence of events, an appealing hypothesis to explain the lengthening of crypts is that immature or damaged epithelium has a greater tendency to stick together and form crypts. Swelling of the lamina propria with associated decrease in villus motility may be a contributory factor. Although it is difficult to say which came first, the reappearance of morphologically and enzymatically¹⁶ mature epithelium was associated with re-formation of villi.

The distribution and sequence of the lesions suggests that enterotoxin acts on the mucosa first and then is absorbed with the development of inflammation about submucosal vessels and in mesenteric lymph nodes. The fact that reticuloendothelial blockade increases susceptibility to emesis induced by enterotoxin¹⁷ suggests that the RE system is involved in detoxification. The presence of acute lymphadenitis supports this hypothesis.

This experimental model appears to conform in many ways to human staphylococcal food poisoning. Monkeys are less sensitive to the emetic action of enterotoxin than man.¹ This may, however, be due to a lessened tendency of monkeys to vomit rather than a lesser degree of tissue sensitivity to enterotoxin. There appears to be no serious objection to the use of purified enterotoxin rather than crude staphylococcal filtrate as these both have similar clinical effects in animals. Enterotoxin B was used in this study because it was more readily available, but at present there is no definite evidence that enterotoxin A has a different mode of action. The time sequence of the clinical illness in monkeys is similar to that in

human staphylococcal food poisoning and the attack rate with the larger dose compares with the high attack rate in humans.¹

Even though clinical signs of illness began about the time that lesions developed, vomiting may not have been due to the presence of the lesions. It has been shown that vagectomy in monkeys increases the threshold to emesis induced by intragastric enterotoxin and delays emesis induced by an agent (CuSO_4) acting through gastorointestinal receptors; vagectomy does not, however, affect emesis induced by an agent (veratrum alkaloid) which does not act through gastrointestinal receptors.¹⁸ This evidence suggests that the emetic effect of enterotoxin is on gastrointestinal receptors with an afferent pathway along the vagus nerve. It is also possible that vagectomy results in increased detoxification of enterotoxin in the stomach by delaying gastric emptying. Schantz and co-workers⁸ have shown that enterotoxin is destroyed by pepsin at pH 2 or below. It is not clear whether the enterotoxin acts directly on gastrointestinal receptors for vomiting or whether the development of a lesion activates these receptors. The fact that monkeys as well as other species vomit after small intravenous doses of enterotoxin suggests that enterotoxin has a direct effect on receptors for the vomiting reflex. Evidence that enterotoxin may excite central centers for vomiting includes the fact that reticuloendothelial blockade with thorotrast lowers the emetic threshold to intragastric enterotoxin in monkeys¹⁷ and the fact that surgical destruction of the area postrema (chemoreceptor trigger zone) prevents vomiting in monkeys challenged with intragastric enterotoxin but does not prevent vomiting by an agent (CuSO_4) acting on gastrointestinal receptors.¹⁹

An understanding of the mechanism of vomiting in enterotoxin poisoning is important because the tissue destructive effect and emetic effect of enterotoxin may not always occur together. In this study it is shown that gastritis progressed in 6 of 15 monkeys after daily intragastric doses of enterotoxin in spite of refractoriness to the emesis. Mild enteritis was also evident in a few animals after repeated doses of enterotoxin. There is some evidence that human subjects also become partially resistant to the emetic effect of enterotoxin.¹ It is possible that enterotoxin could cause chronic gastritis or enteritis in humans without producing symptoms. The finding of a high prevalence of chronic gastritis²⁰ and enteritis²⁰⁻²² in areas of the world where food handling techniques and lack of refrigeration would appear to favor bacterial contamination indicate that further investigation of enterotoxin as the cause of such lesions may be worthwhile. Very little information is available about staphylococcal food poisoning in underdeveloped countries. The recent development of methods for detecting enterotoxin in food⁷ may help

clarify this problem. Felsenfeld and Nasuniya²⁸ found enterotoxigenic staphylococci in approximately 20 per cent of food samples collected in open markets in Thailand, and found higher serum levels of anti-enterotoxin in normal Thais than in Americans who had recently arrived in Thailand. Thais and Americans who had symptoms of staphylococcal food poisoning developed high anti-enterotoxin titers.

Further study of the mechanism of destruction or resistance to enterotoxin in monkeys could also help clarify the role of enterotoxin in producing chronic gastritis or enteritis. For about 1 week after a single oral dose of enterotoxin monkeys fail to vomit in response to a second dose,¹⁷ but it is not known whether this is due to increased destruction of enterotoxin or to refractoriness to its emetic effect. Although animals produce specific antibodies when enterotoxin is given parenterally in large doses,¹ the protective role of antibodies induced by ingestion of enterotoxin is not known.

SUMMARY

Intragastric administration of purified staphylococcal enterotoxin B in rhesus monkeys produced an acute gastroenteritis which was well developed by 2 hours, reached a maximum at 4 to 8 hours and rapidly regressed to a state approaching normal by 72 hours. Gastritis was most severe in the antral and fundic mucosa and was less severe in the area of the stomach containing parietal cells. The lesion in the small intestine was of decreasing severity from jejunum to ileum. In the jejunum there was severe epithelial damage with distended villi and crypts extending nearly to the surface. The ileum exhibited much less epithelial damage and only mild alteration in villus architecture.

After daily intragastric doses of enterotoxin 6 of 15 monkeys developed severe antral gastritis and superficial gastritis with focal deep extension in the gastric body mucosa. About one-third of the monkeys given daily doses of enterotoxin had a mild enteritis characterized by crypt lengthening and a slight increase in inflammatory cell infiltration.

REFERENCES

1. DACK, G. M. Food poisoning. The University of Chicago Press, Chicago, 1956, 251 pp.
2. PALMER, E. D. The morphologic consequences of acute exogenous (staphylococcal) gastroenteritis on the gastric mucosa. *Gastroenterology*, 1951, 19, 462-475.
3. WARREN, S. E.; JACOBSON, M.; MIRANY, J., and VAN PROHASKA, J. Acute and chronic enterotoxin enteritis. *J. Exp. Med.*, 1964, 120, 561-568.
4. WARREN, S. E.; SUGIYAMA, H., and VAN PROHASKA, J. Correlation of staphylococcal enterotoxins with experimentally induced enterocolitis. *Surg. Gynec. Obstet.*, 1963, 116, 29-33.

5. WILSON, B. J. Comparative susceptibility of chimpanzees and *Macaca mulatta* monkeys to oral administration of partially purified staphylococcal enterotoxin. *J. Bact.*, 1959, 78, 240-242.
6. CASMAN, E. P.; BERGDOLL, M. S., and ROBINSON, J. Designation of staphylococcal enterotoxins. *J. Bact.*, 1963, 85, 715-716.
7. CASMAN, E. P., and BENNETT, R. W. Detection of staphylococcal enterotoxin in food. *Appl. Microbiol.*, 1965, 13, 181-189.
8. SCHANTZ, E. J.; ROESSLER, W. G.; WAGMAN, J.; SPERO, L.; DUNNERY, D. A., and BERGDOLL, M. S. Purification of staphylococcal enterotoxin B. *Biochemistry (Wash.)*, 1965, 4, 1011-1016.
9. WAGMAN, J.; EDWARDS, R. C., and SCHANTZ, E. J. Molecular size, homogeneity, and hydrodynamic properties of purified staphylococcal enterotoxin B. *Biochemistry (Wash.)*, 1965, 4, 1017-1023.
10. SPERO, L.; STEFANYE, D.; BRECHER, P. I.; JACOBY, H. M.; DALIDOWICZ, J. E., and SCHANTZ, E. J. Amino acid composition and terminal amino acids of staphylococcal enterotoxin B. *Biochemistry (Wash.)*, 1965, 4, 1024-1030.
11. TOKII, S., and TSUKAMOTO, A. The distribution of parietal cells in stomach of monkeys. *Okajima. Folia. Anat. Jap.*, 1953, 25, 27-36.
12. SURGALLA, M. J.; BERGDOLL, M. S., and DACK, G. M. Some observations on the assay of staphylococcal enterotoxin by the monkey-feeding test. *J. Lab. Clin. Med.*, 1953, 41, 782-788.
13. COLLINS, J. R. Small intestinal mucosal damage with villous atrophy. A review of the literature. *Amer. J. Clin. Path.*, 1965, 44, 36-44.
14. SWANSON, V. L., and THOMASSEN, R. W. Pathology of the jejunal mucosa in tropical sprue. *Amer. J. Path.*, 1965, 46, 511-551.
15. FORMAL, S. B.; LABREC, E. H.; KENT, T. H., and FALKOW, S. Abortive intestinal infection with an *Escherichia coli-Shigella flexneri* hybrid strain. *J. Bact.*, 1965, 89, 1374-1382.
16. KENT, T. H.; JERVIS, H. R., and KUHN, J. G. Enzyme histochemistry of acute staphylococcal enterotoxin gastroenteritis in rhesus monkeys. *Amer. J. Path.*, 1966, 48. (In press)
17. SUGIYAMA, H.; BERGDOLL, M. S., and DACK, G. M. Early development of a temporary resistance to the emetic action of staphylococcal enterotoxin. *J. Infect. Dis.*, 1962, 111, 233-238.
18. SUGIYAMA, H., and HAYAMA, T. Comparative resistance of vagotomized monkeys to intravenous vs. intragastric staphylococcal enterotoxin challenges. *Proc. Soc. Exp. Biol. Med.*, 1964, 115, 243-246.
19. SUGIYAMA, H.; CHOW, K. L., and DRAGSTEDT, L. R., II. Study of emetic receptor sites for staphylococcal enterotoxin in monkeys. *Proc. Soc. Exp. Biol. Med.*, 1961, 108, 92-95.
20. RUSSELL, P. K.; AZIZ, M. A.; AHMAD, N.; KENT, T. H., and GANGAROSA, E. J. Enteritis and gastritis in young asymptomatic Pakistani men. *Amer. J. Dig. Dis.* (In press)
21. SPRINZ, H.; SRIBHIBHADH, R.; GANGAROSA, E. J.; BENYAJATI, C.; KUNDEL, D., and HALSTEAD, S. Biopsy of small bowel of Thai people. With special reference to recovery from Asiatic cholera and to an intestinal malabsorption syndrome. *Amer. J. Clin. Path.*, 1962, 38, 43-51.
22. BAKER, S. J.; IGNATIUS, M.; MATHAN, V. I.; VAISH, S. K., and CHACKO, C. C. Intestinal Biopsy in Tropical Sprue. In: Intestinal Biopsy. Ciba Foundation Study Group No. 14. WOLSTENHOLME, G.E.W., and CAMERON, M. P. (eds.). Little, Brown & Co., Boston, 1962, pp. 84-101.

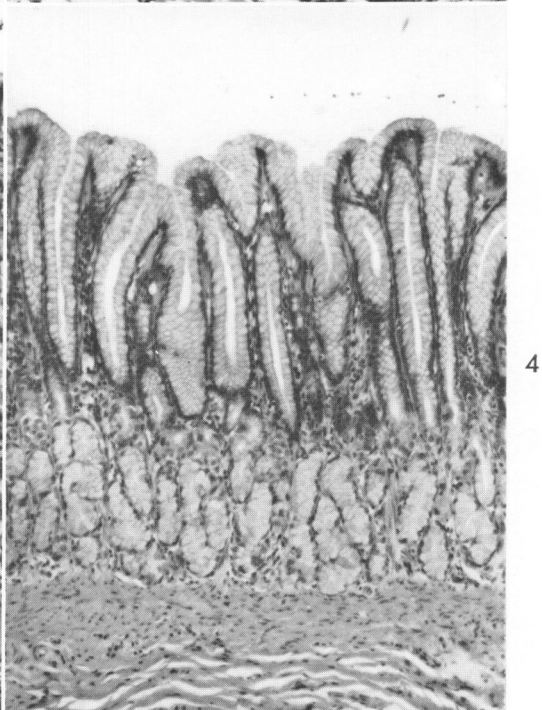
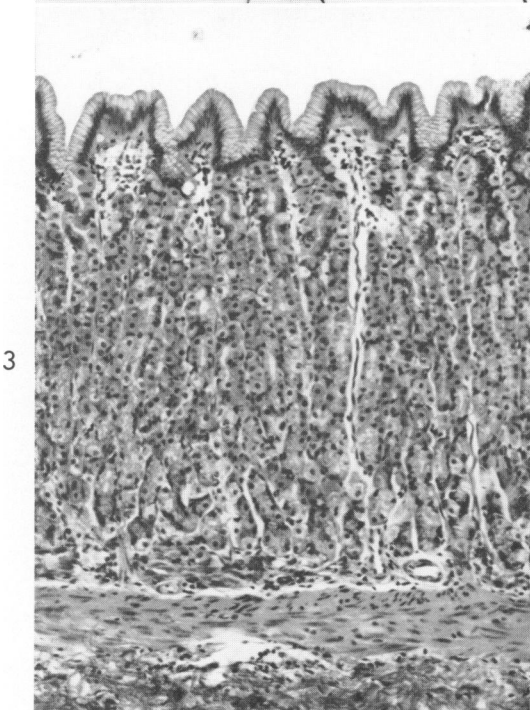
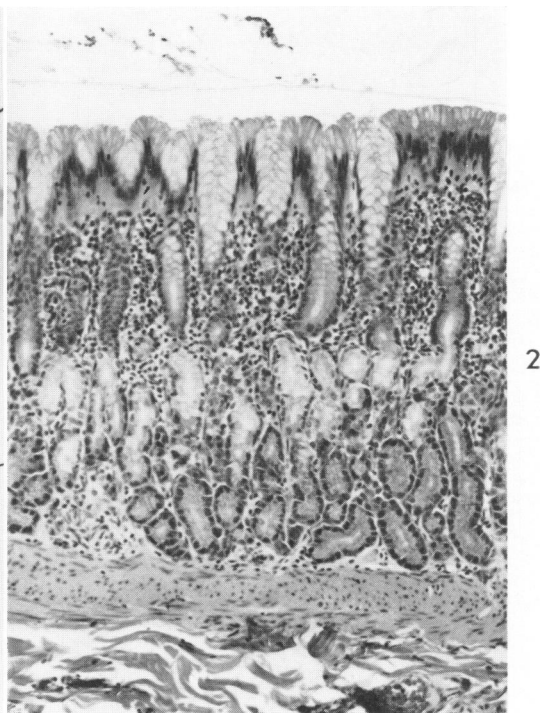
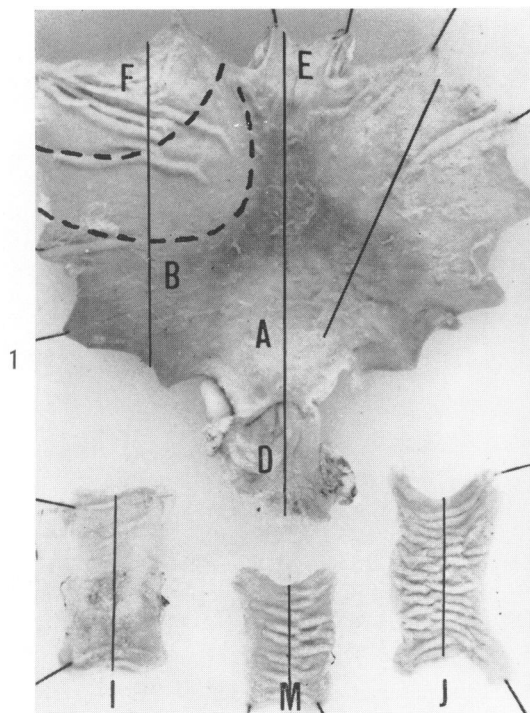
23. FELSENFELD, O., and NASUNIYA, N. Staphylococcal antitoxin values in the sera of permanent residents and visitors in Thailand. *J. Trop. Med. Hyg.*, 1964, 67, 300-303.

Dr. Edward J. Shantz supplied the enterotoxin. Mr. Smiley Austin and Mr. Giles White gave invaluable assistance in handling the monkeys. Mr. John McClain took the photographs. This study would not have been possible without the close cooperation of Dr. S. B. Formal and Colonel Helmuth Sprinz, MC.

LEGENDS FOR FIGURES

All photographs were prepared from sections stained with hematoxylin and eosin.

- FIG. 1. Normal rhesus monkey stomach and small intestine. The stomach displays 3 distinct zones here designated fundus (F), body (B) and antrum (A). The approximate transition zone between fundus and body is marked by dotted lines. Also shown are esophagus (E), duodenum (D), jejunum (J), mid-small intestine (M), and ileum (I). Solid lines indicate the plane of sectioning.
- FIG. 2. Gastric fundus, control monkey. The foveolar and neck regions extend about halfway through the mucosa. The upper part of the glands contain mucous cells and the lower part chief cells. No parietal cells are present in the fundus. Many control monkeys had as much chronic inflammatory cell infiltration as is illustrated here. $\times 80$.
- FIG. 3. Normal gastric body. The glands mainly contain parietal cells, but some chief cells are present in the deeper portion. Inflammatory cell infiltration was minimal in the body mucosa of most control monkeys. $\times 80$.
- FIG. 4. Normal gastric antrum. $\times 90$.



- FIG. 5. Gastric fundus 4 hours after 30 μ g enterotoxin. Cells appear in the lumen and mucous cells are distended. \times 275.
- FIG. 6. Gastric fundus 6 hours after 30 μ g enterotoxin. Surface and deep mucous cells are depleted of mucus and there is an increased inflammatory cell infiltration. Chief cells also appear condensed. \times 80.
- FIG. 7. Gastric body 6 hours after 30 μ g enterotoxin. Focal neutrophil infiltration, as illustrated, was the only reaction evident in the gastric body. \times 80.
- FIG. 8. Gastric antrum 6 hours after 30 μ g enterotoxin. There are severe depletion of mucus, damage to surface epithelium and inflammatory cell infiltration. \times 90.

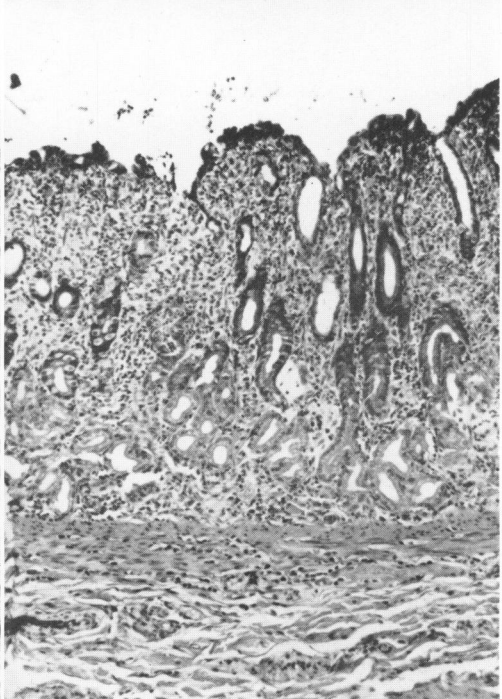
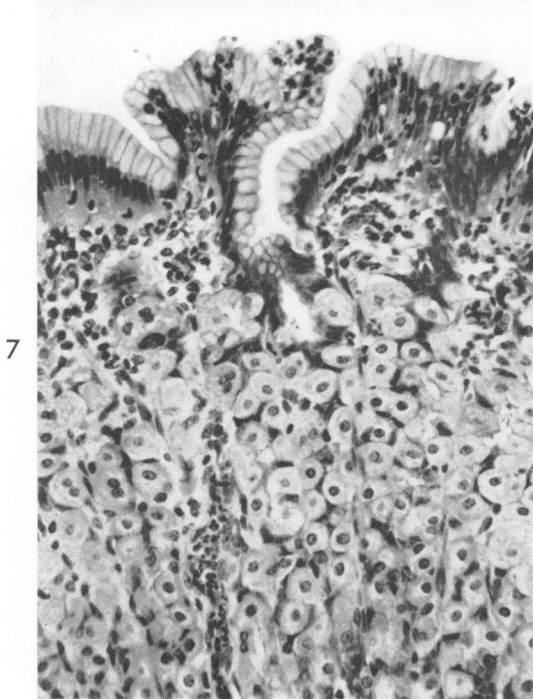
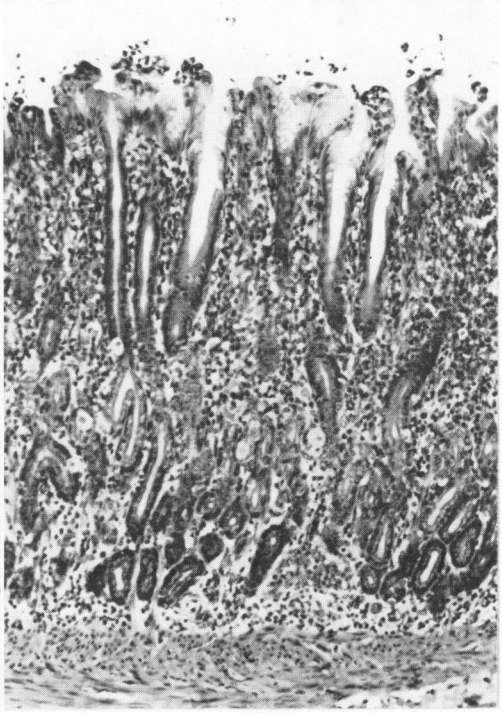
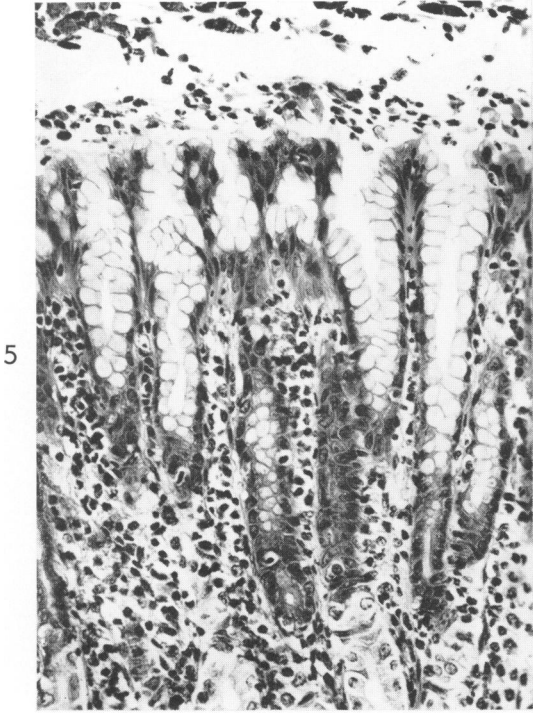
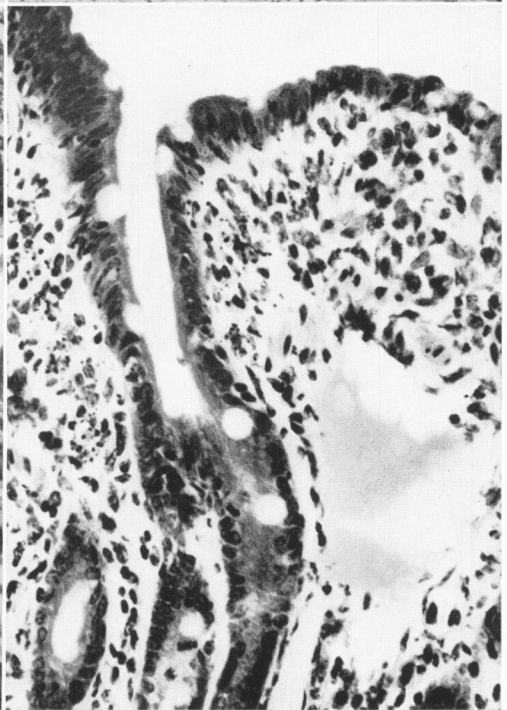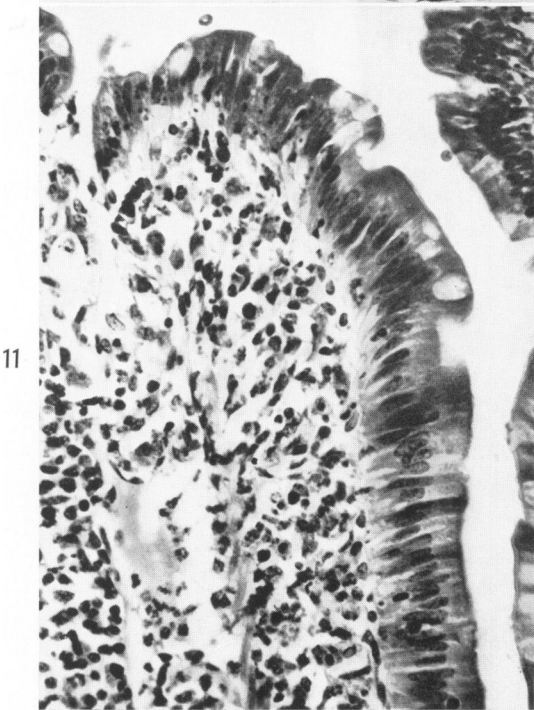
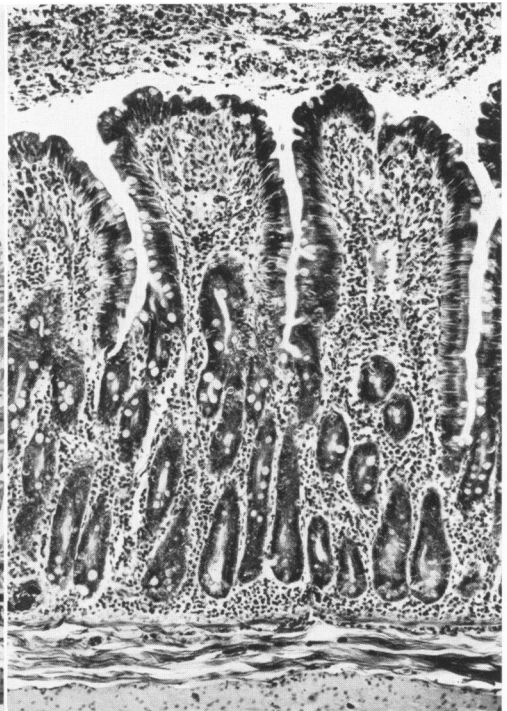
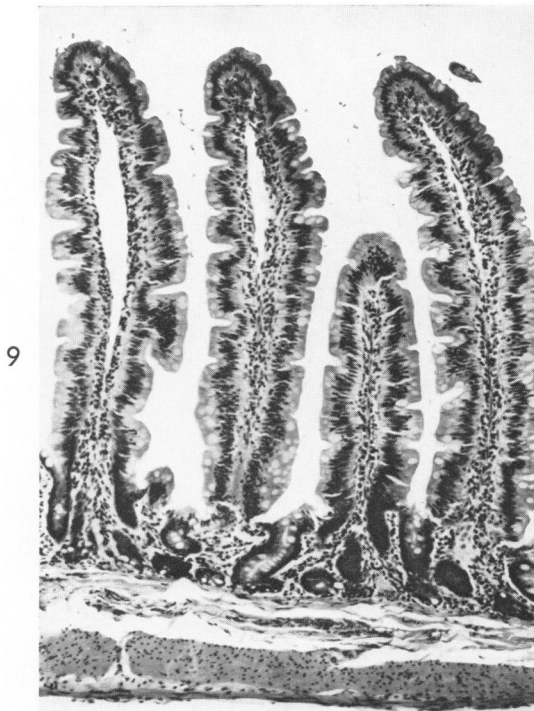


FIG. 9. Normal jejunal mucosa, rhesus monkey. $\times 80$.

FIG. 10. Jejunum 2 hours after 150 μg enterotoxin. Exudate in the lumen is accompanied by distended villi and slightly elongated crypts. $\times 80$.

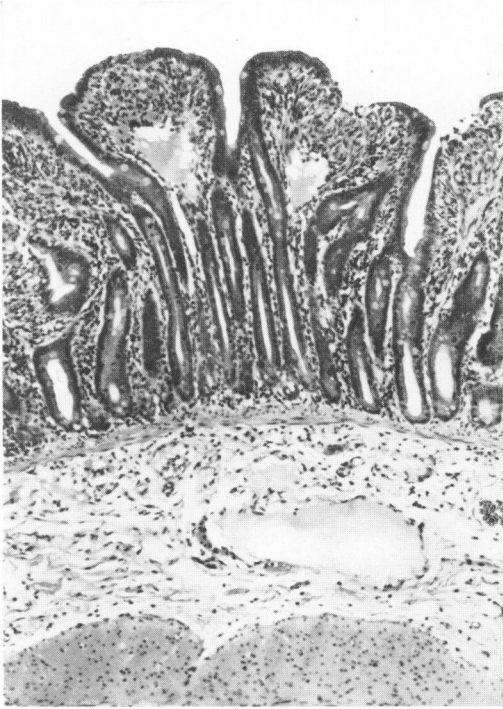
FIG. 11. A higher magnification of Figure 10 illustrates tall epithelial cells with focal degeneration at the tip of a villus. Neutrophils are present in the lamina propria and in a lacteal. $\times 275$.

FIG. 12. Jejunum 4 hours after 150 μg enterotoxin. Epithelium has a more cuboidal shape and there are decreased numbers of neutrophils compared to Figure 11. Mitoses are present in the upper portions of crypts. $\times 275$.

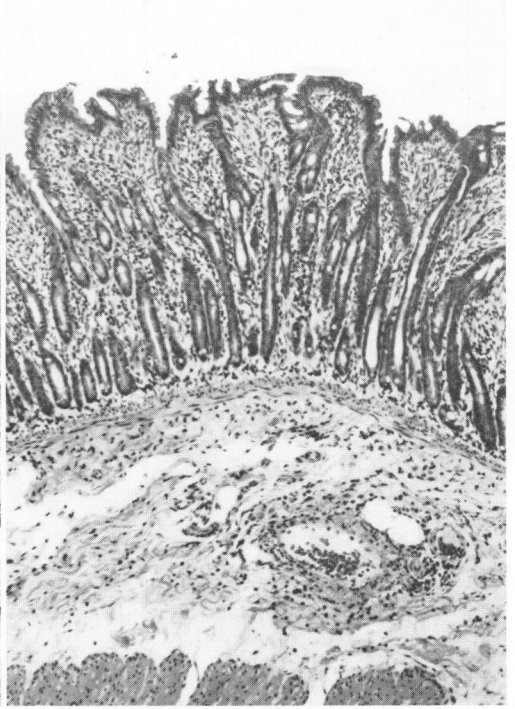


- FIG. 13. Jejunum 4 hours after 150 μ g enterotoxin. Noteworthy are long crypts, cuboidal epithelium and focal erosion at the tips of villi. $\times 80$.
- FIG. 14. Jejunum 8 hours after 150 μ g enterotoxin. The crypts are relatively longer than at 4 hours, but the total mucosal thickness and the amount of inflammatory infiltration are decreased. Inflammatory cells are present about vessels in the submucosa. $\times 80$.
- FIG. 15. Jejunum 24 hours after 150 μ g enterotoxin. The re-forming villi are covered by tall epithelium. The crypt to villus ratio is about 1:1. $\times 80$.
- FIG. 16. Jejunum 72 hours after 150 μ g enterotoxin. The maximum degree of crypt elongation that was evident at 72 hours is illustrated here. $\times 80$.

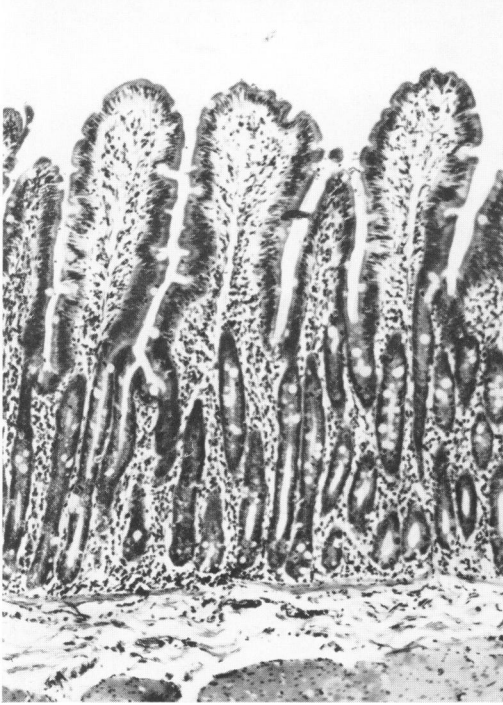
13



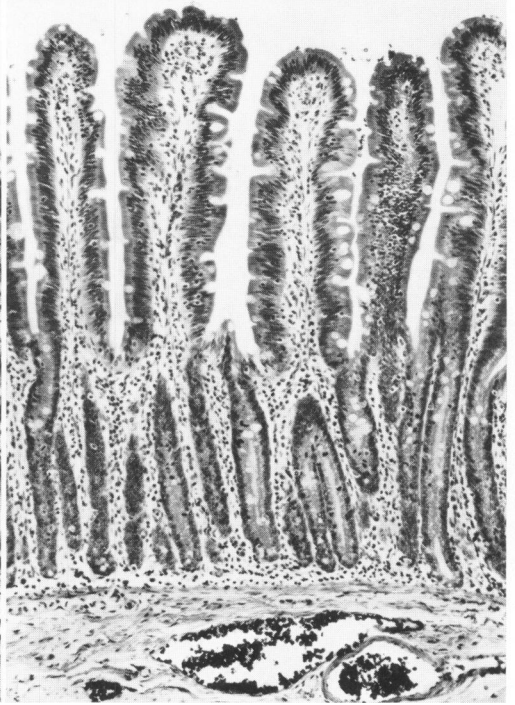
14



15




16

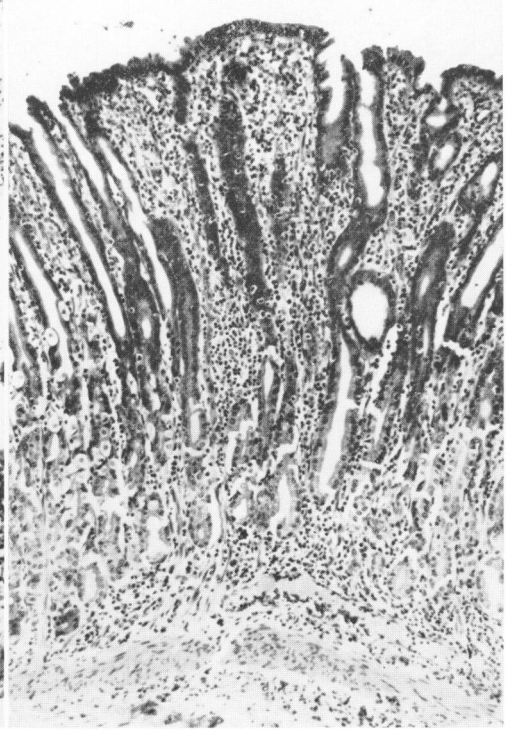


- FIG. 17. Ileum 8 hours after 150 μg enterotoxin. The mucopurulent exudate in the lumen and the increased cellularity of the lamina propria represent the maximum damage observed in the ileum. $\times 80$.
- FIG. 18. Gastric body after 11 daily doses of 30 μg enterotoxin. This monkey was killed 4 hours after the last dose. Focal gastritis involves the full thickness of the mucosa. On the right the glands are lined by undifferentiated cells. On the left parietal and chief cells are present. $\times 80$.
- FIG. 19. Gastric antrum after 10 daily doses of 150 μg enterotoxin. This monkey was killed 24 hours after the last dose. Dense chronic inflammatory cell infiltration is associated with a depletion of mucus from surface and deep cells. $\times 90$.
- FIG. 20. Jejunum after 11 daily doses of 30 μg enterotoxin. This monkey was killed 4 hours after the last dose. The crypts are elongated and there is a slight increase in cellularity in the lamina propria. $\times 80$.

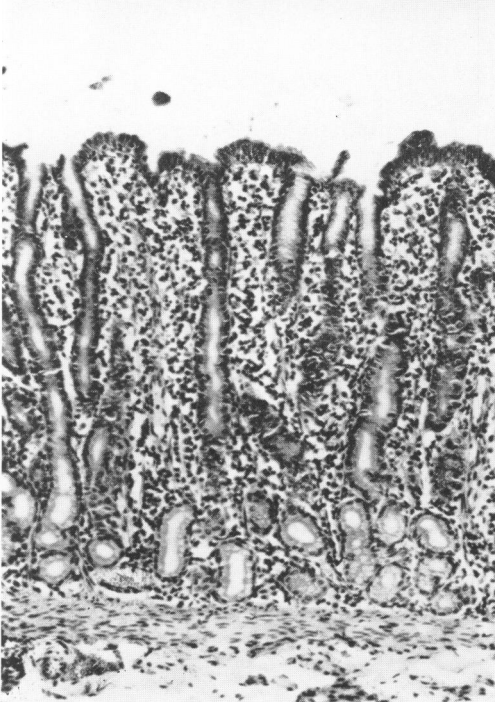
17



18



19



20

