

Clinical Diversity and Chromosomal Localization of X-linked Cone Dystrophy (COD1)

Hee-Kyung Hong,¹ Robert E. Ferrell,¹ and Michael B. Gorin^{1,2}

¹Department of Human Genetics, Graduate School of Public Health, and ²Department of Ophthalmology, School of Medicine, University of Pittsburgh, Pittsburgh

Summary

X-linked progressive cone dystrophy (COD1) causes progressive deterioration of visual acuity, deepening of central scotomas, macular changes, and bull's-eye lesions. The cone electroretinography (ERG) is variably abnormal in affected males, and the rod ERG may also be abnormal. The clinical picture of heterozygous females ranges from asymptomatic to a widespread spectrum of cone-mediated dysfunction. A prior linkage study demonstrated linkage between the COD1 locus and the marker locus DXS84, assigned to Xp21.1, with no recombination. In the present study, we have clinically characterized a large four-generation family with COD1 and have performed a linkage analysis using seven polymorphic markers on the short arm of the X chromosome. No recombination was observed between the disease and the marker loci DXS7 and MAOA, suggesting that the location of COD1 is in the region Xp11.3, distal to DXS84 and proximal to ARAF1.

Introduction

X-linked progressive cone dystrophy (COD1; MIM 304020 [McKusick 1992]) is a disorder primarily affecting the cone system. Affected males present with progressive deterioration of visual acuity, deepening of central scotomas, myopia, absence of nystagmus, and prominent macular changes ranging from granularity to bull's-eye lesions, leading to geographic atrophy of the retina pigment epithelium in older individuals (Pinckers et al. 1981a; Pinckers 1982; Heckenlively and Weleber 1986; Jacobson et al. 1989; Keunen et al. 1990). The retinas of some affected males may present with tapetal-like sheen (Heckenlively and Weleber 1986; Jacobson et al. 1989). Color vision is also impaired, with the eventual development of achromatopsia. Absent or severely attenuated cone-mediated re-

sponses, as well as rod dysfunction, are shown by photopic and scotopic electroretinography (ERG). Female carriers have variable expression of the disorder, clinically asymptomatic to photophobic with mild impairment of visual acuity and abnormalities of color vision, ERG, and visual evoked potential (VEP) (Pinckers et al. 1981a, 1981b; Heckenlively and Weleber 1986; Jacobson et al. 1989; Keunen et al. 1990)

Recently, Jacobson et al. (1989) described a single large family with COD1, which included nine affected and seven normal male offspring of seven obligate-carrier females. Subsequently, Bartley et al. (1989) demonstrated close linkage of COD1 to DXS84 (probe 754), with a maximum lod score ($Z_{\max} = 3.31$ at $\theta_{\max} = .0$, placing the COD1 gene in the region Xp21.1-p11.3. Bergen et al. (1993) presented additional evidence for the assignment of COD1 to the region Xp21.1-p11.3 in a small family. We have identified a four-generation family with X-linked progressive cone degeneration (fig. 1). We have clinically characterized 10 affected males and 9 obligate-carrier females. The clinical spectrum of the disease in this family overlaps that of the previously reported cases of COD1. We have performed a linkage analysis in this family, using markers on the short arm of the X chromosome to further define the location of COD1.

Subjects and Methods

Clinical Evaluation

Thirty-eight members of the four-generation family affected with COD1 were examined. The proband was a 9-year-old male who complained of severe photophobia. He and the other at-risk male members were evaluated for best corrected visual acuities, visual field defects by Goldmann or Humphrey perimetry, color-vision abnormalities (Hardy-Rand-Rittler [HRR] plates, Lanthony test, or Farnsworth Munsell 100 hue), and ERG responses (protocols were in accordance with the international guidelines [International Standardization Committee 1989]). The pedigree of this family is shown in figure 1. One affected male (II-21), refused to participate in the clinical evaluation or linkage analysis. The majority of the potential and actual carriers were evaluated at their homes, with questionnaires, dilated fundus examination and photography, and phlebotomy. The youngest at-risk

Received September 9, 1993; accepted for publication August 12, 1994.

Address for correspondence and reprints: Dr. Michael B. Gorin, The Eye and Ear Institute, 203 Lothrop Street, Pittsburgh, PA 15213.

© 1994 by The American Society of Human Genetics. All rights reserved.
0002-9297/94/5506-0014\$02.00

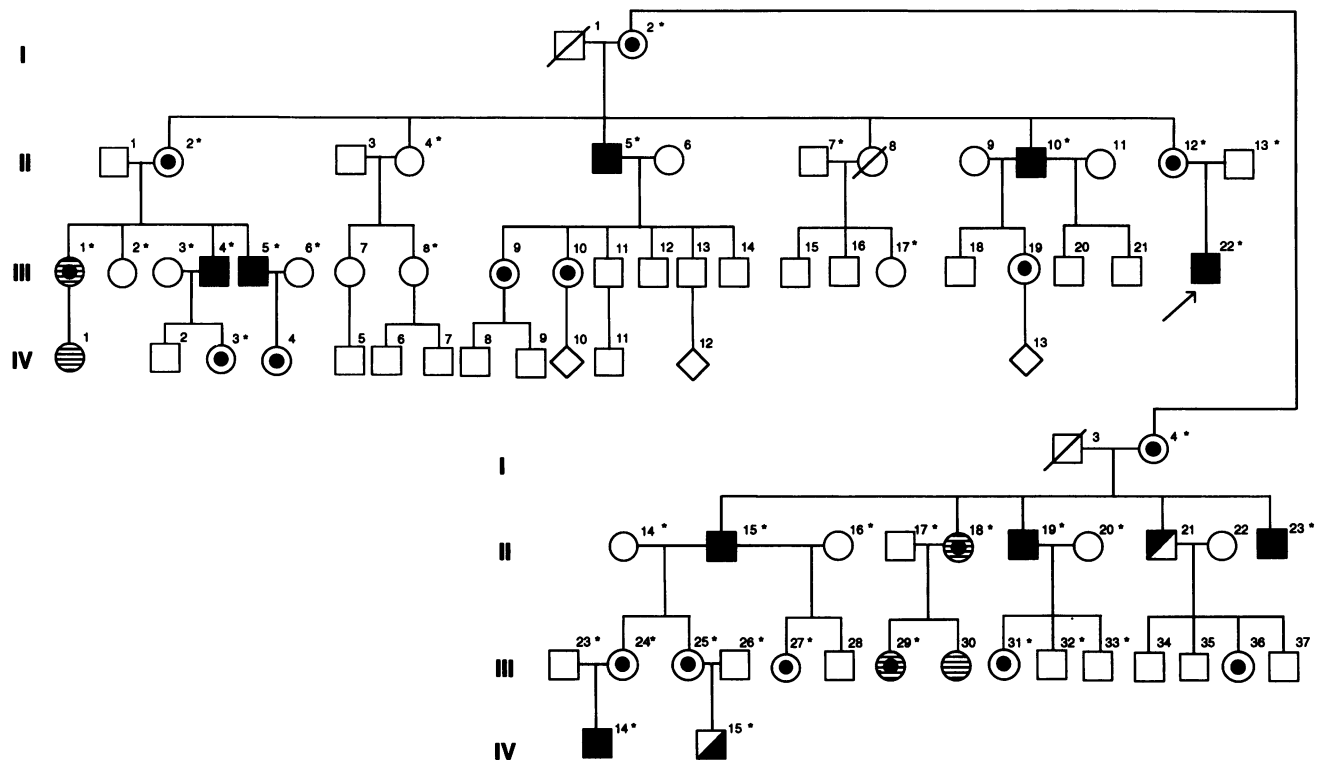


Figure 1 Pedigree of family with X-linked progressive cone dystrophy. An asterisk (*) indicates individuals included in DNA analysis. Shown are males found to be affected on the basis of the molecular study alone (◻), males found to be affected on the basis of clinical examinations alone (◼), males found to be affected on the basis of both the molecular study and clinical examinations (◼), obligate-carrier females (◐), females whose carrier status, on the basis of pedigree position, is unknown (◑), females who were found to have the markers associated with the disease (◉), and females found not to have the markers associated with the disease (○). For tests of linkage, all females were coded as unaffected.

male who was examined was 2 years old, while the oldest affected male was 51 years old.

RFLP Analysis

High-molecular-weight DNA was isolated from peripheral lymphocytes by the salting-out procedure (Miller et al. 1988). Restriction-endonuclease digestion was performed under conditions recommended by the manufacturer (Gibco-BRL). Digested DNA samples were electrophoresed in 0.8%–1.0% agarose gels with TBE buffer (89 mM Tris, 89 mM boric acid, 2 mM EDTA, pH 8.0) and were transferred to MSI Nitro-Plus transfer membrane with $20 \times$ SSC for 24–48 h, according to the method of Southern (1975). Filters were baked for 2 h at 80°C and then prehybridized for 1–2 h at 37°C. Hybridizations were carried out for 18 h at 37°C in 50% formamide, $3 \times$ SSC, 0.1% SDS, 1 mM EDTA, 10 mM HEPES pH 7.5, 100 mg salmon sperm DNA/ml, 0.2% Ficoll, 0.2% polyvinylpyrrolidone, 0.5% sodium pyrophosphate. Probes were labeled by the random oligonucleotide-primed labeling method of Feinberg and Vogelstein (1983), by using α - 32 P-dCTP. Fil-

ters were washed as follows: two 15-min washes in $2 \times$ SSC, 0.1% SDS at room temperature; two 40-min washes in $0.1 \times$ SSC, 0.1% SDS at 55°C; and one 45-min wash in $0.1 \times$ SSC, 0.1% SDS at 65°C. Filters were exposed for autoradiography at -70°C for 1–7 d.

PCR Amplification Analysis

PCR amplification of genomic DNA was performed in an automated thermocycler (model 480; Perkin Elmer Cetus). Amplification reactions were carried out in a volume of 25 μ l containing 100 ng of genomic DNA, 12.5 pmol of each primer, 2.0 mM MgCl_2 , 50 mM KCl, 10 mM Tris-HCl (pH 8.3), 200 mM of each dNTP, and 0.625 units of *Taq* polymerase (Perkin Elmer Cetus). One of each primer set was 5'-end-labeled with α - 32 P-dATP (3,000 Ci/mmol), by using 0.5 μ Ci of primer/12.5 pmol. Cycles were performed as described in table 1. Amplified products were mixed with 25 μ l of formamide sample buffer, and 3–5- μ l aliquots were electrophoresed in 4%–6% denaturing polyacrylamide gels. Sizes of alleles were determined by comparison with M13 DNA sequencing ladders. For the

Table 1**Chromosome Xp Polymorphisms Examined in Present Study**

Locus	Probe	Location	Enzyme	Alleles	Heterozygosity	Reference
DXS84	754	Xp21.1	<i>Pst</i> I	12.0 kb, 9.0 kb	.49	Goodfellow et al. 1985
DXS7	L1.28	Xp11.3	<i>Taq</i> I	12.0 kb, 9.0 kb	.35	Bhattacharya et al. 1984
MAOA		Xp11.3	(CA) _n	7 Alleles (.112-.126kb)	.67	Luty et al. 1989
ARAF1		Xp11.3-11.23	(CA) _n	7 Alleles (.194-.204kb)	.84	Kirchgesner et al. 1991
TIMP		Xp11.3-11.23	<i>Bgl</i> II	3.1 kb, 3.0 kb	.44	Aldred and Wright 1991
DXS426	XL91B10	Xp11.4-11.22	VNTR	12 Alleles (.281-.307kb)	.52	Coleman et al. 1990
DXS1146	HK7.10	Xp11.3-11.22	(CA) _n	6 Alleles (.130-.142kb)	.45	Hong et al. 1993

TIMP locus, PCR amplification was carried out by the method of Aldred and Wright (1991); PCR products were digested with the restriction endonuclease *Bgl*II (BRL) and were separated on a 0.8% agarose gel. The loci examined in the present study are described in table 1.

Data Analysis

Linkage analysis was performed using LINKAGE, version 5.1 (Lathrop et. al. 1985). Pairwise lod scores were calculated using MLINK and ILINK options of the LINKAGE package. For tests of linkage, COD1 was modeled as a fully penetrant X-linked recessive disorder. The frequency of the COD1 gene in the general population was estimated to be .0001. The LINKMAP subroutine of the program LINKAGE was used for multipoint analysis. The order and genetic distances for the markers used in the linkage analysis were estimated from data available in CEPH, version 6, and are DXS84-5 cm-DXS7-1 cm-(MAOA-ARAF1)-4 cm-TIMP.

Results**Clinical Findings**

Despite the published description of this condition as cone dystrophy, the extent of rod and cone involvement among the affected males was quite variable. Though all of the affected demonstrated some of the symptoms and features generally associated with primary cone abnormalities, such as photophobia, color-vision deficits, and central scotomas, significant rod dysfunction was also observed. The scotopic ERG of the proband was more impaired than the photopic responses, while the other affected males continued to show some rod function even when cone responses were nearly extinguished (table 2). All but one of the affected individuals examined had moderate to high myopia. The majority of the affected males lost central vision in their late teens or early twenties, though one individual reported normal vision until the age of 35 years. All but one affected individual reported significant lifelong photophobia that preceded their visual loss. Funduscopic examination ranged from normal to se-

vere macular atrophy to widespread retinal degeneration (fig. 2). The severity of the fundus findings correlates with the degree of visual dysfunction and suggests an age-dependent progression of the condition. As noted in table 2, all of the adult affected males experienced a progressive course of visual deterioration, which is consistent with a degeneration disorder. In those cases for which Humphrey perimetry was done, there was evidence of peripheral visual dysfunction as well as central visual loss. We note that the at-risk males who underwent electrophysiological examination were found to be affected. We propose that this reflects biased ascertainment of this family, which was referred because of the large number of affected males.

The most common symptom among the women who were obligate carriers was photophobia under normal daylight conditions. Many of the obligate carriers noted difficulties with light adaptation and/or night vision; however, these complaints were somewhat nonspecific and were occasionally reported by nonblood relatives within the family. Color vision was normal by simple screening testing, and light adaptation either was normal or there was slight elevation of central cone thresholds. The older obligate carriers and several of the at-risk carriers demonstrated symmetrical changes of the retina and pigment epithelium in the temporal macula, ranging from coalescent drusen to mottled pigment epithelium with or without a retinal sheen. However, DNA linkage established that these changes were not present in all of the women who were COD1 carriers. There were no fundus abnormalities observed in the women who did not carry the COD1-associated markers.

Linkage Analysis

Results of the two-point linkage analysis are summarized in table 3. A total of 10 affected males, 2 unaffected males, 9 obligate carriers, and 7 possible carriers were available for DNA analysis. Two young males did not undergo electrophysiological testing, and their disease status for the linkage analysis was based on ophthalmologic examination. Individual IV-14 was classified as affected, and individual IV-15 was classified as disease status unknown.

Table 2

Summary of Clinical Findings in COD-1-Affected Males

Subject	Age at Examination (years)	Symptoms	Acuity	Refraction	Color Vision	Dark Adaptation	Visual Fields and Other Testing ^a
IV-14	2	Poor vision as infant, strong aversion to sunlight	{ OD=20/60 OS=20/100 }	{ OD=-10.00+0.50X105 OS=-10.50 sph }	Not done	Not done	Visual fields not done
IV-15	5	No visual complaints, anisometropic amblyopia OS	{ OD=20/32 OS=20/63 }	{ OD=+1.25+0.75X134 OS=-7.00+3.00X5 }	Not done	Not done	Visual fields not done
III-22, proband	9	Photophobic, sees better at night than during the day	{ OD=20/15 OS=20/15 }	{ OD=-5.00+0.25X175 OS=-5.25+0.25X119 }	HRR; D-15 normal	Suggestion of macular deficit	Goldmann: normal, EOG: OD=2.0, OS=1.87, ^b ERG consistent with rod dysfunction with normal cone responses
III-05	27	Difficulty with night driving, poor red/green discrimination, sensitive to light	{ OD=20/25 OS=20/40 }	{ OD=-14.25+0.75X125 OS=-15.75+1.25X80 }	Not done	Not done	Visual fields not done, ERGs done elsewhere (decreased photopic and scotopic amplitudes OU, cone flicker almost extinguished)
II-23	31	History of amblyopia, glasses since age 4 years, photophobia onset at age 10 years, decreased vision at age 18 years	{ OD=20/50+ OS=20/50+ }	{ OD=-12.25+2.75X170 OS=-10.00+2.25X170 }	HRR, plates 0/14 OU	Not done	Humphrey 30-2: shallow generalized depression OU, superior paracentral depression OS; ERG: normal rod function, abnormal flicker and photopic responses
III-04	35	Mild light sensitivity, poor color vision, difficulties with light and dark adaptation	{ OD=20/20 OS=20/20 }	{ OD=plano+0.25X180 OS=-1.2+0.37X30 }	Not done	Not done	Visual fields not done
II-19	37	Decrease in vision over last 5 years, photophobia, reportedly colorblind during military service at age 18 years	{ OD=20/30 OS=20/30 }	{ OD=-4.75+0.75X63 OS=-5.50+0.75X142 }	Grossly abnormal; no specific axis	Rod thresholds normal; cones not normal	Humphrey 30-2: peripheral elevation of thresholds, no discrete scotomas; ERG: cone > rod loss
II-10	42	Vision always < 20/25, deteriorated at age 25 years, not photophobic, poor light-to-dark adaptation	{ OD=20/200 OS=20/200 }	{ OD=-10.75+1.00X154 OS=-10.00+1.25X60 }	Lanthony abnormal; no specific axis	Not done	Goldmann: dense central scotomas; EOG: OD=1.66, OS=1.58, ^b ERG: cone response extinguished, rod function depressed
II-15	48	History of amblyopia OS, visual loss began at age 35 years, moderate light sensitivity	{ OD=CF-2' OS=CF-2' }	{ OD=-7.25+2.25X7 OS=-7.75+2.00X5 }	Not done	Not done	Both central and peripheral loss by confrontation fields; ERG: marked decreases in photopic and scotopic ERGs indicating rod and cone dysfunction
II-05	51	Passed pilot vision test at age 25 years, noted poor vision at age 35 years, photophobia progressive since age 46 years, no night-vision problems	{ OD=20/200 OS=5/200 }	{ OD=-4.00+2.25X05 OS=-3.50+1.00X04 }	HRR; D-15 failed; no axis	Cone thresholds not measurable	Goldmann: dense central scotomas OU; EOG: OD=1.67, OS=1.43, ^b ERG: minimal decrease in scotopic B-wave, markedly reduced photopic and flicker

^a EOG = electrooculogram.

^b EOG values are expressed in terms of the Arden ratios.

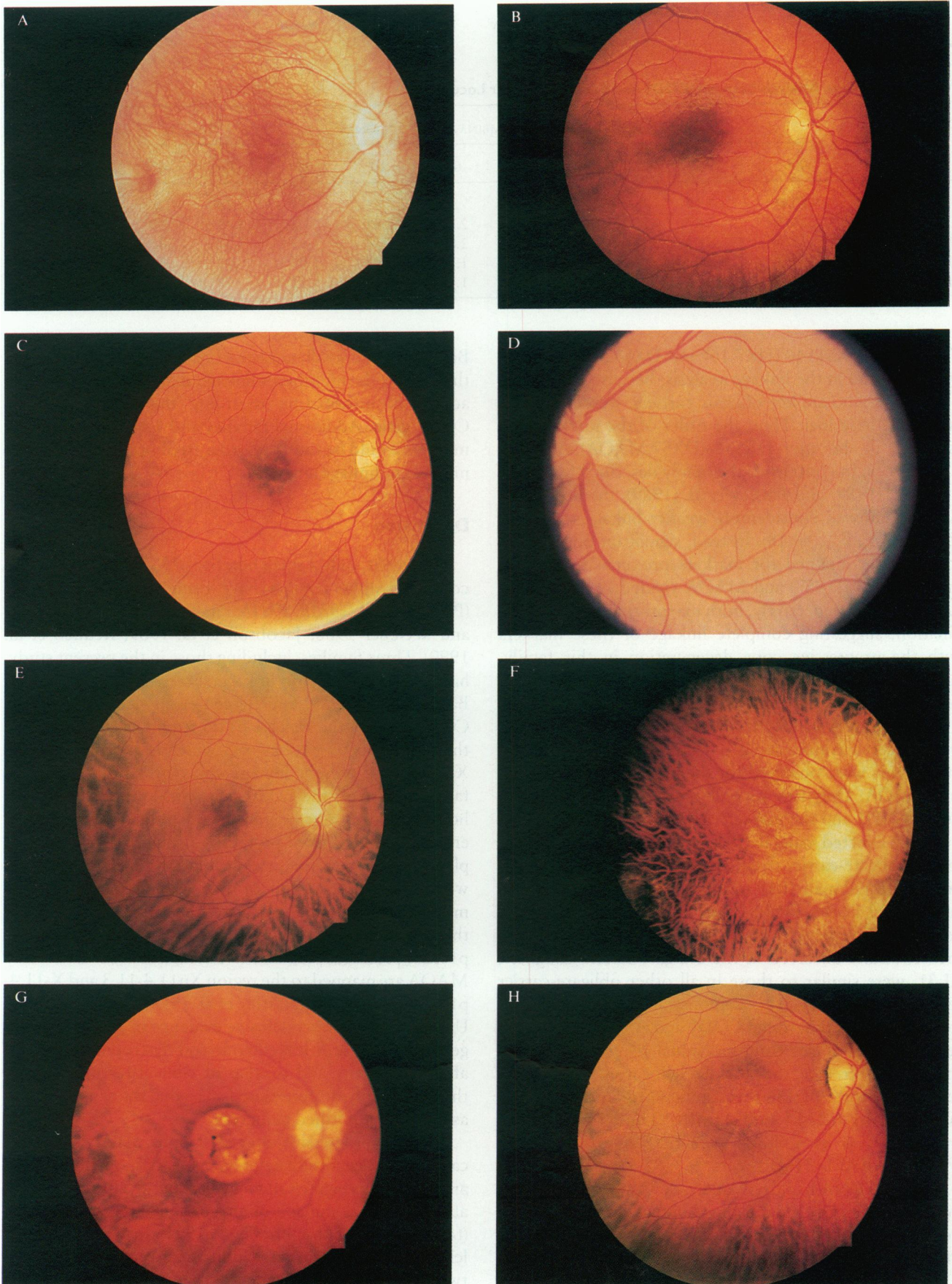


Figure 2 Fundus photographs of selected COD1-affected males. Because the appearances of the two retinas for a given individual are highly symmetrical, only the macula of a single eye is shown for each individual. A, IV-14, right eye. B, IV-15, right eye. C, III-22, right eye. D, II-23, left eye. E, II-19, right eye. F, II-15, right eye. G, II-10, right eye. H, II-05, right eye.

Table 3
Two-Point Linkage Analysis between COD1 and Each Xp Marker Locus

Locus	LOD SCORE AT RECOMBINATION FRACTION OF										θ_{\max}	Z_{\max}
	.000	.002	.005	.01	.05	.10	.20	.30	.40			
DXS84	-17.41	-2.38	-1.60	-1.01	.22	.61	.75	.50	.28	.18	.76	
DXS7	3.08	3.07	3.06	3.03	2.84	2.58	2.02	1.38	.66	.00	3.08	
MAOA	3.04	3.03	3.02	3.00	2.80	2.54	1.98	1.34	.62	.00	3.04	
ARAF1	-4.76	-.07	.32	.60	1.14	1.23	1.07	.73	.31	.10	1.23	
TIMP	-3.79	-.01	.37	.66	1.19	1.28	1.12	.78	.36	.10	1.28	

The probes DXS1146 (HK7.10) and DXS426 (XL91B10) were not used in the linkage analysis, because individuals I-2 and I-4, who are key obligate carriers, were not informative at these loci. Thus, the order of the markers was assumed to be pter-DXS84-(DXS7,MAOA)-ARAF1-TIMP1-cen. In contrast to the family described by Jacobson et al. (1989) and Bartley et al. (1989), the probe 754 (DXS84) showed considerably weaker linkage to COD1 ($Z_{\max} = 0.76$, $\theta_{\max} = .18$). Instead, significant positive lod scores were obtained for markers proximal to DXS84. Probes L1.28 (DXS7) and MAOA yielded Z_{\max} values of 3.08 and 3.04, respectively, both maximizing at .00 recombination, suggesting complete linkage of these markers with the progressive cone degeneration in this family. ARAF1 and TIMP yielded Z_{\max} values of 1.23 and 1.28, respectively, at $\theta_{\max} = .10$.

Two apparent crossovers between DXS84 and COD1 were detected in individuals III-4 and II-5 (fig. 3). No crossover events were observed for the markers L1.28 (DXS7) and MAOA. Only one recombination was detected between COD1 and the markers ARAF1 and TIMP, occurring in an affected male, II-19 (fig. 3). This allele was passed to the obligate-carrier daughter, III-31. While the recombinant affected male II-19 has allele 2 at the ARAF1 locus and allele 2 at the TIMP locus, all other affected males have allele 1 at the ARAF1 locus and allele 4 at the TIMP locus. Results observed in the obligate-carrier daughter, III-31, were similar to those in all other obligate-carrier female in the family. This demonstrates that recombination has occurred between COD1 and ARAF1 during the segregation of alleles from individual I-4 to her affected son II-19. Therefore, the most likely location for the gene responsible for COD1 in this family is proximal to DXS84 and distal to ARAF1 and TIMP1. Thus, the order of the markers is as follows: pter-DXS84-(COD1,DXS7,MAOA)-ARAF1-TIMP1-cen.

From the DNA haplotype analysis, we were also able to determine the carrier status of seven females, which could not be discerned on the basis of pedigree position. Three of seven females (II-18, III-1, and III-29) have inherited the haplotype associated with the COD1 in this family (fig. 1).

Because of the small number of recombinants observed in this family, the multipoint linkage analysis did not provide additional information regarding the location of the COD1 gene. Additional families and highly polymorphic markers would be useful in order to obtain an informative multipoint linkage analysis.

Discussion

At present, only a small number of X-linked progressive cone dystrophy families have been clinically described (Pinckers et al. 1981a, 1981b; Pinckers 1982; Heckenlively and Weleber 1986; Jacobson et al. 1989; Keunen et al. 1990). Three families, including those in the present study, have been studied for linkage. Prior linkage studies by Bartley et al. (1989) and Bergen et al. (1993) placed the COD1 locus in the Xp21.1-p11.3 region, closely linked to the DXS84 locus (probe 754), which is assigned to band Xp21.1. The present linkage study of a four-generation family also maps the COD1 gene within the same region; however, our results suggest the possibility of genetic heterogeneity in X-linked progressive cone dystrophy. Complete linkage with the marker loci DXS7 and MAOA, as well as the observation of two recombinants between marker DXS84 and the disease phenotype, suggests that the most likely location of COD1 is in the region Xp11.4-p11.23, proximal to DXS84. The marker loci DXS7 and MAOA are mapped to the region Xp11.4-11.3 and X-11.4-p11.23, respectively (Hartley et al. 1984; Levy et al. 1989). Until there is more conclusive evidence of genetic heterogeneity for these X-linked cone-rod dystrophies, the variable expressivity and overlap of clinical features require that this family be considered as having the same disorder as do other published pedigrees.

X-linked progressive cone dystrophy may fall into the category of genetically heterogeneous retinopathy. For example, retinitis pigmentosa may be inherited in an X-linked, an autosomal dominant, or an autosomal recessive manner (for review, see Humphries et al. 1992). In addition, nonallelic heterogeneity exists within these categories. At least two X-linked retinitis pigmentosa genes have been localized

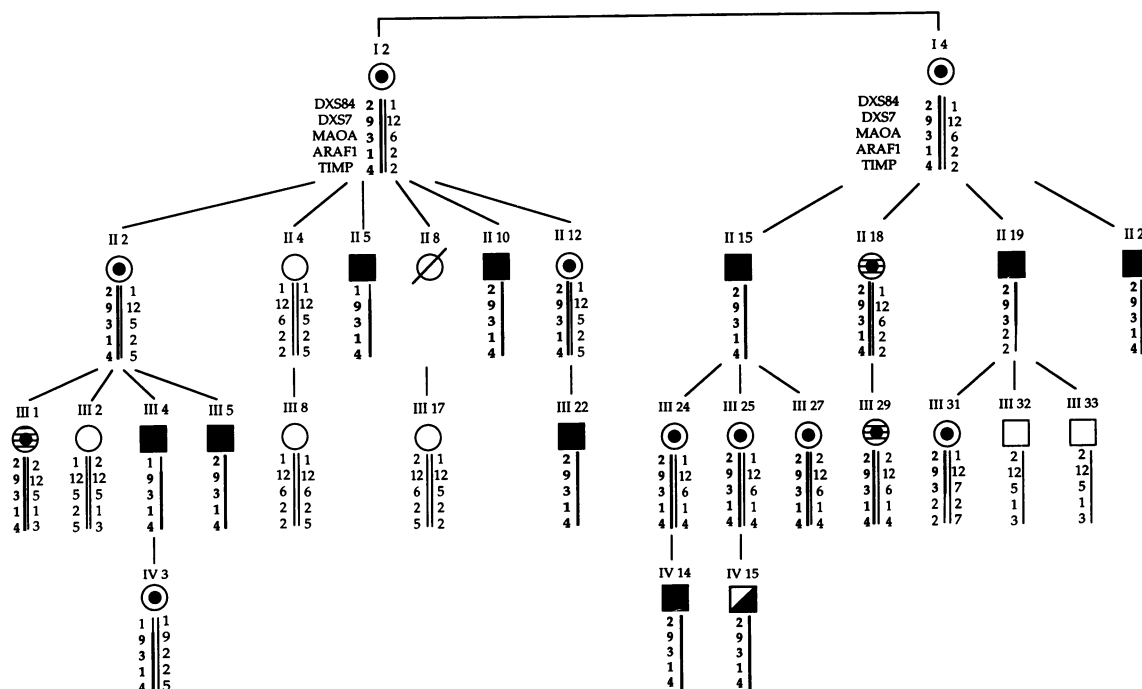


Figure 3 Analysis of inferred haplotypes for loci DXS84, DXS7, MAOA, ARAF1, and TIMP. Individual III-4 has a recombination between DXS84 and XS7, MAOA. His daughter, IV-3, has inherited the same recombinant chromosome. Individuals II-5 also has a recombination between DXS84 and DXS7, MAOA. Individual II-19 has a recombination between DXS7, MAOA and ARAF1, TIMP. Individual III-31 has inherited the same recombinant chromosome. Shown are affected males (■), males found to be affected on the basis of the molecular study alone (▤), unaffected males (□), obligate-carrier female (⊙), females whose carrier status was determined by DNA analysis (⊕), and normal females (○).

to Xp. Retinitis pigmentosa type 2 (locus RP2) is localized to Xp11.4-11.2, and retinitis pigmentosa type 3 (locus RP3) is localized to Xp21.1-11.4 (for review, see Humphries et al. 1992). A recent collaborative linkage analysis by Ott et al. (1990) estimated RP2 to be halfway between the marker loci DXS14 and Xcent, with the distal end spanning the interval DXS7 and OALT1. RP3 was located 1 cM distal to OTC in region Xp21.1. Neither gene has yet been characterized. Extreme phenotypic heterogeneity associated with mutations in a single gene is well documented in ophthalmic genetics. For example, mutations in the gene coding for the photoreceptor-specific glycoprotein peripherin (RDS) can cause autosomal dominant retinitis pigmentosa (for review, see Humphries et al. 1992), butterfly-pattern macular dystrophy (Nichols et al. 1993), a phenotype that has been compared to retinitis punctata albescens (Kajiwara et al. 1993), and adult-onset vitelliform macular dystrophy (Wells et al. 1993). That different mutations in the RDS gene can give rise to such radically different phenotypes suggests the possibility that mutations in the same gene(s) may be responsible for both X-linked retinitis pigmentosa and X-linked progressive cone dystrophy phenotypes. Previous linkage study of a large X-linked cone dystrophy family (Bartley et al. 1989) placed the COD1 gene near the RP3

locus. The probe 754 (DXS84), which maps in the region Xp21.1, was shown to closely segregate with X-linked progressive cone dystrophy in the family described by Bartley et al. (1989), as well as in some of the X-linked retinitis pigmentosa families (Nussbaum et al. 1985; Denton et al. 1988; Musarella et al. 1988; Wirth et al. 1988). The present linkage report maps the COD1 locus to region Xp11.3, where RP2 is assigned. The X-linked progressive cone dystrophy in this family is closely linked to the DSX7 locus, detected by the probe L1.28. Similarly, the RP2 locus was detected by the DNA probe L1.28 (DXS7), by several investigators (Bhattacharya et al. 1984; Mukai et al. 1985; Friedrich et al. 1985; Wright et al. 1987). Therefore, the linkage studies of two independent families with X-linked progressive cone degeneration place the COD1 locus in the region Xp21.1-p11.3, which overlaps the loci for both types of X-linked retinitis pigmentosa, RP2 and RP3. Other hereditary retinal disorders—such as X-linked congenital stationary night blindness and Åland Island eye disease—that have also been mapped to this region of the X-chromosome could involve mutations in the same gene that is responsible for COD1, despite the fact that these are stationary rather than progressive disorders.

Given similarities, in linkage reports, of both the reti-

nopathies, one could speculate that different mutations may give rise to the progressive degeneration that primarily affects the cones—as compared with the retinitis pigmentosa phenotype, where rod degeneration predominates. Our proband exhibited some symptoms that are consistent with cone dysfunction, e.g., photophobia. In the family studied by Jacobson et al., photopic ERG was ≥ 2 SDs below normal for all affected males; and scotopic responses were abnormal to a lesser extent. In the family described by Keunen et al., patient 6, who was 35 years of age, demonstrated severely reduced responses to both cones and rods, while several older subjects had much milder ERG changes. Several of the affected males in the family described by Heckenlively and Weleber (1986) demonstrated mild to moderate rod dysfunction, but all of these individuals also had significant cone dysfunction. Perhaps the most striking feature from the analyses of these families is the variability of rod and cone dysfunction, irrespective of age or pedigree. Others have assumed that the rod disturbance in the affected COD1 males is secondary to extensive cone degeneration, but this is unproved. It is certainly plausible that the rod dysfunction is directly the result of the mutations and gene responsible for COD1. Thus our proband can be considered an extreme case of dissociation of rod and cone dysfunction—but one that is not inconsistent with other examples of retinal degenerations for which specific mutations have given rise to widely varying phenotypes within a family. In every COD-1-affected individual whom we examined, there was evidence of rod dysfunction, as well as a progressive cone defect. It is possible that the effect on the rod photoreceptors is secondary to the primary cone degeneration; however, the ERG in the proband suggests that in this young individual the rods can be more severely affected than are the cones, early in the course of the degeneration. This would suggest that both the rods and cones are vulnerable to the COD-1 mutation, but to differing degrees. This would be analogous to some mutations in peripherin, which cause a retinal degeneration primarily affecting the rod photoreceptors (e.g., in the case of retinitis pigmentosa) or the central visual areas (e.g., in the case of butterfly-pattern macular dystrophy).

In summary, X-linked progressive cone degeneration and X-linked retinitis pigmentosa could be another example of nonallelic as well as allelic genetic heterogeneity of retinal degeneration. Nevertheless, further linkage study of additional COD1 families is necessary to establish whether there is more than one locus responsible for X-linked progressive cone degeneration. In addition, identification and characterization of genes responsible for X-linked progressive cone degeneration and X-linked retinitis pigmentosa will resolve the issues of allelic genetic heterogeneity.

Acknowledgments

The family was identified and characterized when M.B.G. was a medical officer at the National Eye Institute. These studies were

supported by grants from the Pennsylvania Lions Eye Conservation and Eye Research Foundation and Research to Prevent Blindness, Inc.

References

- Aldred MA, Wright AF (1991) PCR detection of existing and new polymorphism at the TIMP locus. *Nucleic Acids Res* 19: 1165
- Bartley J, Gies C, Jacobson D (1989) Cone dystrophy (X-linked) (COD1) maps between DXS7 (L1.28) and DXS206 (Xj1.1) and is linked to DXS84 (754). *Cytogenet Cell Genet* 51:959
- Bergen AAB, Meire F, ten Brink J, Schuurman EJM, van Ommen GB, Delleman JW (1993) Additional evidence for a gene locus for progressive cone dystrophy with late rod involvement in Xp21.1-p11.3. *Genomics* 18:463-464
- Bhattacharya SS, Wright AF, Clayton JF, Price WH, Phillips CI, McKeown CME, Jay M, et al (1984) Close genetic linkage between X-linked retinitis pigmentosa and a restriction fragment length polymorphism identified by recombinant DNA probe L1.28. *Nature* 309:253-255
- Coleman M, Bhattacharya S, Lindsay S, Wright A, Jay M, Litt M, Craig I, et al (1990) Localization of the microsatellite probe DXS426 between DXS7 and DXS255 on Xp and linkage to X-linked retinitis pigmentosa. *Am J Hum Genet* 47:935-940
- Denton MJ, Chen JD, Serravalle S, Colley P, Halliday FB, Donald J (1988) Analysis of linkage relationships of X-linked retinitis pigmentosa with the following Xp loci: L1.28, OTC, XJ-1.1, pERT87, and C7. *Hum Genet* 78:60-64
- Feinberg AP, Vogelstein B (1983) A technique for radiolabeling DNA restriction endonuclease fragments to high specific activity. *Anal Biochem* 132:6-13
- Friedrick U, Warburg M, Wieacker P, Wienker TF, Gal A, Ropers HH (1985) X-linked retinitis pigmentosa: linkage with the centromere and a cloned DNA sequence from the proximal short arm of the X chromosome. *Hum Genet* 71:93-99
- Goodfellow PN, Davies KE, Ropers HH (1985) Report of the committee on genetic constitution of the X and Y chromosomes. 8th International Workshop in Human Gene Mapping. *Cytogenet Cell Genet* 40:296-352
- Hartley DA, Davies KE, Drayna D, White RL, Williamson R (1984) A cytological map of the human X chromosome—evidence for non-random recombination. *Nucleic Acids Res* 12: 5277-5285
- Heckenlively JR, Weleber RG (1986) X-linked recessive cone dystrophy with tapetal-like sheen: a newly recognized entity with Mizuo-Nakamura phenomenon. *Arch Ophthalmol* 104: 1322-1328
- Hong HK, Giordo R, Trucco M, Chakravarti A (1993) Dinucleotide repeat polymorphism at DXS1146 locus. *Hum Mol Genet* 2:1078
- Humphries P, Kenna P, Farrar J (1992) On the molecular genetics of retinitis pigmentosa. *Science* 256:804-808
- International Standardization Committee (1989) Standard for clinical electroretinography. *Arch Ophthalmol* 107:816-819
- Jacobson DM, Thompson ST, Bartley JA (1989) X-linked progressive cone dystrophy: clinical characteristics of affected males and female carriers. *Ophthalmology* 96:885-895

- Kajiwara K, Sandberg MA, Berson EL, Dryja TP (1993) A null mutation in the human peripherin/RDS gene in a family with autosomal dominant retinitis punctata albescens. *Nature Genet* 3:208–212
- Keunen JEE, van Everdignen JAM, Went LN, Oosterhuis JA, van Norren D (1990) Color matching and foveal densitometry in patients and carriers of an X-linked progressive cone dystrophy. *Arch Ophthalmol* 108:1713–1719
- Kirchgesner CU, Trofatter JA, Mahtani MM, Willard HF, DeGennaro LJ (1991) A highly polymorphic dinucleotide repeat on the proximal short arm of the human X chromosome: linkage mapping of the synapsin I/A-raf-1 genes. *Am J Hum Genet* 49:184–191
- Lathrop GM, Lalouel JM, Julier C, Ott J (1985) Multilocus linkage analysis in humans: detection of linkage and estimation of recombination. *Am J Hum Genet* 37:482–498
- Levy ER, Powell JF, Buckle VJ, Hsu YP, Breakefield XO, Craig IW (1989) Localization of human monoamine oxidase-A gene to Xp11.23-11.4 by *in situ* hybridization: implications for Norrie disease. *Genomics* 5:368–370
- Luty JA, Willard HF, Litt M (1989) Three new microsatellite VNTRs on the X chromosome. *Cytogenet Cell Genet* 51:1036
- McKusick VA (ed) (1992) Mendelian inheritance in man, 10th ed. Johns Hopkins University Press, Baltimore, pp 1807–1808
- Miller SA, Dykes DD, Polesky HF (1988) A simple salting out procedure for extracting DNA from human nucleated cells. *Nucleic Acids Res* 16:1215
- Mukai S, Dryja TP, Bruns GA, Aldridge JF, Berson EL (1985) Linkage between the X-linked retinitis pigmentosa locus and the L1.28 locus. *Am J Ophthalmol* 100:225–229
- Musarella MA, Burghes A, Anson-Cartwright L, Mahtani MM, Argonza R, Tsui L-C, Worton R (1988) Localization of the gene for X-linked recessive type of retinitis pigmentosa (XLRP) to Xp21 by linkage analysis. *Am J Hum Genet* 43:484–494
- Nichols BE, Sheffield VC, Vandenburg K, Drack AV, Kimur AE, Stone EM (1993) Butterfly-shaped pigment dystrophy of the fovea caused by a point mutation in codon 167 of the RDS gene. *Nature Genet* 3:202–207
- Nussbaum RL, Lewis RA, Lesko JG, Ferrell R (1985) Mapping ophthalmological disease. II. Linkage of relationship of X-linked retinitis pigmentosa to X chromosome short arm markers. *Hum Genet* 70:45–50
- Ott J, Bhattacharya S, Chen JD, Denton MJ, Donald J, Dubay C, Farrar GJ, et al (1990) Localizing multiple X chromosome-linked retinitis pigmentosa loci using multilocus homogeneity tests. *Proc Natl Acad Sci USA* 87:701–704
- Pinckers A (1982) X-linked progressive cone dystrophy. *Doc Ophthalmol Proc Ser* 33:399–403
- Pinckers A, Groothuizen GGC, Timmerman GJMEN, Deutman AF (1981a) Sex-difference in progressive cone dystrophy. II. *Ophthalmic Paediatr Genet* 1:25–36
- Pinckers A, Timmerman GJMEN (1981b) Sex-difference in progressive cone dystrophy. I. *Ophthalmic Paediatr Genet* 1:17–23
- Southern EM (1975) Detection of specific sequences among DNA fragments separated by gel electrophoresis. *J Mol Biol* 98:503–517
- Wells J, Wroblewski J, Keen J, Inglehearn C, Jubb C, Eckstein A, Jay M, et al (1993) Mutations in the human retinal degeneration slow (RDS) gene can cause either retinitis pigmentosa or macular dystrophy. *Nature Genet* 3:213–218
- Wirth B, Denton M, Chen JD, Neugebauer M, Halliday F, Schooneveld M, Donald J, et al (1988) Two different genes for X-linked retinitis pigmentosa. *Genomics* 2:263–266
- Wright AF, Bhattacharya SS, Clayton JF, Dempster M, Tippett P, McKeown CME, Jay M, et al (1987) Linkage relationships between X-linked retinitis pigmentosa and nine short-arm markers: exclusion of the disease locus from Xp21 and localization to between DXS7 and DXS14. *Am J Hum Genet* 41:635–644