

FIG. 1.—Male pseudohermaphroditism, showing external female appearance.

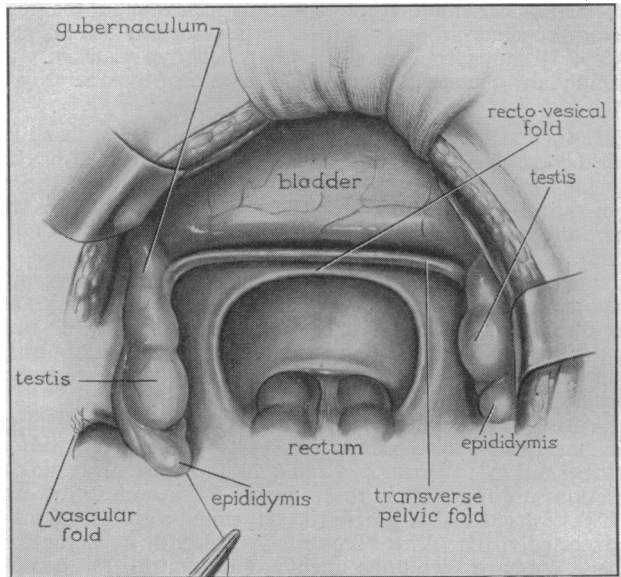


FIG. 2.—Drawing illustrating appearance of pelvis at laparotomy showing internal male gonads and absence of female organs.

D. P. Hammersley

Histology.—Material from each gonad was identical histologically, and consisted of testicular tissue. There were numerous immature seminiferous tubules which showed no evidence of spermatogenesis. Numerous and increased numbers of interstitial cells were present.

The legal determining factor in intersex cases is the anatomical structure of the gonad independent of the social or sexual inclinations or external appearance of the subject. In this case, therefore, the legal sex is male, and although one would have no hesitation in defending this patient's desire to continue living as a female, the clinical problem does arise as to how far a surgeon is justified in carrying out a plastic operation to make a vagina which, in this case, has already been requested.

Vitamin-D Resistant Osteomalacia Associated with Neurofibromatosis.—B. E. C. NORDIN, M.D., and RUSSELL FRASER, M.D., F.R.C.P.

The patient was a 33-year-old woman who was first seen in June 1952, when she complained of generalized bone pains. She had developed kyphoscoliosis in infancy, which had been progressing ever since, had had rickets as a child, and had been excessively liable to fractures since the age of 20. However, she had been ambulant and fit for light work until about two years before the present admission but had been bedridden for the last nine months, mainly on account of bone pain. Her father and a brother (both dead) had had kyphotic deformities, and her mother had had multiple neurofibromatosis.

The patient weighed just under 4 stone and was 4 ft. in height. She had a very severe dorsal kyphoscoliosis with angulation in the midthoracic region, and a false joint with right angle deformity of the right forearm. There were multiple neurofibromata on the trunk, face and limbs.

Radiography revealed thin bones, a tri-radiate pelvis and typical Milkman fractures in the scapulae and the right femur, and fractures in the left clavicle, the right second metacarpal, the right ulna and elsewhere (Fig. 1). The only metabolic abnormality was a low blood phosphate (1.5 mg.%) associated with a relatively high urinary phosphate excretion (nearly 500 mg./24 hours). During the first five days in hospital she rejected all her food and her blood phosphate fell to zero.

Investigation did not reveal the cause of her osteomalacia. Steatorrhoea was excluded by a normal fat balance; Fanconi's syndrome by the absence of abnormal amino-acids and glucose in the urine; renal tubular acidosis by her ability to excrete a highly acid urine (pH 4.5–5.0) containing 50 mEq. ammonia in twenty-four hours after three days on an acid load of 100 mEq. daily. She therefore fell into the category of vitamin-D resistant osteomalacia, and, as expected, her clinical condition and X-ray appearances (Fig. 2) responded slowly but unmistakably to large doses of vitamin-D (50,000 units daily, later raised to 250,000). There was also a rise in blood calcium and phosphate until the former was above and the latter within the normal range (Fig. 3).

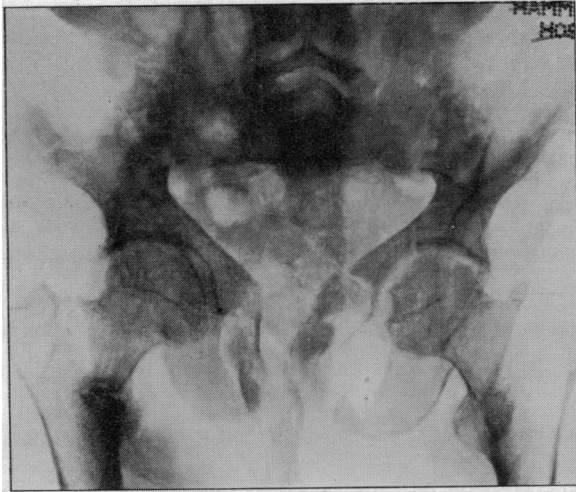

FIG. 1.—X-ray on admission showing tri-radiate pelvis, Milkman fractures of right femur and right ilium and fractures in the pubic rami.

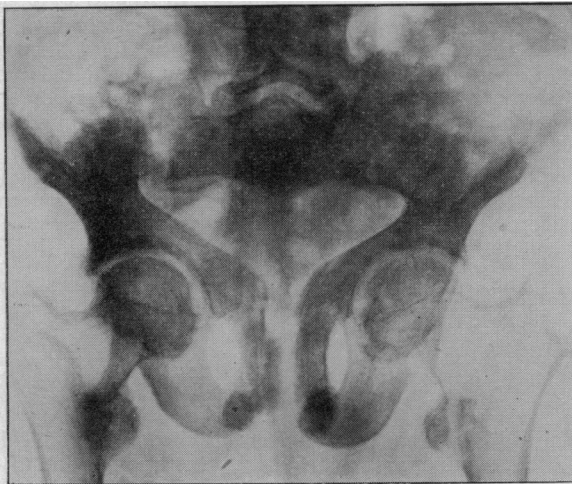


FIG. 2.—X-ray after three months of vitamin-D therapy showing callus formation at site of fractures.

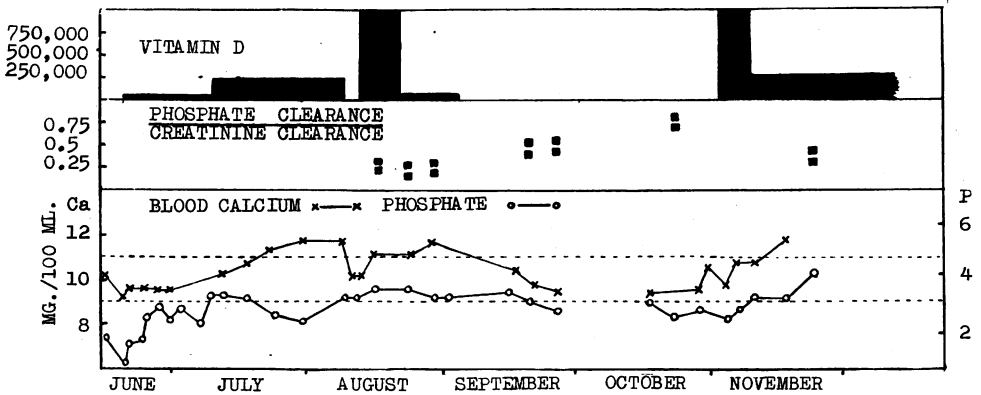


FIG. 3.—Shows the steady rise in blood phosphate and calcium in response to vitamin-D and the fall in both when vitamin-D is withdrawn. Note also the rise in phosphate clearance : creatinine clearance ratio after withdrawal of vitamin-D.

Comment.—The main interest in this case attaches to the ætiology of the condition. The family history is suggestive of a hereditary factor and the lesion is clearly a congenital one. The primary defect in "vitamin-D resistance" is still unknown, and the only hypothesis which has been put forward is that of Fanconi and Girardet (1952) and Dent (1952) that there is a primary renal phosphatic leak; Fanconi has coined the term Phosphate Diabetes to describe the condition. On the other hand Albright and Reifenstein (1948) believe that the low blood phosphate and high phosphate clearance may be due to secondary hyperparathyroidism.

Whatever the cause of the phosphate leak in our patient, it certainly responded to vitamin D. The phosphate : creatinine clearance ratio was just within normal limits (0.2–0.3) after three months' therapy, and rose to 0.75–0.85 when vitamin D was withheld for six weeks. The severity of the leak can also be gauged from the fact that the blood phosphate fell to zero after five days' starvation.

REFERENCES

- ALBRIGHT, F., and REIFENSTEIN, E. C. (1948) *The Parathyroid Glands and Metabolic Bone Disease*. London.
 DENT, C. E. (1952) *J. Bone. Jt. Surg.*, **34B**, 266.
 FANCONI, G., and GIRARDET, P. (1952) *Helv. paediat. acta*, **7**, 14.

Cushing's Syndrome Due to Adrenal Cortical Tumour.—J. M. STOWERS, M.R.C.P. (for Professor M. L. ROSENHEIM, F.R.C.P.).

Miss B. W., aged 34, had been very healthy until February 1951, when she developed amenorrhœa and personality changes with impairment of her memory and general indifference. These changes she ascribed to an unusually early menopause and she did not consult a doctor. In August 1951, her voice became husky and deeper in pitch and she gained 14 lb. in weight in six months. The increase in weight was distributed over the trunk, neck, shoulders and face, sparing the limbs. After Christmas 1951 there was a more rapid development of symptoms. Coarse dark hairs grew on the face and a finer growth appeared on the limbs and abdomen. The scalp hair became thick and greasy and acne developed on the face and chest. Shortly before coming to University College Hospital her periods had returned and she thought her physical strength was increasing.

On examination.—Characteristic appearance of Cushing's syndrome with buffalo obesity, round, red, hairy face, relatively thin limbs and purplish striae over the flanks. B.P. 140/100. All systems normal, but Professor W. C. W. Nixon considered there was some enlargement of the clitoris.

Blood count normal. Low total eosinophil counts. Plasma cholesterol 150 mg./100 ml.

Androgens: Neutral 17-ketosteroid excretion:

1952: March	60 mg./day	
April 4	104	less than 10% β fraction.
11	54	35% β Patterson test positive.
23	66	18% β

Dr. H. Pond (King's College Hospital) analysed the urinary 17-ketosteroids chromatographically on an alumina column: there was (1) a high total, (2) a large proportion of the β fraction and (3) a normal androsterone : etiocholanolone ratio.

Carbohydrate metabolism: Occasional slight glycosuria associated with a normal blood sugar. Oral and intravenous glucose tolerance tests normal.

Urinary 11-oxysteroid excretion (April 16) 0.66 mg./day (normal 0.15 to 0.4) (modified Talbot method).

Mr. I. E. Bush analysed the urinary 11-oxysteroids chromatographically. There was a considerably increased output especially of the fraction measured after immediate acid hydrolysis.

Electrolytes: Serum chlorides 93 and 100, sodium 133 and 143, potassium 3.6 and 4.2; mEq./l. plasma CO₂ combining power 28 mEq./l. Serum Ca 8.8 mg./100 ml. Sulkowitch test on urine strongly positive.

Radiology: Skull normal. I.V.P.: Good concentration of the dye. The left kidney appeared to be depressed and rotated by a mass lying on its superomedial aspect. Chest normal. Long bones and spine: no evidence of decalcification. Abdomen: large rounded abnormal shadow under the left diaphragm.

Soft tissue pneumatography (Dr. C. J. Hodson): large discrete round mass lying in the left paravertebral gutter.

There was good evidence for the existence of a large tumour, probably malignant (17-ketosteroid results), of the left adrenal gland. The tumour appeared to be secreting androgens, glucocorticoids and possibly some mineralo-corticoids.

Operation (Mr. W. R. Merrington) 25.4.52: The patient was prepared with pre- and post-operative ACTH and cortisone and supplementary potassium chloride by mouth. A metabolic balance study