

- LEJEUNE, F., and WUSTROW, P. (1920) *Dtsch. Mschr. Zahnheilk.*, **38**, 15. Cited by Kronfeld.
- MILLER, W. D. (1901) *Dent. Cosmos*, **43**, 845.
- MONTAGUE, M. F. A. (1940) *Hum. Biol.*, **12**, 323.
- MUNRO, D. (1952) *Brit. dent. J.*, **92**, 92.
- RABINOWITCH, B. Z. (1949) *Oral Surg.*, **2**, 1480.
- RUSHTON, M. (1936) *Dent. Rec.*, **56**, 766.
- (1937) *Brit. dent. J.*, **63**, 65.
- SALTER, S. J. A. (1874) *Dental Surgery and Pathology*. London.
- SEARCY, W. M., Jr. (1948) *Dent. Radiogr.*, **21**, 29.
- "SOCRATES" (1856-1857) *Dent. Reg.*, **10**, 355. Cited by Kitchin.
- SPRAWSON, E. (1937) *Brit. dent. J.*, **71**, 177.
- SWANSON, W. F., and MCCARTHY, F. M., Jr. (1947) *J. dent. Res.*, **26**, 167.
- TAYLOR, R. (1951) *N.Z. dent. J.*, **47**, 92.
- TOMES, J. (1859) *A System of Dental Surgery*. London; pp. 227-228.
- TOWNEND, B. R. (1949) *Brit. dent. J.*, **87**, 216.
- TRATMAN, E. K. (1951) *Brit. dent. J.*, **91**, 167.

*Acknowledgments.*—My thanks are due to the photographic department of the Newcastle upon Tyne Dental Hospital for the clinical photographs. I am also indebted to Mr. A. E. Robinson, F.D.S.R.C.S., Senior Dental Officer, Northumberland Co. Council, for facilities for examining pupils at the Grammar School.

## The Diagnosis, Clinical Significance and Treatment of Minor Palatal Invaginations in Maxillary Incisors

By RICHARD R. STEPHENS, B.D.S., M.R.C.S., L.R.C.P.

*Department of Children's Dentistry, Institute of Dental Surgery, Eastman Dental Hospital*

IF, as will be shown, the pulp of a maxillary incisor tooth with a palatal invagination is liable to suffer spontaneous death, it is valuable for the dental surgeon to be able to suspect from the appearance of the crown of an incisor tooth that such an invagination is present.

### DIAGNOSIS

It would appear that only those teeth with the deepest cingulum pits are likely to be affected. Extracted upper lateral incisor teeth were taken at random and divided by crown morphology into three groups according to the depth of cingulum pit. The first group of teeth had no trace of cingulum pit whatsoever, the palatal surface being flat and smooth. The second group comprised those with the usual degree of palatal configuration and pit development, while in the third were placed those teeth only with very deep cingulum pits. Radiographs were then taken of these groups of teeth and it was found that the presence of invaginations was confined to those teeth in the deep pit group.

Therefore, although the presence of a very deep cingulum pit does not necessarily mean that an invagination is present, a tooth without such a pit is unlikely to be affected.

Unless caries has commenced in the deep pits of affected teeth, the point of a sharp probe will not necessarily stick in them although it may be trapped by the surrounding enamel walls.

The condition may be detected radiographically prior to the eruption of the tooth and in the majority of cases root formation continues to completion, eruption is unaffected and the response of the tooth to vitality tests in adult life is normal.

Invaginations appear to be more common in maxillary incisors in association with an abnormal crown form or with the presence of other developmental abnormalities of the dentition. Lateral incisors having a marked fossa on the mesial aspect and absence of the distal incisal angle frequently appear to be affected. In 2 patients invaginations in maxillary lateral incisors were associated with over-development of the cingulum cusps. Supernumerary teeth in the mid-line of the maxillæ were found in 5 out of 20 cases which showed palatal invaginations (as in Fig. 7 of Professor Hallett's paper). Another example of association with other developmental abnormalities of the dentition was a case showing bilateral invaginations in maxillary lateral incisors, with several premolars absent and the lower incisors represented by diminutive conical teeth.

There is thus an indication to take radiographs of upper lateral incisors in children when the crowns show very deep pits or some abnormal morphology and especially if, in addition, the dentition is affected by other developmental abnormalities such as supernumerary teeth or partial anodontia.

In relation to the diagnosis of this condition the following figures on incidence in patients at the Eastman Dental Hospital may be of value. Out of a series of routine full mouth radiographs on 150 patients with both upper lateral incisors present, 3 patients had bilateral invaginations in lateral incisors and 9 patients had unilateral invaginations. Thus 15 teeth were affected out of 300, an incidence of 5% of upper lateral incisors. Intra-oral radiographs taken of the upper lateral incisors in 1,000 patients were examined. Of these, invaginations were present in 36 teeth, and of these teeth, the radiographs of 9 showed definite periapical changes resulting from pulp death.

CLINICAL EVIDENCE THAT INVAGINATIONS MAY RESULT IN SPONTANEOUS DEATH OF THE PULP

The question arises as to whether pulp death does indeed result from an invagination or whether pulp death in these teeth may have resulted from some trauma to the tooth severe enough to cause apical vessel disruption and yet easily able to be forgotten by the patient.

The following 4 cases all lend support to the contention that spontaneous pulp death may indeed occur. None of these patients gave any history whatsoever of trauma to the teeth concerned.

*Case I.*—A girl aged 14 was one of a group of some 200 children being studied to assess various factors in growth and development. As part of the investigation routine lateral jaw radiographs were taken on each child. When the radiographs of this girl were studied, areas of rarefaction were detected over the apices of the maxillary lateral incisor teeth (Fig. 1).

Intra-oral radiographs showed bilateral invaginations in the lateral incisors with large periapical areas of rarefaction and the typical appearance of cessation of root formation (Fig. 2).

On clinical examination there were no signs whatsoever of periapical involvement. The patient had never had any symptoms from these teeth and was unaware that anything was amiss.

It can only be concluded in this case that spontaneous death of the pulps of both teeth occurred soon after they erupted and that symptomless chronic apical abscesses slowly developed.

More commonly, however, the patient presents because of symptoms of an acute exacerbation of such a chronic apical abscess or because, without other symptoms, a sinus has developed.

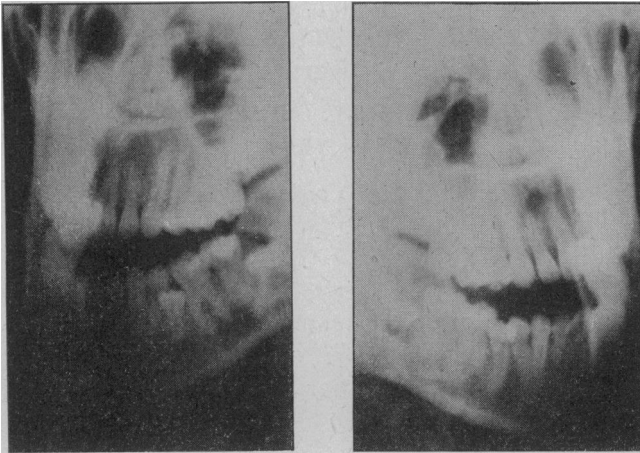


FIG. 1 (*Case I*).—Lateral jaw radiographs showing areas of rarefaction over both maxillary lateral incisors. (Radiograph kindly lent by Mr. G. J. Parfitt.)

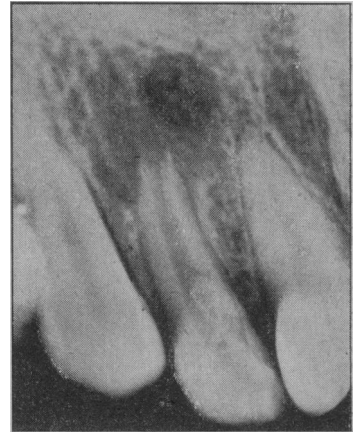

FIG. 2 (*Case I*).—Intra-oral radiograph showing the periapical condition of the invaginated right lateral incisor.

*Case II.*—A boy aged 15 presented with the symptoms of a subacute apical abscess on the upper right lateral incisor.

The radiograph showed a long-standing apical abscess (Fig. 3) and an apicectomy was performed. Six months later the patient again complained of acute symptoms, this time on the left lateral incisor. The radiograph (Fig. 4) showed such a similar appearance to the previous one of the right side that they were then more carefully studied. It was noticed that both teeth had invaginations and that an occlusal radiograph taken at the first attendance but not carefully studied, did in fact show symmetrical chronic apical abscesses (Fig. 5).

Again it can only be assumed that spontaneous pulp death of both teeth occurred soon after eruption.

The process of pulp necrosis, including the development of the periapical lesion, was in the case of each tooth entirely symptomless, the patient presenting only when each chronic apical abscess in turn became the subject of an acute exacerbation.

It was this case that stimulated this investigation into the possibility of minor invaginations being the cause of pulp death.

*Case III.*—A girl aged 16 presented with a sinus over the upper right central incisor. The palatal aspects of all upper incisors showed deep pits. Neither the upper right central nor left lateral incisor responded to vitality tests, whereas all the other incisors did.

Radiographs showed invaginations in these two teeth only, and a chronic apical abscess had developed in the right central incisor (Fig. 6).

If, therefore, a tooth other than a maxillary lateral incisor has an invagination its pulp may die. Pulp death does not result from any peculiar characteristic of the lateral incisor alone.

*Case IV.*—This is another case illustrating the same point. The patient, an adult male, had typical invaginations in his upper lateral incisors. However, in addition all eight premolars had invaginations extending from their occlusal surfaces. Of these premolars, the pulps of the lower left first and right second premolars had died apparently a spontaneous death with subsequent chronic apical abscess formation. There was no

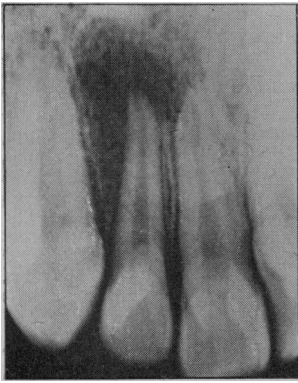


FIG. 3 (Case II).—Radiographic appearance of the right lateral incisor in a patient presenting with the symptoms of an acute apical abscess.

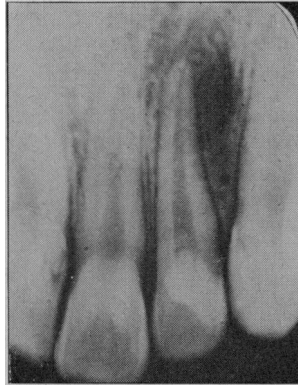

FIG. 4 (Case II).—Radiographic appearance of the left lateral incisor similar to that of FIG. 3. This was taken when the patient presented six months later, again with symptoms of an acute apical abscess.

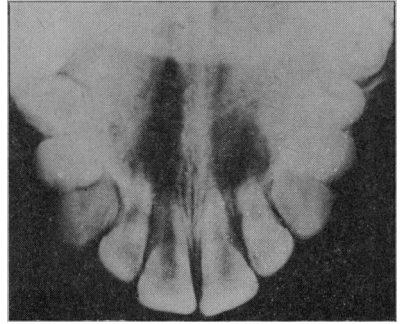


FIG. 5 (Case II).—Original occlusal radiograph showing bilateral areas of rarefaction of the same extent in association with both lateral incisors.

other explanation for the death of these pulps in this case. Fig. 7 shows an affected lower left first premolar. (The radiographs of this case were kindly lent by Mr. W. B. Palderston of University College Hospital Dental School.)

SEQUELÆ OF PULP IN INVAGINATED TEETH

It is usual for pulp death to occur before the root is fully formed and it is interesting to note that in the case of the upper lateral incisor the degree of root formation frequently corresponds with the normal stage of development of the root of this tooth as the crown erupts into the mouth.

Case V.—This illustrates well the usual time of cessation of root formation.

A girl aged 10 presented with an acute apical abscess associated with the upper right lateral incisor. There had been no history of trauma. The upper left lateral incisor reacted normally to vitality tests. Fig. 8 shows radiographs of both sides taken on the same occasion. Both teeth have invaginations. Root formation on the right side had ceased some time previously while on the left it has continued normally.

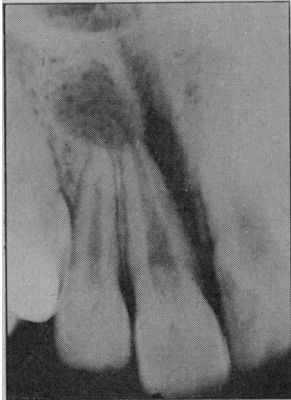


FIG. 6.

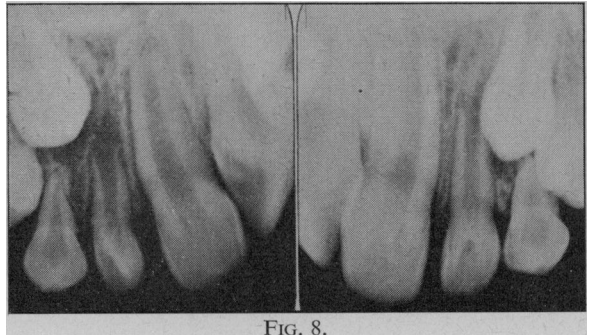


FIG. 8.

FIG. 6 (Case III).—The central rather than the lateral incisor has an invagination and a chronic apical abscess has developed.

FIG. 7 (Case IV).—Chronic apical abscess formation associated with a lower first premolar in patient with invaginations in all premolars in addition to maxillary lateral incisors.

FIG. 8 (Case V).—These intra-oral radiographs were taken on the same occasion. Root formation of the right lateral incisor has ceased following pulp death. That of the left lateral incisor has continued normally.

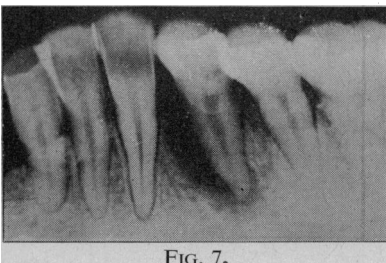


FIG. 7.

Pulp death and periapical lesions resulting from invaginations may often be quite insidious: The patient may not be aware that anything is amiss for many years until, for example, the symptoms of a dental cyst occur.

Routine radiographic examination of a girl of 13 revealed symptomless development of a small dental cyst over the period of three years four months as shown in Fig. 9.

*Case VII.*—An even more striking example of the insidious development of a periapical lesion resulting from an invagination is illustrated in Fig. 10.

The patient was a woman of 27 who presented with all the typical symptoms and signs of a large infected dental cyst associated with the upper left lateral incisor. The tooth can be seen to have a well-marked invagination and from the degree of root formation and size of pulp chamber and root canal it appears that the original pulp death occurred at about the age of 8 or 9.

A differential diagnosis must, therefore, be made between such radicular dental cysts and other cysts arising in this region such as the fissural and globulo-maxillary cysts.

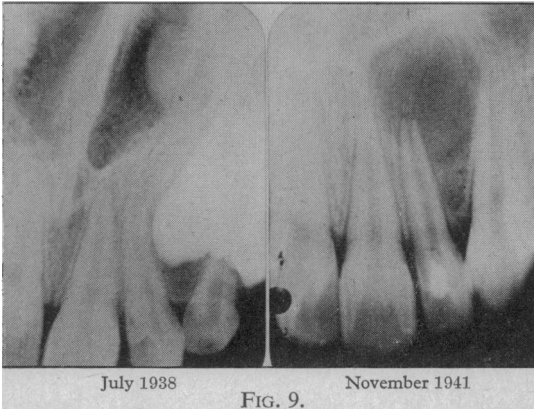


FIG. 9.

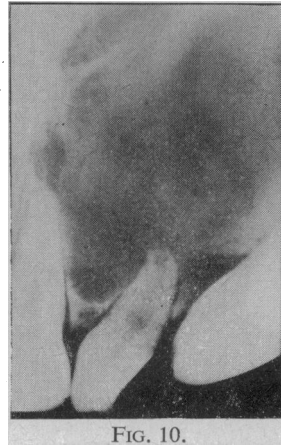

FIG. 10.

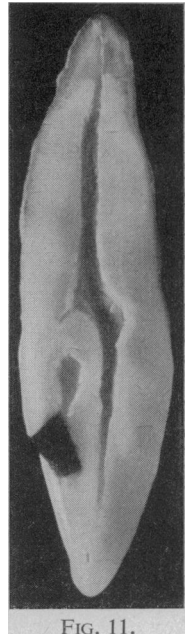

FIG. 11.

FIG. 9 (*Case VI*).—Development of a small dental cyst over a period of three years four months in association with a lateral incisor with an invagination. Root formation of the tooth is incomplete.

FIG. 10 (*Case VII*).—Large dental cyst in patient aged 27, resulting from pulp necrosis in an invaginated malformed tooth.

FIG. 11.—Longitudinal section of a maxillary lateral incisor showing the manner of cavity preparation and restoration to occlude the orifice of the invagination at the gingulum pit.

#### TREATMENT AND CLINICAL SIGNIFICANCE

An obvious prophylactic treatment to lessen the chances of pulpal necrosis is to close the orifice to the invagination as soon as it has passed the gingival margin during the course of eruption of the tooth. This may most easily be effected by preparing an undercut cavity in the gingulum pit to the thickness of palatal enamel only (Fig. 11). This may be filled with amalgam pressed on to soft oxyphosphate cement. Passage of the bur into the cavity of the invagination is to be avoided as the risk of pulp exposure is very great.

After restoration in this way the affected tooth should have periodical vitality checks and radiographic examination to observe continued root formation.

It is particularly important not to extract upper first premolar teeth for orthodontic reasons when the lateral incisors have invaginations until the condition of the pulps of the affected teeth has been assessed.

Another point of clinical significance is that if a patient presents for treatment of a chronic apical abscess or dental cyst associated with an upper lateral incisor and that tooth is seen to have an invagination, a radiograph should be taken of the other lateral incisor to exclude the possibility of a similar periapical condition.

#### SUMMARY

(1) The presence of invaginations in maxillary lateral incisor teeth may be suspected from the appearance of the palatal surface and possibly from the associations with other developmental abnormalities.

(2) There is clinical evidence to show that death of the pulp may be associated with non-carious invaginations.

(3) Pulp death may be followed by insidious development of a chronic apical abscess or dental cyst.

(4) Prophylactic treatment by occlusion of the invagination orifice at the cingulum pit is advised. The significance in relation to orthodontic treatment is noted.

#### CONCLUSIONS

It appears that spontaneous pulp death may occur in teeth with minor invaginations. This is often unnoticed by the patient. A chronic apical abscess or dental cyst may result and be discovered only on routine radiographic examination or because the patient presents with one of the various symptoms of such a periapical condition.

(38 clinical photographs and radiographs illustrated the original communication.)

## The Pathology of Pulp Death in Non-Carious Maxillary Incisors with Minor Palatal Invaginations

By IVOR R. H. KRAMER, L.D.S. R.C.S.

*Department of Dental Pathology, Institute of Dental Surgery, Eastman Dental Hospital*

A LARGE number of papers have been published describing histological studies on invaginated teeth, but the majority of these have been on the grosser forms of invagination usually referred to as dens in dente. Gustafson and Sundberg (1950) review 68 previous communications. As Hallett has shown in Table III the smaller and less readily recognized invaginations (Hallett's Classes II to IV) are quite common, and it is this type of abnormality that forms the subject of the present study. The investigation was started when it was pointed out (Stephens R. R., 1951, personal communication) that the majority of permanent upper lateral incisors that had suffered "spontaneous" pulp death (i.e. pulp death in the absence of caries or a history of trauma) showed the radiological appearances typical of minor degrees of invagination. The purpose of the investigation was to determine the relationship between these two associated observations.

#### METHOD

Although many previous workers chose the ground section technique for the preparation of their material, it was considered that paraffin sections of decalcified specimens had overwhelming advantages, for by this method soft tissues are preserved and serial sections can be obtained. The only definite advantage of the ground section technique is the preservation of the enamel, but it was felt that, even in decalcified material, it might be possible to determine the distribution of the enamel within the invagination as enamel matrix is often preserved during decalcification in such protected sites.

Following radiographic examination to determine the anatomical features of the abnormality, each specimen was decalcified and serial paraffin sections prepared. The specimens of upper lateral incisors with palatal invaginations were cut in the labio-palatal plane; that is, in the long axis of the tooth at right angles to the labial surface.

#### RESULTS

It was difficult to obtain a specimen of this type of abnormality prior to pulp death. However, in one instance such a specimen was obtained, extraction of the tooth being indicated because of gross root resorption in association with an unerupted canine. Fig. 1 shows a section of this specimen prepared as described. There is a palatal invagination of moderate size and a small cornu of the pulp extends for a short distance behind the invagination towards the palatal surface of the crown. The pulp shows no histological evidence of inflammation, the only abnormality being the presence of some calcified deposits near the base of the invagination. Such deposits were not found in other specimens.

The majority of specimens on section showed only necrotic tissue within the pulp space. However, it was noticed that there was evidence that abscess formation had preceded death of the pulp (Fig. 2). This observation was confirmed by the examination of further sections impregnated by the Gomori method for the demonstration of reticulin (Fig. 3). In such preparations the reticulin "scaffolding" of the pulp was clearly seen and close examination showed the typical appearance of an abscess wall in the region of the invagination. Although it has, so far, proved impossible to obtain a specimen with such a minor invagination in which an abscess has developed but death of the pulp has not supervened, further confirmation of the observation that abscess formation preceded pulp death was found following the examination of specimens showing more marked invaginations. Fig. 4 shows the pulp opposite an invagination extending towards the apex, and in this region an abscess has