

## Specific Infection and Destruction of Dopaminergic Neurons in the Substantia Nigra by Theiler's Virus

KEVIN R. OLIVER,<sup>1</sup> PETER BRENNAN,<sup>2</sup> AND JOHN K. FAZAKERLEY<sup>1\*</sup>

*Departments of Pathology<sup>1</sup> and Animal Behaviour (Zoology),<sup>2</sup>  
University of Cambridge, Cambridge, United Kingdom*

Received 7 February 1997/Accepted 8 May 1997

**Theiler's murine encephalomyelitis virus was stereotaxically inoculated unilaterally into the substantia nigra of the mouse brain. Virus specifically infected tyrosine hydroxylase-positive neurons and spread rostrocaudally throughout this subpopulation of neurons, resulting in impaired function and degeneration of the substantia nigra. The spread of the virus to other areas of the brain was minimal and rare.**

The common neurodegenerative disorders of humans, Alzheimer's disease and Parkinson's disease, are both associated with degeneration of specific neurotransmitter-containing neuronal populations. These diseases may be multifactorial, but viruses have often been suggested as their etiologic agents. In humans, parkinsonism has been shown to occur during the acute phase of encephalitis due to a number of viruses, including, measles, varicella, polio, and Japanese B encephalitis viruses (6, 11). The best-known encephalitis associated with parkinsonism was von Economo's disease or encephalitis lethargica, the basis of which remains unknown but is generally assumed to have been a virus infection. Most individuals affected with this disease showed evidence of basal ganglia involvement, and many survivors developed postencephalitic

parkinsonism (6, 27). More recently, dopamine deficits have been observed in AIDS patients (21). In this study, we have sought to determine in principle whether a virus can infect, replicate in, and affect a single neuronal subpopulation, in this case the dopaminergic neurons of the substantia nigra, without spreading to and damaging other neuronal populations.

Experimentally, changes in the dopamine system have been observed during encephalitis produced by Semliki Forest, vaccinia, herpes simplex, encephalomyocarditis, influenza, coxsackie B4, and Newcastle disease viruses (1, 3, 5, 10, 13–15, 17–20, 22). Studies on virus distribution and pathological changes in the central nervous system demonstrate that Theiler's virus and mouse hepatitis virus have a predilection for and can severely damage the substantia nigra (9, 12, 24, 25, 28).

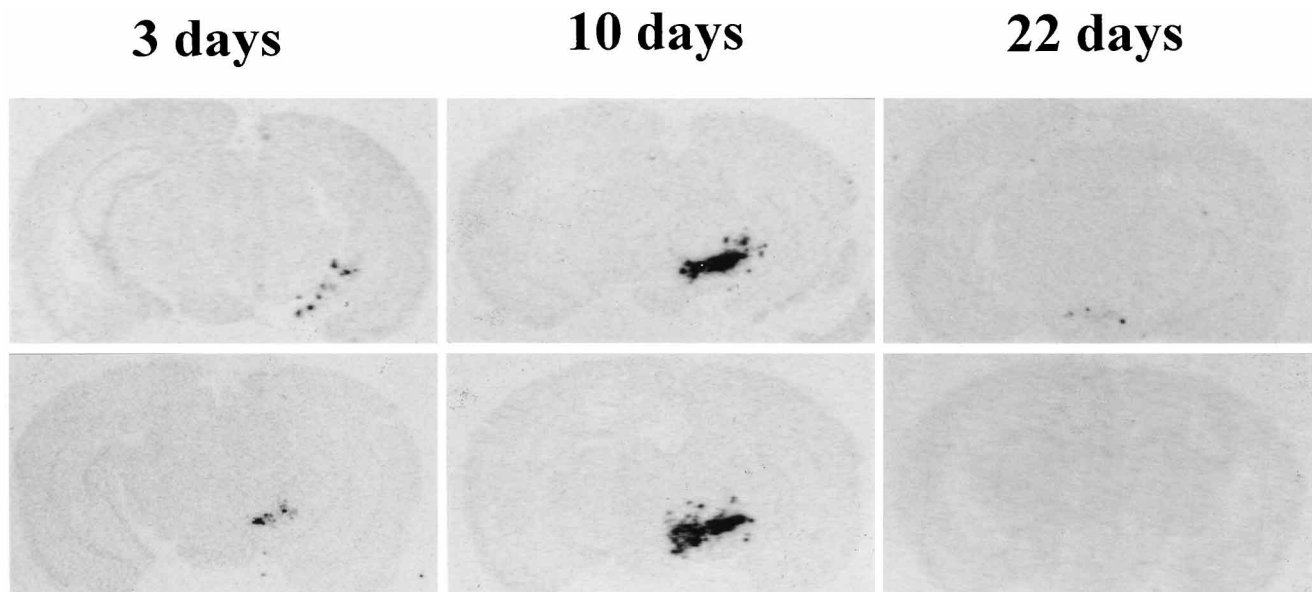


FIG. 1. Representative autoradiographic images showing the extents of infection in the substantiae nigrae of two mice each at 3, 10, and 22 days postinfection. Virus-positive areas are black and were detected by in situ hybridization using <sup>35</sup>S-labeled riboprobes. Initial unilateral foci of infection at 3 days postinoculation spread throughout the entire rostrocaudal length of the substantia nigra by 10 days postinfection. Note the confined foci of infection with little if any spread to adjacent structures. Little or no viral RNA was detected at 22 days postinfection.

\* Corresponding author. Present address: Department of Veterinary Pathology, University of Edinburgh, Summerhall, Edinburgh EH9 1QH, United Kingdom. Phone and fax: (44) 131 650 6160. E-mail: John.Fazakerley@ed.ac.uk.

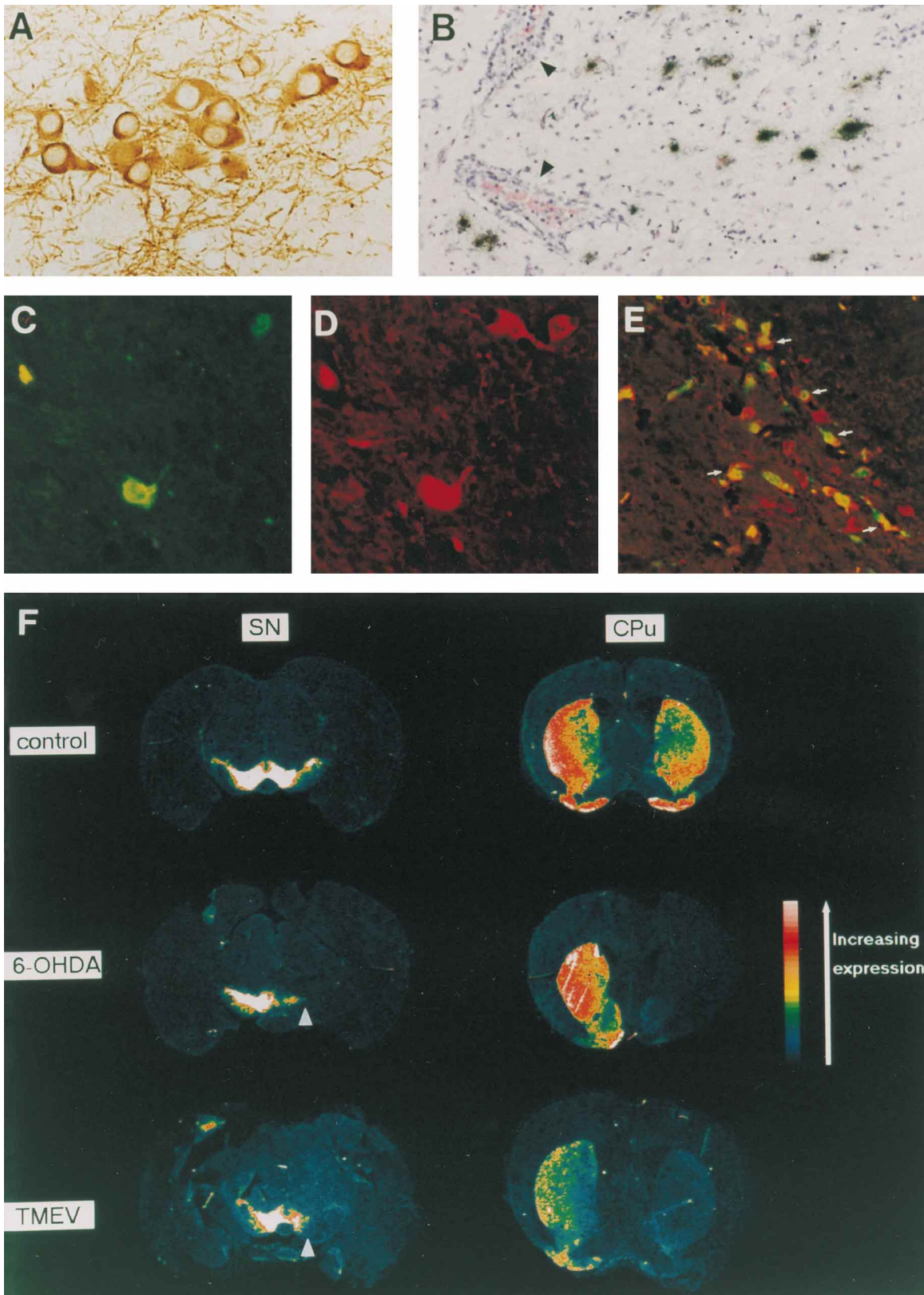


FIG. 2. (A) Example of immunostaining for tyrosine hydroxylase in the substantia nigra pars compacta. Magnification,  $\times 400$ . (B) Hematoxylin-and-eosin-stained section showing virus RNA-positive cells (silver grains) and the ensuing inflammatory response, including two blood vessels (arrowheads) surrounded by inflammatory mononuclear cells in the inoculated substantia nigra at 10 days postinfection. Magnification,  $\times 200$ . (C and D) Double fluorescence labeling for viral RNA and tyrosine hydroxylase at 10 days postinfection. (C) Viral RNA-positive cells detected with a digoxigenin-labeled riboprobe and visualized by green fluorescein staining. Magnification,  $\times 400$ . (D) Same field as in panel C, but tyrosine hydroxylase-positive neurons are immunostained red with rhodamine. Note that all virus-positive cells are tyrosine hydroxylase positive. (E) Lower-power double-exposure micrograph showing extensive double labeling in the substantia nigra pars compacta at 10 days postinfection. Note that most tyrosine hydroxylase-positive neurons are also viral RNA positive (some examples are marked with arrows) and that there are few virus-positive cells which are not also tyrosine hydroxylase positive. Magnification,  $\times 200$ . (F) Paired representative computer-generated images demonstrating the intensity of tyrosine hydroxylase immunostaining in the substantia nigra (SN) and caudate putamen (CPu) from the same mouse. These two regions are present at different levels on the rostrocaudal axis of the brain. Note the bilateral expression of tyrosine hydroxylase in the substantia nigra and caudate putamen in the control animal. 6-OHDA inoculated unilaterally caused a unilateral depletion of tyrosine hydroxylase immunoreactivity in the substantia nigra (arrowhead) and the ipsilateral caudate putamen. A similar effect was observed following virus infection with Theiler's murine encephalomyelitis virus.

However, following conventional intracerebral inoculation these viruses are never confined to this structure alone but rather infect and cause degeneration throughout the limbic system and other areas of the brain.

Following our recent observation that after conventional intracerebral inoculation Theiler's virus can spread to, infect, and destroy the mouse substantia nigra without death of the animal (24), we chose this virus to inject stereotaxically into this nucleus. The stereotaxic coordinates ( $-2.8$  mm anterior,  $-1.4$  mm lateral of bregma, and  $-4.6$  mm below the cortical surface) were established by using a stereotaxic atlas (26) and trial dye injection. In a series of experiments carried out at different times, a total of nine adult ( $>8$ -week-old) female CBA mice were anesthetized and unilaterally inoculated stereotaxically with  $0.1 \mu\text{l}$  of phosphate-buffered saline containing 50 PFU of the BeAn strain of Theiler's virus. Seven negative control animals received the same inoculum without virus. As positive controls, another seven animals were "lesioned" with  $6.75 \mu\text{g}$  of 6-hydroxydopamine (6-OHDA), an aminergic neurotoxin which destroys dopaminergic neurons. Following the insertion of the cannula, infusion of the inoculum was carried out at a rate of  $0.1 \mu\text{l}/\text{min}$ . In order to allow the virus to attach to cells in the substantia nigra and to prevent the virus from being drawn back up the cannulation tract, the cannula was left in place for 45 min and was withdrawn slowly over a 5-min period. Three infected animals were sacrificed at each of 3, 10, and 22 days postinfection. The control animals and those with 6-OHDA lesions were sacrificed at 22 days postinfection. Brains were removed, immersion fixed in 4% phosphate-buffered formal saline, and embedded in paraffin wax. Each brain was serially sectioned coronally into  $5\text{-}\mu\text{m}$  sections, and representative sections at multiple levels were processed for in situ hybridization to determine the location of viral RNA-positive cells. In situ hybridization was carried out as appropriate with  $^{35}\text{S}$ -, digoxigenin-, or biotin-labeled riboprobes complementary to the capsid region of the viral genome (16, 24). For double labeling, biotin-labeled riboprobes were detected with avidin conjugated to fluorescein isothiocyanate and sections were then stained for tyrosine hydroxylase by using a rabbit anti-tyrosine hydroxylase antibody (Bioreme S.A., Reims, France) detected with a goat anti-rabbit antibody conjugated to rhodamine isothiocyanate.

The negative control mice never showed any degeneration of the substantia nigra, whereas those mice inoculated with 6-OHDA had, as expected, large ipsilateral lesions in this area.

In mice given virus, foci of viral RNA-positive cells were observed in the substantia nigra at 3 days postinfection (Fig. 1). By 10 days postinfection, the infection had spread throughout the entire rostrocaudal length of the substantia nigra and the intensity of the positive in situ-hybridization signal in infected cells had increased relative to that on day 3. The spread of the virus to other brain areas was only very rarely observed and involved few cells (Fig. 1). Double labeling indicated that

nearly all infected cells were tyrosine hydroxylase-positive neurons and that most tyrosine hydroxylase-positive neurons in the substantia nigra pars compacta were infected (Fig. 2C to E). Tyrosine hydroxylase immunoreactivity was normal in the contralateral substantia nigra. An inflammatory infiltrate was present from 10 days postinfection (Fig. 2B).

By 22 days postinfection, little or no viral RNA could be detected in the substantia nigra or elsewhere (Fig. 1). By this time, few or no tyrosine hydroxylase-immunoreactive neurons were detectable in the substantia nigra on the inoculated side and all mice demonstrated neuronal atrophy and inflammation, indicating that the infection had effectively lesioned this nucleus (Fig. 2F). Again, there was no evidence either by in situ hybridization for viral RNA or by histopathological changes that the infection had spread to any other structures. Interestingly, at this time little or no tyrosine hydroxylase immunoreactivity was detected in the ipsilateral caudate putamen, which receives projections from nigral neurons. This was also observed in the positive controls with lesions caused by 6-OHDA (Fig. 2F) and has previously been observed following loss of innervation by nigrostriatal projections (4, 23) and in rabbits infected with herpes simplex virus (10). The mice with 6-OHDA lesions and some virus-infected mice were observed to possess a postural and/or rotational bias, characteristic of unilateral dopaminergic deficit.

The explanation for this confined infection is not immediately apparent. A number of previous studies have demonstrated that the spread of the BeAn strain of Theiler's virus is relatively slow in the mature mouse brain (24, 28), and confinement of the infection to the substantia nigra could represent the balance between virus spread and its control by the immune response. Alternatively, since the infection does spread throughout the entire rostrocaudal length of the substantia nigra, the virus may be unable to travel out of this system along neurites or it may be unable to replicate in connected neurons or neurons in adjacent structures.

This is the first direct evidence of the ability of a virus to specifically infect catecholaminergic neurons. The present studies also demonstrate for the first time that a virus can establish an infection in and destroy a specific subpopulation of neurons without significant spread to connected or adjacent areas. Furthermore, the isolated virus damage in the substantia nigra affected the function of distant terminal projection fields in the caudate putamen. The concept of a confined, localized, destructive or disruptive virus infection may be an important scenario in neurodegenerative diseases of man. That we have shown this by targeting the substantia nigra is perhaps particularly relevant to human disease. It is possible to speculate that a virus may enter this structure along olfactory connections. Indeed, Theiler's virus and other viruses such as neurotropic strains of mouse hepatitis virus readily and relatively selectively infect the substantia nigra following intranasal inoculation (2, 7, 12, 28). Alternatively, the virus could enter this structure

following random entry into the central nervous system from the blood (8).

We are grateful to Trevor Robbins, Barry Everett, and Barry Keverne, Departments of Experimental Psychology, Anatomy and Zoology, University of Cambridge, for expert assistance and advice and to M. Rigby for image analysis.

This study was supported by grants from the United Kingdom Medical Research Council and the Myalgic Encephalomyelitis Association.

#### REFERENCES

- Alexander, D. J. 1988. Historical aspects, p. 1–10. *In* D. J. Alexander (ed.), Newcastle disease: developments in veterinary virology. Kluwer Academic Publishers, Norwell, Mass.
- Barnett, E. M., M. D. Cassell, and S. Perlman. 1993. Two neurotropic viruses, herpes simplex virus type I and mouse hepatitis virus, spread along different neural pathways from the main olfactory bulb. *Neuroscience* **57**: 1007–1025.
- Barrett, A. D. T., A. J. Cross, T. J. Crow, J. A. Johnson, A. R. Guest, and N. J. Dimmock. 1986. Subclinical infections in mice resulting from the modulation of a lethal dose of Semliki Forest virus with defective interfering viruses: neurochemical abnormalities in the central nervous system. *J. Gen. Virol.* **67**:1727–1732.
- Blanchard, V., M. Chritin, S. Vyas, M. Savasta, C. Feuerstein, Y. Agid, F. Javoy-Agid, and R. Raisman-Vasari. 1995. Long-term induction of tyrosine hydroxylase expression: compensatory response to partial degeneration of the dopaminergic nigrostriatal system in the rat brain. *J. Neurochem.* **64**: 1669–1679.
- Cross, A. J., T. J. Crow, J. A. Johnson, N. P. Neeley, and G. R. Taylor. 1984. Effects of experimental herpes simplex virus (HSV) encephalitis on monoamine systems in mouse brain. *J. Physiol.* **350**:30.
- Duvoisin, R. C., and M. D. Yahr. 1965. Encephalitis and parkinsonism. *Arch. Neurol.* **12**:227–239.
- Esiri, M. M., and A. H. Tomlinson. 1984. Herpes simplex encephalitis. Immunohistological demonstration of spread of virus via olfactory and trigeminal pathways after infection of facial skin in mice. *J. Neurol. Sci.* **64**: 213–217.
- Fazakerley, J. K., S. Pathak, M. Scallan, S. Amor, and H. Dyson. 1993. Replication of the A7(74) strain of Semliki Forest virus is restricted in neurons. *Virology* **195**:627–637.
- Fishman, P. S., J. S. Gass, P. T. Swoveland, E. Lavi, M. K. Highkin, and S. R. Weiss. 1985. Infection of the basal ganglia by a murine coronavirus. *Science* **229**:877–879.
- Kataoka, K., I. Bak, and C. H. Markham. 1979. Alterations in tyrosine hydroxylase, glutamic acid decarboxylase and choline acetyltransferase in basal ganglia following herpes simplex virus inoculation in rat neostriatum. *Brain Res.* **169**:401–405.
- Kusano, N., Y. Aoyama, and H. Kawamura. 1966. The diagnosis of Japanese encephalitis by means of fluorescent antibody. *Neuropathol. Pol.* **4**:449–456.
- Lavi, E., P. S. Fishman, M. K. Highkin, and S. R. Weiss. 1988. Limbic encephalitis after inhalation of a murine coronavirus. *Lab. Invest.* **58**:31–36.
- Lokanatha, V., and W. Rajendra. 1995. Catecholaminergic transmission in different brain regions of chick during Newcastle Disease virus (NDV) infection. *Biochem. Mol. Biol. Int.* **26**:95–100.
- Lycke, E., and B.-E. Roos. 1975. Virus infections in infant mice causing persistent impairment of turnover of brain catecholamines. *J. Neurol. Sci.* **26**:49–60.
- Lycke, E., K. Modish, and B. E. Roos. 1970. The monoamine metabolism in viral encephalitis of the mouse. I. Virological and biochemical results. *Brain Res.* **23**:235–246.
- Oliver, K. R., M. F. Scallan, H. Dyson, and J. K. Fazakerley. 1997. Susceptibility to a neurotropic virus and its changing distribution in the developing brain is a function of CNS maturity. *J. Neurovirol.* **3**:38–48.
- Paivarinta, M. A., R. J. Marttila, M. Koulu, U. Pesonen, M. Roytta, and U. K. Rinne. 1991. Brain monoamine metabolism and rotational behaviour induced by experimental herpes simplex virus encephalitis. *J. Neural Transm.* **86**:181–190.
- Paivarinta, M. A., R. J. Marttila, J. O. Rinne, and U. K. Rinne. 1992. Decrease in mesencephalic dopamine autoreceptors in experimental herpes simplex encephalitis. *J. Neural Transm.* **89**:71–80.
- Paivarinta, M. A., R. J. Marttila, J. O. Rinne, and U. K. Rinne. 1993. Dopaminergic neurotransmission in chronic herpes simplex virus brain infection in rabbits. *J. Neural Transm.* **93**:205–212.
- Paivarinta, M. A., M. Roytta, V. Hukkanen, R. J. Marttila, and U. K. Rinne. 1994. Nervous system inflammatory lesions and viral nucleic acids in rabbits with herpes simplex virus encephalitis-induced rotational behaviour. *Acta Neuropathol.* **87**:259–268.
- Sarder, A. M., C. Czudek, and G. P. Reynolds. 1996. Dopamine deficits in the brain: the neurochemical basis of parkinsonian symptoms in AIDS. *Neuroreport* **7**:910–912.
- Seegal, R. F., E. Sikora, and J. Hotchin. 1980. Locomotor effects of catecholaminergic drugs on herpes-infected mice. *Pharmacol. Biochem. Behav.* **12**:61–66.
- Sherman, T. G., and C. A. Moody. 1995. Alterations in tyrosine hydroxylase expression following partial lesions of the nigrostriatal bundle. *Mol. Brain Res.* **29**:285–296.
- Simas, J. P., and J. K. Fazakerley. 1996. The course of disease and persistence of virus in the CNS varies between individual CBA mice infected with the CBA strain of Theiler's murine encephalomyelitis virus. *J. Gen. Virol.* **77**:2701–2711.
- Simas, J. P., H. Dyson, and J. K. Fazakerley. 1995. The neurovirulent GDVII strain of Theiler's virus can replicate in glial cells. *J. Virol.* **69**:5599–5606.
- Slotnick, B. M., and C. M. Leonard. 1975. A stereotaxic atlas of the albino mouse forebrain. U.S. Department of Health, Education and Welfare, Alcohol, Drug Abuse and Mental Health Administration, Rockville, Md.
- von Economo, C. 1931. Encephalitis lethargica: its sequelae and treatment. Oxford Medical, London, United Kingdom.
- Wada, Y., and R. J. Fujinami. 1993. Viral infection and dissemination through the olfactory pathway and the limbic system by Theiler's virus. *Am. J. Pathol.* **143**:221–229.