

[February 18, 1955]

Bilateral, Symmetrical, Peri-ureteric Fibrosis

By F. P. RAPER, F.R.C.S.

A PURELY descriptive title has been chosen because the exact nature of the disease to be described remains obscure. No cause has been found for the condition and it therefore differs from the peri-ureteric fibrosis which may follow irradiation or which may involve one ureter in some patients with regional ileitis or diverticulitis. The disease seems to originate as an inflammatory process in the region of the main vessels of the posterior abdominal wall. A very invasive fibrosis occurs which may surround and penetrate the ureters as a result of which they are pulled towards the mid-line, compressed and finally occluded. The early stage of the disease is vague and insidious but it proceeds to its climax rapidly as uræmia or anuria develops. The early symptoms are so variable as to defy compilation and therefore the individual case histories have to be reported.

Case I.—Miss E. C., aged 25.

In December 1952 she was admitted to hospital with the complaint that for two weeks she had had abdominal colic, vomiting and vaginal bleeding. For two days before admission she had severe headache and œdema of her legs and face. She looked pale and ill and was found to have a tender enlarged left kidney and slight tenderness in the right loin. Examination of the vagina showed no bleeding and there were no signs of pregnancy. A small, very offensive cotton-wool swab was removed from the vagina. The urine was sterile but contained a few red cells and scanty clumps of pus. The blood urea was 240 mg. %.

She was cystoscoped and catheters were passed into both ureters but the left ureter was found to be obstructed at about 10 cm. while the right catheter, after a little difficulty, reached the kidney. The ascending pyelograms showed a right hydronephrosis with a tortuous upper ureter but no dye reached the left kidney (Fig. 1).

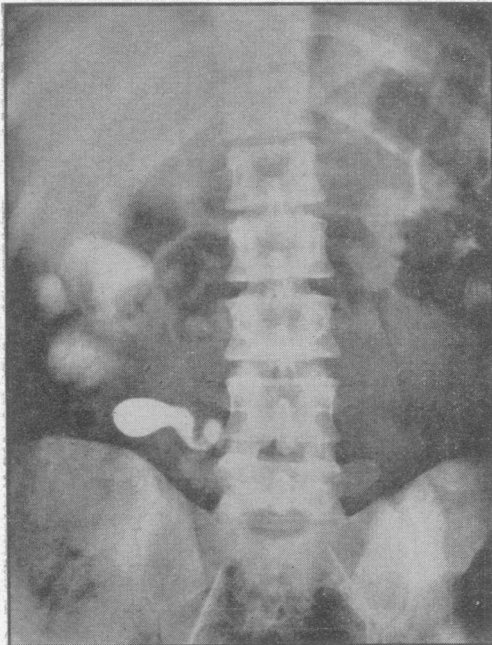


FIG. 1.—Ascending pyelogram, Case I, showing right hydronephrosis and tortuous upper ureter. No dye could be injected into the left kidney. Both ureters are closer to the mid-line than normal where they cross the promontory of the sacrum.

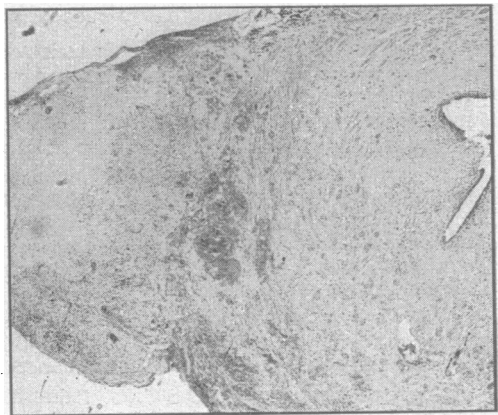


FIG. 2.—Transverse section of part of the left ureter removed from Case I. The lumen of the ureter is on the right of the picture and the wall of the ureter has been invaded by fibrous tissue which penetrates between the muscle fibres. $\times 10$

After preliminary control of her electrolyte balance as a result of which the blood urea had fallen to 146 mg. %, the right kidney was explored. The hydronephrosis was found to be due to obstruction of the ureter by a short length of fibrous tissue just above the point where it crossed the common iliac artery. The ureter was dissected from the scar tissue without much difficulty and appeared undamaged. A piece of the fibrous tissue was removed for histological examination. One month later the left ureter was explored and an identical type of obstruction found. On this occasion it was impossible to dissect the ureter from the scar tissue and about 3 cm. had to be excised, continuity being restored by end-to-end anastomosis. The peritoneum was opened but no intra-abdominal abnormality could be felt. The histology of the excised piece of ureter and of the fibrous tissue removed at the first operation showed marked fibrosis, lymphocytic and plasma cell infiltration and some areas of calcification in the scar tissue. The epithelial layer of the ureter was normal even where the lumen was almost obliterated by surrounding fibrosis (Fig. 2).

Case II.—Mr. J. C. T., aged 45.

In 1951 he was admitted to hospital with pain in the chest and loss of energy. He had also had pain in his limbs for six months. A marked pericardial friction rub was found but an X-ray of his chest was normal. His B.S.R. was 57 mm. in the first hour (Westergren). He was given salicylates and his condition improved so that after four months he returned to work. He continued to get occasional pains in his abdomen and loins and in February 1954 had persistent epigastric pain and a barium meal showed a duodenal ulcer. He was treated for this with Aludrox and a diet but, as his symptoms did not abate, he was admitted to hospital for further investigations. A month before admission he developed the additional symptoms of vomiting, coldness of his hands and feet and pain in his calves when he walked. He looked pale and ill but no abnormality was found on clinical examination. All the pulses were present in his legs. Another barium meal showed that the duodenal ulcer was still present. His white cell count was 16,000, the erythrocyte sedimentation rate 140 and his blood urea was 56 mg. %.

He was treated by an intragastric milk drip but within twenty-four hours got severe pain in his left loin and his left kidney was found to be enlarged and tender. Two days later his blood urea had risen to 172 mg. % and frequent pus cells were found in a sterile mid-stream specimen of urine. An ascending pyelogram was attempted but both catheters were held up at about 10 cm. (Fig. 3). As the

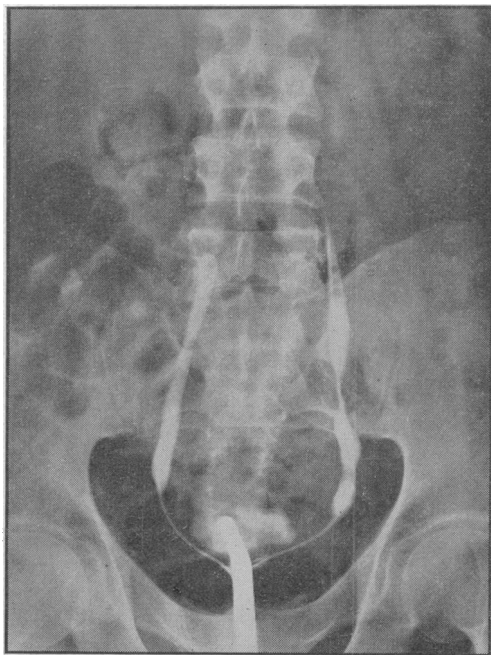


FIG. 3.—Ascending pyelogram, Case II. Both ureters are blocked at the level of the fifth lumbar vertebra and are closer to the mid-line than normal.

sites of the ureteric obstructions seemed close together, a laparotomy was done and the ureters were found to be involved in an inflammatory process centred on the tissues in front of the vertebral bodies. In addition, the upper part of the jejunum was fixed to the posterior wall as if its mesentery had become contracted rather than by intraperitoneal adhesions. The left ureter was dissected free from scar tissue which involved about 2 cm. of it near its centre and which bound it firmly to the side of the aorta. The right ureter was completely obliterated by the fibrous tissue where it crossed the bifurcation of the iliac vessels and it was therefore divided above and below the obstruction and re-

united over a T-tube. About 4 cm. of ureter were involved by the fibrosis. Histological examination of the fibrous tissue including the obstructed ureter showed very similar changes to those in Case I.

At first he passed urine from the bladder satisfactorily but no urine ever drained from the T-tube. His blood urea fell but then began to rise again and the urine output diminished. A left nephrostomy was therefore done and the previously constricted area of ureter re-examined and fixed further from the mid-line. Several muscle biopsies were done but there was no evidence of polyarteritis. One month later, urine reached the bladder when the nephrostomy tube was clamped and this tube and the T-tube were then removed. Both wounds closed spontaneously.

He now looks and feels very much better and no longer has pain in his legs. His urine is normal, his blood urea is 45 mg. % but an intravenous pyelogram still shows no function in the right kidney; there is a short area of constriction in the centre of the left ureter and slight left hydronephrosis.

Case III.—Mrs. B. J., aged 41.

In June 1950 she had a right radical mastectomy for carcinoma of the breast, the tumour being in the upper and outer quadrant, but all the lymph glands examined were free from metastases. This was followed by a course of deep X-ray therapy. She remained well until May 1954 when she developed menorrhagia. In June 1954 she also noticed a lower abdominal swelling and had attacks of painful lower abdominal distension and constipation. She was referred to a gynaecologist in November 1954 who found a large uterine fibroid which appeared to be the explanation of her symptoms.

On 17.11.54, she had a total hysterectomy and bilateral salpingo-oophorectomy. There was one large fibroid in the uterus and several smaller ones. The surgeon noted that the parametric tissues were more indurated than usual. Her post-operative progress was satisfactory until the seventeenth day when she developed anuria and slight pain in the left loin. On the following day she was cystoscoped and the bladder was normal. Ureteric catheters were passed up both ureters but on the right side the catheter was obstructed at about the pelvi-ureteric junction. On the left side there was a temporary hold-up at the same level but the catheter then passed into the pelvis and urine immediately drained down it. The ascending pyelogram showed a right hydronephrosis with an obstruction at the pelvi-ureteric junction and a slight left hydronephrosis with some irregularity of the upper end of the ureter (Fig. 4). The ureteric catheters were removed immediately after the X-ray but she passed no urine during the next twenty-four hours.

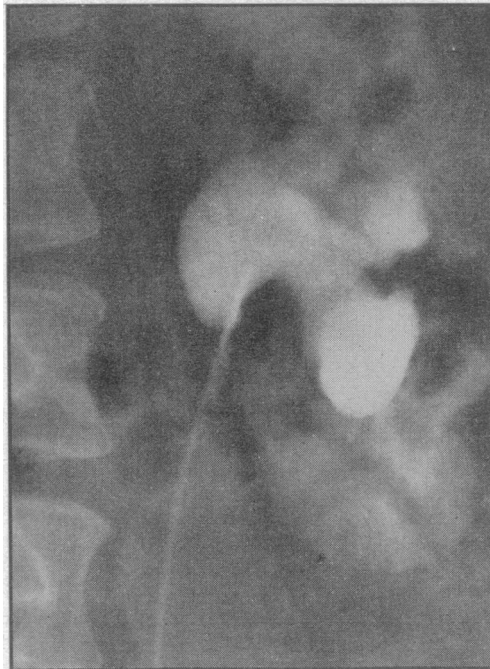

FIG. 4.—Left ascending pyelogram, Case III, showing an area of nodularity in the ureter just below the pelvi-ureteric junction. There is some hydronephrosis.

On the following day a left nephrostomy was performed. At this operation the kidney looked almost normal but the pelvi-ureteric junction and upper part of the ureter were found to be firmly adherent to the vertebral bodies close to the aorta and were surrounded by scar tissue. A small portion of this was removed for histology.

She died within twenty-four hours of the operation probably because of a high blood potassium. Histological examination of the tissue removed showed that it was a plaque of fibrous tissue which included part of a small blood vessel.

These 3 patients were all thought to be suffering from the same disease but its exact nature is uncertain. 6 similar cases of bilateral ureteric obstruction have been reported previously (Ormond, 1948; Amselem, 1950; Ewell and Bruskevitz, 1952; Miller *et al.*, 1952; Bradfield, 1953; Chisholm *et al.*, 1954) and two cases of unilateral ureteric obstruction which may be examples of the same disease (Oppenheimer *et al.*, 1952; MacLean, 1954). All have very complex histories which are difficult to review in a short space but certain general principles about the disease can be deduced.

(1) Evidence that the Ureteric Obstruction is Incidental to a Disease Arising in the Mid-line

The fact that both ureters may be pulled towards the mid-line suggests a lesion arising between them. 4 of the reported cases support this idea. The first 2 were reported by Ormond (1948). Both patients developed anuria during the course of somewhat inconclusive investigations for chronic backache. The first patient had bilateral nephrostomies which were closed when he began to pass urine normally. He died three-and-a-half years later from uræmia and anæmia and at the post-mortem his kidneys were found to be completely destroyed by back pressure and infection. This was the result of retroperitoneal fibrosis surrounding the aorta and including the ureters.

The second patient had a laparotomy at which a retroperitoneal flat mass with indistinct lateral margins was felt covering the sacral promontory and the ureters passed through it near its lateral margins. They were dissected out of the fibrous tissue and after deep X-ray therapy he made good recovery.

A third case suggesting a mid-line origin was reported by Miller *et al.* (1952). This patient also had a laparotomy and differs from the others only in that the inflammatory tissue formed a larger mass and was palpable in the umbilical region before operation. The ureters, although embedded in the mass, were not freed from it and urinary drainage was maintained by ureteric catheters for two weeks. The abdominal mass was still palpable nearly two years later.

A fourth case reported by Chisholm *et al.* (1954) had a bilateral ureterolysis done in two stages. The appearance on each side suggested that the ureters were obstructed by a thick fibrous sheath perhaps arising from fascia over the psoas laterally and extending across the ureter to disappear over the vertebral bodies medially. They quote an anatomical dissection reported by Daseler and Anson (1943) in which a body with bilateral ectopic kidneys appeared to have a fibrous sheath enveloping the great vessels and the ureters.

(2) The Nature of the Inflammatory Process

Although this disease is thought to be inflammatory, there are certain unusual features about it. Firstly the only reported case in which a primary infective focus is suggested was in a patient who had ulcerative colitis for nine years before the ureteric obstruction occurred (Chisholm *et al.*, 1954). Secondly, pyrexia does not seem to be a feature of the disease. This was particularly so in the patient who had the palpable abdominal mass (Miller *et al.*, 1952) for, although a biopsy showed the presence of small abscesses amongst chronic inflammatory tissue, he had no fever until ten days after his operation. Thirdly, in none of the cases is there any mention of enlarged lymph glands. The appearance of the fibrous tissue engulfing and infiltrating the ureters shows that it is of a highly active type and not really like that which occurs during the healing of acute or chronic bacterial infections.

It is worth mentioning that the obstruction of the ureters in these patients is not always demonstrable as a mechanical block on ascending pyelography. In fact in some of the patients, even when anuria had developed, both ureters were catheterized with ease and it seems likely that when a ureter is surrounded by fibrous tissue, peristalsis may be prevented. A similar state of affairs sometimes occurs with extensive malignant disease on the posterior abdominal wall.

(3) Unilateral Ureteric Obstruction

Two examples of unilateral ureteric obstruction have been reported which seem to be the same disease. In one (MacLean, 1954) the left ureter was densely bound down where it crossed the iliac bifurcation and for a distance of about 5 cm. below this point. The other (Oppenheimer *et al.*, 1952) had a similar obstruction on the right but it extended almost to the bladder. Although the disease in these unilateral cases appeared to be at a different site from the bilateral cases, its description as being where the ureter crossed the iliac vessels is interesting and suggests that the disease might originate as an arteritis. This is supported by evidence from a fourth patient in whom what appears to be the same disease presented

with an acute arterial block. She is a woman of 51 who had a hysterectomy for fibroids one year before. Thirteen days after the operation she developed pain and pallor in the right leg and an aortogram showed a complete block of the right external iliac artery just at its origin. Some months later Mr. H. Shucksmith, to whom the patient had been referred, exposed the right iliac arteries with the idea of replacing the blocked artery with a graft. The operation report reads as follows: "Considerable fibrosis about bifurcation of right common iliac artery involving right ureter." The whole of the external iliac artery was found firmly thrombosed and no graft could be used.

SUMMARY

- (1) Three case histories are reported of patients who developed oliguria or uræmia due to obstruction of the ureters by an invasive type of fibrosis which seemed to originate around the main vessels on the posterior abdominal wall.
- (2) The previous literature is reviewed.
- (3) The evidence that the disease is primarily arterial or periarterial is supported by a fourth case history of a patient in whom the disease presented as an arterial block.

REFERENCES

- AMSELEM, A. (1950) *Med. esp.*, **23**, 230.
 BRADFIELD, E. O. (1953) *J. Urol.*, **69**, 769.
 CHISHOLM, E., HUTCH, J. A., and BOLOMEY, A. (1954) *J. Urol.*, **72**, 812.
 DASELER, E. H., and ANSON, B. J. (1943) *J. Urol.*, **49**, 789.
 EWELL, G. H., and BRUSKEWITZ, H. W. (1952) *Urol. cutan. Rev.*, **56**, 3.
 MACLEAN, J. T. (1954) *Brit. J. Urol.*, **26**, 127.
 MILLER, J. M., LIPIN, R. J., MEISEL, H. J., and LONG, P. H. (1952) *J. Urol.*, **68**, 447.
 OPPENHEIMER, G. D., NARINS, L., and SIMON, N. (1952) *J. Urol.*, **67**, 476.
 ORMOND, J. K. (1948) *J. Urol.*, **59**, 1072.

An Assessment of Sodium Acetrizoate and an Experimental Basis for its Use in Intravenous Pyelography [*Summary*]

By P. G. KEATES, M.D., M.R.C.P., D.M.R.D.

20 c.c. of 70% sodium acetrizoate were injected into 5 normal patients who had been deprived of fluid for more than fifteen hours. The average maximum concentration was reached about ten minutes after injection and the best period for radiography was from 7 to 20 minutes after injection. The urine iodine content was about twice as high with this medium as with diodone.

A controlled comparison of 20 c.c. 70% sodium acetrizoate in which a number of patients were each examined with both media showed that sodium acetrizoate produced better and more dense pyelograms.

The diuretic effects of various doses and media were studied. Good filling of pyelograms seems to depend on an adequate rate of urine flow, and is probably related to fluid pressure within the pelvis and calyces.

70% sodium acetrizoate is a local irritant and perivenous leakage is to be avoided. No other serious difficulty in its use was found.

[This paper will be published in full in *J. Fac. Radiol., Lond.*]