

PRIMARY BILIARY CIRRHOSIS

CHRONIC NON-SUPPURATIVE DESTRUCTIVE CHOLANGITIS

EMANUEL RUBIN, M.D.; FENTON SCHAFFNER, M.D., AND HANS POPPER, M.D.

From the Department of Pathology, The Mount Sinai Hospital, New York, N.Y.

Primary biliary cirrhosis (P.B.C.) designates an uncommon clinical entity characterized by jaundice of many years duration, in the absence of extrahepatic biliary obstruction.¹ The outstanding symptom is pruritus which frequently precedes the jaundice. Hepatosplenomegaly is usual. In the early stages of the disease the increase in activity of serum alkaline phosphatase, bromsulfalein retention and serum bile acid level is out of proportion to the degree of hyperbilirubinemia.^{2,3} Hypercholesterolemia is the rule, and xanthomas appear in a variable percentage. The activity of serum transaminase is only moderately elevated and results of flocculation tests are normal. Patients may survive for more than 10 years, because hepatic failure and portal hypertension appear late in the course of the disorder.

Several factors induced us to focus our attention on the early stages of the disease, when the term primary biliary "cirrhosis" is actually a misnomer, since neither septa nor nodules are present. Terms such as "pre-cirrhosis" or "pseudocirrhosis" are avoided since we do not wish to complicate the nomenclature in use. The pathologic evolution of this disease has not been resolved because of the paucity of cases, although several workers have supplied detailed descriptions of the hepatic lesions.⁴⁻⁷ Therefore, we utilized liver specimens from clinically diagnosed cases of primary biliary cirrhosis in the files of this laboratory in an attempt to: (1) recognize the specific lesions associated with the condition, (2) define the morphologic stages with the purpose of establishing the pathologic evolution, and (3) compare these lesions with those in other well recognized diseases. Since primary biliary cirrhosis frequently presents puzzling diagnostic problems in the liver biopsy, the present study is also intended to assist in histologic diagnosis.

MATERIAL AND METHODS

The material was derived from 63 patients, of whom 12 were admitted to the Mount Sinai Hospital. The remaining specimens were obtained from patients at

Supported by Research Grant AM-03846 from the National Institutes of Arthritis and Metabolic Diseases, United States Public Health Service, and the United States Army-Medical Research and Development Command under Contract DA-Md-49193-61-024.

Accepted for publication, September 23, 1964.

other institutions. The available clinical data were sufficient to make the diagnosis of P.B.C. but varied in completeness.

A total of 87 specimens were examined. In 39 cases, single biopsy specimens were available. The remaining 36 specimens were obtained from 12 patients, with 2 to 6 specimens from each. Among the biopsies, 38 were obtained by needle and 37 at laparotomy. Necropsies provided 12 specimens. Therefore, in 49 cases there was anatomic evidence of extrahepatic biliary tract patency. Hematoxylin and eosin stained sections were available in all cases. In addition, in most instances, sections were also stained with an aniline blue stain for connective tissue, Gomori's silver impregnation for reticulum and the periodic acid-Schiff (PAS) reaction after diastase digestion of glycogen. Selected sections were stained with toluidine blue for metachromasia and the PAS stain after acetylation.⁸ Others were stained with acridine orange and examined by fluorescent microscopy for mucopolysaccharides.⁹

Females comprised 75 per cent of the cases. All but 9 were Caucasian. The median age was 46 years, with a range of 32 to 71. The duration of symptoms at the time of the first or the only biopsy ranged from 1 to 9 months, with an average of 6 months. The longest known duration to necropsy was 7 years. Hepatomegaly was recorded in 95 per cent and splenomegaly in 45 per cent. The average total serum bilirubin level at the time of biopsy was 7.4 mg per 100 ml, while in patients who died, it was 19.5 mg. Bromsulfalein retention was reported in 13 cases, with an average of 25 per cent. Serum alkaline phosphatase activity averaged 29.8 Bodansky units and 59.4 King-Armstrong units. Cephalin flocculation was more than 2+ in 42 per cent and the average thymol turbidity was 9.8 units. Average activity of serum glutamic oxalacetic transaminase was 125 units; in only 11 per cent was it below 50. The serum cholesterol average was 610 mg per 100 ml, with values up to 1,400 mg. In 13 per cent, the cholesterol value was below 300 mg per 100 ml. Serum globulins were increased in 80 per cent.

In 6 patients cholecystectomy had been performed from 1 to 6 years prior to the onset of symptoms pertinent to P.B.C. In 2, the disease began shortly after childbirth. Sjögren's syndrome was present in 1 patient. Two first developed jaundice 2 and 3 months after blood transfusions. Three had febrile illnesses with jaundice, suggestive of viral hepatitis, 1, 3 and 4 years prior to the onset of symptoms.

HISTOLOGIC OBSERVATIONS

Examination of tissue obtained at laparotomy and necropsy was generally more rewarding than that of needle biopsy specimens. The latter usually did not include complete large portal tracts or septal bile ducts, and architectural changes had to be inferred from a small core of tissue.

Classification of Intrahepatic Biliary Passages

The following nomenclature, partly based on injection techniques,¹⁰ is utilized. *Biliary canaliculi* are the biliary spaces lined by hepatocytes. *Bile ductules* are passages lined by cuboidal or flat epithelium and are not accompanied by branches of the portal vein, but sometimes by very small branches of the hepatic artery. In the normal liver they appear mainly in the portal tracts and rarely extend far into the lobule.

The *interlobular bile ducts* which are the smallest ducts accompanied by a branch of the portal vein, have a columnar epithelium with nuclei in the center or toward the basal portion of the cell. More than one

interlobular duct may appear in a portal tract, and each is accompanied by portal vein branches. *Septal* (called by some trabecular) *bile ducts*, from which the interlobular ducts branch, are single ducts with high columnar epithelium and basal nuclei; goblet cells are frequent.

Proliferated bile ductules are of two types. Those with cuboidal or plump oval epithelium surrounding a distinct lumen lie within the portal tract or at its immediate periphery and are designated "typical ductules." Other ductules, especially those extending into the parenchyma have flat irregular epithelium and a minute lumen; these are termed "atypical ductules."

Histologic Division of Specimens

The specimens were divided into three main groups:

Type A. Portal Inflammation and Bile Duct Injury (19 specimens). The lobular architecture was unchanged, the relationship of portal tracts to central veins being unaltered. Liver cells appeared essentially normal. The portal tracts and trabeculae were widened throughout and were unusually prominent with low power examination (Fig. 1). They had sharp borders, were surrounded by an intact limiting plate of hepatocytes and contained numerous lymphocytes, commonly arranged as follicles. The latter occasionally exhibited germinal centers. In three-quarters of the specimens many plasma cells appeared at the periphery of the follicles or extended throughout the portal tract.

Bile ducts exhibited lesions varying from tract to tract. Both interlobular and septal bile ducts within such tracts were often surrounded by lymphocytes and plasma cells (Fig. 2), and occasionally ran through a follicle. Periductal tissues were edematous and infiltrated by inflammatory cells (Figs. 3 and 4). In some ducts, the full thickness could only be visualized with connective tissue and reticulum stains which demonstrated concentric layers of fibers. The epithelium of the affected bile ducts was varied, ranging from flat to high columnar. Ductal nuclei also varied in size and appearance (Fig. 5); karyorrhexis, indicative of necrosis, was noted (Fig. 5). In certain ducts, the epithelial lining was irregularly infolded with an almost papillary appearance (Fig. 3). The lining epithelium was infiltrated by inflammatory cells, rarely including neutrophils.

In 6 specimens bile ducts were not only surrounded by lymphoid cells but also by numerous epithelioid cells which formed periductal granulomas (Fig. 6). Some epithelioid cells contained non-glycogenic PAS positive material. In 5 cases, ducts showed frank necrosis, indicated by discontinuity of the epithelial lining, scattering of cells and cell groups, accumulation of nuclear debris and streaky extraluminal

PAS positive coagulates (Fig. 7). The extraluminal PAS positive material was diastase resistant and reacted histochemically in a manner similar to the material in epithelioid cells. Both PAS reactions were abolished by acetylation, suggesting that the substance was not of glycolipid character. It was not metachromatic with toluidine blue and did not fluoresce when stained with acridine orange, indicating the absence of mucopolysaccharides. It was therefore thought to be a mucoprotein.

Necrotic ducts were surrounded by macrophages and lymphoid cells and a few multinucleated giant cells containing PAS positive material. On occasion connective tissue stains demonstrated the stroma of collapsed ducts (Fig. 8). In the vicinity of the periductal granulomas numerous macrophages containing non-glycogenic PAS positive material were found in the sinusoids, often in close contact with lymphoid cells. Periductal granulomas and phagocytes appeared to be transitory since they were seen in only a few florid cases. In most specimens, PAS positive macrophages were uncommon in portal tracts and sinusoids.

At this stage, the number of bile ducts, especially interlobular ducts, frequently appeared to be increased, suggesting tortuosity. By contrast few bile ductules were observed. Fibrous septa were either absent or were represented by small spurs which occasionally gave the portal tracts a stellate appearance. Cholestasis, indicated by bile plugs in dilated canaliculi whether or not accompanied by bile pigment in liver or Kupffer cells, was absent in 10 specimens and in 6 was inconspicuous. In the remaining 3 specimens, pronounced cholestasis was either diffusely distributed or more prominent in the peripheral zone. Distinct centrilobular cholestasis was not encountered, nor was lipofuscin pigment and non-bile related PAS positive pigment ever prominent in liver cells.

Type B. Proliferation and Destruction of Bile Ductules (42 specimens.) The hepatocytes remained essentially normal, except for scattered cells showing cytoplasmic degeneration. This was characterized by a rarefied, reticulated and bile stained cytoplasm. Cholestasis was the rule, and generally lacked distinct zonal distribution. In a few instances it was more prominent in the central zone. Portal tracts were enlarged, frequently more than in type A, and their borders were more irregular, variably exhibiting radiating fibrous spurs (Fig. 9). Collagen fiber bundles frequently enveloped the portal tracts. Interlobular and septal bile ducts did not show the inflammatory reaction observed in type A, but in two cases duct walls were thickened and fibrotic.

Lymphocytes and plasma cells were less prominent than in type A. Within the portal tracts bile ductules had proliferated; this was less

prominent at the periphery of the lobules. In 15 cases of types B and AB "typical ductules" were surrounded by the same form of infiltrate seen about the injured ducts in type A lesions (Fig. 10). Plasma cells and lymphocytes were common and occasionally a granuloma with epithelioid cells containing PAS positive material surrounded a "typical ductule." In 9 examples of types B and AB, epithelium in "typical" ductules appeared ballooned and irregular (Fig. 11), and occasionally displayed necrosis evidenced by karyorrhexis. "Atypical ductules" were often surrounded by neutrophils, by collagen fibers (Fig. 12) and by histiocytes with ellipsoid nuclei. Some of the latter probably represented fibroblasts.

Septa accompanied only "atypical ductules," which, in many instances were embedded in the fibrous mass and appeared atrophic. Septa interconnected portal tracts but failed to reach central veins, thus somewhat distorting but nowhere destroying the lobular architecture. In 5 needle biopsy specimens in which ducts were not found, cholestasis was absent and proliferation of bile ductules was not extensive. In some of these a larger specimen might have revealed type A lesions.

Type AB, Bile Duct Injury Associated with Bile Ductular proliferation (9 specimens). In this group lesions of bile ducts were associated with proliferation of bile ductules, thus combining the characteristics of types A and B. Only one lacked cholestasis.

Type C. Cirrhosis (17 specimens). In 6 necropsy specimens slabs of liver or photographs of gross specimens were available. In 4 instances the livers were enlarged, with weights varying from 2,300 to 3,550 gm. In 2 livers the weights were normal, 1,350 gm and 1,500 gm. The livers were dark green and the outer surfaces finely nodular. Cut sections showed loss of lobular architecture, with nodules varying from 0.1 to 0.4 cm in diameter, and a uniformly fine network of thin septa.

Microscopically the lobular architecture was distorted by nodules and septa which connected portal tracts and the connective tissue of hepatic vein tributaries throughout the liver (Fig. 13). The septa were irregularly distributed and did not contain collapsed lobules; many extended into the parenchyma without interconnection and ended blindly (Fig. 14). They exhibited smooth borders, hyalinized stroma and contained few cells except for occasional lymph follicles. The number of bile ducts appeared to be strikingly reduced. In 7 instances scars in the portal tracts could have represented obliterated ducts. Inflamed ducts were absent, except in 1 case, where a few portal tracts showed cholangitis. "Typical ductules" were absent; the few "atypical ductules" present were small and atrophic.

The nodules varied in size and contained persisting portal tracts and

central veins. Frequently large hepatic vein tributaries lay close to the septa. Evidence of regeneration, which was not conspicuous, included binucleated cells, polyploidy, twin cell plates and thinning of other plates as the result of pressure. Cholestasis was encountered in almost all cases. It was unusually severe and particularly prominent at the periphery of the nodules. Otherwise the liver cells exhibited few changes except for occasional rarefaction of the cytoplasm associated with bile imbibition and, in a few instances, centrilobular coagulation necrosis, a lesion attributed to shock associated with terminal bleeding. The morphologic pattern was not diagnostic and the arrangement of septa and nodules resembled that of "posthepatic cirrhosis" described by Gall.¹¹

Intralobular Alterations

In almost all cases there was an increased number of cells in the sinusoids (Fig. 15). In addition to endothelial cells, Kupffer cells containing PAS positive granules and a few small lymphocytes, many cells with round, dense nuclei and a varying amount of amphoteric to basophilic cytoplasm were seen. They did not contain PAS staining material, and were probably of lymphoid nature. This inflammatory reaction was particularly prominent in 2 type A, 7 type B and 2 type C lesions. Intra-lobular granulomas characterized by the accumulation of epithelioid cells with little PAS positive content were particularly prominent in 3 type A and 4 type B cases; in 1 case foam cells were present.

Studies of Serial Specimens

In 6 of 12 cases with more than one biopsy or in which biopsy and necropsy specimens were both available, cholestasis was not seen in the initial specimen, while it was regularly present in the tissue obtained later. Transition from group A to group B was seen in 1 case, from group A to group C in 1 case, and from group B to group C in 2 cases. The small needle specimens in the other 8 cases showed no features indicating progression. In 4 cases serial specimens permitted observations on the effects of prolonged prednisone and cholestyramine therapy. In no instance was an improvement in the histologic appearance established with certainty. However, difficulties in sampling did not permit conclusions as to the effect of treatment on altered bile ducts.

CORRELATION OF HISTOLOGIC AND CLINICAL FEATURES

Since the cases originated from various institutions, the clinical data cannot be considered as consistent as those obtained from a single hospital. The average duration of symptoms at the time of procuring the

specimen was about 9 months for types A, B and AB; it was 43 months for type C. Serum bilirubin averaged 5.3 mg per 100 ml for type A, 6.5 mg for type B and 14.2 mg for type C. There were no significant differences among the groups in the activity of serum alkaline phosphatase or the serum level of total cholesterol.

Differential Diagnosis

Of the three stages of P.B.C. delineated, the first, representing a chronic, destructive cholangitis and pericholangitis, is recognized more readily by surgical biopsy excision than in the smaller needle fragments. In conjunction with clinical information needle specimens in stage A cases or surgically excised tissues at other stages may suggest the diagnosis of P.B.C. Activation of sinusoidal cells, some of which are basophilic and without phagocytic activity, is a subtle point in favor of P.B.C. Chronic idiopathic jaundice without pigment (Rotor's syndrome) can usually be excluded by the existence of portal inflammation.

To determine whether the characteristic cholangitis is found in the absence of the clinical syndrome of P.B.C., examples of other hepatic disorders were studied for comparison. These included diseases of the bile ducts and various types and stages of cirrhosis, particularly those which may simulate P.B.C. clinically. Lymphomas were also included because of the histologic similarity of the portal infiltrate (Table I).

Acute Extrahepatic Biliary Obstruction (10 Cases). Portal lymphocytic infiltration was not pronounced, plasma cells were absent and segmented leukocytes frequent. Severe central cholestasis was invariable, the reverse of early P.B.C. "Typical ductules" with cuboidal epithelium and distinct lumens, extended into the parenchyma. This was in contrast to the second stage of P.B.C., where the ductules which extended into the parenchyma were "atypical."

Chronic Extrahepatic Biliary Obstruction—Secondary Biliary Cirrhosis (9 Cases). Chronic inflammatory lesions of bile ducts with the accumulation of neutrophils and eosinophils, periductal lymphocytes and foamy macrophages were seen, but here periductal concentric fibrosis was more conspicuous. Plasma cells were absent. Follicular accumulations of lymphocytes were occasionally noted, but the bile duct wall was characteristically fibrotic and the follicles did not impinge upon the duct. In late stages cirrhosis similar to the corresponding stage of P.B.C. was observed. Cholestasis varied from minimal to severe; in the latter situation it was both central and peripheral.

Diffuse Septal Cirrhosis (Portal, Laennec's, Nutritional) (40 Cases). Among these specimens, derived mostly from alcoholics, 8 cases with clinical jaundice and severe histologic cholestasis were intentionally in-

TABLE I
HISTOLOGIC FEATURES WITH DIAGNOSTIC SIGNIFICANCE IN PRIMARY BILIARY CIRRHOSIS

| Number of specimens | Types P.B.C. | | | Extrahepatic obstruction | | Diffuse septal cirrhosis | Post-necrotic cirrhosis | Drug-induced cholestasis | Lymphoma | Ulcerative colitis | | |
|------------------------|--------------|-----|-----|--------------------------|---------|--------------------------|-------------------------|--------------------------|----------|--------------------|---------|-----|
| | A | B | C | Acute | Chronic | | | | | Sub-acute | Chronic | |
| | 19 | 42 | 9 | 17 | 10 | 9 | 40 | 75 | 65 | 12 | 7* | 3 |
| Portal inflammation | 100† | 100 | 100 | 65 | 100 | 100 | 93 | 80 | 80 | 100 | 100 | 100 |
| Excess plasma cells | 74 | 43 | 67 | 12 | 0 | 0 | 8 | 37 | 8 | 18 | 0 | 33 |
| Lymphoid follicles | 68 | 21 | 55 | 18 | 0 | 22 | 0 | 4 | 0 | 0 | 0 | 33 |
| Infolding of ducts | 32 | 0 | 11 | 0 | 0 | 11 | 0 | 0 | 0 | 0 | 0 | 0 |
| Periductal granulomas | 21 | 5 | 11 | 0 | 0 | 0 | 0 | 0 | 0 | 0 | 0 | 0 |
| Ductal necrosis | 26 | 0 | 11 | 0 | 10 | 11 | 0 | 0 | 0 | 9 | 0 | 0 |
| Ductule proliferation | | | | | | | | | | | | |
| "Typical" | 0 | 55 | 55 | 0 | 100 | 78 | 15 | 19 | 17 | 0 | 29 | 67 |
| "Atypical" | 0 | 100 | 100 | 82 | 50 | 89 | 100 | 95 | 52 | 33 | 100 | 100 |
| Cholestasis, | | | | | | | | | | | | |
| Central | 0 | 17 | 11 | 6 | 80 | 33 | 0 | 0 | 68 | 0 | 29 | 0 |
| Peripheral | 5 | 5 | 11 | 47 | 0 | 0 | 0 | 0 | 0 | 0 | 0 | 0 |
| Central and peripheral | 10 | 55 | 67 | 29 | 20 | 67 | 20 | 12 | 32 | 42 | 57 | 100 |
| Ductular | 0 | 29 | 0 | 24 | 10 | 44 | 5 | 5 | 0 | 0 | 0 | 33 |

* Includes one case of regional enteritis.

† Incidence is given in percentage of cases.

cluded; in these plasma cells were rare. The bile duct epithelium was not altered.

Postnecrotic Cirrhosis (75 Cases) and Chronic Active Hepatitis (80 Cases). These cases included both the coarse nodular form of postnecrotic cirrhosis with extensive collapse, and the posthepatic form.¹¹ Cholestasis was conspicuous in 9 instances. In 3 cases, lymphocytic follicles were noted; these occasionally contained germinal centers. In 2 instances bile duct epithelium was altered, but no necrosis was seen; in none of these cases was jaundice present. In 9 cases of prolonged jaundice with postnecrotic cirrhosis, but lacking other features of the clinical syndrome of P.B.C., pericholangitis was not seen.

In short, although rare, the characteristic non-suppurative chronic pericholangitis may occur without the clinical syndrome of P.B.C., but duct destruction was not a feature among these. In addition, the pericholangitis here was always associated with cirrhosis. Pericholangitis was not encountered among the 80 cases of chronic active (subacute) hepatitis.

Drug Induced Intrahepatic Cholestasis (65 Cases). The principal histologic features which might be confused with P.B.C. were portal inflammation and proliferation of bile ductules. Only 1 case, in which jaundice followed the administration of the antidiabetic agent, chlorpropamide, exhibited injury to bile ducts. The portal inflammation differed from that in P.B.C. in the absence of lymphoid follicles, the frequent admixture of eosinophils and neutrophils and the rarity of plasma cells. Central cholestasis, frequently severe, was the rule, whereas it was uncommon in early P.B.C.

A few cases of prolonged drug-induced cholestasis showed moderate portal tract fibrosis. These, both clinically and histologically, mimicked P.B.C. However, recovery was the rule, and no transitions to chronic, progressive and intractable disease were recorded.

Lymphoma (12 Cases). Four cases of Hodgkin's disease and 8 of lymphosarcoma, all with jaundice, were studied. Portal infiltration was found in all, but in 9, the bile ducts were entirely spared. In the other 3, 2 of Hodgkin's disease and 1 of lymphosarcoma, neoplastic cells surrounded and infiltrated the bile ducts. In 1 case, the bile duct epithelium was distorted and atypical with occasional karyorrhexis. Critical cytologic inspection permitted identification of neoplastic cells and distinction from P.B.C.

Ulcerative Colitis (9 Cases) and Regional Enteritis (1 Case). Among the liver injuries associated with ulcerative colitis, cholestatic jaundice, characterized by high serum alkaline phosphatase and histologically by cholestasis and inflammatory lesions in the portal tracts, has been de-

scribed.^{12,13} In a subacute variety, of which 7 cases were studied, proliferation of bile ductules and infiltration by neutrophils were prominent. Three cases of prolonged jaundice for 1, 8 and 14 years, were studied. Two exhibited type B lesions and 1, type C.

The typical chronic destructive cholangitis and pericholangitis of type A was not demonstrated in these cases. This could, however, have been the result of examination of limited stages. It cannot be denied, nonetheless, that the chronic cholestatic liver disease associated with ulcerative colitis might actually be a variant of P.B.C.

SUMMARY OF DIFFERENTIAL DIAGNOSIS

A reliable histologic diagnosis of P.B.C. by liver biopsy without recourse to clinical and laboratory findings can only be based on the existence of chronic non-suppurative cholangitis. Frank necrosis of ducts is uncommon, but when seen is pathognomonic. The characteristic features of the cholangitis and pericholangitis are highly suggestive of P.B.C. Pericholangitis without duct destruction or clinical features of P.B.C. is very uncommon in postnecrotic cirrhosis and very rare in other types of cirrhosis. Periductal inflammation may be evident in biliary obstruction. Serious difficulties may arise with lymphoma, but the cytologic features are usually diagnostic, and examination of lymph nodes should be conclusive.

In other than stage A, or in needle biopsy fragments which do not exhibit cholangitis or pericholangitis, the differential diagnosis is based on a correlation of clinical and laboratory findings with histologic observations. The first stage of P.B.C. may be suspected when pruritus and jaundice with elevation of direct reacting bilirubin, high activity of serum alkaline phosphatase and high bromsulphalein retention are present in the absence of histologic evidence of cholestasis. Five such cases were classified type B in needle biopsy tissue which showed slight proliferation of ductules. These livers might actually have demonstrated an earlier lesion with surgical biopsy. In the second stage (type B), the differentiation from chronic active hepatitis and drug induced hepatic injury, in a small needle biopsy specimen usually cannot be made histologically. In the third stage (type C), the separation from postnecrotic cirrhosis with prolonged jaundice is difficult. The degree and activity of cirrhosis is, however, far more conspicuous in postnecrotic cirrhosis than in P.B.C.

DISCUSSION

Previous attempts to categorize the morphologic peculiarities found in P.B.C. into a coherent pathologic entity have led to such terms as

pericholangiolitic biliary cirrhosis, mainly in women,⁶ obstructive intrahepatic cholangitis, with no sex predilection,¹⁴ chronic cholangiolitis,¹⁵ and diffuse mesenchymatous hepatitis with nodular lymphomatosis, mostly in men.¹⁶ Cameron and Hou¹⁷ distinguished P.B.C. from the hypertrophic cirrhosis of Hanot. They suggested that in the latter malady excessive connective tissue and xanthomas might contribute to intrahepatic mechanical obstruction. The controversy is of such extent that recently an anatomic lesion characteristic of P.B.C. has been denied. The disorder has been considered merely a variant of chronic hepatitis, although the nature of the hepatitis has not been identified.¹⁸

These conflicting views reflect difficulties inherent in the morphologic analysis of P.B.C. They relate to: (1) the small size of needle and occasional surgical biopsy specimens precluding representative sampling of the intrahepatic biliary tree, (2) the fact that a biopsy or necropsy specimen may represent only one stage of a disease, and (3) the irregular development of cirrhosis, a situation notoriously misleading in needle biopsy specimens. Despite these differences we do not believe that the histologic evolution of P.B.C. is so obscure that its distinctive nature cannot be elucidated.

Preliminary studies with fewer cases revealed an early non-suppurative chronic destructive cholangitis of septal and interlobular bile ducts.¹⁹ Examination of larger numbers of cases in this study has confirmed the distinctive nature of the cholangitis and pericholangitis in early P.B.C. It is characterized, not only by a characteristic ductal inflammation but by duct destruction as well. These changes are fairly specific; we have not observed the bile duct lesion in the absence of cirrhosis except in lymphoma. The lesion may occur infrequently in postnecrotic cirrhosis, which could be taken to indicate that the syndrome of P.B.C. might complicate other types of cirrhosis. On the other hand, the characteristic clinical manifestations of P.B.C. were absent in these cases; the significance of the inflammatory portal lesion in postnecrotic cirrhosis is thus not clear; active duct destruction and periductal granulomas were not encountered.

The characteristic cholangitic lesion of P.B.C. was associated with laboratory evidence of cholestasis. In a significant number of instances, however, no histologic evidence of cholestasis was found, suggesting that bile may regurgitate through damaged septal and interlobular bile ducts. The increased activity of serum alkaline phosphatase, bromsulphalein retention, elevation of total serum cholesterol, and the prominence of itching may be considered reflections of elevated serum bile acid level. These phenomena are usually out of proportion to the degree of hyperbilirubinemia and could be explained by preferential excretion

of bilirubin. This may not be as easily accomplished for the other bile components. It thus appears, in keeping with previous concepts,^{6,7,19} that the insult to the biliary tract represents the initial injury in P.B.C.

The development of the lesion has been evolved by the grouping of random specimens with similar patterns. Intermediate stages with characteristic lesions apparently preceding or following each other have been encountered in the same specimen and in biopsies made in series from the same patient.

The initial cholangitis involves destruction of ductal epithelium. This is followed by a periductal granulomatous inflammation. Intracellular and extracellular PAS positive deposits encountered at this stage may represent material derived from necrotic ductal epithelium. It is apparently of mucoprotein character, is presumably irritant and is possibly antigenic. The phagocytic reaction appears to be followed by a lymphoid response and proliferation of bile ductules then takes place. "Typical ductules" are also destroyed and are accompanied by the same reaction. "Atypical ductules" are associated with an initially inflammatory and a later fibroblastic reaction. At this stage, both central and more characteristically periportal cholestasis is present and is frequently associated with bile plugs in ductules. This observation supports the assumption that ductular alteration and fibrosis may result in a mechanical intrahepatic biliary obstruction.

The development of cirrhosis after the phase of ductular proliferation can be related to the production of radiating fibrous septa. This seems to occur rather slowly and is usually unassociated with active cholangitis. A few cases, however, do show concentric periductal fibrosis as in chronic extrahepatic biliary obstruction. In most examples of the late cirrhotic stage, the only indication of the earlier destructive cholangitis is a reduction in the number of bile ducts. Septum formation is irregular and only in the late stages are the parenchymal portions circumscribed sufficiently to produce nodules.²⁰ The final appearance is that of septal cirrhosis of the incomplete type, a form designated by Gall as posthepatic cirrhosis.¹¹ At the cirrhotic stage, in many instances, only a preceding biopsy may give the key to its evolution. In this late phase, which may not be histologically characteristic, the functional manifestations of cirrhosis, with ascites and hepatic failure, become the presenting manifestations. In view of the involvement of the portal tracts,²¹ portal hypertension of a presinusoidal character occurs earlier. At a still later stage, postsinusoidal hypertension, characteristic of all types of cirrhosis^{6,22} becomes life threatening.

Thus it is postulated that the lesion of P.B.C. begins with injury to bile ducts, resulting in jaundice by regurgitation. This progresses as a ductular lesion, which adds an element of intrahepatic biliary obstruc-

tion. Eventually the process terminates as an incomplete septal cirrhosis, frequently lacking the characteristic alterations existing during its evolution.

SUMMARY

On the basis of 87 necropsy and biopsy specimens from 63 cases of primary biliary cirrhosis, the disorder is considered to be an entity with characteristic clinical manifestations. In its initial stage the process is characterized by a chronic non-suppurative destructive cholangitis and pericholangitis affecting septal and interlobular bile ducts. Characterized by necrosis of ducts and a granulomatous reaction, this lesion may be responsible for regurgitation of bile, frequently in the absence of visible cholestasis. This stage appears to be followed by the accumulation of lymphoid and plasma cells, proliferation and destruction of bile ductules, periductular inflammation and septal fibrosis. During this period centrilobular and peripheral cholestasis are common. The final stage is that of an incomplete septal cirrhosis, usually without persisting cholangitis. In needle biopsy specimens exhibiting no cholestasis procured from jaundiced patients with elevation of direct serum bilirubin, bromsulphalein retention and increased activity of serum alkaline phosphatase, primary biliary cirrhosis may be suggested. Surgically excised biopsy specimens are usually more helpful than those obtained by needle biopsy. Active destruction of bile ducts is thought to be a pathognomonic alteration. Surgical biopsy specimens in the early stages of this disorder are usually diagnostic, and those obtained in the intermediate stage are suggestive, particularly when correlated with the clinical and laboratory findings. The lesions encountered in terminal stages, usually at necropsy, are non-diagnostic.

REFERENCES

1. AHRENS, E. H., JR.; PAYNE, M. A.; KUNKEL, H. G.; EISENMENGER, W. J., and BLONDHEIM, S. H. Primary biliary cirrhosis. *Medicine*, 1950, 29, 299-364.
2. SHERLOCK, S. Primary biliary cirrhosis (chronic intrahepatic obstructive jaundice). *Gastroenterology*, 1959, 37, 574-586.
3. HOFFBAUER, F. W. Primary biliary cirrhosis; observations of the natural course of the disease in 35 women. *Am. J. Digest. Dis.*, 1960, 5, 348-383.
4. HANOT, V. La Cirrhose Hypertrophique avec Ictère Chronique. Rueff et Cie, Paris, 1892.
5. MOSCHCOWITZ, E. Morphology and pathogenesis of biliary cirrhosis. *Arch. Path.*, 1952, 54, 259-275.
6. MACMAHON, H. E. Biliary cirrhosis. Differential features of the five types. *Lab. Invest.*, 1955, 4, 243-261.
7. CAMERON, R. Some problems of biliary cirrhosis. *Brit. Med. J.*, 1958, 1, 535-543.
8. BARKA, T., and ANDERSON, P. J. Histochemistry, Theory, Practice and Bibliography. Paul Hoeber Medical Division, Harper & Row, Publishers, Inc., New York, 1963, 660 pp.

9. SAUNDERS, A. M. Histochemical identification of acid mucopolysaccharides with acridine orange. *J. Histochem.* 1964, 12, 164-170.
10. MASUKO, K.; RUBIN, E., and POPPER, H. Proliferation of septal bile ducts in cirrhosis. *Arch. Path.*, 1964, 78, 421-431.
11. GALL, E. A. Posthepatic, postnecrotic and nutritional cirrhosis. *Am. J. Path.*, 1960, 36, 241-271.
12. MCCARTHY, C. F., and READ, A. E. Bleeding esophageal varices in ulcerative colitis. *Gastroenterology*, 1962, 42, 325-329.
13. VINNIK, I. E., and KERN, F., JR. Biliary cirrhosis in a patient with ulcerative colitis. *Gastroenterology*, 1963, 45, 529-534.
14. RÖSSLE, R. In: *Handbuch der Speziellen Pathologischen Anatomie und Histologie*. HENKE, F. and LUBARSCH, O. (eds.). Berlin, Springer, 1930, Vol. 5, Part 1, pp. 243-250.
15. KÜHN, H. A.; MÜLLER, W., and PFISTER, R. Über chronische Cholangiolitis und ihre Beziehung zur primären biliären Cirrhose. *Ztschr. klin. Med.*, 1957, 154, 462-493.
16. ALBOT, G. La cholestase intrahepatique chronique. *Arch. mal. app. digest.*, 1957, 46, 177J-227J.
17. CAMERON, R., and HOU, P. C. Biliary Cirrhosis. Charles C Thomas, Springfield, Ill., 1962, 170-177.
18. JONES, W. A., and TISDALE, W. A. Posthepatic cirrhosis clinically simulating extrahepatic biliary obstruction (so-called "primary biliary cirrhosis"). *New England J. Med.*, 1963, 268, 629-639.
19. RUBIN, E.; SCHAFFNER, F., and POPPER, H. Localization of the basic lesion in primary biliary cirrhosis. *J.A.M.A.*, 1963, 183, 331-334.
20. POPPER, H., and ELIAS, H. Histogenesis of hepatic cirrhosis studied by the three-dimensional approach. *Am. J. Path.*, 1955, 31, 405-441.
21. HALES, M. R.; ALLAN, J. S., and HALL, E. M. Injection-corrosion studies of normal and cirrhotic livers. *Am. J. Path.*, 1959, 35, 909-941.
22. POPPER, H., and ZAK, F. G. Pathologic aspects of cirrhosis. *Am. J. Med.*, 1958, 24, 593-619.

We wish to thank all the physicians who provided material for this study.

LEGENDS FOR FIGURES

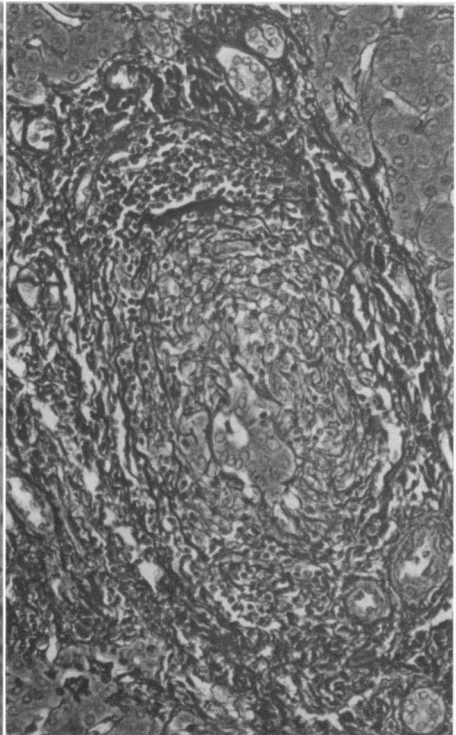
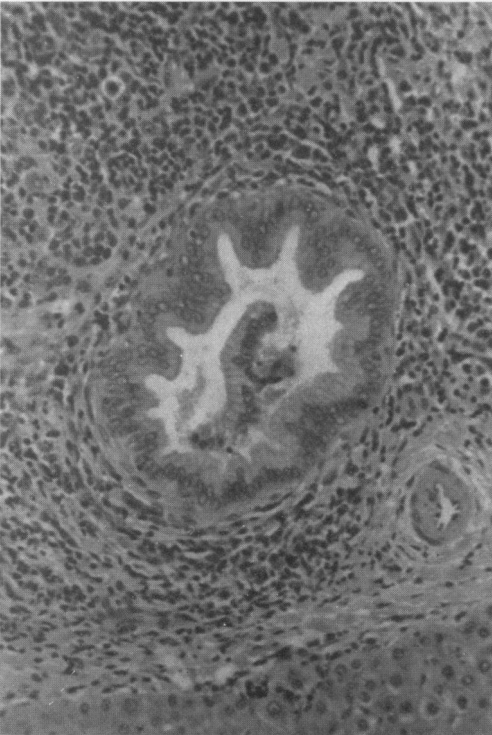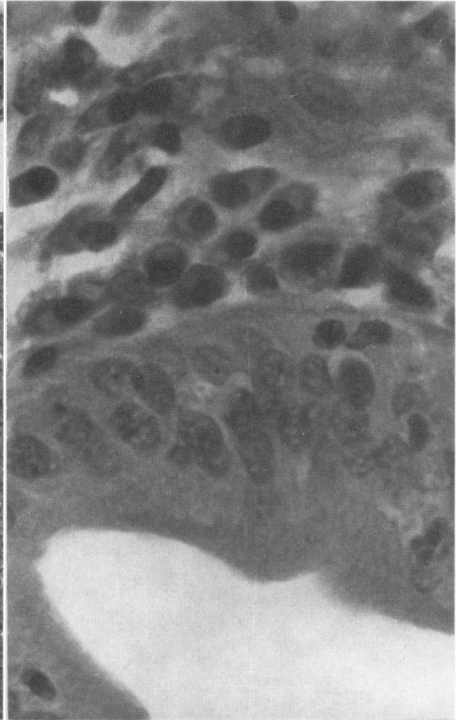
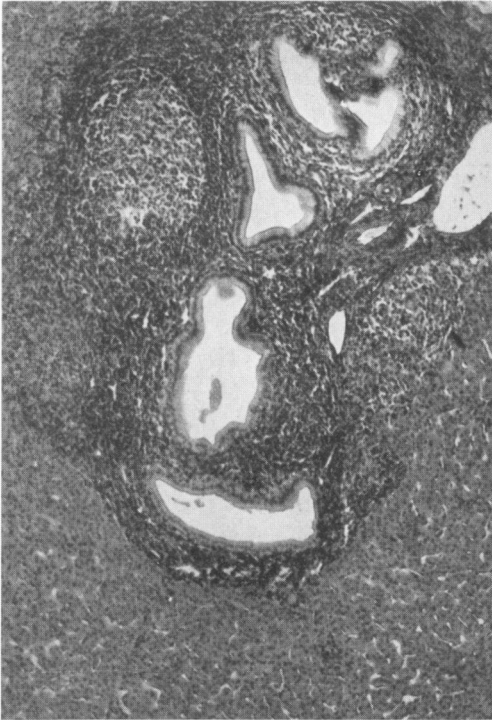
Except where indicated photomicrographs were prepared from sections stained with hematoxylin and eosin.

FIG. 1. Primary biliary cirrhosis (P.B.C.), type A. Septal bile ducts are surrounded by lymph follicles which contain germinal centers. $\times 80$.

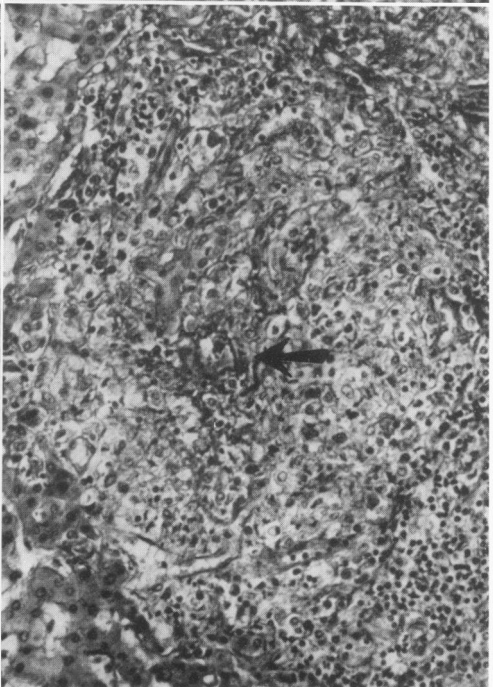
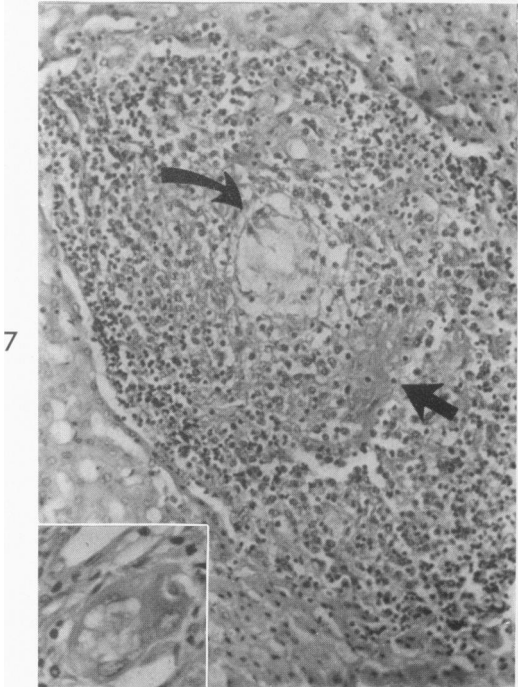
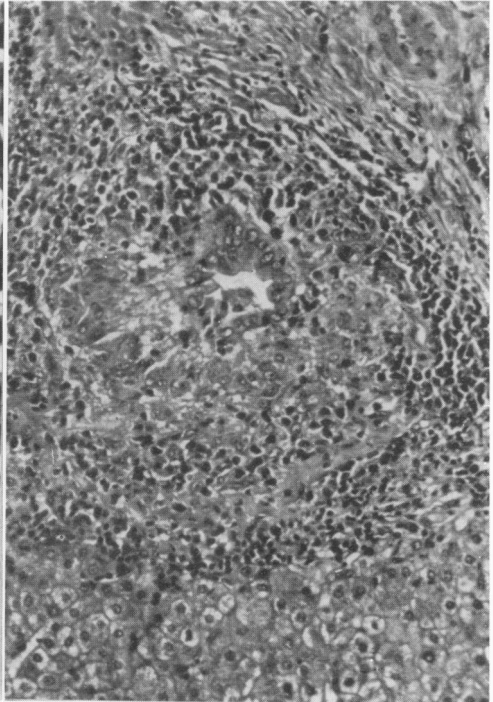
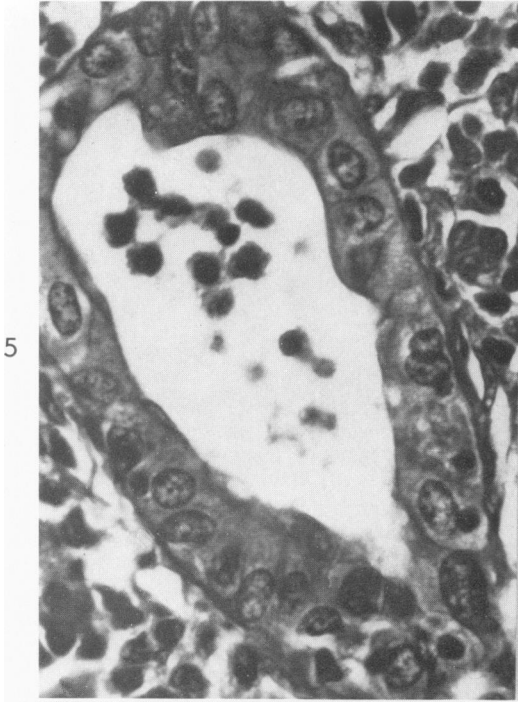
FIG. 2. Type A. Portal tracts are swollen and the septal bile ducts are surrounded by plasma cells. Inflammatory cells appear within the epithelium. $\times 800$.

FIG. 3. Type A. The wall of a septal bile duct is infiltrated by lymphocytes and plasma cells. The epithelium exhibits a papillary appearance. $\times 200$.

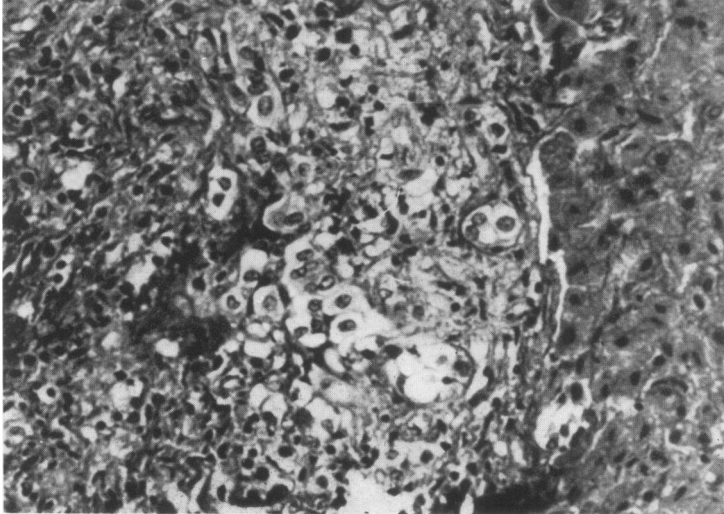
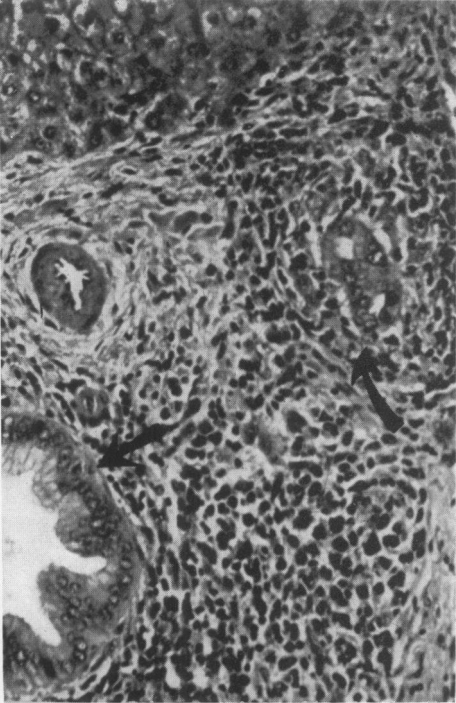
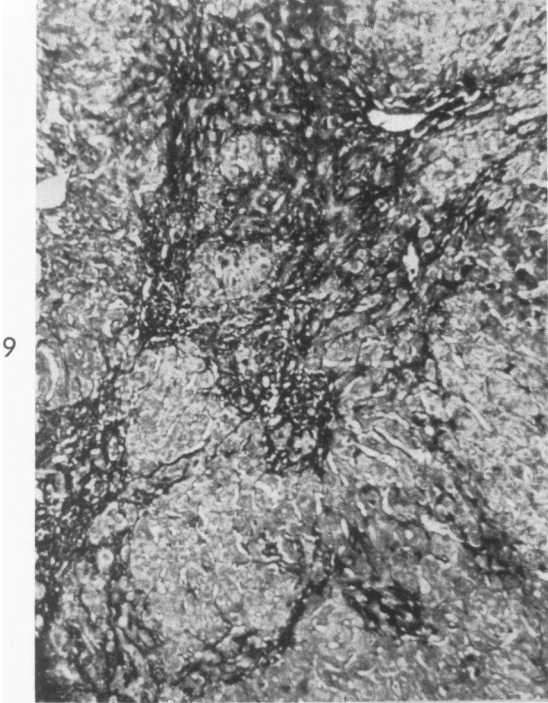
FIG. 4. Type A. A reticulum stain of a portal tract shows ductal and periductal edema. Gomori's silver impregnation. $\times 200$.



- FIG. 5. Type A. An interlobular bile duct exhibits severe inflammation and atypical epithelium. $\times 800$.
- FIG. 6. Type A. A damaged interlobular bile duct is surrounded by epithelioid macrophages and lymphoid cells, forming a periductal granuloma. $\times 200$.
- FIG. 7. Type A. A necrotic duct (curved arrow) is surrounded by a granuloma. There are extracellular periodic acid-Schiff (PAS) positive deposits (straight arrow). PAS after diastase digestion. $\times 200$.
Inset. Phagocyte with foamy cytoplasm with (PAS) positive material. $\times 800$.
- FIG. 8. Type A. The stroma of a collapsed duct is surrounded by a granuloma. Chromotrope-aniline blue stain. $\times 200$.

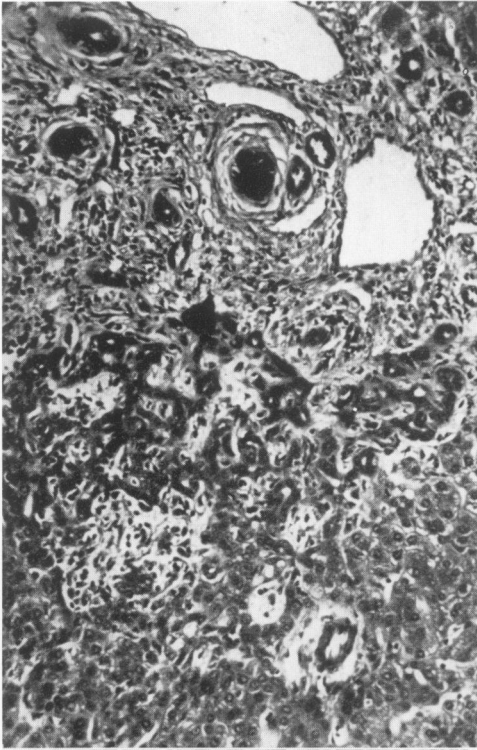


- FIG. 9. Type B. Periportal fibrosis exhibits no linking septa. Regenerative nodules are absent. Chromotrope-aniline blue stain. $\times 80$.
- FIG. 10. Type AB. A "typical ductule" (curved arrow) is surrounded by epithelioid macrophages and lymphoid cells, similar to those encountered about the septal bile duct (straight arrow). $\times 200$.
- FIG. 11. Type AB. Bile ductules contain ballooned epithelial cells and show obliteration of their lumens. $\times 800$.

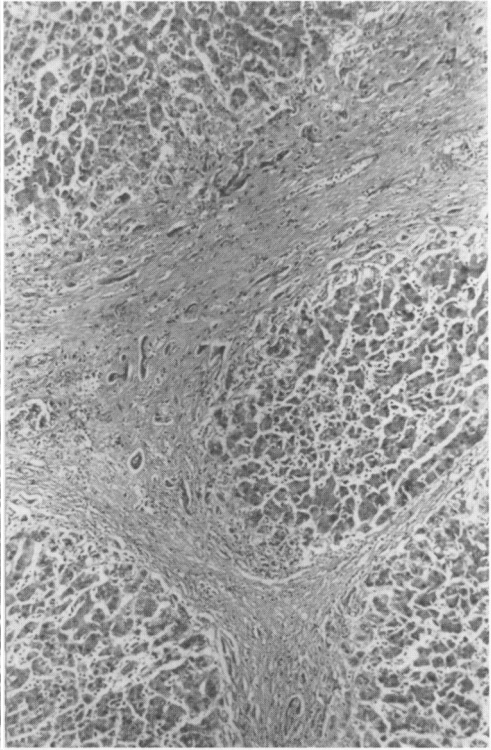


- FIG. 12. Type B. The border of a portal tract shows extensive proliferation of "atypical ductules" surrounded by fibers. $\times 200$.
- FIG. 13. Type C. Septal cirrhosis is featured by linking septa and regenerative nodules. A few atrophic bile ductules are present in the septa. Borders are smooth and inflammatory cells scarce. No bile ducts are seen. $\times 60$.
- FIG. 14. Type C. Septa extend into the parenchyma without linking. They have smooth borders and contain a paucity of inflammatory cells. $\times 60$.
- FIG. 15. Type B. Intralobular sinusoidal cells are increased in number. Many are round and bulge into the sinusoid lumen. $\times 400$.

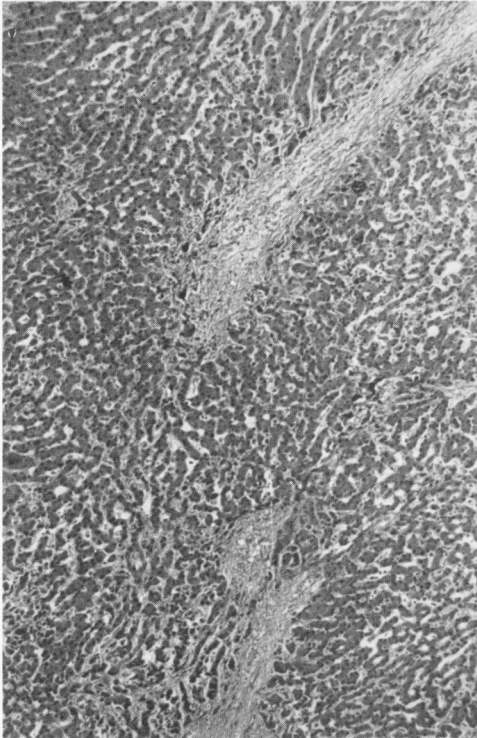
12



13



14



15

