

Primary Hodgkin's disease of the CNS in an immunocompetent patient: A case study and review of the literature

Jim Biagi, Robert G. MacKenzie,¹ Megan S. Lim, Michelle Sapp, and Neil Berinstein

Divisions of Medical Oncology and Hematology (J.B., N.B.), Radiation Oncology (R.G.M.), and Pathology (M.S.L., M.S.), Toronto - Sunnybrook Regional Cancer Centre, Sunnybrook and Women's College Health Science Centre, University of Toronto, Toronto, Ontario, Canada M4N 3M5

Primary Hodgkin's disease limited to the CNS is exceedingly rare. Little is known regarding etiologic risk factors, optimal management, and prognosis. A case of Hodgkin's disease confined to the CNS, with cerebrospinal fluid negative for cytology, is described in an immunocompetent patient previously treated for hyperthyroidism with ¹³¹I. The patient underwent craniotomy, with resection of two lesions in close proximity within the parenchyma of the temporoparietal lobe. Histopathology revealed classic nodular sclerosing Hodgkin's disease, without evidence of Epstein-Barr viral infection. Treatment included radiation to the whole brain with a boost to the tumor bed. The patient made a full neurologic recovery and remains free of disease recurrence 21 months after treatment. A literature review has identified only 9 additional cases. Seven of 8 evaluable patients remain alive and free of recurrence with a median follow-up of 13 months. The risk factors for this presentation remain undefined. Although follow-up is short, radiotherapy alone appears to provide excellent disease-free survival. Chemotherapy may be reserved for patients with positive cerebrospinal fluid, extracranial disease, or subsequent relapse. *Neuro-Oncology* 2, 239–243, 2000 (Posted to *Neuro-Oncology* [serial online], Doc. 00-028, September 6, 2000. URL <neuro-oncology.mc.duke.edu>)

Hodgkin's disease with CNS involvement is uncommon, even in the HIV-positive population, and usually occurs in the setting of advanced or recurrent disease. Reports of primary Hodgkin's disease confined to the CNS are exceedingly rare. We describe a case of primary CNS Hodgkin's disease in a patient previously treated with ¹³¹I for Grave's hyperthyroidism and review the literature with respect to potential risk factors, management, and treatment outcomes.

Case Study

A 52-year-old right-handed male truck driver developed sudden onset of headache and confusion. He presented to the emergency department 2 days later with mild disorientation and receptive aphasia. Functional inquiry was negative for fatigue, weight loss, pruritis, fever, and night sweats. Physical examination revealed proptosis, but no evidence of peripheral adenopathy or hepatosplenomegaly. Assessment of cranial nerves, power, sensation, and coordination revealed no abnormalities.

Past health included a history of Grave's hyperthyroidism with ophthalmopathy 4 years earlier. The patient was treated with radioactive iodine at a total dose of 229 mbq (6.2 mCi) administered orally. There was a 40-pack-year smoking history. Medication on admission was limited to L-thyroxine, 0.125 mg per day. Family history was negative for cancer.

Initial investigations revealed a normal complete blood cell count, peripheral blood smear, electrolytes, blood urea nitrogen, creatinine, random glucose, and international normalized ratio. Serum lactate dehydrogenase and erythrocyte sedimentation rate were not performed. A CT scan with contrast of the head revealed a contrast-enhancing 1.0 cm left temporoparietal lesion, with significant edema and mass effect (Fig. 1).

Received 18 April 2000, accepted 19 June 2000.

¹Address correspondence and reprint requests to Robert G. MacKenzie, Division of Radiation Oncology, Toronto-Sunnybrook Regional Cancer Centre, 2075 Bayview Ave., Toronto, Ontario, Canada, M4N 3M5.

²Abbreviations used are as follows: CSF, cerebrospinal fluid; HIV, human immunodeficiency virus.

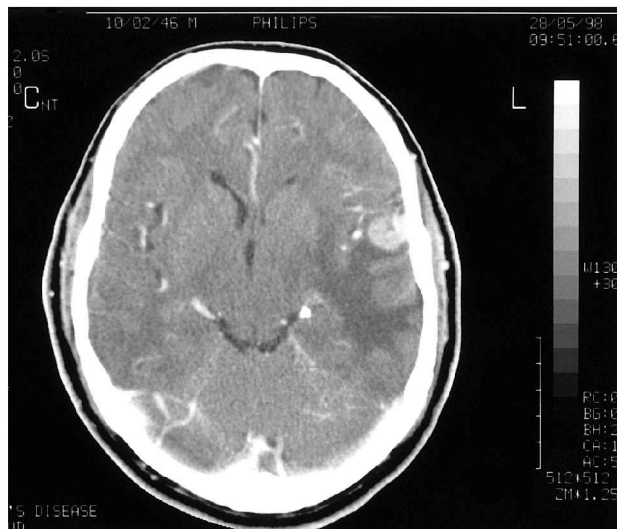


Fig. 1. Contrast-enhanced CT scan of the head, demonstrating a parenchymal lesion in the left temporoparietal region.

Treatment was initiated in the emergency department with phenytoin and dexamethasone. Craniotomy with tumor resection was performed 2 days later. Two mass lesions measuring 8 × 6 × 4 mm and 2 × 2 × 1 mm were removed without complications. The larger lesion was parenchymal, with the smaller adjacent mass adherent to the arachnoid mater.

Pathologic work-up included histologic and immunohistochemical studies, as well as in situ hybridization for Epstein-Barr virus RNA. The surgical specimen was fixed in 10% neutral buffered formalin and embedded in paraffin, and sections were stained with hematoxylin and eosin. For immunohistochemical staining, commercially available antibodies and the biotinylated-streptavidin

horseradish peroxidase technique were used. In situ hybridization for Epstein-Barr virus RNA was performed using the EBER-1 probe (Novocastra Laboratories, Newcastle upon Tyne, U.K.).

Examination of the hematoxylin- and eosin-stained tissue demonstrated a mixed infiltrate composed of lymphocytes, plasma cells, numerous eosinophils, and large pleomorphic malignant cells separated into vague nodules by fibrous tissue. Numerous multinucleated cells with classic features of Reed-Sternberg cells were present (Fig. 2a). Lacunar variants and mononuclear variants were frequently identified. The Reed-Sternberg cells were CD30- (Fig. 2b) and CD15-positive. They were negative for CD45, CD20, and CD3, although the reactive component revealed a mixed infiltrate of T cells and B cells. Reed-Sternberg cells and lymphocytes were negative for Epstein-Barr virus LMP-1 protein and RNA using the EBER-1 probe.

The patient's postoperative course was uneventful, and the dexamethasone was successfully tapered. He achieved full neurologic recovery and was discharged on phenytoin with no documented seizures.

Subsequent staging work-up included a normal bone marrow aspirate and biopsy. A lumbar puncture yielded clear CSF² characterized by normal white cell count, normal protein level, and slightly elevated glucose. The CSF was negative for malignant cells. Ultrasound of liver and CT scan of thorax, abdomen, and pelvis revealed no significant abnormality. A whole-body gallium scan was within normal limits. Thyroid ultrasound revealed a small coarse gland with no significant abnormality. HIV testing was negative.

The patient was classified as Ann Arbor stage IEA. Radiation planning was begun 10 weeks after surgery. The target volume included the whole brain and meninges. The patient was treated supine, immobilized in

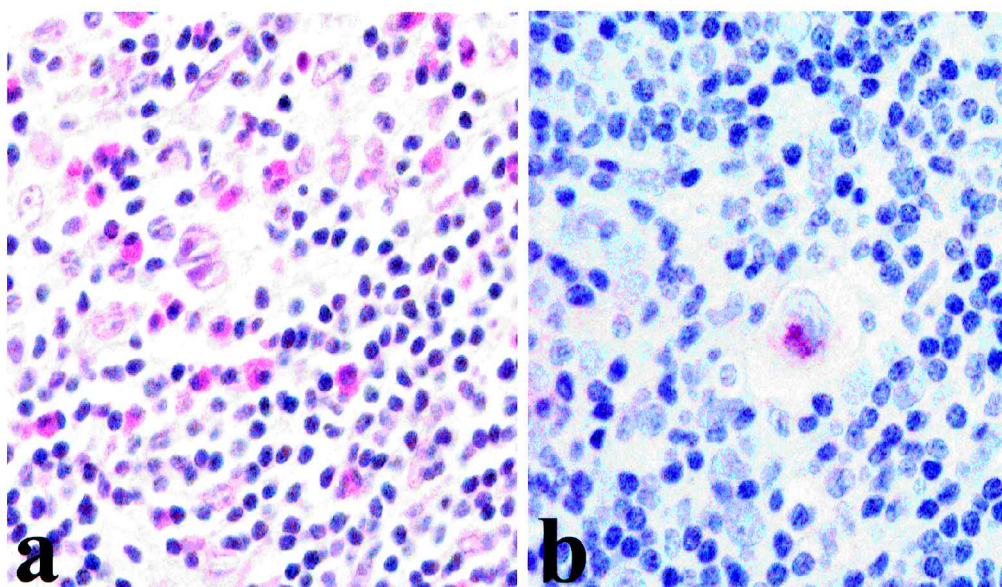


Fig. 2. Histopathology of CNS lesion. A. Histology of polymorphous infiltrate composed of numerous eosinophils, small lymphocytes, and occasional classic binucleate Reed-Sternberg cells (hematoxylin and eosin, original magnification ×400). B. Prominent perinuclear Golgi staining of Reed-Sternberg cell with CD30. (Dako primary, diaminobenzidine chromogen, hematoxylin counterstain, original magnification ×600).

Table 1. Case reports of primary Hodgkin's disease of the CNS

Case	Year, author	Patient (age/sex)	Disease site	Treatment	Outcome at last follow-up
1	1946, Sparling and Adams	53/M	L frontal	None	Died 5 days postop
2	1955, Schrickler and Smith	45/M	R temporal	RT 1500 r	NED-36 mo.
3	1980, Nagashima	60/M	Falx cerebri	None	Unknown
4	1986, Bender and Mayernik	34/M	R frontal dura/bone, spinal meninges	RT+CT	NED-12 mo.
5	1987, Doorly et al.	51/M	L cerebellum	RT 3000 cGy WB boost 1500 cGy	NED-12 mo.
6	1988, Ashby et al.	62/M	R frontoparietal	RT 4000 cGy; +IT CT	NED-14 mo.
7	1990, Sickler et al.	84/F	R parieto-occipital	RT 3500 cGy	NED-8 mo.
8	1992, Clark et al.	53/F	R cerebellum	RT 4500 cGy	NED-6 mo.
9	1999, Klein et al.	54/M	R occipital	RT 3600 cGy WB boost 1400 cGy+CT	NED-16 mo.
10	Current report	52/M	L temporoparietal	RT 3000 cGy WB boost 500 cGy	NED-21 mo.

Abbreviations: M, male; F, female; R, right; L, left; RT, radiation therapy; CT, chemotherapy; r, roentgens; cGy, centigray; WB, whole brain; IT, intrathecal; NED, alive with no evidence of disease; mo, months.

a plastic shell. A lateral parallel pair was used to deliver a dose of 3000 cGy in 17 fractions to midplane on cobalt-60. The eyes were shielded throughout therapy. A weighted lateral parallel pair was used to boost original sites of gross disease with a margin of 2 cm to a dose of 500 cGy in 3 fractions. Radiation was well tolerated.

Follow-up CT scans at 1, 6, 12, and 20 months post-treatment revealed no evidence of recurrence. At 21 months from completion of radiation treatment, the patient remains well with no evidence of local or systemic Hodgkin's disease.

Discussion

CNS Hodgkin's disease has been described in patients with disseminated disease, particularly those with relapse involving extranodal sites (Cuttner et al., 1979; Dujovny et al., 1980; Sapozink and Kaplan, 1983). Primary Hodgkin's disease isolated to the CNS is exceedingly rare (Algers et al., 1981; Wood and Coltman, 1973). A review of the literature over the past 50 years reveals only 9 well-documented cases of Hodgkin's disease confined to the craniospinal axis at presentation (Table 1). Tumors have been described as isolated cerebral or cerebellar masses or, less commonly, parenchymal disease with attachment to the dura or bone. In two cases, disease was confined to the dura (Bender and Mayernik, 1986; Nagashima et al., 1980). In one report, the primary CNS lesion was treated 3 months before lung involvement was ultimately discovered (Deckert-Schluter et al., 1998). Other case reports (Bertelsen, 1970; Burstein et al., 1963; Henry et al., 1974; Zimmerman, 1975) provide inadequate diagnostic information or have been reclassified as non-Hodgkin's lymphoma, an unsurprising finding given the evolving pathologic classification and staging methods over the period of this review.

Patients with immunodeficiency are at increased risk of malignancy, including Hodgkin's disease (Gatti and Good, 1971; Rabkin et al., 1991). An increased risk of Hodgkin's disease has been confirmed in those infected with HIV (Hessol et al., 1992; Levine, 1998; Schoepfel et

al., 1986; Serraino et al., 1997; Straus, 1997). HIV-infected patients with Hodgkin's disease are more likely to present with B symptoms, mixed cellularity histology, extranodal involvement, and advanced stage of disease (Carbone et al., 1991; Tirelli et al., 1992). Epstein-Barr virus infection is common in this population, particularly in those aged 50 years and older (Tirelli et al., 1995). Primary CNS malignancies including high-grade non-Hodgkin's lymphoma and Kaposi's sarcoma have been associated with the low CD4⁺ count of HIV infection (Petrukevitch et al., 1999; Rubio, 1994). A similar association has not been established for CNS Hodgkin's disease. However, as HIV-related Hodgkin's disease cases accumulate, a propensity for primary CNS involvement may emerge.

Interest in radiation-induced cancers has grown in recent years as the number of long-term survivors has increased. The results of epidemiologic reviews are of particular interest in this case because of the possible relationship between ¹³¹I exposure and development of Hodgkin's disease. A number of population-based studies from the United States and Sweden have examined cancer incidence in patients undergoing diagnostic ¹³¹I scans and therapeutic doses of I¹³¹ for hyperthyroidism or thyroid cancer. These studies have reported an increased risk of some solid tumors (Goldman et al., 1988; Hoffman et al., 1982) and chronic myeloid leukemia (Shimon et al., 1995; Walgraev et al., 1991). An increase in the incidence of lymphoma or acute leukemia has not been observed (De Vathaire et al., 1997; Hall et al., 1992; Holm et al., 1991). Large population-based reviews have not identified an increase in the relative risk of death from hematopoietic or lymphoreticular malignancy among patients treated with ¹³¹I (Franklyn et al., 1998; Ron et al., 1998). The weight of the evidence suggests that ¹³¹I exposure is unlikely to be related to the pathogenesis of Hodgkin's disease in this case.

The optimum management of primary CNS Hodgkin's disease is not known. The role of chemotherapy is under active investigation in primary CNS lymphoma because of disappointing results with radiotherapy alone (Laperriere et al., 1997; Nelson et al., 1992; Neuwelt et al., 1991).

Chemotherapy is also playing a larger role in the management of localized extracranial Hodgkin's disease. In current risk-adapted treatment protocols, radiotherapy alone is limited to selected patients with favorable prognostic factors (Gospodarowicz et al., 1992; Specht et al., 1988). Combined modality therapy has been recommended with increasing frequency for patients judged to be at risk of local or distant failure when treated with radiotherapy alone (Abrahamsen et al., 1996; Tubiana et al., 1985).

The reported outcomes following treatment of primary CNS Hodgkin's disease (Table 1) suggest that the short-term prognosis for these patients is excellent. Seven of 8 evaluable patients remain alive and free of recurrence with follow-up ranging between 6 and 36 months.

Although 3 of the 9 reported cases were treated with chemotherapy, there is insufficient data to recommend the routine use of adjunctive intrathecal or systemic chemotherapy without evidence of positive CSF cytology or extracranial extension. It is not clear if whole-brain irradiation is required to prevent intracranial relapse. Conclusions regarding treatment efficacy are clearly limited by small numbers and lack of long term follow-up.

In summary, primary Hodgkin's disease limited to the CNS is exceedingly rare. The risk factors for this presentation remain undefined. Although follow-up is short, radiotherapy alone appears to provide excellent disease-free survival. Chemotherapy may be reserved for patients with positive CSF, extracranial disease, or subsequent relapse.

References

- Abrahamsen, A.F., Hannisdal, E., Nome, O., Holte, H., Hager, B., Langholm, R., and Kvaloy, S. (1996) Clinical stage I and II Hodgkin's disease: Long-term results of therapy without laparotomy: Experience at one institution. *Ann. Oncol.* **7**, 145-150.
- Algers, G., Boquist, L., Fodstad, H., Liliequist, B., and Singounas, E. (1981) Hodgkin's disease primarily localized to the brain: Case report. *Acta Neurochir.* **59**, 231-237.
- Ashby, M.A., Barber, P.C., Holmes, A.E., Freer, C.E., and Collins, R.D. (1988) Primary intracranial Hodgkin's disease: A case report and discussion. *Am. J. Surg. Pathol.* **12**, 294-299.
- Bender, B.L., and Mayemik, D.G. (1986) Hodgkin's disease presenting with isolated craniospinal involvement. *Cancer* **58**, 1745-1748.
- Bertelsen, K. (1970) Primary cerebral reticulosarcoma. *Acta. Pathol. Microbiol. Scand. [A]* **78**, 209-214.
- Burstein, S.D., Kernohan, J.W., and Uihlein, A. (1963) Neoplasms of the reticuloendothelial system of the brain. *Cancer* **16**, 289-305.
- Carbone, A., Tirelli, U., Vaccher, E., Volpe, R., Gloghini, A., Bertola, G., De Re, V., Rossi, C., Boiocchi, M., and Monfardini, S. (1991) A clinicopathologic study of lymphoid neoplasias associated with human immunodeficiency virus infection in Italy. *Cancer* **68**, 842-852.
- Clark, W.C., Callihan, T., Schwartzberg, L., and Fontanesi, J. (1992) Primary intracranial Hodgkin's lymphoma without dural attachment: Case report. *J. Neurosurg.* **76**, 692-695.
- Cuttner, J., Meyer, R., and Huang, Y.P. (1979) Intracerebral involvement in Hodgkin's disease: A report of 6 cases and review of the literature. *Cancer* **43**, 1497-1506.
- De Vathaire, F., Schlumberger, M., Delisle, M.J., Francese, C., Challeton, C., de la Genardiere, E., Meunier, F., Parmentier, C., Hill, C., and Sancho-Garnier, H. (1997) Leukaemias and cancers following iodine-131 administration for thyroid cancer. *Br. J. Cancer* **75**, 734-739.
- Deckert-Schluter, M., Marek, J., Setlik, M., Markova, J., Pakos, E., Fischer, R., and Wiestler, O.D. (1998) Primary manifestation of Hodgkin's disease in the central nervous system. *Virchows Arch.* **432**, 477-481.
- Dooley, T.P., Farrell, M.A., and Phillips, J. (1987) Primary intracerebral Hodgkin's lymphoma. *J. Neurol. Neurosurg. Psychiatry* **50**, 1048-1050.
- Dujovny, M., McBride, D., and Segal, R. (1980) Intracranial manifestations of Hodgkin's disease. *Surg. Neurol.* **13**, 258-265.
- Franklyn, J.A., Maisonneuve, P., Sheppard, M.C., Betteridge, J., and Boyle, P. (1998) Mortality after the treatment of hyperthyroidism with radioactive iodine. *N. Engl. J. Med.* **338**, 712-718.
- Gatti, R.A., and Good, R.A. (1971) Occurrence of malignancy in immunodeficiency diseases: A literature review. *Cancer* **28**, 89-98.
- Goldman, M.B., Maloof, F., Monson, R.R., Aschengrau, A., Cooper, D.S., and Ridgway, E.C. (1988) Radioactive iodine therapy and breast cancer: A follow-up study of hyperthyroid women. *Am. J. Epidemiol.* **127**, 969-980.
- Gospodarowicz, M.K., Sutcliffe, S.B., Bergsagel, D.E., and Chua, T. (1992) Radiation therapy in clinical stage I and II Hodgkin's disease. *Eur. J. Cancer* **28A**, 1841-1846.
- Hall, P., Boice, J.D., Jr., Berg, G., Bjelkengren, G., Ericsson, U.B., Hallquist, A., Lidberg, M., Lundell, G., Mattsson, A., Tennvall, J., Wiklund, K., and Holm, L.E. (1992) Leukaemia incidence after iodine-131 exposure. *Lancet* **340**, 1-4.
- Henry, J.M., Heffner, R.R., Jr., Dillard, S.H., Earle, K.M., and Davis, R.L. (1974) Primary malignant lymphomas of the central nervous system. *Cancer* **34**, 1293-1302.
- Hessol, N.A., Katz, M.H., Liu, J.Y., Buchbinder, S.P., Rubino, C.J., and Holmberg, S.D. (1992) Increased incidence of Hodgkin's disease in homosexual men with HIV infection. *Ann. Int. Med.* **117**, 309-311.
- Hoffman, D.A., McConahey, W.M., Diamond, E.L., and Kurland, L.T. (1982) Mortality in women treated for hyperthyroidism. *Am. J. Epidemiol.* **115**, 243-254.
- Holm, L.E., Hall, P., Wiklund, K., Lundell, G., Berg, G., Bjelkengren, G., Cednerquist, E., Ericsson, U.B., Hallquist, A., Larsson, L.G., Lidberg, M., Lindberg, S., Tennvall, J., Wicklund, H., and Boice, J.D., Jr. (1991) Cancer risk after iodine-131 therapy for hyperthyroidism. *J. Natl. Cancer Inst.* **83**, 1072-1077.
- Klein, R., Mullges, W., Bendszus, M., Woydt, M., Kreipe, H., and Roggendorf, W. (1999) Primary intracerebral Hodgkin's disease: Report of a case with Epstein-Barr virus association and review of the literature. *Am. J. Surg. Pathol.* **23**, 477-481.
- Laperriere, N.J., Cerezo, L., Milosevic, M.F., Wong, C.S., Patterson, B., and Panzarella, T. (1997) Primary lymphoma of brain: Results of management of a modern cohort with radiation therapy. *Radiother. Oncol.* **43**, 247-252.
- Levine, A.M. (1998) Hodgkin's disease in the setting of human immunodeficiency virus infection. *J. Natl. Cancer Inst. Monogr.* **23**, 37-42.
- Nagashima, K., Mori, S., Yoshimasu, N., and Takahashi, K. (1980) Primary Hodgkin's disease of the falx cerebri. *Acta. Neuropathol. (Berl.)* **51**, 161-163.
- Nelson, D.F., Martz, K.L., Bonner, H., Nelson, J.S., Newall, J., Kerman, H.D., Thomson, J.W., and Murray, K.J. (1992) Non-Hodgkin's lymphoma of the brain: Can high dose, large volume radiation therapy improve survival? Report on a prospective trial by the Radiation Therapy Oncology Group (RTOG): RTOG 8315. *Int. J. Radiat. Oncol. Biol. Phys.* **23**, 9-17.
- Neuwelt, E.A., Goldman, D.L., Dahlborg, S.A., Crossen, J., Ramsey, F., Roman-Goldstein, S., Brazier, R., and Dana, B. (1991) Primary CNS lymphoma treated with osmotic blood-brain barrier disruption: prolonged survival and preservation of cognitive function. *J. Clin. Oncol.* **9**, 1580-1590.

- Petruckevitch, A., Del Amo, J., Phillips, A.N., Stephenson, J.M., Johnson, A.M., and De Cock, K.M. (1999) Risk of cancer in patients with HIV disease: London African HIV/AIDS Study Group. *Int. J. STD AIDS* **10**, 38-42.
- Rabkin, C.S., Biggar, R.J., and Horm, J.W. (1991) Increasing incidence of cancers associated with the human immunodeficiency virus epidemic. *Int. J. Cancer* **47**, 692-696.
- Ron, E., Doody, M.M., Becker, D.V., Brill, A.B., Curtis, R.E., Goldman, M.B., Harris, B.S., III, Hoffman, D.A., McConahey, W.M., Maxon, H.R., Preston-Martin, S., Warshauer, M.D., Wong, F.L., and Boice, J.D., Jr. (1998) Cancer mortality following treatment for adult hyperthyroidism: Cooperative Thyrotoxicosis Therapy Follow-up Study Group. *JAMA* **280**, 347-355.
- Rubio, R. (1994) Hodgkin's disease associated with human immunodeficiency virus infection: A clinical study of 46 cases: Cooperative Study Group of Malignancies Associated with HIV Infection of Madrid. *Cancer* **73**, 2400-2407.
- Sapozink, M.D., and Kaplan, H.S. (1983) Intracranial Hodgkin's disease: A report of 12 cases and review of the literature. *Cancer* **52**, 1301-1307.
- Schoepfel, S., Hoppe, R., Abrams, D., Baer, D., Dorfman, R., Grant, K., Horning, S., Wilkinson, L., and Ziegler, J. (1986) Hodgkin's disease (HD) in homosexual men: The San Francisco Bay area experience. *Proc. Am. Soc. Clin. Oncol.* **5**, 9 (abstract).
- Schricker, J.L., Jr., and Smith, D.E. (1955) Primary intracerebral Hodgkin's disease. *Cancer* **8**, 629-633.
- Serraino, D., Pezzoti, P., Dorrucchi, M., Alliegro, M.B., Sinicco, A., and Rezza, G. (1997) Cancer incidence in a cohort of human immunodeficiency virus seroconverters: HIV Italian Seroconversion Study Group. *Cancer* **79**, 1004-1008.
- Shimon, I., Kneller, A., and Olchovsky, D. (1995) Chronic myeloid leukaemia following ¹³¹I treatment for thyroid carcinoma: A report of two cases and review of the literature. *Clin. Endocrinol.* **43**, 651-654.
- Sickler, G.K., Hanson, S.K., Hsu, S.M., and Papasozomenos, S.C. (1990) Primary intracerebral Hodgkin's disease: A case report. *Clin. Neuropathol.* **9**, 143-147.
- Sparling, H.J., Jr., and Adams, R.D. (1946) Primary Hodgkin's sarcoma of the brain. *Arch. Pathol.* **42**, 338-344.
- Specht, L., Nordentoft, A.M., Cold, S., Clausen, N.T., and Nissen, N.I. (1988) Tumor burden as the most important prognostic factor in early stage Hodgkin's disease: Relations to other prognostic factors and implications for choice of treatment. *Cancer* **61**, 1719-1727.
- Straus, D.J. (1997) Human immunodeficiency virus-associated lymphomas. *Med. Clin. North Am.* **81**, 495-510.
- Tirelli, U., Errante, D., Vaccher, E., Repetto, L., Rizzardini, G., Spina, M., Gastaldi, R., Bertola, G., Serraino, D., Carbone, A., and Monfardini, S. (1992) Hodgkin's disease in 92 patients with HIV infection: The Italian experience. *Ann. Oncol.* **3** (Suppl. 4), 69-72.
- Tirelli, U., Errante, D., Dolcetti, R., Gloghini, A., Serraino, D., Vaccher, E., Franceschi, S., Boiocchi, M., and Carbone, A. (1995) Hodgkin's disease and human immunodeficiency virus infection: clinicopathologic and virologic features of 114 patients from the Italian Cooperative Group on AIDS and Tumors. *J. Clin. Oncol.* **13**, 1758-1767.
- Tubiana, M., Henry-Amar, M., Van der Werf-Messing, B., Henry, J., Abbatucci, J., Burgers, M., Hayat, M., Somers, R., Laugier, A., and Carde, P. (1985) A multivariate analysis of prognostic factors in early stage Hodgkin's disease. *Int. J. Radiat. Oncol. Biol. Phys.* **11**, 23-30.
- Walgraeve, D., Verhoef, G., Stul, M., Cassiman, J.J., Mecucci, C., Van den Berghe, H., and Boogaerts, M. (1991) Chronic myelogenous leukemia after treatment with I131 for thyroid carcinoma: Report of a case and review of the literature. *Cancer Genet. Cytogenet.* **55**, 217-224.
- Wood, N.L., and Coltman, C.A. (1973) Localized primary extranodal Hodgkin's disease. *Ann. Int. Med.* **78**, 113-118.
- Zimmerman, H.M. (1975) Malignant lymphomas of the nervous system. *Acta Neuropathol. (Berl.)* (Suppl. 6), 69-74.