

# Reversible, strokelike migraine attacks in patients with previous radiation therapy

J. D. Bartleson,<sup>1</sup> Karl N. Krecke, Brian P. O'Neill, and Paul D. Brown

Departments of Neurology (J.D.B., B.P.O.) and Radiology (K.N.K) and Division of Radiation Oncology (P.D.B.), Mayo Clinic, Rochester, MN 55905, USA

We report 2 adults with a past history of radiation therapy to the head for malignancy (one with primary B-cell lymphoma confined to the skull and the other with multiple hemangioendotheliomas) who developed episodes consistent with migraine with and without aura. In addition to more typical migraine attacks and beginning many years after their radiation therapy, both patients have experienced infrequent, stereotyped, prolonged, reversible neurologic deficits associated with headache, occasional seizures, and striking, transient, cortical gadolinium enhancement of the posterior cerebral gyri on MRI. Interictal MRI brain scans show stable abnormalities consistent with the patients' previous radiation therapy. The neurologic deficits often progressed over a few days, sometimes lasted weeks, and completely resolved. Electroencephalograms did not show epileptiform activity. Thorough investigation showed no residual or recurrent tumor and no recognized cause for the patients' attacks.

We postulate a causal relationship between the patients' remote radiation therapy and their prolonged, strokelike migraine attacks. Radiation-induced vascular changes could provoke the episodes, with or without an underlying migraine diathesis. Recognition of this syndrome can help avoid invasive testing. *Neuro-Oncology* 5, 121–127, 2003 (Posted to *Neuro-Oncology* [serial online], Doc. 02-040, February 24, 2003. URL <http://neurooncology.mc.duke.edu>)

Recurrent, prolonged, strokelike episodes in young and middle-aged adults are cause for concern, especially if there is a history of malignancy and radiation therapy to the head. We report 2 adult patients with a remote history of radiation to the head for malignancy who experienced recurrent, prolonged episodes of focal neurologic deficits preceded by migrainous phenomena. The episodes were sometimes associated with seizures and with fleeting, striking MRI scan abnormalities affecting the parieto-occipital cortex unilaterally. We postulate that our patients' episodes are due to an adverse effect of the radiation therapy, probably coupled with a migrainous diathesis.

## Methods and Materials

Mayo and outside records and imaging studies for 2 adult patients were reviewed. Both cases have been followed at Mayo for decades. Both patients gave their consent to report their medical experience.

## Results

### Patient 1

A 30-year-old, right-handed woman (previously reported in part by Friedenberg and Dodick [2000]) presented to Mayo Clinic Rochester in 1976 for evaluation of an enlarging, tender left occipital lump. She had a history of frequent headaches dating to childhood. For the 6 months prior to presentation, she had had an increase in her headaches, which would start in the left occipital region and move to a right or left retro-orbital location. The patient's mother, maternal grandfather, and two brothers had a history of migraine. Neurologic examination was normal. A skull radiograph showed a large lytic lesion involving the left occipital bone that extended across the

Received October 17, 2002; accepted December 31, 2002.

<sup>1</sup> Address correspondence and reprint requests to J. D. Bartleson, Mayo Clinic Department of Neurology, 200 First Street Southwest, Rochester, MN 55905 (bartleson.john@mayo.edu)

<sup>2</sup> The abbreviation used is as follows: EEG, electroencephalogram.

midline, laterally to the left mastoid air cells, and downward to the margin of the foramen magnum. Biopsy showed a diffuse large B-cell lymphoma of bone. A staging work-up was completely negative for involvement of other areas. The patient was treated with a linear accelerator using 4-MV photons to deliver a total dose of 5000 cGy to the midplane over 25 fractions. A split-course technique was employed, with a 25-day break after 12 treatments, and the radiation treatments were completed January 7, 1977. Parallel opposed lateral fields measuring 10 x 17 cm were used, which encompassed the entire cerebellar hemispheres, the occipital lobes, the vast majority of the parietal lobes, and a portion of the temporal lobes. Compensating blocks were added to the last few treatments to provide a more homogenous dose distribution. There has been no evidence of recurrent lymphoma to date.

The patient's headaches continued. When seen in 1995 at age 49, she reported throbbing hemicranial headaches, left side more frequent than right, accompanied by nausea and light and noise sensitivity. The headaches lasted a few hours to a few days, occurred once or twice a month, and were associated with menses and ovulation and relieved by sumatriptan. With 1 episode, she lost vision for 30 min before one of her typical migraine headaches. She also had nearly daily tension-type headaches. Neurologic examination remained normal. MRI brain scan showed several tiny foci of decreased T2 signal within the white matter of both parietal lobes, consistent with areas of hemosiderin or tiny cavernous hemangiomas, likely related to her prior radiation therapy, and several areas of increased T2 signal in the deep parieto-occipital white matter and pons that were possibly related to her previous radiation.

On September 18, 1997, the patient had a particularly severe right-sided migraine headache without aura. Over the next 3 days, the patient's family noted the gradual onset of confusion and left visual neglect. On September 24, the patient had a generalized seizure followed by confusion. A CT scan without contrast material and CSF examination were normal. An MRI brain scan on September 24 showed striking gadolinium enhancement in the right posterior temporo-parieto-occipital cortex (Fig. 1). The patient was hospitalized at Mayo for additional evaluation. On September 25, neurologic examination showed mild confusion, left homonymous hemianopia with some left-sided neglect, and mild impairment of tandem gait. Repeat CSF examination was normal. An electroencephalogram (EEG)<sup>2</sup> showed right posterior slowing without epileptiform activity. Infarction, radiation effect, and tumor were considered as possible etiologies. A follow-up MRI scan on September 29 showed near-complete resolution of the abnormal enhancement (Fig. 2). The magnetic resonance angiogram was negative. The patient improved rapidly, and her visual fields were nearly normal when she was dismissed on September 30, 1997. Cognitive and visuospatial function gradually returned to normal over several weeks. She was placed on divalproex; sumatriptan was discontinued. She continued to have about 2 migraine attacks per month with rare visual aura.

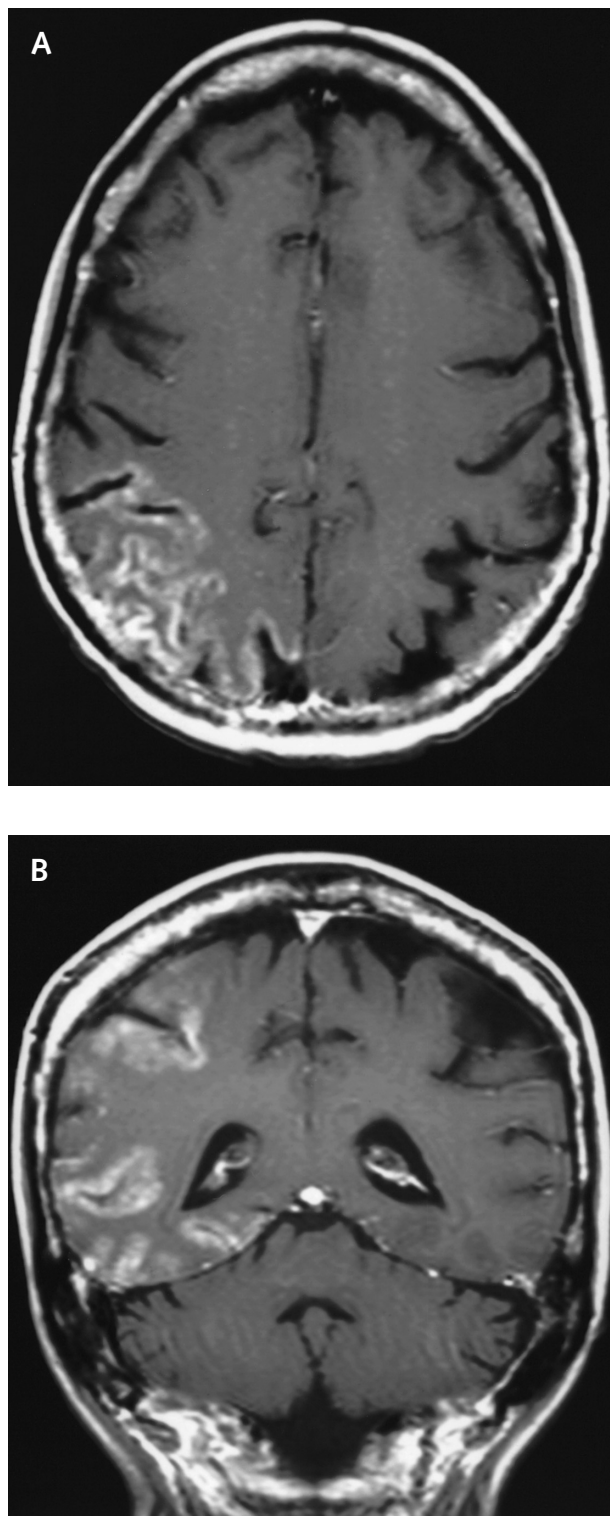


Fig. 1. Patient 1—MRI brain scan 6 days post-ictus. Axial (A) and coronal (B) T1-weighted images of the brain following intravenous administration of gadolinium. Gyriform enhancement of right posterior temporo-parieto-occipital cortex.

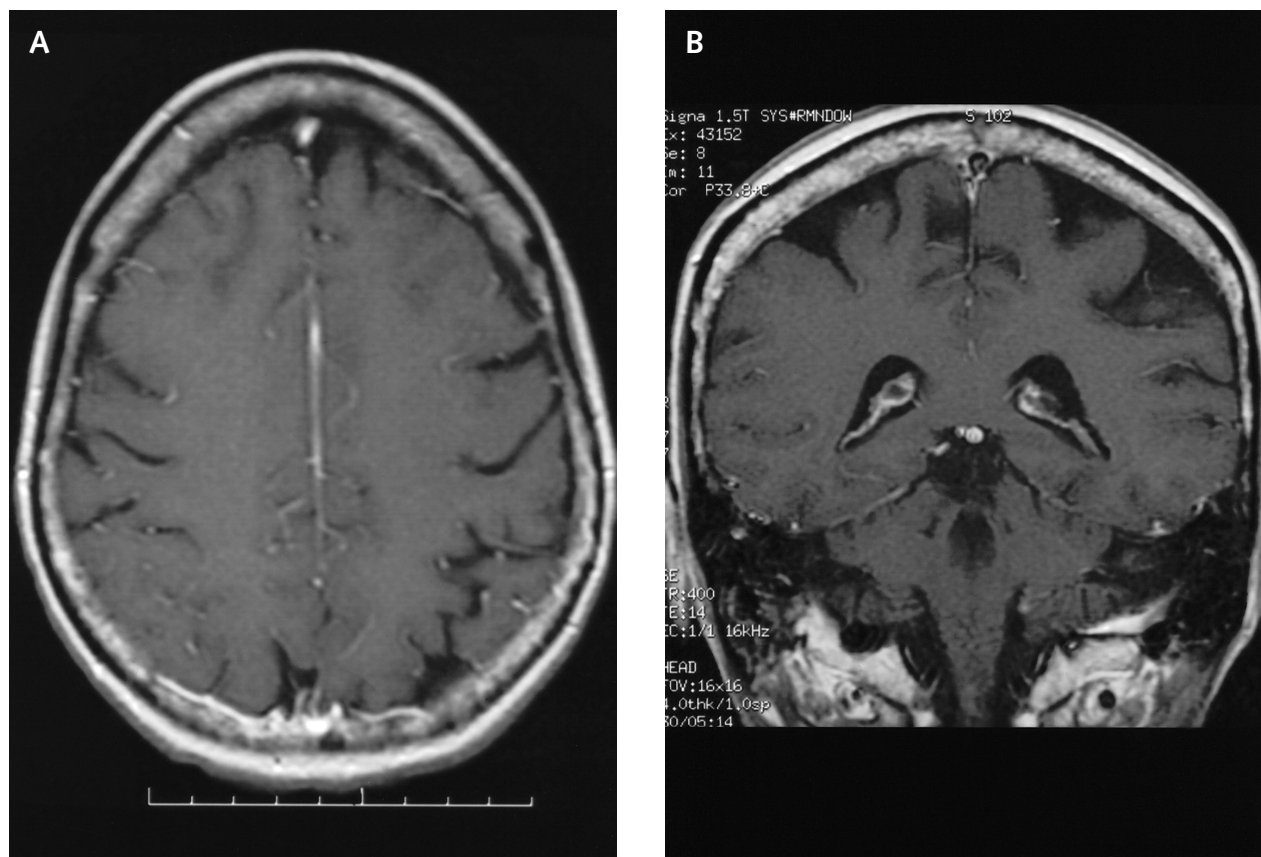


Fig. 2. Patient 1—MRI brain scan 11 days post-ictus. Axial (A) and coronal (B) T1-weighted images of the brain following intravenous gadolinium administration; anatomically matched to Figs. 1A and 1B. Near-complete resolution of abnormal cortical enhancement.

In August 2000, the patient was still having 2 migraine attacks per month, which could affect either side of the head. A follow-up MRI brain scan with magnetic resonance angiogram was stable.

On October 28, 2000, the patient developed a severe migraine headache that lingered for several days. On November 2, the patient had 2 generalized seizures. Her valproic acid level was low, and the divalproex dose was increased. She developed a left homonymous hemianopia and parietal-type sensory loss in her left hand. An MRI brain scan on November 4, 2000, showed a large area of cortical enhancement involving the right temporal, occipital, and parietal lobes in a distribution identical to that of the September 24, 1997, MRI examination. As she had in 1997, she gradually recovered over a matter of weeks.

At this time, the patient is 56 years old and continues to have her previous migraine-type headaches. When last seen, the patient's neurological examination was nearly normal. Bilateral parieto-occipital baldness was present and attributed to the patient's previous radiation therapy.

#### *Patient 2*

In 1978, this 23-year-old, right-handed man was seen for a 1-year history of progressive posterior column sensory

loss affecting first the left, then the right side of the body, followed by singultus and imbalance. Neurologic examination showed left greater than right posterior column sensory loss, positive Romberg's sign, left limb incoordination, lower limb hyperreflexia, and nystagmus on left lateral gaze. Investigation showed 2 left cerebellar hemangiopericytomas, a left third cervical spinal hemangiopericytoma, a first thoracic spinal hemangiopericytoma, and syringomyelia and syringobulbia. A diagnosis of von Hippel-Lindau disease was made in the patient and his mother. The 2 cerebellar and the cervical hemangiopericytomas were removed, and the syrinx was drained. The patient was treated with a linear accelerator using 4-MV photons with an initial posterior-anterior field that delivered 2340 cGy to a depth of 5 cm over 13 fractions. The initial field measured 32 x 17 cm and encompassed the entire cranial contents down to the second thoracic vertebral body. Parallel opposed lateral fields measuring 24 x 11 cm were then used for 15 fractions to boost the posterior cranium to a total dose of 5040 cGy. These fields encompassed the entire cerebellar hemispheres, the occipital lobes, the vast majority of the parietal lobes, and a portion of the temporal lobes. A small posterior-anterior field was matched to the parallel opposed lateral fields, and a total dose of 6100 cGy was delivered to the cervical and upper thoracic spine. The



radiation treatments were completed August 30, 1978. The patient improved, but some left-sided sensory loss and incoordination persisted.

Since the early 1980s, the patient has been subject to recurrent spells, which have worsened over time and are more likely to occur if he is fatigued. The episodes begin with a visual disturbance. He sees oblong, colored spots that are sometimes elongated "like snakes with dots inside," usually affect one-half of his vision, and are followed by scotomata. The visual episodes usually last about 15 min and are followed by numbness, tingling, and weakness on 1 side of the body, more often the left than the right. Sometimes, the patient's speech is affected with the episodes. There is no set sequence of symptoms, but there is a staggered onset for the visual, somatosensory, motor, and speech symptoms. Initially, the attacks lasted 2 h and were later sometimes followed by several hours of throbbing pain on the same side of his neck as his numbness and weakness. The patient reported occasional episodes of unilateral neck and separate head pain without associated neurologic symptoms. On 4 occasions from 1996 through 2000, the patient experienced similar but much more prolonged spells lasting many days to several weeks. Although he had had neck pain before his hemangiopericytomas were discovered in 1978, he had no past history of headaches prior to his initial neurosurgery and subsequent radiation therapy. One cousin had a positive history of migraine. (The patient has no siblings and no children.)

When his dominant hemisphere was affected with his attacks, he had accompanying Wernicke-type aphasia. With 2 of his more severe attacks, he had accompanying seizure activity.

An episode with onset on January 22, 2000, was typical. This episode was accompanied by right-sided weakness and Wernicke-type aphasia that progressed over the course of several days. An MRI brain scan on January 24, 2000, with and without gadolinium (Fig. 3), showed homogeneous cortical enhancement of the left parietal lobe, occipital lobe, and posterior margin of the left frontal lobe, with mild associated cortical T2 signal abnormality but little underlying white matter T2 signal abnormality. The patient experienced 2 generalized seizures on the third day of this attack, both of which occurred after the MRI brain scan had been obtained. The patient gradually recovered over several weeks. Tests for recurrent metabolic encephalopathy were normal. An EEG was not obtained with this episode. EEGs taken during other attacks showed decreased amplitude and intermittent slowing of the background over the affected hemisphere. Despite a history of seizures with 2 of the patient's more severe attacks, epileptiform activity has not been seen on EEG.

When last seen in October 2002, this now 47-year-old man was stable neurologically with spastic paraparesis, mild weakness of the left upper extremity, posterior column sensory loss in the left more so than right limbs, and decreased pin perception below about the second thoracic level bilaterally. In addition, there was bilateral severe parieto-occipital baldness secondary to the patient's previous radiation therapy. The patient had been spell-

free for more than 2 years on a combination of carbamazepine, verapamil, and warfarin, which had been started with his most recent episode for deep vein thrombophlebitis. A follow-up MRI brain examination in 2002 showed scattered areas of increased T2 signal in the white matter of both cerebral hemispheres, especially parieto-occipitally, and mild generalized cerebral and cerebellar atrophy. These interictal findings had been stable for at least 6 years and while nonspecific were attributed to the patient's prior radiation therapy.

## Discussion

With each of the more severe spells, appropriate testing has been performed in both patients to exclude stroke from various causes, subclinical seizure activity, and systemic disease. The striking MRI scan findings are transient, and MRI examinations were performed irregularly with respect to symptom onset. The MRI findings were seen between 2 and 8 days after attack onset.

The two patients share the following features:

- Remote history of therapeutic external beam cranial irradiation ( $\geq 5000$  cGy) for malignancy
- Long-standing migrainelike attacks both with and without aura (patient 1 had had headaches prior to her radiation therapy)
- The more recent development of prolonged episodes consistent with complicated migraine, sometimes accompanied by seizure activity early in the attack
- Transitory, intense gadolinium enhancement of posterior cerebral gyri with prolonged episodes on MRI (CT scans have not shown similar findings)
- Eventual complete recovery, sometimes taking as long as 4 to 7 weeks
- No evidence of residual or recurrent tumor

At the time of the acute attacks, diagnostic considerations have included tumor, prolonged seizure activity, cerebral infarction, remote effects of radiation, and prolonged, complicated migraine. Tumor was effectively excluded by imaging studies obtained at the time of the patients' attacks and subsequently.

Can the patients' constellation of symptoms and imaging findings be explained simply by the association of a severe migraine attack with a seizure (migralepsy) (Friedenberg and Dodick, 2000)? Although Patient 1 had 1 or 2 seizures associated with each of her episodes, Patient 2 had 1 or 2 seizures with only half of his events. Seizure activity did occur with all 3 of the attacks during which a gadolinium-enhanced MRI scan showed the characteristic cortical abnormality. With Patient 2's January 2000 attack, the abnormal MRI scan was obtained before his 2 generalized seizures. An EEG was not obtained during this attack. While MRI scan abnormalities have been reported in a patient with migraine and complex visual hallucinations associated with occipital epileptic discharges (Lindner et al., 1996), EEGs in our patients, when obtained, did not show epileptiform activity. Thus, they were not experiencing subclinical seizures that might

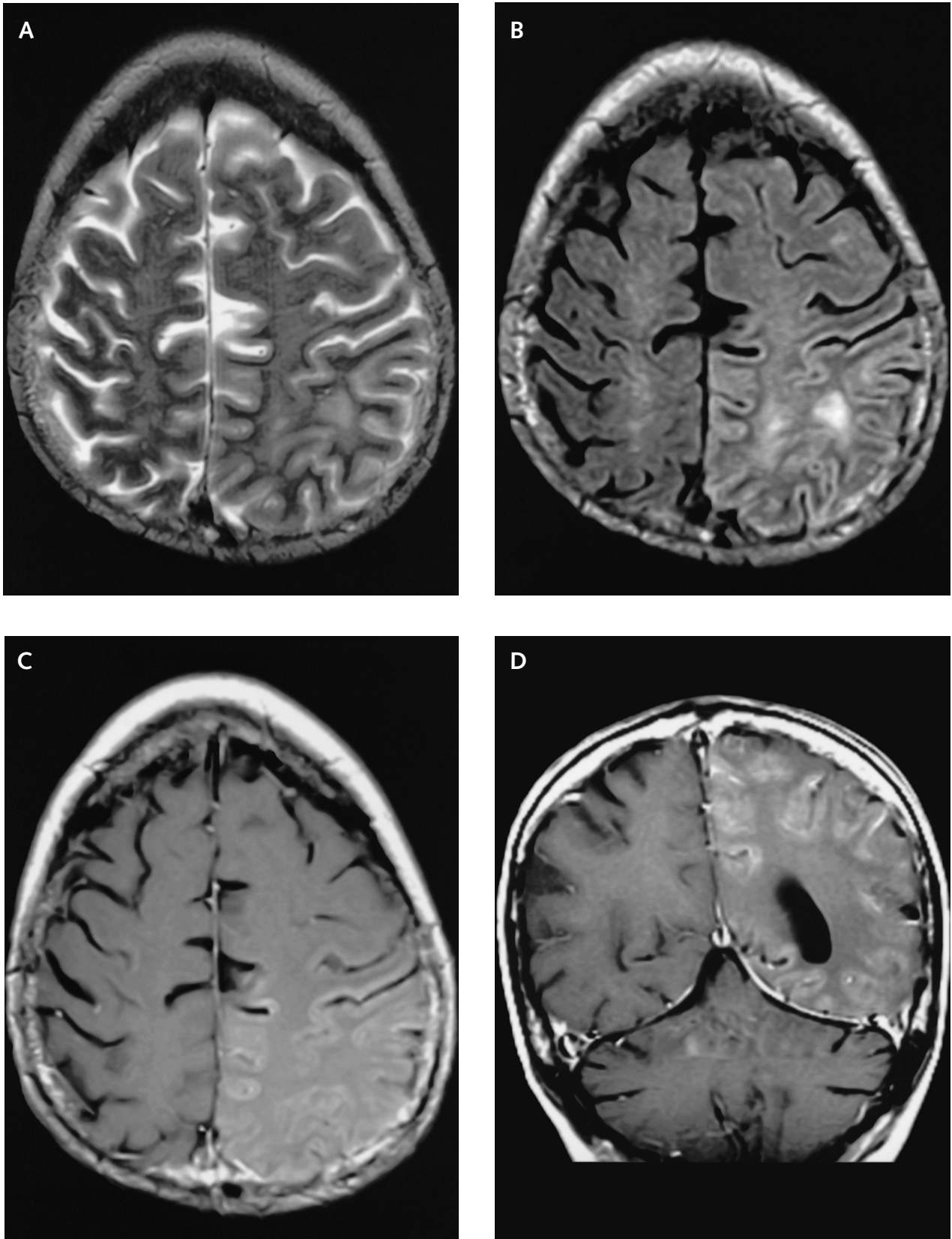


Fig. 3. Patient 2—MRI brain scan 2 days post-ictus. Axial T2-weighted fast spin-echo (A) and fluid-attenuated, T2-weighted fast spin-echo (B) images demonstrate increased T2 signal intensity in the left fronto-parietal region near the vertex, most prominently involving the cortex. Axial (C) and coronal (D) T1-weighted images following gadolinium administration. Gyriform enhancement of the left posterior temporo-parieto-occipital cortex, including pre-central and post-central gyri, matching the T2 signal abnormality. Subtle, less extensive enhancement of right fronto-parietal cortex.

help to explain the imaging findings and their prolonged neurologic deficits. We do not believe that 1 or 2 seizures can fully explain our patients' prolonged neurologic deficits or their MRI scan findings.

Both patients had extensive testing to look for a non-migrainous stroke mechanism, and none was found. Although neither patient underwent cerebral angiography, the MRI scan findings were beyond the bounds of a single vascular territory. While the right cerebral hemisphere was affected in both of Patient 1's prolonged attacks, Patient 2's episodes affected each hemisphere. The patients' recoveries without residual imaging abnormalities also argue against infarction. There was no evidence for an infectious or recognized inflammatory condition.

Could the patients' recurrent spells be related to their previous, significant radiation therapy? The late effects of radiotherapy have been blamed on vascular endothelial injury or on an effect on oligodendroglial cells and can include white matter changes or focal necrosis with mass effect or both (Levin et al., 2001; Posner, 1995). Late effects of radiation therapy also include large vessel occlusive vasculopathy, hypothalamic-pituitary dysfunction, and secondary neoplasia (Levin et al., 2001; Posner, 1995). In general, these late delayed effects of radiation therapy are gradual in onset, remain stable or slowly worsen, and can be associated with headache.

Following radiation therapy, late delayed transient episodes of neurologic symptoms associated with headache have not previously been described in adults but have been reported in children. Shuper et al. (1995) described "complicated migraine-like episodes" in 4 children 1 to 3 years after craniospinal radiation therapy and systemic chemotherapy for 1 pineal and 3 posterior fossa brain tumors. None of their patients had associated seizures, and the duration of neurologic symptoms was  $\leq 60$  min in each. Investigation showed no underlying cause for the attacks, and there was no family history of migraine in any of the patients, which led the authors to conclude that the migrainelike attacks were a sequela of the previous cranial radiation and chemotherapy. Our Patient 1 had headaches before her cranial radiation, but Patient 2 did not; both patients received radiation without chemotherapy, their headaches worsened over time, and their prolonged attacks did not begin until 21 and 18 years, respectively, after their radiation therapy. It is important to note this long interval between radiation therapy and the development of prolonged, strolkelike migraine attacks in our patients. Radiation therapy to the head is usually given, as it was in our patients, for serious malignancies, and many patients do not survive for decades afterward. If these reversible, strolkelike migraine attacks are related to remote radiation therapy, this relationship may be underrecognized because many of the patients do not live long enough to experience the episodes.

Additional evidence that radiation can provoke headaches comes from the experience with gamma knife radiosurgery. This technique has been reported to cause migrainelike vascular headaches (Rozen and Swanson, 1997).

Could our patients' episodes represent complicated

migraine? Stroke is a recognized, albeit rare complication of migraine, and migraine with or without a history of stroke can be associated with brain MRI abnormalities (Cooney et al., 1996). Unusual white matter enhancement in migraine with aura (Arnold et al., 1998) and unusual cortical abnormalities in hemiplegic migraine (Barbour et al., 2001; Hayashi et al., 1998) and in basilar artery migraine (Maytal et al., 1998) have been reported, but gadolinium gyral enhancement has not to our knowledge. Seizures can be associated with migraine (Friedenberg and Dodick, 2000; Welch and Lewis, 1997). When epilepsy and migraine occur together, the episodes are not usually prolonged. The combination of migrainelike attacks associated with gyral enhancement and prolonged neurologic impairment, sometimes accompanied by seizure activity, seems to be unique.

We postulate that there is a relationship between the patients' remote radiation therapy and the development of their prolonged, migrainelike attacks. Although Patient 1 had headaches consistent with migraine without aura for several years prior to receiving radiation therapy, neither patient had migraine with aura until years after their radiation had been administered. We speculate that radiation-induced endovascular changes could induce migrainelike headaches or, alternatively, aggravate a pre-existing tendency to migraine and result in the unusual, prolonged spells described herein. The radiation therapy could cause injury to the trigeminovascular system, which is thought to be related to migraine pathophysiology. A patient with a personal history or family history of migraine or both (such as Patient 1) might be at greater risk for developing this syndrome as a consequence of radiation therapy. As noted above, there is support for a similar entity in children, although none of their attacks were prolonged (Shuper et al., 1995). In this regard, we have seen 2 young adults in their twenties who developed episodes of migraine with aura whose deficits were severe but short-lived; the patients' attacks began 1 to several years following radiation therapy for brain malignancies. It is of note that Shuper's 4 patients, the 2 patients we report here, and the 2 young adults we have observed have all had their skull or brain tumor in the posterior aspect of the cranium. Presumably, the posterior aspect of the brain received more radiation; the parieto-occipital cortex seems to be especially prone to developing migrainous symptoms.

Is this a recognizable syndrome in patients with remote radiation therapy? We believe that it is but point out that the striking MRI findings are transient, usually beginning a few days after the onset of symptoms and then disappearing. We cannot be certain that the imaging abnormalities always occur. We believe that the syndrome is recognizable even if the MRI scan findings are not observed. Additional experience is needed, and we encourage providers to be aware of this possible syndrome. Recognition of such a syndrome, if it exists, can obviate the need for invasive testing such as cerebral angiography or brain biopsy. In this regard, it is important to note that all 3 of Shuper's patients who underwent cerebral angiography had complications consisting of severe headache, delirium, and cortical blindness lasting up to 48 h (Shuper et al., 1995).

## Conclusions

Our limited experience precludes us from making any hard recommendations with regard to therapy. Medications such as antiplatelet agents aimed at reducing the risk of stroke should be considered, along with anticonvulsants that have been shown to help prevent migraine attacks. Our Patient 2 reported a decrease in the fre-

quency of his severe episodes while taking warfarin for a history of deep vein thrombophlebitis.

## Acknowledgment

The authors gratefully acknowledge the superb assistance of Linda A. Schmidt.

## References

- Arnold, G., Reuter, U., Kinze, S., Wolf, T., and Einhäupl, K.M. (1998) Migraine with aura shows gadolinium enhancement which is reversed following prophylactic treatment. *Cephalalgia* **18**, 644–646.
- Barbour, P.J., Castaldo, J.E., and Shoemaker, E.I. (2001) Hemiplegic migraine during pregnancy: Unusual magnetic resonance appearance with SPECT scan correlation. *Headache* **41**, 310–316.
- Cooney, B.S., Grossman, R.I., Farber, R.E., Goin, J.E., and Galetta, S.L. (1996) Frequency of magnetic resonance imaging abnormalities in patients with migraine. *Headache* **36**, 616–621.
- Levin, V.A., Leibel, S.A., and Gutin, P.H. (2001) Neoplasms of the central nervous system. In: DeVita, V.T., Jr., Hellman, S., and Rosenberg, S.A. (Eds.) *Cancer: Principles and Practice of Oncology*, 6th ed. Philadelphia: Lippincott, Williams & Wilkins, pp. 2114–2118.
- Friedenberg, S., and Dodick, D.W. (2000) Migraine-associated seizure: A case of reversible MRI abnormalities and persistent nondominant hemisphere syndrome. *Headache* **40**, 487–490.
- Hayashi, R., Tachikawa, H., Watanabe, R., Honda, M., and Katsumata, Y. (1998) Familial hemiplegic migraine with irreversible brain damage. *Int. Med.* **37**, 166–168.
- Lindner, A., Reiners, K., and Toyka, K.V. (1996) Meningeal hyperperfusion visualized by MRI in a patient with visual hallucinations and migraine. *Headache* **36**, 53–57.
- Maytal, J., Libman, R.B., and Lustrin, E.S. (1998) Basilar artery migraine and reversible imaging abnormalities. *Am. J. Neuroradiol.* **19**, 1116–1119.
- Posner, J.B. (1995) Side effects of radiation therapy. In: Posner, J.B., *Neurologic Complications of Cancer*. Philadelphia: F.A. Davis Company, pp. 311–337.
- Rozen, T.D., and Swanson, J.W. (1997) Post gamma knife headache: A new headache syndrome? *Headache* **37**, 180–183.
- Shuper, A., Packer, R.J., Vezina, L.G., Nicholson, H.S., and Lafond, D. (1995) 'Complicated migraine-like episodes' in children following cranial irradiation and chemotherapy. *Neurology* **45**, 1837–1840.
- Welch, K.M.A., and Lewis, D. (1997) Migraine and epilepsy. *Neurol. Clin.* **15**, 107–114.