

# Importance of MR technique for stereotactic radiosurgery<sup>1</sup>

Bernadine R. Donahue,<sup>2</sup> Judith D. Goldberg, John G. Golfinos, Edmond A. Knopp, Jessica Comiskey, Stephen C. Rush, Kerry Han, Vandana Mukhi, and Jay S. Cooper

Departments of Radiation Oncology (B.R.D., K.H., J.S.C.) and Neurosurgery (J.G.G., E.A.K., J.C.) and Division of Biostatistics (J.D.G., V.M.), New York University Medical Center, New York, NY 10016; Nassau Radiologic Group (S.C.R.), Garden City, NY 11530

We investigated how frequently the imaging procedure we use immediately prior to radiosurgery—triple-dose gadolinium-enhanced MR performed with the patient immobilized in a nonrelocatable head frame and 1-mm-thick MPRAGE (magnetization-prepared rapid gradient echo) images (SRS3xGado)—identifies previously unrecognized cerebral metastases in patients initially imaged by conventional MR with single-dose gadolinium (1xGado). Between July 1998 and July 2000, the diagnoses established for 47 patients who underwent radiosurgical procedures for treatment of cerebral metastases at The Gamma Knife Center of New York University were based initially on the 1xGado protocol. In July 1998, we began using SRS3xGado as our routine imaging protocol in preparation for targeting lesions for radiosurgery, using triple-dose gadolinium and acquisition of contiguous 1-mm T1-weighted axial images. Because our

SRS3xGado scans sometimes unexpectedly revealed additional metastases, we sought to learn how frequently the initial 1xGado scans would underestimate the number of metastases. We therefore reviewed the number of brain metastases identified on the SRS3xGado studies and compared the results to the number found by the 1xGado protocol, which had initially identified the brain metastases. Additional metastases, ranging from 1 to 23 lesions per patient, were identified on the SRS3xGado scan in 23 of 47 patients (49%). In 57% of the 23 patients, only one additional lesion was identified. The mean time interval between the 1xGado and the SRS3xGado scans was 20.6 days (range, 4–83 days), and the number of additional lesions detected and the time interval between two scans were negatively correlated (–0.11). The number of lesions detected on the SRS3xGado was associated only with the number of lesions on the 1xGado and not with any other patient or tumor pretreatment characteristics such as age, gender, largest tumor volume on the 1xGado, or number of days between the 1xGado and the SRS3xGado or prior surgery. The identification of additional lesions with SRS3xGado MR may have implications for patients who are treated with stereotactic radiosurgery alone (without whole-brain irradiation) with single-dose gadolinium imaging, in that unidentified lesions may go untreated. As a result of these findings we continue to use and advocate SRS3xGado scans for radiosurgery. *Neuro-Oncology* 5, 268–274, 2003 (Posted to *Neuro-Oncology* [serial online], Doc 03-004, August 27, 2003. URL <http://neuro-oncology.mc.duke.edu>; DOI: 10.1215/S1152-8517-03-00004-8)

Received January 29, 2003; accepted June 17, 2003.

<sup>1</sup> Supported in part by NCI Grant P30 CA16087 to the New York University Cancer Institute, Rita J. and Stanley H. Kaplan Comprehensive Cancer Center (J.D.G. and V.M.).

<sup>2</sup> Address correspondence to Bernadine Donahue, Department of Radiation Oncology, New York University Medical Center, 566 First Avenue, Room HC107, New York, NY 10016 (bernadine.donahue@med.nyu.edu).

<sup>3</sup> Abbreviations used are as follows: 1xGado, conventional MR with single-dose gadolinium; df, degrees of freedom; MPRAGE, magnetization-prepared rapid gradient echo; RPA, recursive partitioning analysis; RTOG, Radiation Therapy Oncology Group; SRS, stereotactic radiosurgery; SRS3xGado, triple-dose gadolinium and acquisition of contiguous 1-mm MPRAGE T1-weighted axial images while the patient's head is immobilized in a nonrelocatable head frame; WBRT, whole-brain radiotherapy.

**M**ore than 100,000 patients in the United States are diagnosed each year as having cerebral metastases (Johnson and Young, 1996). Several

options for treatment need to be considered for these patients, but many studies have now documented the role of stereotactic radiosurgery (SRS)<sup>3</sup> in improving the local control of radiographically identified metastases in the brain (Alexander et al., 1995; Flickinger et al., 1994; Mehta et al., 1992).

Gamma knife SRS uses primarily MR for targeting of lesions. Because MR imaging requires interpretation, technique may influence outcome. For example, the use of triple-dose gadolinium-enhanced, 1-mm-thick images and/or volume acquisition may increase the sensitivity of lesion detection. Because we were concerned about potential underestimation of the extent of lesions, beginning in July 1998, our routine imaging protocol in preparation for targeting lesions for radiosurgery has used triple-dose gadolinium and acquisition of contiguous 1-mm magnetization-prepared rapid gradient echo (MPRAGE) T1-weighted axial images while the patient's head is immobilized in a Leksell (Elekta, Norcross, Ga.) non-relocatable head frame (SRS3xGado). At the 2000 meeting of The American Radium Society, we presented our unexpected initial finding with the use of this protocol—additional metastases in patients for whom brain metastases had been identified on conventional MR with single-dose gadolinium (1xGado) (Donahue et al., 2000). In this, the first full report of our experience, we include additional cases, evaluate the factors that may be related to the likelihood of detecting additional lesions, and present information not reported previously.

## Materials and Methods

In July 1998, we routinely began to use triple-dose gadolinium for MR planning for SRS. This was prompted by our concern that some patients were refusing the addition of whole-brain radiation, thereby increasing the importance of detection of “small” metastases for SRS targeting. There were studies addressing the usefulness of triple-dose gadolinium versus magnetization transfer in the detection of metastases (Knauth et al., 1996; Thng et al., 1999). Magnetization transfer would be problematic in a head frame, and triple-dose is not. Since the efficacy of the two techniques is equivalent, we decided to use triple-dose gadolinium.

We reviewed the MR scans of 93 patients treated with SRS because of parenchymal brain metastases at The Gamma Knife Center of New York University between July 1998 and July 2000 to determine how frequently SRS3xGado identified additional brain metastases as compared with 1xGado. In addition, one patient who had received triple-dose gadolinium for targeting earlier in 1998 was included in the analysis.

Only 63 patients of the 94 received 1xGado at their initial diagnosis. We identified 47 patients of these 63 for whom 1xGado had been performed to diagnose brain metastases and for whom a SRS3xGado had been done for SRS planning. The other 16 patients were not included for the following reasons: the initial MR was done on an open MR machine (2 patients), the SRS planning study was a CT because of the presence of a pacemaker (2

patients), or the SRS study could not be independently confirmed to be a triple-dose study (12 patients).

To decrease the likelihood that the initial 1xGado films had been underinterpreted, the number of brain metastases initially observed was first recorded from the diagnostic radiology report and/or the radiation oncologist's consultation note. In all cases this number had been obtained from conventional T<sub>1</sub>- and T<sub>2</sub>-weighted MR imaging with single-dose gadolinium. If there was a disagreement between the diagnostic report and the radiation oncologist's review of the film, the greater number of lesions was recorded. The initial 1xGado films were then reviewed by a neurosurgeon (JG) and a neuroradiologist (EK) and compared to the targeting films (Figs. 1 and 2) to confirm that the additionally discovered lesions were not evident even in retrospect. Patient and tumor characteristics at the initial scan were recorded from the radiation oncologist's consultation note.

SRS3xGado imaging was performed with the Leksell stereotactic frame in place using triple-dose gadolinium (0.3 mmol/kg) and acquisition of contiguous 1-mm T<sub>1</sub>-weighted MPRAGE axial images (2nex, 512 × 256 matrix, 250 × 250 field of view). We documented the number of brain metastases identified on this study by the same neurosurgeon and neuroradiologist as recorded in the SRS procedure note and compared this to the number of initially identified lesions. The change in lesion number from the 1xGado to the SRS3xGado study was examined in relation to both patient and tumor characteristics, as well as to the length of time between both MR studies. Volumetric measurements were made of treated lesions at the time of the SRS3xGado study. Thus, the volume of the originally identified metastases, that is, the lesion(s) seen on the 1xGado study, was actually measured on the day of the SRS3xGado study. Not all additionally identified lesions were treated, and therefore not all of them were measured.

## Statistical Methods

Patient characteristics at the initial scan were recorded, and the changes in lesion numbers from the 1xGado to the SRS3xGado were examined in relation to initial characteristics using exact tests for contingency tables (StatXact 4, 2000, Cytel Software Corporation, Cambridge, Mass.). No adjustments were made for multiplicity, and *P*-values were used only as a screen. We used *t*-tests and nonparametric tests as appropriate to examine the length of the time interval between the 1xGado and the SRS3xGado MR and largest tumor volume in relation to other baseline characteristics. We fit regression models with all variables, as well as with each variable individually, to further explore the interrelationship among the characteristics at the initial scan, number of lesions identified on the 1xGado, and number of lesions identified on the SRS3xGado. For these exploratory regression analyses, 0.1 was used as the significance level for variables to enter and to be retained. We performed all of these analyses using SAS, version 8.2 (2002) (SAS Institute, Inc., Cary, N.C.).

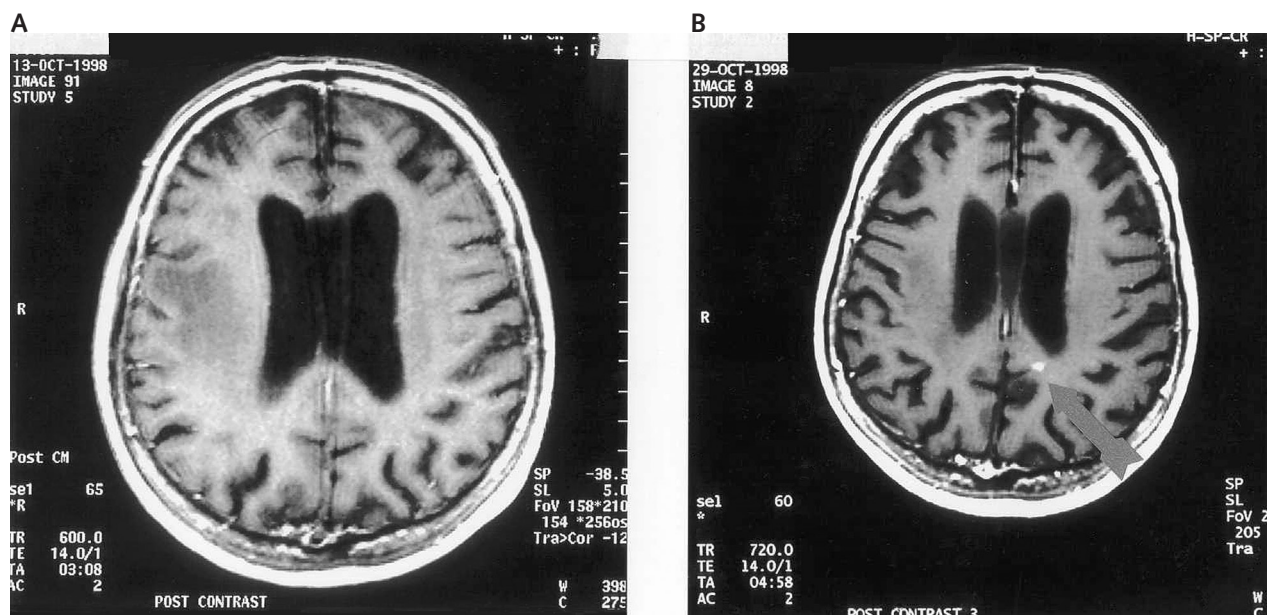


Fig. 1. MR imaging to reveal lesion in left occipital lobe. A. Conventional MR with single-dose gadolinium. B. Triple-dose gadolinium-enhanced MR on the day of gamma knife planning reveals a contrast enhancing lesion in the left occipital lobe (immediately posterior to the ventricle) that was not visualized on the conventional study 2 weeks earlier.

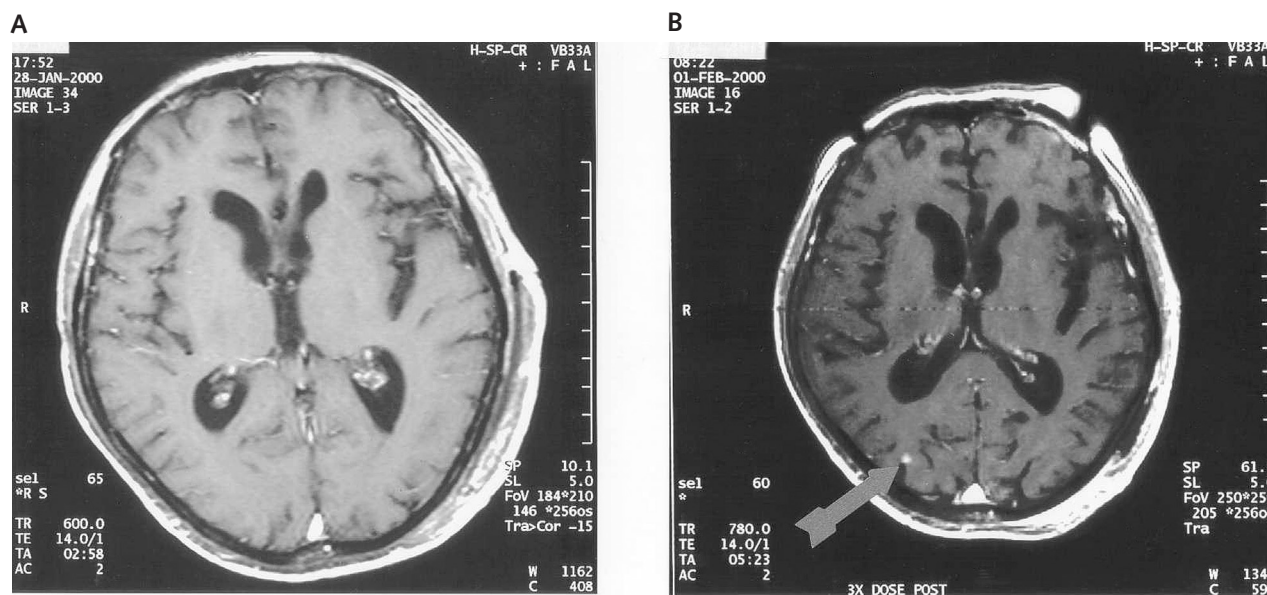


Fig. 2. MR imaging to reveal lesion in right occipital pole. A. Conventional single-dose gadolinium enhanced MR at time of initial evaluation. B. Triple-dose MR obtained on day of gamma knife planning (as evidenced by fiducials) showing a contrast enhancing lesion in the right occipital pole that was not visualized 4 days earlier on conventional imaging. Review of this lesion in sagittal and coronal imaging verified that this was not a vessel.

### Results

Table 1 presents the characteristics of the 47 patients at the time of the first scan. The mean age of patients was 59 (SD = 11.5 years, range 28–84 years).

The mean time interval between the 1xGado and SRS3xGado study was 20.6 days (SD = 15.6, range 4–83 days). For the 25 patients who had prior radiation therapy, the mean interval of 26.8 days was significantly

longer than the mean interval of 13.6 days for the 22 patients without prior radiation (adjusted for unequal variances;  $t = -3.3$ ,  $P$ -value = 0.002, degrees of freedom [df] = 32.1).

The 4 patients with prior gamma knife radiosurgery had (on average) a smaller largest tumor volume on 1xGado of 0.33 cm<sup>3</sup> compared with 1.66 cm<sup>3</sup> among 43 patients without prior gamma knife radiosurgery (adjusted for unequal variances;  $t = 3.6$ ,  $P$ -value = 0.0015, df = 23.2).

**Table 1.** Baseline characteristics of 47 patients at the time of conventional 1xGado MR

Baseline characteristics	Categories	Patients	
		Number	Percent
Gender	Female	27	57.4
	Male	20	42.6
Histology	Lung	20	42.6
	Breast	11	23.4
	Melanoma	8	17.0
	Renal	4	8.5
	Other	4	8.5
Solitary/Multiple	Solitary	9	19.2
	Multiple	38	80.8
RTOG RPA Class	I	14	29.8
	II	30	63.8
	III	3	6.4
Location of lesions on 1xGado MR	Supratentorial	39	83
	Infratentorial	3	6.4
	Both	5	10.6
Prior WBRT	No	22	46.8
	Yes	25	53.2
Prior Surgery (unknown in 1 patient)	No	31	67.4
	Yes	15	32.6
Prior SRS	No	43	91.5
	Yes	4	8.5

Abbreviations: Gado, gadolinium; RPA, recursive partitioning analysis; RTOG, Radiation Therapy Oncology Group; SRS, stereotactic radiosurgery; WBRT, whole-brain radiotherapy.

Sixty-eight additional metastases (range of lesions per patient, 1–23) were identified on the SRS3xGado in 23 of the 47 patients (49%). Only one additional lesion was identified in 57% of the 23 patients. However, one patient had an increase of 23 lesions at SRS3xGado, one patient had an increase of 7, and one patient had an increase of 8.

We determined the largest tumor identified by SRS3xGado and treated and the largest tumor identified by 1xGado and treated (Fig. 3). The mean volume of the largest tumor in lesions identified on 1xGado that were treated was 1.55 cm<sup>3</sup> (range 0.004–9.9 cm<sup>3</sup>) as measured on the day of radiosurgery, that is, when the SRS3xGado study was obtained. This compares with a mean of 0.144 cm<sup>3</sup> (range 0.007–0.719 cm<sup>3</sup>) of largest tumor volume of additional lesions identified on SRS3xGado and treated. The average volume of the lesions additionally identified on SRS3xGado and treated was 0.133 cm<sup>3</sup> (range 0.003–0.719). This compares with an average lesion volume of 1.23 cm<sup>3</sup> (range 0.0041–9.9 cm<sup>3</sup>) on the 1xGado.

The number of additional lesions found by time interval between the 1xGado procedure and the SRS3xGado imaging procedure is shown in Fig. 4. For the 23 of 47 (49%) cases with additional metastases, the mean time interval between the 1xGado and the SRS3xGado of 18.6 days (range 4–83 days) was not significantly different from the mean time interval of 22.5 days (range

5–55 days) in cases without additional lesions ( $t = 0.86$ ,  $P$ -value = 0.39,  $df = 45$ ).

An exact test for contingency tables was used to examine the baseline classification variables (gender, histology, solitary/multiple, prior radiation, prior surgery, prior gamma knife, and RPA class) by change in lesion number (no change [i.e., 0], 1, 2, 3,  $\geq 4$ ). In no case was there any significant difference in the increase in number of lesions by these characteristics (exact  $P$ -values  $\geq 0.28$ ).

We used regression procedures to explore the relationship between number of lesions on the SRS3xGado and age, gender, largest tumor volume on the 1xGado, interval days between the 1xGado and the SRS3xGado, number of lesions on the 1xGado, and prior surgery. Regardless of procedures used for model selection (forward, backward, stepwise, all subset), for the 47 observations in the data set, the only variable that was a significant predictor of the number of lesions on the SRS3xGado was the number of lesions on the 1xGado ( $F$ -value = 8.30,  $P$ -value = 0.006,  $df = [1,44]$ ). Patients who had a greater number of lesions seen on their 1xGado scan were more likely to have additional lesions detected by SRS3xGado. Also, 47% of the variability in number of lesions detected at 3xGado was explained by the number of lesions at 1xGado.

Furthermore, when the number of lesions on the 1xGado was not included in the model, no variable met the 0.1 significance level for entry into the model. Because one patient had 25 lesions identified on the SRS3xGado and the change in lesion number may have had an undue influence on the results, we removed the outlying observation and refit the models. Again, the number of lesions on the 1xGado ( $F$ -value = 39.32,  $P$ -value < 0.0001,  $df = [1,43]$ ) was the only variable that significantly contributed to the model.

### *Influence of SRS3xGado on Treatment*

A total of 91 lesions were identified initially by 1xGado. With the SRS3xGado, an additional 68 (total of 159 lesions) were detected. Eighty-eight percent of the lesions identified by 1xGado were treated, and 40% (27/68) of the additionally identified lesions were treated. Of the 23 patients in whom additional lesions were identified, 18 patients had all additionally identified lesions treated, one patient had 2 of the 3 additionally identified lesions treated, and 4 patients had none of the additionally identified lesions treated. No patient received immediate postradiosurgery whole-brain radiotherapy (WBRT), although 8 patients had previously been treated with WBRT. In the remaining 4 patients who had 2 to 23 additional lesions, only the 1 to 3 (median = 2) largest and/or most neurologically threatening metastases identified on 1xGado were treated, and no additionally identified lesions were treated. Two of these 4 patients had prior WBRT and received supportive care following SRS. The patient who was found to have 23 additional lesions had previously refused WBRT and had elected to proceed with SRS alone. After the findings on the SRS3xGado study were reviewed with this patient, he agreed to WBRT.

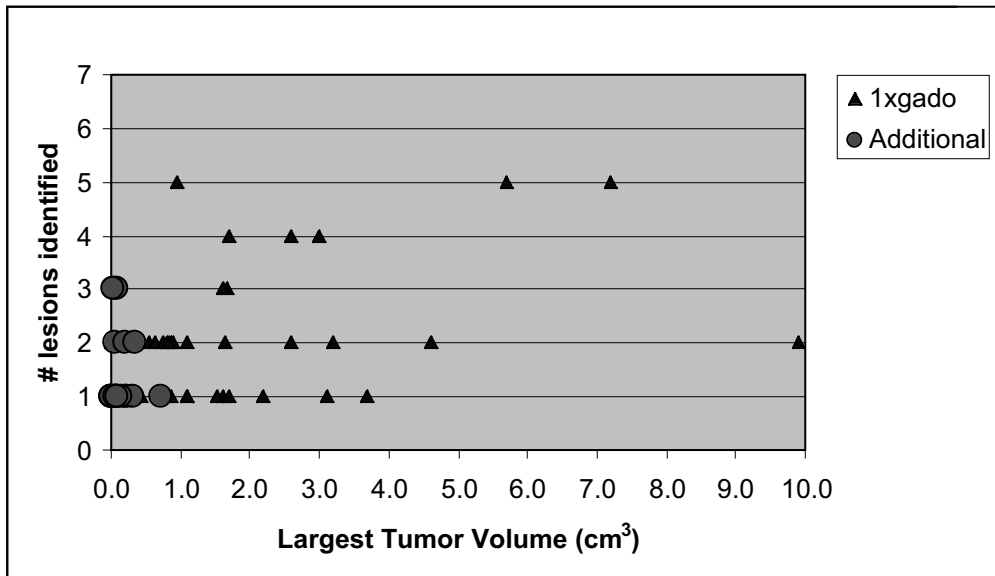


Fig. 3. Largest tumor volume versus the number of lesions identified, classified by whether they were identified on 1xGado or as additional lesions on 3xGado.

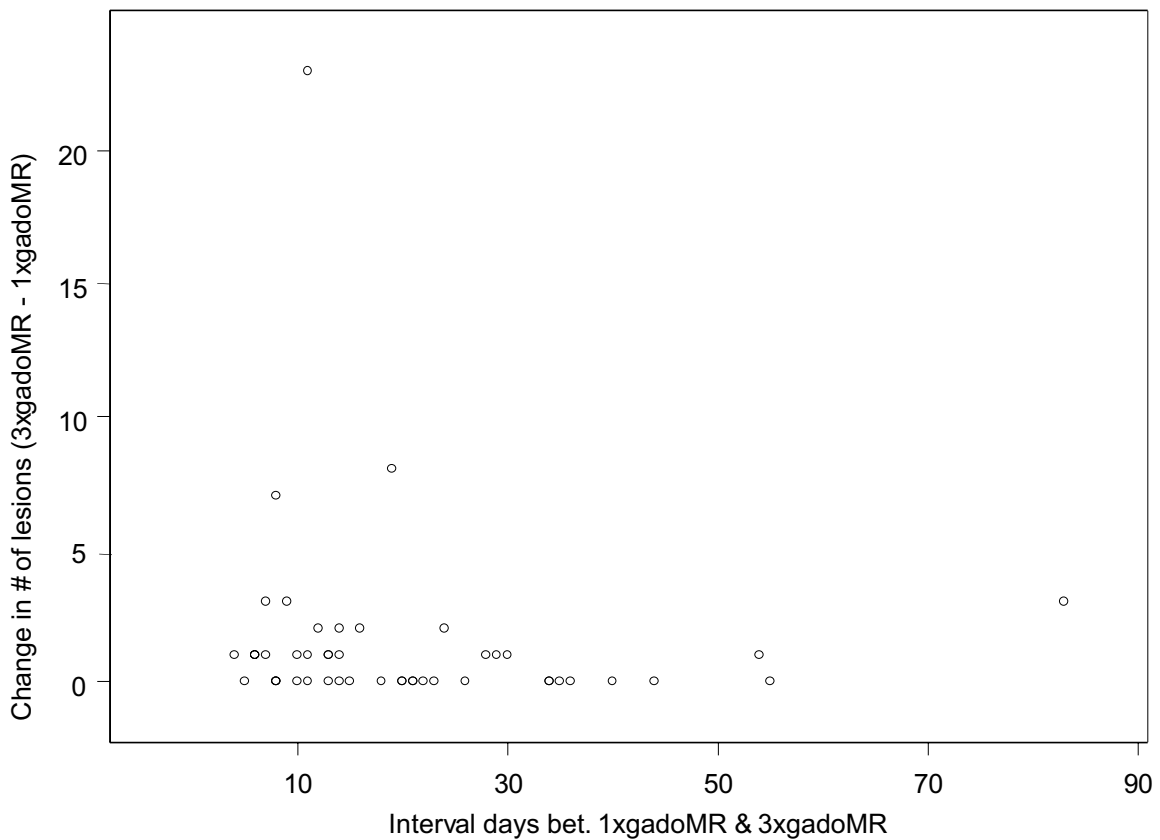


Fig. 4. Change in number of lesions between 1xGado and SRS3xGado MR by time interval between 1xGado and SRS3xGado MR (days).

## Discussion

Whole-brain radiation therapy traditionally has been delivered to eradicate or at least retard the growth of microscopic (i.e., radiographically invisible) disease in the brain, as well as to palliate the effects of visible metastases. Standard treatment has been 30 Gy delivered in 10 daily fractions, and median survival usually has been only 4 to 6 months following this treatment. Delivered in this fashion, WBRT historically has been thought to have only approximately a 50% chance of resulting in complete regression of even “small” metastases (Nieder et al., 1997). However, more recent data from the Radiation Therapy Oncology Group (RTOG) suggests that local control with WBRT may be approximately 70% (Sperduto et al., 2002). Relatively recently, SRS has been shown to improve the local control of radiographically identified metastases in the brain (Alexander et al., 1995; Flickinger et al., 1994; Mehta et al., 1992), and a recent multi-institutional analysis of patients with brain metastases treated with SRS suggests that, when stratified according to RTOG recursive partitioning analysis (RPA) classification, the SRS-treated patients have improved survival (Sanghavi et al., 1999). Furthermore, a phase 3 randomized trial from the RTOG has shown improved survival in specific subsets of patients with brain metastases when SRS has been added to WBRT (Sperduto et al., 2002). However, the success of SRS is dependent on appropriate identification and targeting of individual brain metastases. Thus, accurate radiographic imaging is of prime importance in SRS treatment planning. Furthermore, if consideration is given to avoiding whole-brain irradiation, and treatment entails SRS *alone* to the radiographically identified metastases, high-resolution radiographic imaging is necessary to avoid “missing” metastases.

Gamma knife SRS uses primarily MR for identification and targeting of lesions. Many linear accelerator-based radiosurgical systems also rely on MR for SRS planning. Single-dose conventionally acquired gadolinium MR has traditionally been used for these studies. It has been suggested that the use of high-dose contrast agent and an optimized imaging protocol facilitates imaging of brain metastases (Fellner et al., 1998). One study from Singapore showed that conventional T<sub>1</sub>-weighted triple-dose scans detected 19% (5/26) more lesions than conventional T<sub>1</sub>-weighted single-dose scans (Thng et al., 1999). Although triple-dose gadolinium may not increase the yield of lesions detected when it is employed as a screening tool (Sze et al., 1998), it has been shown to increase the identification of brain metastases at least as well as magnetization transfer (Knauth et al., 1996; Thng et al., 1999).

Our study suggests that the use of triple-dose gadolinium in conjunction with 1-mm MPRAGE data acquisition identified additional metastases in nearly half the patients undergoing this imaging protocol. This is in keeping with Patchell's finding of the development of intracranial metastases outside the surgical site in 37% of patients who had single metastasis treated with surgery alone (Patchell et al., 1998). We identified additional lesions despite the use of MPRAGE, which might be

expected to result in decreased conspicuity of lesions (Knopp et al., 1993).

The finding of additional lesions was not related to any of the examined pretreatment patient or tumor characteristics, with the exception that the number of lesions identified on the initial conventional single-dose MR was predictive of the number of lesions identified on the triple-dose study. After deleting the outlying observation, 47% of the original variability in the lesion number on the SRS3xGado was explained by the number of lesions on the 1xGado (correlation coefficient = 0.689). Of interest was the finding that the length of time between the MR studies, in this series, was not related to the finding of additional metastases. This may be surprising given that, from a biologic perspective, one might expect interval development of additional brain metastases with a delay in rescanning. Alternatively, if it is true that once gross brain metastases are recognized, all of the metastases that are going to develop are already present and just not visualized with standard radiological techniques, it would not be unexpected that such detailed scans identify so many other lesions. With 2 samples of size 23, an average difference of 13 days between 1xGado and SRS3xGado MR would be detectable between patients with and without additional metastases at alpha = 0.05 and power of 80%; alternatively, 244 patients would be required in each of the 2 groups for an observed average difference of 4 days to be detectable. With 47 patients, we have 80% power to detect a difference of  $\pm 0.395$  between the null hypothesis correlation of 0.00 and the alternative hypothesis correlation of 0.395 between the number of lesions by the SRS3xGado and the number of lesions by the 1xGado, using a 2-sided hypothesis test with a significance level of 0.05.

We do not know if the high rate of additional metastases in our study is a result of the high dose of contrast, the volume acquisition nature of the studies, the immobilization in a head frame allowing for the acquisition of 1-mm slices without motion artifact, or a combination of the above resulting in improved conspicuity of lesions. Given that the mean volume of the additional lesions that were visualized and treated on our SRS3xGado studies was only 0.133 cm<sup>3</sup> (range 0.003–0.719 cm<sup>3</sup>), the possibility exists that some of the additional lesions identified and treated on the SRS studies were “overinterpreted” as metastases (i.e., false positives). Triple-dose gadolinium may yield improved sensitivity in detecting lesions, but it may be at the cost of an increased false positive rate (Sze et al., 1998). It will be difficult to determine if the additional lesions that we identified are all metastases and not artifact, because these small stereotactically treated lesions are not likely to progress during these patients' remaining survival. However, the studies that report high false positive rates with triple-dose gadolinium are usually screening studies or studies performed for patients with equivocal conventional single-dose MR, unlike our patients who had known brain metastases.

The finding of additional lesions is important for several reasons. First, some patients may not be treated with WBRT (which might adequately control undetected “small” metastases) because of concern about neurocog-

nitive damage or prior WBRT, or because certain protocols seek to evaluate SRS alone. In this setting it may be important to obtain the highest diagnostic accuracy possible. Patients who are identified as having additional lesions may need to reconsider or be reevaluated for WBRT. Furthermore, patients who are to undergo SRS should be made aware of the likelihood of finding

additional lesions nearly 50% of the time. Patients who have multiple metastases on single-dose studies are at particular risk of having more metastases than may be reasonably treated by SRS alone, as they are in the group in which we were most likely to detect additional lesions.

## References

- Alexander, E., 3rd, Moriarty, T.M., Davis, R.B., Wen, P.Y., Fine, H.A., Black, P.M., Kooy, H.M., and Loeffler, J.S. (1995) Stereotactic radiosurgery for the definitive, noninvasive treatment of brain metastases. *J. Natl. Cancer Inst.* **87**, 34–40.
- Donahue, B., Golfinos, J.G., Rush, S., Han, K., Holland, B., and Cooper, J.S. (2000) Detection of additional brain metastases with triple dose gadolinium for stereotactic radiosurgery. *Proc. 83rd Annu. Mtg. Am. Radium Soc.* **25** (abstract #31).
- Fellner, F., Lungenschmid, K., Fellner, C., Bohm-Jurkovic, C.H., and Bautz, W. (1998) Experiences with gadodiamide, a non-ionic contrast agent, in MRI of brain metastases. *Rontgenpraxis* **51**, 203–211.
- Flickinger, J.C., Kondziolka, D., Lundsford, L.D., Coffey, R.J., Goodman, M.L., Shaw, E.G., Hudgins, W.R., Weiner, R., Harsh, G.R., 4th, Sneed, P.K., and Larson, D.A. (1994) A multi-institutional experience with stereotactic radiosurgery for solitary brain metastasis. *Int. J. Radiat. Oncol. Biol. Phys.* **28**, 797–802.
- Johnson, J.D., and Young, B. (1996) Demographics of brain metastases. *Neurosurg. Clin. North Am.* **7**, 337–344.
- Knauth, M., Forsting, M., Hartmann, M., Heiland, S., Balzer, T., and Sartor, K. (1996) MR enhancement of brain lesions: Increased contrast dose compared with magnetization transfer. *Am. J. Neuroradiol.* **17**, 1853–1859.
- Knopp, E.A., Chandra, R., and Litt, A.W. (1993) MP-RAGE vs. T1 weighted SE imaging—a quantitative comparison of contrast enhanced lesion detectability. Presented at the Twelfth Annual Scientific Meeting of the Society of Magnetic Resonance Imaging in Medicine, Berkeley, Calif.
- Mehta, M.P., Rozental, J.M., Levin, A.B., Mackie, TR., Kubsad, S.S., Gehring, M.A., and Kinsella, T.J. (1992) Defining the role of radiosurgery in the management of brain metastases. *Int. J. Radiat. Oncol. Biol. Phys.* **24**, 619–625.
- Nieder, C., Berberich, W., and Schnabel, K. (1997) Tumor-related prognostic factors for remission of brain metastases after radiotherapy. *Int. J. Radiat. Oncol. Biol. Phys.* **39**, 25–30.
- Patchell, R.A., Tibbs, P.A., Regine, W.F., Dempsy, R.J., Mohiuddin, M., Kryscio, R.J., Markesbery, W.R., Foon, K.A., and Young, B. (1998) Post-operative radiotherapy in the treatment of single metastases to the brain: A randomized trial. *JAMA* **280**, 1485–1489.
- Sanghavi, S.N., Miranpuri, S.S., Chappell, R., Mabanta, S., Suh, J.H., Regine, W.F., Weltman, E., Sneed, P.K., Goetsch, S.J., Breneman, J.C., Sperduto, P.W., Scott, C., Buatti, J.M., and Mehta, M.P. (1999) Multi-institutional survival analysis of brain metastases patients treated with radiosurgery, stratified by RTOG RPA Classification (Proceedings of the 41st Annual ASTRO Meeting). *Int. J. Radiat. Oncol. Biol. Phys.* **45**, 171.
- Sperduto, P.W., Scott, C., Andrews, D., Schell, M.C., Flanders, A., Werner-Wasik, M., Demas, W., Ryu, J.K., Gaspar, L.E., Bahary, J., Souhami, L., Rotman, M., and Curran, W.J. (2002) Stereotactic radiosurgery with whole brain radiation therapy improves survival in patients with brain metastases: Report of Radiation Therapy Oncology Group phase III study 95-08 (abstract) (Proceedings of the 44th Annual ASTRO Meeting). *Int. J. Radiat. Oncol. Biol. Phys.* **54**, 3.
- Sze, G., Johnson, C., Kawamura, Y., Goldberg, S.N., Lanage, R., Friedland, R.J., and Wolf, R.J. (1998) Comparison of single- and triple-dose contrast material in the MR screening of brain metastases. *Am. J. Neuroradiol.* **19**, 829–828.
- Thng, C.H., Tay, K.H., Chan, L.L., Lim, E.H., Khoo, B.K., Huin, E.L., and Tan, K.P. (1999) Magnetic resonance imaging of brain metastases: Magnetization transfer or triple dose gadolinium? *Ann. Acad. Med. Singapore* **28**, 529–533.