

# PostScript

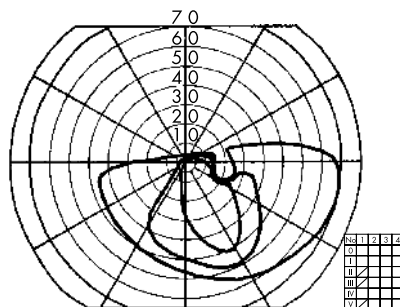
## LETTERS

### Case of acute zonal occult outer retinopathy with altitudinal hemianopsia

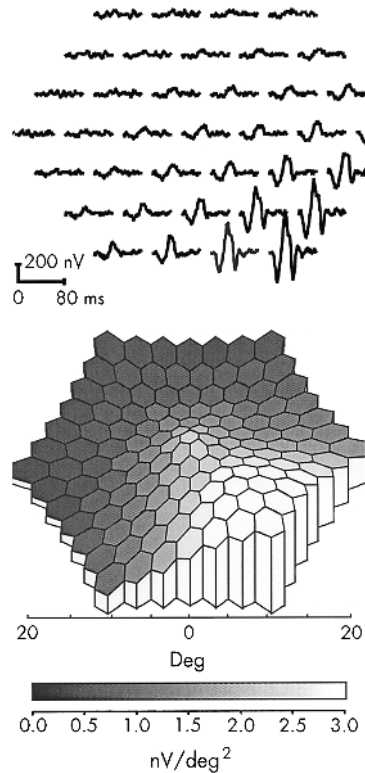
Since the clinical entity of acute zonal occult outer retinopathy (AZOOR) was initially proposed,<sup>1</sup> it has been noted that the visual loss may be misattributed to lesions in the optic nerve or central nervous system. Even with a likely visual field defect for those diseases—an afferent pupillary defect and reduced subjective central flicker fusion threshold—clinicians should be always aware of the possibility of AZOOR.

#### Case report

A 32 year old woman noticed a large scotoma in her right eye. She was examined by an ophthalmologist who found her corrected visual acuity to be 0.4 in the right eye and 1.0 in the left eye. She also had an afferent pupillary defect in the right eye. Goldmann perimetry showed a superior altitudinal hemianopic defect in the right eye (fig 1). Subjective central flicker fusion threshold was reduced in the right eye (18 Hz) and normal in the left eye (35 Hz). Ophthalmoscopic examination, fluorescein angiography, blood screening, and computed tomography were normal. Suspecting ischaemic optic neuropathy (ION), a 5 day course of intravenous succinic hydrocortisone, 100 mg/day, was used but this treatment was not effective. The patient was then referred to us for further examination. Full field rod and cone electroretinograms (ERGs) were reduced in her right eye (about 50% of those in the left eye). Multifocal ERGs (mfERGs) recorded with the VERIS Science 4.0 system (Electro-Diagnostic Imaging, San Mateo, CA, USA) revealed reduced responses in areas corresponding to the visual field defect (fig 2). These findings led us to presume the diagnosis to be AZOOR.<sup>1</sup> While we have followed her for approximately a year, no retinal finding has been observed and the visual defect has not changed.



**Figure 1** Goldmann visual field of the right eye showing superior altitudinal hemianopic depression including the blind spot. The field for the left eye was normal (not shown).



**Figure 2** (Upper panel) Trace array of multifocal ERGs (mfERGs) of the right eye showing marked depression in the superior retinal areas. Waveforms that are close to "extinguished" within the lesion are one of the characteristics of mfERGs in AZOOR. Recorded with: length of m-sequence, 2<sup>14</sup>-1; base rate, 75 Hz; flash intensity, 2.67 cd/s/m<sup>2</sup>; band pass filter, 10-300 Hz; and artefact removal procedure, one iteration (0-80 ms on the first order kernel). (Lower panel) The 3D topographic plot translated from the trace array shown above showing functional distribution of the retina corresponding to the visual field defect.

#### Comment

Although altitudinal hemianopsia is found in many optic nerve disorders—for example, as meningioma, optic neuritis, ION, sinuses or intracranial artery disorders, and congenital abnormalities of the optic nerve head,<sup>2</sup> this type of field defect had been rarely reported in AZOOR.<sup>3</sup> The visual field abnormality in AZOOR varies from case to case,<sup>1</sup> but central or paracentral scotoma is most common. When the clinical entity of AZOOR was initially proposed,<sup>1</sup> the visual loss was attributed to retrolbulbar neuritis, a pituitary adenoma, or other intracranial lesions during the early stages of this disease. Normal fundus and fluorescein angiographic findings with dense scotoma led ophthalmologists to suspect optic nerve or intracranial diseases. In addition, the afferent pupillary defect and disc swelling in AZOOR<sup>1</sup> were very misleading. Our patient had a superior altitudinal hemianopic defect, an afferent pupillary

defect, the reduced subjective central flicker fusion threshold and no disc swelling, and thus, had to be differentiated from ION or posterior ION (PION) without optic disc involvement. PION is an unusual subset of ION and frequently related to arteritis. ERG observations may be critical for the differential diagnosis of cases with visual field defect without observable retinal lesions that are usually attributed to optic nerve or intracranial diseases. While the full field ERG may be sufficient to make the diagnosis,<sup>4</sup> in many of the cases, focal ERG<sup>5</sup> or mfERG<sup>6-8</sup> can show the correspondence of the retinal dysfunction to the visual field defect which strongly reinforce the diagnosis of AZOOR.

**Y Shimada, M Horiguchi, H Yamada, T Sugino, H Suzuki, Y Oya**  
Fujita Health University, Aichi, Japan

Correspondence to: Yoshiaki Shimada, Department of Ophthalmology, Fujita Health University, 1-98 Dengakugakubo, Kutsukake-cho, Toyooka-city, Aichi 470-1192, Japan; ysm@za2.so-net.ne.jp

Accepted for publication 9 April 2002

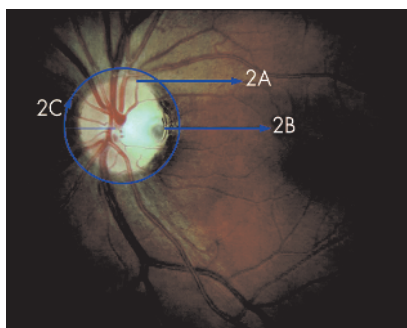
Grant support: Grant No 13877293 from the Ministry of Education, Culture, Sports, Science and Technology, Japan.

#### References

- 1 Gass JD. Acute zonal occult outer retinopathy. *J Clin Neuro Ophthalmol* 1993;13:79-97.
- 2 Herse PR. Altitudinal hemianopsia: a case report and mini-review. *Optom Vis Sci* 1991;68:314-17.
- 3 Saito K, Ishibashi K, Nakamura M, et al. AZOOR with ischemic optic neuropathy-like visual field. *Jpn Rev Clin Ophthalmol* 1999;93:319-22.
- 4 Jacobson SG, Morales DS, Sun XK, et al. Pattern of retinal dysfunction in acute zonal occult outer retinopathy. *Ophthalmology* 1995;102:1187-98.
- 5 Horiguchi M, Miyake Y, Nakamura M, et al. Focal electroretinogram and visual field defect in multiple evanescent white dot syndrome. *Br J Ophthalmol* 1993;77:452-5.
- 6 Arai M, Nao-i N, Sawada A, et al. Multifocal electroretinogram indicates visual field loss in acute zonal occult outer retinopathy. *Am J Ophthalmol* 1998;126:466-9.
- 7 Yasuda K, Shimura M, Noro M, et al. Clinical course of acute retinal zonal occult outer retinopathy in visual field and multifocal electroretinogram. *Br J Ophthalmol* 1999;83:1089-90.
- 8 Al-Yousuf N, Parks S, Dhillon B, et al. Acute zonal occult outer retinopathy. *Br J Ophthalmol* 2000;84:118-19.

### Congenital optic nerve head pit associated with reduced retinal nerve fibre thickness at the papillomacular bundle

Congenital pits of the optic nerve head result from an imperfect closure of the superior edge of the embryonic fissure. An unequal growth on both sides causes a delayed closure of the fissure at approximately 5 weeks of gestation. Optic pits appear as crater-like



**Figure 1** Fundus image of the left large optic nerve head with a horizontal diameter of 2.28 mm, vertical diameter of 2.09 mm, and area of 3.42 mm<sup>2</sup>. The optic disc has a grey oval pit at the inferotemporal side and is surrounded by a hyperpigmented margin. The papillomacular bundle appeared to be darker extending from the edge of the optic nerve to the macula. In the superior and inferior quadrant the main nerve fibres are visible. The blue arrows indicate the location and direction of the corresponding linear and circular OCT scans.

indentations of the surface of the optic nerve head usually with a steep temporal wall.<sup>1</sup>

Anatomically the most anterior component of the optic nerve head contains the retinal nerve fibre layer (RNFL), composed of approximately 1.2 million unmyelinated retinal ganglion cell axons extending from all regions of the retina. The outgrowth of axons from certain ganglion cells may be incomplete so that the primitive epithelial papilla is built up with aberrant nerve fibres.<sup>2</sup>

Histological sections of optic pits define defects in the lamina cribrosa associated with rudimentary retinal tissue, resembling pigmented tissue and aberrant nerve fibres. These anomalous papillomacular nerve fibre bundles may be less resistant,<sup>1</sup> predisposing this sector to spontaneous schisis-like retinal detachments during later life.<sup>3</sup>

We present a young patient with a unilateral optic pit and a clinically significant temporal nerve fibre loss. In vivo measurements by optical coherent tomography (OCT) determined the thickness of RNFL at the side of the pit and the corresponding papillomacular bundle.

### Case report

A 27 year old white woman presented with a 9 month history of blurred vision; her best corrected visual acuity was 20/20 right eye and 20/25 left eye. On Goldmann perimetry in both eyes, there were no visual field defects, arcuate or paracentral scotomas. On slit lamp examination the anterior segment appeared normal in both eyes. Fundus biomicroscopy of the left eye revealed a large optic nerve head with a grey oval pit at the temporal margin and a brownish rim at the temporal side. The papillomacular bundle appeared to be darker, extending from the edge of the optic nerve to the macula, compared to the superior and inferior quadrant corresponding with severe RNFL loss according to the semiquantitative assessment of Niessen *et al*<sup>6</sup> (Fig 1). Fundus examination of the right eye was unremarkable.

Linear OCT disclosed a significantly thickened RNFL in the superior quadrant (Fig 2A) and thinned RNFL at the temporal quadrant of the optic nerve in the left eye. There were

no signs of a schisis-like retinal detachment (Fig 2B). Circular OCT demonstrated a significantly reduced thickness of the RNFL in all quadrants but predominantly in the temporal (90 µm) quadrant (Fig 2C).

### Comment

The oval depression of the optic nerve head in optic pits may relate to an enlarged optic nerve head, an incomplete closure of the embryonic fissure and a reduced RNFL. The size of the optic disc was significantly larger when compared to the mean size (1.76 mm) in normal eyes, reducing the mean RNFL density.<sup>4</sup> In addition, an incomplete closure of the embryonic fissure seams to prevent a proper fusion of the temporal RNFL. OCT confirmed both a reduced mean RNFL and significant loss especially in the papillomacular bundle. Whereas normal subjects have a mean RNFL of 153 µm and 126 µm in the temporal quadrant,<sup>5</sup> our patient with an optic pit had a mean RNFL of 115 µm and 90 µm in the temporal quadrant. Glaucomatous eyes with a mean RNFL below 103 µm frequently develop visual field defects,<sup>6</sup> whereas in our patient with a mean RNFL of 115 µm none became apparent.

OCT precisely measured the retinal thickness with micrometer scale and provided additional evidence for pronounced reduced thickness of the RNFL in the temporal quadrant of the optic pit. Fundus photography confirmed the enlarged optic disc and temporal RNFL damage. The imperfect closure and lack of papillomacular nerve fibre bundles represent a "loco minoris resistentiae" in optic pits, the development of a spontaneous schisis-like detachment during ageing.

C H Meyer, E B Rodrigues, J C Schmidt

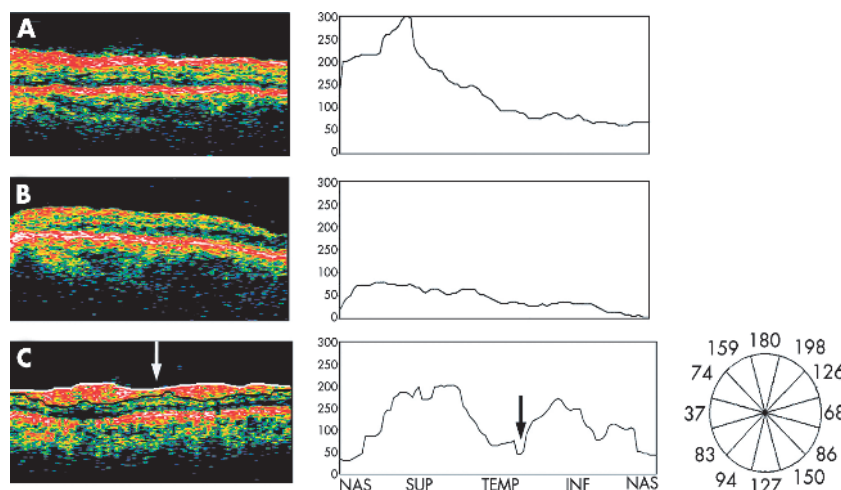
Department of Ophthalmology, Philipps-University Marburg, Germany

Correspondence to: Carsten H Meyer, MD, Department of Ophthalmology, Philipps-University Marburg, Robert-Koch-Strasse 4, 35037 Marburg, Germany; meyer\_eye@yahoo.com

Proprietary interest: none.

Financial support: none.

Accepted for publication 20 February 2003



**Figure 2** (A) Horizontal OCT scan of the temporal optic disc and the papillomacular region of the left eye. Fibroglial tissue membrane appears to overlies the vitreoretinal surface at the upper edge of the pit. The thick hyper-reflective band which is white to reddish in colour, corresponds to the retinal nerve fibre layer (RNFL). The reflectivity is elevated and the thickness is wider than normal. The standardised measurement of the RNFL determines a thickness of  $\geq 200$  µm at the edge of the optic nerve and 80 µm at 1 DD distance. (B) Horizontal OCT scan of the papillomacular region left eye. A less reflective and thinned hyper-reflective band in red and orange colours extends from the edge of the optic nerve to the fovea. The standardised measurement of the RNFL determines a thickness of 70 µm at the edge of the optic nerve and 5 µm at 1 DD distance. (C) Circular OCT scan of 3.4 mm diameter centred on the optic disc left eye. The cylindrical section is unfolded and displayed as flat cross sectional, two dimensional false colour image. The scan started nasally and measured clockwise perpendicular around the optic nerve with a diameter of 2.0 mm. Each b-scan consists of 100 individual A-scans (one thickness value for each 3.6'). The RNFL measurement determined a mean thickness of 182 µm in the superior quadrant, 90 µm in the temporal quadrant, 125 µm in the inferior quadrant, 64 µm in the nasal quadrant. There is a marked reduction in the RNFL to 48 µm at the 4 o'clock position consistent with the location of the optic pit.

### References

- 1 Kranenberg EW. Crater-like holes in the optic disc and central serous retinopathy. *Arch Ophthalmol* 1960;64:912-24.
- 2 Sugar HS. Congenital pits in the optic disc and their equivalents (congenital colobomas and colobomalike excavations) associated with submacular fluid. *Am J Ophthalmol* 1967;63:298-307.
- 3 Lincoff H, Kreissig I. Optic coherence tomography of pneumatic displacement of optic disc pit maculopathy. *Br J Ophthalmol* 1998;83:367-72.
- 4 Niessen AG, van den Berg TJ, Langerhorst CT, *et al*. Grading of retinal nerve fiber layer with photographic reference set. *Am J Ophthalmol* 1995;120:577-86.
- 5 Schuman JS, Pedut-Kloizman T, Hertzmark E, *et al*. Reproducibility of nerve fiber layer thickness measurements using optical coherence tomography. *Ophthalmology* 1996;103:1889-9.
- 6 Williams ZY, Schuman JS, Gamell L, *et al*. Optical coherence tomography measurement of nerve fiber layer thickness and the likelihood of a visual field defect. *Am J Ophthalmol* 2002;134:538-46.



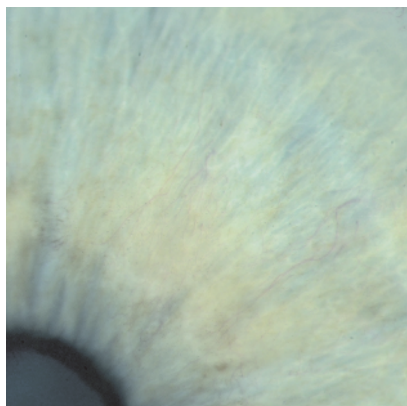
## Ocular ischaemic syndrome in thyroid eye disease, confirmed using magnetic resonance angiography

Ocular ischaemic syndrome (OIS) is most commonly caused by severe ipsilateral carotid artery stenosis.<sup>1-3</sup> Occasionally it is caused by ophthalmic artery stenosis.<sup>4,5</sup> Features commonly observed are iris neovascularisation, angle neovascularisation, rubeotic glaucoma, and iritis. In the posterior segment common signs are narrowing of the retinal arterioles, mid-peripheral retinal haemorrhages, optic disc pallor or neovascularisation and, rarely, retinal neovascularisation. Fluorescein angiography characteristically demonstrates delayed filling of the retinal circulation and occasionally patchy filling of the choroidal circulation is also observed.<sup>1-3</sup> To the best of our knowledge OIS has not previously been described in thyroid eye disease. We report a case of OIS in thyroid eye disease confirmed by magnetic resonance angiography (MRA) and treated by orbital decompression.

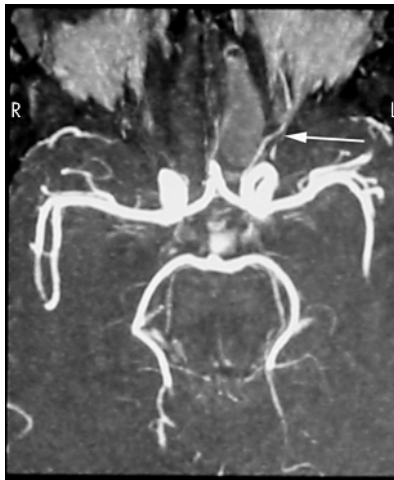
### Case report

A 48 year old woman with known thyroid eye disease presented with a 4 week history of pain, redness, and reduced visual acuity in her right eye. Eight years previously she had undergone bilateral three wall orbital decompression for severe corneal exposure. On examination visual acuity was counting fingers in the right eye and 6/9 in the left. There was bilateral lid retraction and mild generalised restriction of eye movements. There was bilateral proptosis measuring 24 mm in the right eye and 23 mm in the left (Keeler exophthalmometer). A right relative afferent pupillary defect was present. Intraocular pressures were 50 mm Hg in the right eye and 20 mm Hg in the left. There was right corneal oedema, rubeosis iridis (Fig 1), and moderate anterior chamber activity. Gonioscopy showed an open, grade 2 angle (Shaffer's classification) with rubeotic vessels present in the angle. Fundal examination was limited by the corneal oedema but no specific abnormality was identified. Examination of the left eye was normal.

Fluorescein angiography showed delayed filling of the retinal vasculature in the right eye relative to the left. Computed tomography scans of the orbits showed previous bilateral three wall orbital decompression and diffuse



**Figure 1** Photograph of the right iris demonstrating rubeosis iridis.



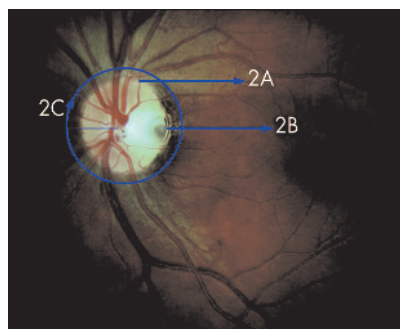
**Figure 2** Preoperative MRA. Blood flow is clearly visible in the left ophthalmic artery (arrow). The absence of signal from the right ophthalmic artery demonstrates that blood flow in the right ophthalmic artery is reduced.

enlargement of extraocular muscles. Carotid duplex ultrasound examination was normal. An MRA of the orbits demonstrated that blood flow in the right ophthalmic artery was reduced. Blood flow in the left ophthalmic artery was normal (Fig 2).

The patient was admitted and treated with intravenous mannitol and acetazolamide and topical apraclonidine 0.5% and betaxolol 0.5% but intraocular pressure remained elevated at 29 mm Hg. A further right orbital decompression was performed (where the lateral orbital wall was removed as far posteriorly as the anterior wall of the middle cranial fossa and superiorly to the floor of the anterior cranial fossa). Postoperatively the right proptosis measured 21 mm, the relative afferent pupillary defect resolved and the intraocular pressure was controlled ( $\leq 20$  mm Hg) with oral acetazolamide and topical apraclonidine 0.5% and betaxolol 0.5%. The corneal oedema resolved and the visual acuity gradually improved to 6/9. At the 3 month follow up postoperatively the rubeotic iris vessels had regressed. An MRA performed 4 months postoperatively demonstrated normal blood flow in both ophthalmic arteries (Fig 3).

### Comment

Imaging methods available for evaluating the ophthalmic artery include duplex ultrasonography and cerebral angiography. Duplex



**Figure 3** Postoperative MRA. Normal blood flow is present in both ophthalmic arteries (arrows).

ultrasonography is a non-invasive technique that gives quantitative information about flow; however, it requires an experienced operator and it is not always possible to positively identify the ophthalmic artery. Cerebral angiography is an invasive technique with the inherent risk of embolisation and stroke. MRA is a relatively new technique and has not previously been used to investigate disturbances of blood flow in the ophthalmic artery. It is non-invasive and does not require the level of technical experience required for Doppler studies. MRA detects blood flowing at a defined velocity. In this case 25 mm/s was chosen as it has been shown in many studies using Doppler ultrasound to be the mean ophthalmic artery blood flow. The absence of signal from the right ophthalmic artery in the preoperative MRA demonstrates that at no stage during the cardiac cycle was blood flowing at this velocity in the artery. The images shown in Figures 2 and 3 are composites of all slices taken through the orbits. Hence it is not possible that one of the ophthalmic arteries could have been missed as a result of the orientation of any one particular slice.

Various abnormalities of the orbital circulation have been reported in thyroid ophthalmopathy. Blood flow in the superior ophthalmic vein has been shown to be reduced,<sup>6-8</sup> or even reversed<sup>7,8</sup> in some patients. Increased central retinal artery,<sup>8</sup> ophthalmic artery,<sup>8</sup> and retinal blood flow<sup>9</sup> have also been demonstrated. Ischaemia of the optic nerve head has been postulated to have a role in the development of optic neuropathy in some patients with thyroid ophthalmopathy.<sup>10</sup> However, to the best of our knowledge ophthalmic artery obstruction as a result of thyroid eye disease has not previously been described.

In summary, this case demonstrates for the first time, the ocular ischaemic syndrome as a result of ophthalmic artery obstruction in thyroid eye disease. Furthermore, it demonstrates the usefulness of MR imaging in evaluation of the ophthalmic artery.

**A J Shortt, T Fulcher**

Institute of Ophthalmology, Mater Misericordiae Hospital, Dublin, Ireland

**D Conroy**

Department of Radiology, Mater Misericordiae Hospital, Dublin, Ireland

Correspondence to: Dr Alex J Shortt, Institute of Ophthalmology, Mater Misericordiae Hospital, Eccles Street, Dublin 7, Ireland; alexjshortt@eircom.net

Accepted for publication 21 February 2003

### References

- 1 Mizener JB, Podhajsky P, Hayreh SS. Ocular ischemic syndrome. *Ophthalmology* 1997;104:859-64.
- 2 Brown GC, Magargal LE. The ocular ischemic syndrome: clinical, fluorescein angiographic and carotid angiographic features. *Int Ophthalmol* 1988;11:239-51.
- 3 Sturrock GD, Mueller HR. Chronic ocular ischaemia. *Br J Ophthalmol* 1984;68:716-23.
- 4 Bullock JD, et al. Ischaemic ophthalmia secondary to ophthalmic artery occlusion. *Ophthalmology* 1972;74:486-93.
- 5 Madsen PH. Venous-stasis retinopathy: insufficiency of the ophthalmic artery. *Acta Ophthalmol* 1966;44:940-7.
- 6 Benning H, Lieb W, Kahaly G, et al. [Colour duplex ultrasound findings in patients with

endocrine ophthalmopathy] (in German). *Ophthalmologie* 1994;**91**:20–5.

- 7 Nakase Y, Osanai T, Yoshikawa K, *et al.* Color Doppler imaging of orbital venous flow in dysthyroid optic neuropathy. *Jpn J Ophthalmol* 1994;**38**:80–6.
- 8 Alp MN, Ozgen A, Can I, *et al.* Color Doppler imaging of the orbital vasculature in Graves' disease with computed tomographic correlation. *Br J Ophthalmol* 2000;**84**:1027–30.
- 9 Kurioka Y, Inaba M, Kawagishi T, *et al.* Increased retinal blood flow in patients with Graves' disease: influence of thyroid function and ophthalmopathy. *Eur J Endocrinol* 2001;**144**:99–107.
- 10 Dosso A, Safran AB, Sunaric G, *et al.* Anterior ischemic optic neuropathy in Graves' disease. *J Neuro-ophthalmol* 1994;**14**:170–4.

## MAILBOX

If you have a burning desire to respond to a paper published in *BJO*, why not make use of our eletters option?

Log on to our website ([www.bjophthalmol.com](http://www.bjophthalmol.com)), find the paper that interests you, click on "full text" and send your response by email by clicking on "eletters submit a response".

Providing it isn't libellous or obscene, it will be posted within seven days. You can retrieve it by clicking on "read eletters" on our homepage.

The editors will decide, as before, whether to also publish the eletter as a mailbox in a future paper issue.

## Silicone oil in diabetic vitrectomy

Castellarin and colleagues<sup>1</sup> recount their recent experience of infusing silicone oil in a small series of patients with advanced diabetic eye disease, either during primary vitrectomy (12 eyes) or after earlier surgery had failed (11 eyes). They compare their results with previous reports and conclude that silicone oil remains a useful adjunct in diabetic vitrectomy. However, their conclusions and historical comparisons are open to question.

Silicone oil was first used in primary diabetic vitrectomy in an era (1979–84) before the introduction of endolaser and the Landers' double concave lens for phakic fluid:air exchange.<sup>2–4</sup> Dealing with large or multiple posteriorly located breaks (whether pre-existing or iatrogenic) was problematic, and direct fluid:silicone oil exchange (by virtue of the optical advantages of oil over air in the phakic eye) provided a surgical escape route, obviating the need for lensectomy. Furthermore, the clarity of the media immediately postoperatively facilitated the slit lamp delivery of focal laser in order to seal retinal breaks that had been closed by the internal tamponade and, in addition, the application of scatter laser to reattached, untreated, ischaemic retina that had undergone deturgescence, in part through the "waterproofing" effect of silicone oil.<sup>3,4</sup> All being well, the silicone oil could then be removed shortly thereafter, and some eyes that would undoubtedly have been lost were saved by the intervention of silicone oil in this way. Often, however, there were considerable associated problems, not least the rapid development of reparative epiretinal fibrosis whereby the retina redetached under

tangential traction and/or from reopening of retinal breaks.<sup>2–6</sup> Sometimes huge areas of retinal disintegration eventually developed.<sup>5,7</sup> The fibroglial epiretinal proliferation appeared (both clinically and pathologically) to be particularly induced by clotted blood trapped between the silicone oil and the retinal surface or, ironically, by fibrin released as a result of the extensive scatter laser that was often needed to prevent highly vascularised membranes from reepithelialising behind the silicone oil.<sup>4,5,8,9</sup>

It was hoped that the so called "compartmentalisation" of the eye by silicone oil (to which the retro-silicone oil neovascularisation was attributed) might in turn result in prevention or reversal of rubeosis iridis through its putative barrier effect against anterior diffusion of angiogenic substances derived from the ischaemic retina.<sup>2–8</sup> Paradoxically, eyes with successful retinal reattachment (albeit with unabated ischaemia) often underwent rapid development or progression of iris neovascularisation,<sup>3,8</sup> while those with failed surgery from post-operative rhegmatogenous recurrence of retinal detachment (and therefore eyes with an exaggerated angiogenic drive) had evidence of protection from rubeotic phthisis, at least in the short term.<sup>3</sup> Perhaps naively it was postulated that rhegmatogenous confinement of the redetachment by intravitreal silicone oil (and the consequent 100% oil filling of the shrinking vitreous cavity) might allow an effective obstruction to anterior molecular diffusion to be established in these failed cases.<sup>3</sup> Others had planned from the outset to employ silicone oil in their surgical protocol, not least for those diabetic eyes wherein earlier vitrectomy had been unsuccessful as a consequence of retinal redetachment<sup>4,10,11</sup> or recurrent vitreous cavity haemorrhages.<sup>4</sup> However, whether used during primary diabetic vitrectomy or secondarily, whether unpremeditated or planned, and whether infused by direct fluid:oil exchange or sequential fluid:air and air:oil exchanges, the possibility of silicone oil limiting rubeosis and maintaining macular attachment despite peripheral retinal redetachment was always welcome, even if surgical "success" (that is, retinal attachment through 360 degrees) had strictly been denied.<sup>2–4,8,12</sup>

Nowadays, posterior retinal breaks and retinectomies can generally be managed successfully by employing wide angle viewing systems, heavy liquids, endolaser, and long acting gases. However, silicone oil continues to be infused during diabetic vitrectomy despite the attendant posterior segment and anterior segment complications that have been only partially mitigated by the improved quality of the silicone oil. The important question that thus arises is: what is the appropriate use of silicone oil in the diabetic eye in the modern era? Where retinal breaks might be closed just as readily using gas tamponade, or where rubeosis iridis might be reversed or prevented by retinal reattachment and/or a sufficiency of scatter laser photocoagulation, the use of silicone oil might be described fairly as "gratuitous." Exceptions might include anticipated posturing difficulties<sup>3</sup> or the need for early visual rehabilitation in one eyed patients.<sup>4</sup> However, recent reports documenting the use of silicone oil in diabetic vitrectomy have failed to provide clear criteria or explanations regarding case selection.<sup>1,12,13</sup> Only seven of the 23 eyes in Castellarin and colleagues' series, for example, had retinal

breaks (two pre-existing, four iatrogenic, and one retinectomy), so the need for prolonged internal break tamponade was presumably not an issue in the majority of their eyes. More information is needed on the rationale for silicone oil infusion (not just the overall indications for surgery) in the remaining eyes in order to enable the potential benefits of this surgical adjunct to be assessed at this time. Furthermore, surgical success can really only be judged after a minimum of 6 months from the last vitreoretinal procedure,<sup>3,4,8,10–12</sup> and that judgment should preferably include consideration of whether the silicone oil has been removed and the status of the fellow eye.<sup>14</sup> The fact that 10 of the 23 eyes in Castellarin's series were followed for only 1 or 2 months was thus a further serious limitation of their study.<sup>1</sup>

Infusion of silicone oil can be a most beguiling option during the closed microsurgical management of the stricken diabetic eye but, as mentioned, complications are prone to accumulate with time. Distinguishing the gratuitous from the virtuous use of silicone oil can be problematic, and equally it may be difficult to define the line between a surgeon's infusing silicone oil in anticipation of eventual surgical failure and such infusion representing his/her unstated admission that surgical failure has occurred already. All these issues need to be borne in mind when making historical comparisons between case series and in defining the place in history for silicone oil in diabetic vitrectomy.

**D McLeod**

Manchester Royal Eye Hospital, Oxford Road,  
Manchester M13 9WH, UK;  
[david.mcleod@man.ac.uk](mailto:david.mcleod@man.ac.uk)

Accepted for publication 10 April 2003

## References

- 1 Castellarin A, Grigorian R, Bhagat N, *et al.* Vitrectomy with silicone oil infusion in severe diabetic retinopathy. *Br J Ophthalmol* 2003;**87**:318–21.
- 2 Lean JS, Leaver PK, Cooling RJ, *et al.* Management of complex retinal detachments by vitrectomy and fluid/silicone exchange. *Trans Ophthalmol Soc UK* 1982;**102**:203–5.
- 3 McLeod D. Silicone-oil injection during closed microsurgery for diabetic traction retinal detachment. *Graefes Arch Clin Exp Ophthalmol* 1986;**24**:55–9.
- 4 Lucke KH, Foerster MH, Laqua H. Long-term results of vitrectomy and silicone oil in 500 cases of complicated retinal detachment. *Am J Ophthalmol* 1987;**104**:624–33.
- 5 Barry PJ, Hiscott PS, Grierson I, *et al.* Reparative epiretinal fibrosis after diabetic vitrectomy. *Trans Ophthalmol Soc UK* 1985;**104**:285–96.
- 6 Charles S. *Vitreous surgery*, 2nd ed Baltimore: Williams and Wilkins, 1987:115–31.
- 7 Wilson-Holt N, Gregor Z. Spontaneous relieving retinotomies in diabetic silicone filled eyes. *Eye* 1992;**6**:461–4.
- 8 Yeo JH, Glaser BM, Michels RG. Silicone oil in the treatment of complicated retinal detachments. *Ophthalmology* 1987;**94**:1109–13.
- 9 McLeod D, James CR. Viscodelamination at the vitreoretinal junction in severe diabetic eye disease. *Br J Ophthalmol* 1988;**72**:413–19.
- 10 Rinkoff JS, de Juan E, McCuen BW II. Silicone oil for retinal detachment with advanced proliferative vitreoretinopathy following failed vitrectomy for proliferative diabetic retinopathy. *Am J Ophthalmol* 1986;**101**:181–6.
- 11 Brouman ND, Blumenkranz MS, Cox MS, *et al.* Silicone oil for the treatment of severe proliferative diabetic retinopathy. *Ophthalmology* 1989;**96**:759–64.



- 12 **Azen SP**, Scott IU, Flynn HW Jr, *et al.* Silicone oil in the repair of complex retinal detachments. A prospective observational multicenter study. *Ophthalmology* 1998;**105**:1587-97.
- 13 **Scott IU**, Flynn HW Jr, Lai M-Y, *et al.* First operation anatomic success and other predictors of postoperative vision after complex retinal detachment repair with vitrectomy and silicone oil tamponade. *Am J Ophthalmol* 2000;**130**:745-50.
- 14 **McLeod D.** Microsurgical management of neovascularisation secondary to posterior segment ischaemia. *Eye* 1991;**5**:252-9.

## Authors' reply

We thank Professor McLeod for his interest in our paper<sup>1</sup> and value the opportunity to address some of the issues he has raised.

McLeod notes that surgical success can be judged only if the retina has remained attached for a minimum of 6 months from the last retinal procedure. He notes that 10 (43%) of 23 eyes in our report had a follow up of only 1 or 2 months. Tables 1-5 list the results in 17 (74%) eyes on which we have follow up of at least 6 months (mean 9.3 months). Of the six patients on whom we do not have at least 6 months' follow up, two have left the United States, and the whereabouts of four are unknown. The follow up of these six patients ranged from 1 to 4 months after surgery.

The composition of the subgroup with at least 6 months' follow up strongly resembles the composition of the entire group of 23 eyes.<sup>1</sup> For example, the indications for surgery are almost identical in their representation (Table 1). The average complexity score in this subgroup was 4.5, which is the same as that of the entire cohort. Additional details regarding this cohort of 17 eyes are as follows. In eight (47%) eyes, silicone oil infusion (SOI) was part of the initial operation during primary vitrectomy. In nine (53%) eyes, SOI was done after previously failed vitrectomy. Preoperatively, 11 (65%) eyes were phakic and six (35%) were pseudophakic. Eight (73%) of 11 phakic eyes underwent lensectomy and five (29%) of these were left aphakic. Four (67%) of the pseudophakic eyes underwent intraocular lens removal and were left aphakic. Different intraocular procedures were performed at the time of surgery. Scleral buckles were placed in two (12%) eyes. Epiciliary dissection was done in two (12%) eyes, one of which had preoperative hypotony. Membrane peeling was done in all eyes. A Baerveldt valve was placed in one (6%) eye, and a peripheral relaxing retinectomy was necessary in one (6%) eye. Silicone oil (SO) was removed in two (12%) eyes at 5 and 8 months after surgery, respectively, without complication. SO was removed because of migration

into the anterior segment with corneal touch in one eye and because of cataract progression in the second eye. As one might expect, in all these aspects, this cohort of 17 eyes with at least 6 months' follow up resembles the overall cohort of 23 eyes on which we reported.<sup>1</sup>

The anatomical results of surgery among eyes with at least 6 months' follow up are quite similar to those of the entire cohort although a lower reattachment rate occurred among eyes undergoing surgery after having failed previous vitrectomy (Table 2). After a single operation employing pars plana vitrectomy (PPV) with membrane peeling and SOI, the retina was fully attached in 12 (71%) of 17 eyes with at least 6 months' follow up. In the eight eyes that were operated for the first time with primary SOI, the retina was attached in seven (88%) eyes. In the nine eyes that underwent SOI after previously failed vitrectomy, the retina was attached in five (56%). The difference in the reattachment rate between these two groups was not statistically significant (Fisher's exact test,  $p=0.18$ ) as was the case in the cohort of 23 eyes.<sup>1</sup>

Among eyes with at least 6 months' follow up, three of the five eyes with recurrent detachment underwent repeat PPV and SOI. The retina was reattached in two (40%) eyes. The third eye developed hypotony despite complete retinal attachment five months after SOI and underwent repeat surgery with additional SOI and epiciliary dissection but became phthisical. The remaining two patients declined additional surgery. Therefore, with multiple operations employing PPV and SOI, the final anatomical success rate at last follow up was 14/17 (82%), which is close the final anatomical success rate (20/23 (87%)) we reported previously.<sup>1</sup>

With longer follow up, visual results were not as good as we reported initially (Table 3). Among eyes with at least 6 months' follow up (and as noted in our initial report<sup>1</sup>), two (9%) had no light perception at last follow up (neither underwent scleral buckling). Both eyes had preoperative vision of light perception. Loss of light perception was due to retinal and optic nerve ischaemia in each case. Preoperatively, the visual acuity of all patients ranged from light perception to less than counting fingers at 1 foot. Six months or more after surgery, three (18%) of 17 eyes had vision greater than or equal to 5/200. Among the entire cohort of 23 eyes, five (22%) had vision greater than or equal to 5/200.

Rubeosis iridis was present preoperatively in seven (30%) of 23 eyes, three of which had neovascular glaucoma (NVG). The rate of NVG regression among eyes with at least 6 months' follow up was the same as in the

**Table 2** Anatomical results of pars plana vitrectomy (PPV) membrane peeling, and silicone oil infusion (SOI)

Cohort	Retinal reattachment rate
<b>Eyes with &gt;6 months' follow up</b>	
Overall	12/17 (71%)
PPV+SOI as primary intervention	7/8 (88%)
PPV+SOI for failed previous vitrectomy	5/9 (56%)
<b>All eyes</b>	
Overall	17/23 (74%)
PPV+SOI as primary intervention	9/12 (75%)
PPV+SOI for failed previous vitrectomy	8/11 (73%)

entire cohort (Table 4). The rate of rubeosis iridis regression was greater than we reported initially (that is, 3/7 (43%)) because of continued regression of rubeosis during the longer period of follow up (Table 4). Of the three eyes with NVG, one eye underwent Baerveldt valve placement with normalisation of the postoperative intraocular pressure. Five months after surgery, however, the eye developed hypotony. Subsequently, the valve was removed, and the eye underwent additional SOI. As noted above, however, the eye became phthisical. As reported initially, the NVG regressed after surgery in the second eye, and the third eye had NVG regression but no light perception postoperatively because of ischaemia. As noted in our initial report, only one eye developed de novo rubeosis iridis.<sup>1</sup> Among the 17 eyes with at least 6 months' follow up, six (35%) had intraocular pressure  $\leq 5$  mm Hg. In our initial report, five (23%) of 23 eyes had intraocular pressure  $\leq 5$  mm Hg.<sup>1</sup> Three of these six eyes had persistent retinal detachment, which we presume to be the cause of the hypotony. Among eyes with at least 6 months' follow up, the remaining 11 (65%) had intraocular pressure ranging from 6-48 mm Hg, with four patients taking anti-glaucoma medications.

Intraoperative complications were not different among eyes with at least 6 months' follow up versus the entire cohort of 23 eyes (Table 5). Postoperative complications differed in that there was an increased prevalence of cataract, hypotony, and silicone oil in the anterior chamber over time, which is not surprising.

McLeod suggests that in addition to using data from eyes with at least 6 months' follow up, one should use the status of the fellow eye to judge surgical success. At the time of surgery, all fellow eyes had proliferative diabetic retinopathy (in addition to other vision threatening conditions) and had undergone full panretinal photocoagulation (Table 6). Among patients with traction retinal detachment in the fellow eye, two underwent fellow eye surgery and one patient refused surgery (Table 6). Six (29%) of 21 fellow eyes were pseudophakic. Among the six fellow eyes with visual acuity  $<20/400$ , two had no light perception. Among the 21 patients we reported, the severity of disease in the fellow eye was such that two patients underwent PPV+SOI bilaterally, and results from both pairs of eyes were

**Table 1** Surgical indications

Indication*	Eyes with >6 months' follow up	All operated eyes
TRD+VH	7/17 (41.2%)	11/23 (47.8%)
TRD	3/17 (17.6%)	4/23 (17.4%)
TRRD	2/17 (11.8%)	2/23 (8.7%)
TRD+FS	1/17 (5.9%)	2/23 (8.7%)
TRD+NVG	1/17 (5.9%)	1/23 (4.3%)
TRD+NVG+VH	1/17 (5.9%)	1/23 (4.3%)
TRD+VH+FS	1/17 (5.9%)	1/23 (4.3%)
TRD+FS+NVG	1/17 (5.9%)	1/23 (4.3%)

\*TRD = traction retinal detachment; VH = vitreous haemorrhage; TRRD = traction-rhegmatogenous retinal detachment; FS = fibrinoid syndrome; NVG = neovascular glaucoma.

**Table 3** Visual outcome

Visual outcome	Eyes with >6 months' follow up	All eyes
Improved	4/17 (23.5%)	10/23 (43.5%)
Unchanged	10/17 (58.9%)	3/23 (13.0%)
Worse	3/17 (17.6%)	10/23 (43.5%)

**Table 4** Regression of rubeosis iridis and neovascular glaucoma

	Eyes with >6 months' follow up	All eyes
Rubeosis iridis regression	5/7 (71%)	5/7 (71%)
Neovascular glaucoma regression	2/3 (67%)	2/3 (67%)

**Table 5** Prevalence of complications

Complication	Eyes with >6 months' follow up	All eyes
Intraoperative retinal break	3/17 (18%)	4/23 (17%)
Silicone oil in anterior chamber	3/17 (18%)	3/23 (13%)
Cataract	3/17 (18%)	3/23 (13%)
Hypotony with attached retina	3/17 (18%)	3/23 (13%)
Fibrinoid reaction	1/17 (6%)	1/23 (4%)
New onset rubeosis iridis	1/17 (6%)	1/23 (4%)
Keratopathy	1/17 (6%)	2/23 (9%)

**Table 6** Condition of fellow eye

Condition	Prevalence
Proliferative diabetic retinopathy	21/21 (100%)
Status post panretinal photocoagulation	21/21 (100%)
Status post vitrectomy	10/21 (48%)
Clinically significant macular oedema	3/21 (14%)
Traction retinal detachment	3/21 (14%)
Rubeosis iridis	2/21 (10%)
Neovascular glaucoma	2/21 (10%)
Central retinal vein occlusion	1/21 (5%)
Macular pucker	1/21 (5%)
Primary open angle glaucoma	1/21 (5%)
<b>Visual acuity</b>	
20/20–20/50	6/21 (29%)
20/60–20/100	7/21 (33%)
20/200–20/400	2/21 (10%)
Worse than 20/400	6/21 (29%)

described.<sup>1</sup> Thus, the majority of our patients were visually disabled because of bilateral, severe eye disease.

McLeod points out that only seven (30%) of 23 eyes in our series had retinal breaks (either pre-existing or intraoperative), and he asks what the rationale for silicone oil use was in the remaining 16 eyes. It is not our habit to use silicone oil routinely for reoperation of eyes with proliferative diabetic retinopathy. We usually manage such cases with membrane dissection, extensive laser photocoagulation, and gas tamponade, when indicated.<sup>2</sup> The average case complexity score in a series of more than 150 eyes with severe diabetic retinopathy on which we operated using modern surgical techniques was 3.7.<sup>2</sup> In this series, the average complexity score was 4.5, which was significantly greater.<sup>1</sup> We felt that silicone oil was needed in all these cases owing to the severe nature of the proliferative

diabetic retinopathy as well as specific features of the case.

Specifically, rubeosis iridis was present in seven (30%) eyes, despite previous application of substantial panretinal photocoagulation, and silicone oil was used to compartmentalise the eye and inhibit progression of rubeosis iridis (Table 4). Among six (26%) eyes with retinal breaks, silicone oil tamponade was used because of the extensive nature of the retinal breaks. Normally, we use intraocular gas for this purpose.<sup>2</sup> Five (22%) eyes had traction retinal detachment and anterior hyaloidal fibrovascular proliferation, and silicone oil was used to help maintain a more normal intraocular pressure and forestall the development of phthisis. In two (9%) eyes with the fibrinoid syndrome, silicone oil was used to prevent the development of transvitreal fibrous sheets, which we feared might foster recurrent retinal detachment

(Tables 1 and 2). Two eyes (9%) had no light perception in the fellow eye, and silicone oil was used to provide more rapid visual rehabilitation (Table 6). One eye (4%) had recurrent vitreous haemorrhage, and silicone oil was used to help maintain media clarity postoperatively.

McLeod observes that silicone oil continues to be used during diabetic vitrectomy despite the attendant anterior and posterior segment complications. He suggests that wide angle viewing systems, heavy liquids, endolaser, and long acting gases enable one to manage posterior retinal breaks and retinectomies. McLeod asks, "What is the appropriate use of silicone oil in the diabetic eye in the modern era?" He suggests that in cases where breaks can be managed with gas tamponade and rubeosis can be reversed with retinal reattachment and laser photocoagulation, the use of silicone might be "gratuitous." McLeod suggests that appropriate uses of silicone might include patients with posturing difficulties or patients in whom there is a need for early visual rehabilitation.

We recognise that the conclusions of our study are limited because it is a non-randomised retrospective study without a control group. Thus, we cannot identify the "virtuous" indications for the use of silicone oil in the setting of severe proliferative diabetic retinopathy based on these data. Without the use of silicone oil, for example, rubeosis iridis might have regressed, and the retina might have remained attached in eyes exhibiting the fibrinoid syndrome. None the less, the data from our study are consistent with the notion that silicone oil is an acceptable and useful tool in the management of eyes with severe complications of proliferative diabetic retinopathy. Our experience suggests, but does not prove, that silicone oil tamponade improves the prognosis in some otherwise unsalvageable cases. Among 11 (48%) of 23 eyes in this series, silicone oil was used initially at the time of repeat vitreous surgery. Short term retinal reattachment was achieved in eight (73%) of these eyes. Among these 11 eyes, nine had follow up of at least 6 months, and retinal reattachment was maintained in five (56%) of these nine with a single operation. Overall, 10 eyes failed initial PPV with or without SOI, underwent repeat PPV and SOI, and had at least 6 months' follow up. Retinal reattachment without phthisis was achieved in seven (70%) of these eyes. Since the initial vitrectomies employed modern surgical techniques, these results indicate that even in the modern surgical era, use of silicone oil can improve anatomical (and functional) outcome in selected cases.

**M A Zarbin, R Grigorian**

Institute of Ophthalmology and Visual Science, Rm 6156 006, 90 Bergen Street, Newark, NJ 07103, USA

Correspondence to: Marco A Zarbin, Institute of Ophthalmology and Visual Science, Rm 6156 006, 90 Bergen Street, Newark, NJ 07103, USA; zarbin@umdnj.edu

Accepted for publication 22 May 2003

## References

- 1 **Castellarin A, Grigorian R, Bhagat N, et al.** Vitrectomy with silicone oil infusion in severe diabetic retinopathy. *Br J Ophthalmol* 2003;**87**:318–21.

- 2 **Grigorian R**, Castellarin A, Forgan R, *et al*. Epiretinal membrane removal in diabetic eyes: comparison of viscodissection with conventional methods of membrane peeling. *Br J Ophthalmol* 2003;**87**:737–41.

## Primary scleral buckle placement during repair of posterior segment open globe injuries

We read with interest the recent article by Arroyo and associates.<sup>1</sup> They are to be commended on a very interesting study to compare the visual and anatomical outcomes of patients who underwent primary scleral buckle placement during posterior segment open globe repair with matched control patients who did not undergo primary scleral buckle placement.

Prophylactic scleral buckle of posterior segment open globe injuries has been a controversial topic in ophthalmology. The value of scleral buckling to support peripheral and especially inferior breaks is rarely disputed. However, the utility of using an encircling buckle in the absence of retinal breaks remains controversial.

The benefits of primary scleral buckle placement are that it is technically easy and there is no scarring between the wound and overlying Tenon's capsule and conjunctiva. However, there are some important considerations against primary scleral buckle such as the perforating injury subsequent rhegmatogenous retinal detachment (RD) is often not directly related to the site of the posterior exit wound but develops secondary to a new retinal break in the vitreous base region within 2 clock hours of the wound.<sup>2</sup> In addition, it is usually difficult to place a buckle over the exit wound and involves potentially high morbidity (especially in the hands of an inexperienced doctor who usually receives the patient in the emergency room (at least in Venezuela)).

To counter subsequent traction at the vitreous base, a vitrectomy may be just as effective as a prophylactic scleral buckle, avoiding the associated morbidity.<sup>3</sup> If retinal incarceration occurs through the wound, secondary reconstruction must almost always be performed anyway, typically involving a scleral buckle and vitrectomy 10–14 days after the injury (when inflammation is under control, and the intraocular anatomical status has been assessed adequately).<sup>4</sup>

We believe that the results of the study by Arroyo and associates contribute to the understanding of the role of prophylactic primary scleral buckle in the treatment of posterior segment open globe injuries. Their impressive results suggest that the benefits of placing a prophylactic primary scleral buckle may outweigh the risks involved. A multi-centre randomised clinical trial is desirable to confirm their results.

**C F Fernandez, A J Mendoza,  
J Fernando Arevalo**

Retina and Vitreous Service, Clinica Oftalmologica  
Centro Caracas, Caracas, Venezuela

Correspondence to: J Fernando Arevalo, MD, Clinica Oftalmologica Centro Caracas, Centro Caracas PH-1, Av Panteon, San Bernardino, Caracas 1010, Venezuela; areval1@telcel.net.ve

Accepted for publication 26 March 2003

The authors have no proprietary or financial interest in any products or techniques described in this article.

## References

- 1 **Arroyo JG**, Postel EA, Stone T, *et al*. A matched study of primary scleral buckle placement during repair of posterior segment open globe injuries. *Br J Ophthalmol* 2003;**87**:75–8.
- 2 **Cooling RJ**. Immediate management of posterior perforating trauma. *Trans Ophthalmol Soc UK* 1982;**102**:223–4.
- 3 **Kuhn F**, Pieramici DJ. *Ocular trauma: principles and practice*. New York: Thieme Medical Publishers, 2002:277.
- 4 **Han DP**, Mieler WF, Abrams GW, *et al*. Vitrectomy for traumatic retinal incarceration. *Arch Ophthalmol* 1988;**106**:640–5.

## Author's reply

We read with interest the comments made by Fernandez and colleagues regarding our article.<sup>1</sup> We certainly agree that new breaks may develop in the vitreous base region within 2 clock hours of the scleral wound. Because of this, we advocate the use of encircling scleral buckles (3.5–5 mm wide) as opposed to segmental scleral buckles in patients undergoing primary open globe injury repair.

We agree that placing an encircling scleral buckle to support the posterior edge of the vitreous base does require more skill than simply closing an open globe wound. However, we have found that with adequate training, encircling scleral buckles can usually be placed after open globe injury repair in 15–30 minutes.

The timing of vitrectomy in cases of ocular trauma is controversial. We also try to wait at least 1–2 weeks before performing a vitrectomy, if necessary, in order to minimise the risks of very early (potential bleeding, inflammation, and poor visualisation) and very late (cellular proliferation) complications.

We agree that a prospective randomised clinical trial is needed to better delineate the role of primary encircling scleral buckle placement at the time of open globe injury repair.

**J Arroyo**

Correspondence to:  
Massachusetts Eye and Ear Infirmary, 243 Charles  
Street Boston, MA 02114, USA;  
jarroyo@massmed.org

Accepted for publication 28 May 2003

## Reference

- 1 **Arroyo JG**, Postel EA, Stone T, *et al*. A matched study of primary scleral buckle placement during repair of posterior segment open globe injuries. *Br J Ophthalmol* 2003;**87**:75–8.

## NOTICES

### Helping the blind and visually impaired

The latest issue of *Community Eye Health* (No 45) discusses help for the blind, with an editorial by Sir John Wall of the Royal National Institute for the Blind on the rights of blind people. For further information please contact: Journal of Community Eye Health, International Resource Centre, International Centre for Eye Health, Department of Infectious and Tropical Diseases, London School of Hygiene and Tropical Medicine, Keppel Street, London

WC1E 7HT, UK (tel: +44 (0)20 7612 7964; email: Anita.Shah@lshtm.ac.uk; website: www.jceh.co.uk). Annual subscription (4 issues) UK£28/US\$45. Free to developing country applicants.

### Second Sight

Second Sight, a UK based charity whose aims are to eliminate the backlog of cataract blind in India by the year 2020 and to establish strong links between Indian and British ophthalmologists, is regularly sending volunteer surgeons to India. Details can be found at the charity's website ([www.secondsight.org.uk](http://www.secondsight.org.uk)) or by contacting Dr Lucy Mathen ([lucymathen@yahoo.com](mailto:lucymathen@yahoo.com)).

### Specific Eye ConditionS (SPECS)

Specific Eye ConditionS (SPECS) is a not for profit organisation which acts as an umbrella organisation for support groups of any conditions or syndrome with an integral eye disorder. SPECS represents over 50 different organisations related to eye disorders ranging from conditions that are relatively common to very rare syndromes. The website acts as a portal giving direct access to support groups' own websites. The SPECS web page is a valuable resource for professionals and may also be of interest to people with a visual impairment or who are blind. For further details about SPECS contact: Kay Parkinson, SPECS Development Officer (tel: +44 (0)1803 524238; email: [k@eyeconditions.org.uk](mailto:k@eyeconditions.org.uk); website: [www.eyeconditions.org.uk](http://www.eyeconditions.org.uk)).

### The British Retinitis Pigmentosa Society

The British Retinitis Pigmentosa Society (BRPS) was formed in 1975 to bring together people with retinitis pigmentosa and their families. The principle aims of BRPS are to raise funds to support the programme of medical research into an eventual cure for this hereditary disease, and through the BRPS welfare service, help members and their families cope with the everyday concerns caused by retinitis pigmentosa. Part of the welfare service is the telephone help line (+44 (0)1280 860 363) for any queries relating to retinitis pigmentosa, especially for those recently diagnosed with retinitis pigmentosa (tel: +44 (0)1280 821 334; email: [lynda@brps.demon.co.uk](mailto:lynda@brps.demon.co.uk); website: [www.brps.demon.co.uk](http://www.brps.demon.co.uk)).

### Surgical Eye Expeditions International

Volunteer ophthalmologists in active surgical practice are needed to participate in short term, sight restoring eye surgery clinics around the world. Contact: Harry S Brown, Surgical Eye Expeditions International, 27 East De La Guerra, C-2, Santa Barbara, CA 93101-9858, USA (tel: +805 963 3303; fax: +805 965 3564; email: [hsbrown.md@cox.net](mailto:hsbrown.md@cox.net) or [seeintl@seeintl.org](mailto:seeintl@seeintl.org); website: [www.seeintl.org](http://www.seeintl.org)).

### Rise in organ transplant numbers

According to UK Transplant, the UK has seen the highest number of organ transplants in six years. Last year (1 April 2002 to 31 March 2003) 2777 patients had their lives saved or dramatically improved through the generosity of 1064 donors. This equated to a 6% increase compared to the previous 12 months (1 April 2001 to 31 March 2002). Furthermore during 2002–3, the highest number of people benefited from a cornea transplant for five years (1997–98) and 240 more people had their sight restored than the previous year. For further information see



UK Transplant's website ([www.uktransplant.org.uk](http://www.uktransplant.org.uk)).

### **Elimination of avoidable blindness**

The 56th World Health Assembly (WHA) considered the report on the elimination of avoidable blindness (doc A56/26) and urged Member States to: (1) Commit themselves to supporting the Global Initiative for the Elimination of Avoidable Blindness by setting up a national Vision 2020 plan by 2005; (2) Establish a national coordinating committee for Vision 2020, or a national blindness prevention committee to help implement the plan; (3) Implement the plan by 2007; (4) Include effective monitoring and evaluation of the plan with the aim of showing a reduction in the magnitude of avoidable blindness by 2010; (5) To support the mobilisation of resources for eliminating avoidable blindness. The WHA also urged the Director-General to maintain and strengthen WHO's collaboration with Member States and the partners of the Global Initiative for the Elimination of Avoidable Blindness as well as aid in the coordination and support of national capability.

### **Ophthalmic Anesthesia Society (OAS)— 17th Scientific Meeting**

The 17th Scientific Meeting of the Ophthalmic Anesthesia Society (OAS) will be held 3-5 October 2003 at the Westin Michigan Avenue Chicago, Chicago, USA. Programme co-chairs: Marc Allen Feldman MD MHS and Steven T Charles MD. The CME joint sponsor is the Cleveland Clinic Foundation; CME hours are pending. Fees

for OAS members are \$300; non-members \$475; students \$50. Further details: OAS, 793-A Foothill Blvd, PMB 119, San Luis Obispo, CA 93405 USA (tel: +1 805 534 0300; fax: +1 805 534 9030; email: [info@eyeanesthesia.org](mailto:info@eyeanesthesia.org); website: [www.eyeanesthesia.org](http://www.eyeanesthesia.org)).

### **Glaucoma Society 24th Annual Meeting and Dinner**

The Glaucoma Society 24th Annual Meeting and Dinner will take place on 20 November 2003, from 8:30 am to 5:00 pm at The Royal College of Physicians, London, UK. Further details: Ms Janet Flowers (email: [glausoc@ukeire.freereserve.co.uk](mailto:glausoc@ukeire.freereserve.co.uk)).

### **Detachment Course with international faculty on: Retinal and Vitreous Surgery with Case Presentations preceding the Annual Meeting of Iranian Society of Ophthalmology**

The detachment course with international faculty on: Retinal and Vitreous Surgery with Case Presentations preceding Annual Meeting of Iranian Society of Ophthalmology will be held on 29-30 November 2003 and 1-4 December 2003 respectively, at the Razi Conference Center, Hemmat Hyw, Tehran, Iran. Further details: Scientific programme: Prof Ingrid Kreissig, University of Tuebingen, Schleichstr. 12, Breuningerbau, 72076 Tuebingen, Germany (tel: +49 7071 295209; email: [ingrid.kreissig@med.uni-tuebingen.de](mailto:ingrid.kreissig@med.uni-tuebingen.de)). Local organisation: Dr Arman Masheyekhi, Dr Siamak Moradian, Dept of Ophthalmology, Labbanfinejad Medical Center, Pasdaran Ave, Boostan 9, Tehran, 16666, Iran (fax: +98 21 254 9039; email: [labbafi@hotmail.com](mailto:labbafi@hotmail.com)).

### **5th International Symposium on Ocular Pharmacology and Therapeutics (ISOPT)**

The 5th International Symposium on Ocular Pharmacology and Therapeutics (ISOPT) will take place 11-14 March 2004, in Monte Carlo, Monaco. Please visit our website for details of the scientific programme, registration, and accommodation. To receive a copy of the Call for Abstracts and registration brochure please submit your full mailing details to <http://www.kenes.com/isopt/interest.htm>. Further details: ISOPT Secretariat (website: [www.kenes.com/isopt](http://www.kenes.com/isopt)).

### **XVth Meeting of the International Neuro-Ophthalmology Society**

The XVth Meeting of the International Neuro-Ophthalmology Society will take place 18-22 July 2004, in Geneva, Switzerland. Further details: Prof. A Safran, University Hospital Geneva, c/o SYMPORG SA, Geneva (fax: +4122 839 8484; email: [info@symporg.ch](mailto:info@symporg.ch); website: [www.symporg.ch](http://www.symporg.ch)).

### **4th International Congress on Autoimmunity**

The 4th International Congress on Autoimmunity will take place 3-7 November 2004 in Budapest, Hungary. The deadline for the receipt of abstracts is 20 June 2004. Further details: Kenes International Global Congress Organisers and Association Management Services, 17 Rue du Cendrier, PO Box 1726, CH-1211 Geneva 1, Switzerland (tel: +41 22 908 0488; fax: +41 22 732 2850; email: [autoim04@kenes.com](mailto:autoim04@kenes.com); website: [www.kenes.com/autoim2004](http://www.kenes.com/autoim2004)).