

so occupied have, for the most part, received their training in the United States. There is a very good reason for this. Not until 1953 did a training program, based on the concept of the U.S. program as outlined above, begin in Canada when the University of Toronto commenced to offer a three-year program in oral surgery. Undoubtedly other Canadian dental schools will eventually follow suit and incorporate an oral surgery program in their graduate training. Thus, from this nucleus of young oral surgeons, the number of personnel practising this specialty will grow, and with their numerical

growth they will endeavour to bring the latest knowledge and best techniques to further the oral health of Canadian communities.

#### REFERENCES

1. Committee on Specialists and Specialization: Provincial regulations governing dental specialties, Appendix A, *In: Transactions of the Canadian Dental Association, 1960*, Canadian Dental Association, Toronto, 1960, p. 221.
2. THOMA, K. H.: *New Engl. J. Med.*, 257: 871, 927, 1957.
3. GULLETT, D. W.: Personal communication.
4. American Dental Association, Council on Dental Education: Hospital dental internships and residencies, approved by the Council on Dental Education (Revised to April 1, 1960), American Dental Association, Chicago, 1960.

## CASE REPORT

### Hernia Through the Foramen of Winslow

L. S. BLEVIS, M.D. and H. T. VAN PATER, M.D., *Toronto*

**H**ERNIA through the foramen of Winslow is a rare cause of intestinal obstruction which, if recognized preoperatively or at laparotomy, may be treated with good results. If the condition is not recognized, the prognosis is poor.

#### INCIDENCE

Roberts<sup>1</sup> found 64 cases of herniation through the foramen of Winslow in the literature prior to 1953, of which the first 30 had been summarized by Ullman<sup>2</sup> in 1924. Roberts added two cases and Khilnani, Lautkin and Wolf<sup>3</sup> found 10 additional cases up to 1959 and added one of their own, making 77 in all. There is a two-to-one predominance of males, and the age varies from 15 months to 77 years, the greatest incidence being between 20 and 60 years.

#### PATHOLOGY

The foramen of Winslow is bounded above by the liver, below by the first part of the duodenum, behind by the inferior vena cava, and in front by the free edge of the lesser omentum, containing the portal vein, the hepatic artery and the common bile duct. It normally admits one finger and allows entry into the lesser peritoneal sac. Of the 64 cases reported by Roberts, 45 cases involved herniation of the small bowel, 16 of the right side of the colon and cecum, and five of the transverse colon. Occasional cases have been described where the

hernia had ruptured through the lesser omentum, giving rise to a re-entrant hernia, such as the case recorded by Dorian and Stein.<sup>4</sup>

#### PATHOGENESIS

Moynihan and Dobson (quoted by Dorian and Stein<sup>4</sup>) have postulated that one or more of the following conditions must be present in order for herniation to occur: (1) a common mesentery for the entire intestinal tract; (2) absence of secondary fusion of the ascending colon to the parietal abdominal wall; (3) an abnormally large foramen of Winslow; (4) an abnormally long mesentery allowing undue mobility of the small bowel. Other authors<sup>4</sup> have suggested that an enlarged right lobe of the liver may also predispose to this type of hernia by forming a funnel-like approach to the foramen. It has also been postulated that individuals in whom this occurs may have a congenitally enlarged foramen of Winslow and that a sudden rise in intra-abdominal pressure due to muscular effort may result in the hernia. The predominantly male incidence may bear this out. Another factor which has been implicated is the gallbladder, which, with or without adhesions, may produce a funnel-shaped arrangement to direct viscera towards the foramen.

#### SYMPTOMATOLOGY

The symptoms are those of acute or subacute intestinal obstruction, and quite often the patients will give a history of a previous similar but milder attack. Usually there is a fairly sudden onset with pain in the upper abdomen. The only notable

From the Department of Pathology, St. Michael's Hospital, Toronto.

symptom, other than symptoms due to obstruction, appears to be pain on extending the trunk. This pain is relieved in some instances by sitting up, crouching forward, or assuming the knee-chest position. An important sign is epigastric or periumbilical swelling appearing soon after the onset of symptoms. Usually the swelling is in the midline, but occasionally it is in the right hypochondrium. Even in the presence of generalized abdominal distension the tumefaction in the epigastric or umbilical regions may be recognized. However, this sign is most easily recognized early, before the distension has become generalized.<sup>2</sup> The other signs are those of subacute or acute intestinal obstruction.

#### INVESTIGATION

Radiographic examination may show distended loops of bowel occupying the region of the lesser sac located medial and posterior to the body of the stomach. Some authors have used the barium enema and barium meal as aids to the diagnosis, but most authors feel that a barium meal is contraindicated in such cases. The laboratory findings are those of subacute or acute intestinal obstruction and the differential diagnosis is that of intestinal obstruction. Recognition of the possibility that this condition does exist is the main essential for diagnosis.

#### TREATMENT

Treatment consists of early laparotomy, and recognition and reduction of the hernia. In most cases reduction can be obtained by traction on the herniated bowel. Some authors have used sterile enterotomy to deflate the herniated portion of bowel and then reduce it. Others have opened through the lesser sac and reduced the bowel using direct vision on both sides of the foramen. Still others have performed *in situ* enterectomy within the lesser sac. Another method of reduction is to enlarge the foramen of Winslow either by digital dilatation or by dissection. According to Roberts,<sup>1</sup> this has been done in the cadaver by incising the peritoneal reflexion on the upper surface of the first part of the duodenum and developing an interval between the common bile duct and portal vein, although this has not been done in the living patient. The best maneuver to enlarge the foramen would seem to be mobilization of the second part of the duodenum and head of the pancreas by incising the lateral peritoneal reflexion. The free edge of the lesser omentum with its contained structures may be then swung forward away from the inferior vena cava, and the foramen is thus enlarged.<sup>2</sup> Methods used to prevent recurrence have been occlusion of the foramen by suture, or fixation of the cecum in the right iliac fossa. However, recurrence has rarely been recorded in those cases in which no special precautions of this sort have been taken.

#### PROGNOSIS

Of 66 cases recorded before 1953, 54 patients have been operated upon and 28 have recovered. Most authors report that gangrene of the incarcerated portion of bowel is rare, death being due to intestinal obstruction.

#### CASE REPORT

The patient was a 57-year-old white man, a known alcoholic, who had been told on clinical grounds that he had hepatic cirrhosis, but had refused hospitalization and was subsequently discharged from his work. He had had no previous hospital admissions. On September 6, 1960, in the evening, he noticed tightness in his abdomen and shortness of breath. During the next two days, this dyspnea increased until he could not sleep, and he had also developed vague abdominal pain. On the following night, that of admission, he collapsed and fell. His eyes rolled back, but he had no convulsions or incontinence. He was unconscious for approximately five minutes, and his pulse was unobtainable by the family doctor.

On admission to the emergency department on September 9 at 9 p.m., he did not admit to abdominal pain and had no complaints other than shortness of breath, relieved somewhat by sitting up. Physical examination revealed a thin, dark-skinned man in no acute distress, but markedly short of breath. The ears, nose and throat were normal. The trachea was in the midline. He had no apparent cough or sputum. The lung borders were elevated and there was very little movement of the diaphragm on respiration. The chest, however, was clear to percussion and auscultation. Examination of the cardiovascular system revealed a regular heart rate of 120 per minute; the heart sounds were somewhat obscured, and there was a harsh mitral diastolic murmur. The blood pressure was 60/40 mm. Hg, and the peripheral pulses were present. The abdomen was tense and tympanitic, but bowel sounds were heard. The liver was not palpable, and percussion revealed the lower edge to be at the right costal margin and the upper edge below the nipple line. No other masses or organs were palpable. There were bilateral direct inguinal hernias. The rectum was empty and no masses were felt. Genitourinary examination revealed small testes bilaterally. Neurological examination established that the cranial nerves and the motor system were intact, but sensation to pinprick was dull over both feet. The plantar responses were downgoing, and the remaining reflexes were normal. A radiograph of the chest was negative, but erect and supine abdominal films showed gross distension of the colon, with a large, markedly dilated loop of bowel in the mid-abdomen. This was interpreted as suggesting a low mechanical obstruction of the bowel, possibly a sigmoid volvulus. Gastric suction was applied and approximately 4000 c.c. of brownish fluid was obtained over the course of several hours.

Laboratory investigations revealed that the hemoglobin was 70% (10.9 g. %); the hematocrit, 35%; white blood count, 6950 per c.mm.; blood urea nitrogen, 15 mg. %; serum sodium, 75 mEq./l.; serum potassium, 2.9 mEq./l.; serum chlorides, 51.9 mEq./l.; and van den Bergh, neg./0.6. At 5 a.m. on the next day, his blood pressure became unobtainable. He was transfused with two bottles of blood and intravenous fluids. A repeat abdominal examination revealed total disappear-

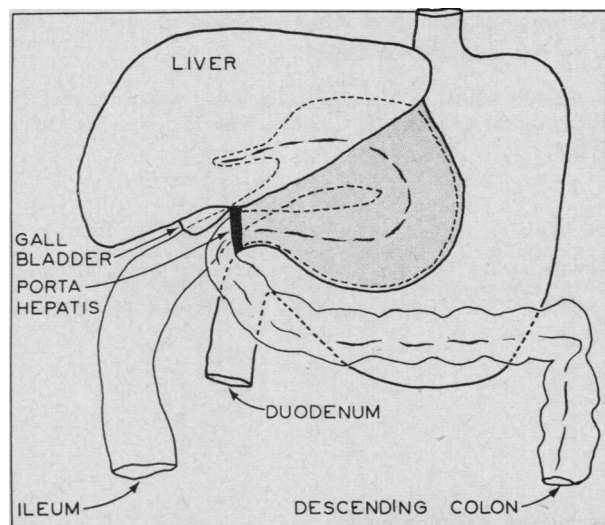


Fig. 1.—Schematic representation of the upper abdominal viscera as found at autopsy. The shaded portion represents the protruding lesser omentum overlying the hernia within the distended lesser sac. The black band indicates the foramen of Winslow through which the herniated ileum enters the lesser sac and the transverse colon emerges.

ance of bowel sounds, and he died at 11.20 a.m. on September 10, 1960.

#### Autopsy Findings

At necropsy, the body was that of a well-nourished, well-developed white man whose abdomen appeared distended. The external examination was otherwise unremarkable.

Internal examination revealed that the diaphragm was elevated. The liver was displaced to the right and the stomach to the left by a large greenish-grey, bulging mass in the left side of the epigastrium which was covered anteriorly by lesser omentum. On tracing the small bowel distally from the ligament of Treitz, the jejunum and ileum were not remarkable, but the distal 20 cm. of the ileum was markedly dilated and

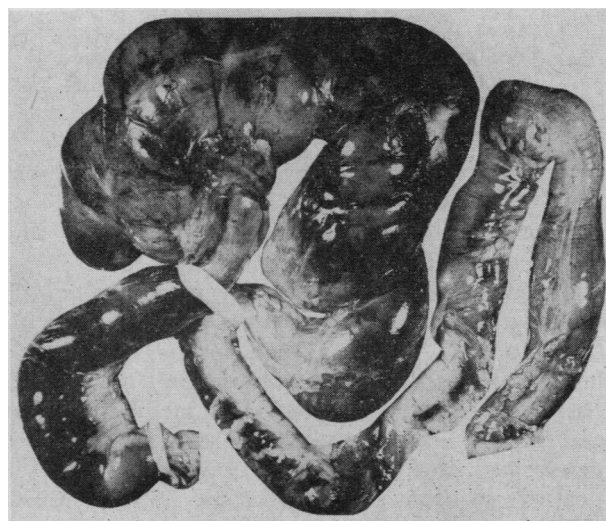


Fig. 2.—Photograph of the intestine after removal, repositioned to correspond with the location in the body. The lower tape is on the dilated distal ileum which lies in the right lower quadrant approximately opposite McBurney's point. The upper tape marks the foramen of Winslow through which the hernia enters into the lesser sac. The distended bowel above and to the right of this tape represents the herniated segment with the cecum on the left and the ascending colon on the right. The dark discoloured area in the mid-portion of the herniated segment is gangrenous. The collapsed distal transverse and descending colon is seen below and on the far right.

congested. The terminal ileum was traced upward into the foramen of Winslow, from which it could not be extracted. Emerging from the foramen was the mid-transverse colon which was also markedly congested. From the splenic flexure onwards, the colon was not remarkable. It then became apparent that the epigastric mass consisted of herniated discoloured intestine within the lesser sac. The hernia was reduced by cutting across the porta hepatis. It contained the terminal ileum, appendix, cecum, ascending colon, hepatic flexure and the proximal half of the transverse colon (Figs. 1 and 2). This entire segment of intestine was markedly congested and distended. Part of the ascending colon appeared gangrenous on gross examination and there was some fibrinous exudate on the surface of the cecum. It was estimated that the volume of the herniated organs was approximately three litres.

Of the structures forming the wall of the hernial sac, the lesser omentum showed congestion and fibrinous exudate on the surface adjacent to the hernia, as did the serosa of the stomach where it was in contact. The pancreas was not remarkable grossly. The left lobe of the liver showed very marked congestion, and the remainder appeared fatty. The liver weighed 2090 g. There was a small adenomatous polyp in the portion of transverse colon not involved in the hernia, and another in the descending colon. The lungs showed moderate atelectasis, anthracosis and slight emphysema. The heart, spleen, kidneys, adrenals, prostate and bone marrow were not remarkable. The head was not examined. Microscopic examination of the bowel involved in the hernia showed thrombosis of submucosal veins and early acute inflammation of the bowel from terminal ileum to ascending colon. Portions of the ascending colon showed gangrene. The lesser omentum showed congestion and early acute inflammation, as did the serosa of the stomach. The gastric mucosa also showed chronic gastritis with intestinalization of glands. The pancreas showed focal atrophy and acute fat necrosis, as well as inspissated secretion in the pancreatic ducts. The left lobe of the liver showed very marked congestion and atrophy of liver cords consistent with Zahn infarction. Both lobes showed marked fatty infiltration.

Microscopic examination of the thyroid was unremarkable. The aorta showed moderate atherosclerosis. The heart was unremarkable histologically. Microscopic examination of the lungs confirmed the gross observations. The spleen showed slight congestion, and the adrenals showed slight patchy loss of lipid. The esophagus revealed acute ulceration.

#### DISCUSSION

The various pathogenetic factors previously mentioned were not specifically investigated at the time of autopsy. However, in retrospect, it would appear that the most likely cause of the hernia in this case was undue mobility of the cecum and ascending colon, owing to their lack of fusion to the posterior abdominal wall. The enlarged fatty right lobe of the liver may also have contributed by channelling the mobile intestine to the foramen of Winslow. The size of the foramen was not precisely determined at autopsy, but, since the hernia resisted reduction by traction, the foramen probably was not enlarged.

As the diagnosis was not made until autopsy, it remains problematical whether or not operative reduction would have been successful in this case. It is clear, however, that early laparotomy and reduction or resection of the herniated intestine provides the only hope for survival.

#### SUMMARY

A brief review of intestinal hernia through the foramen of Winslow is presented. A case diagnosed at

necropsy is described which showed gangrene of the involved segment of bowel.

Thanks are due Mr. A. Smialowski, who prepared the illustrations, and Dr. R. C. Ross, who reviewed the manuscript.

#### REFERENCES

1. ROBERTS, P. A. L.: *Guy Hosp. Rep.*, 102: 253, 1953.
2. ULLMAN, A.: *Surg. Gynec. Obstet.*, 38: 225, 1924.
3. KHILNANI, M. T., LAUTKIN, A. AND WOLF, B. S.: *J. Mount Sinai Hosp. N.Y.*, 29: 188, 1959.
4. DORIAN, A. L. AND STEIN, G. N.: *Surgery*, 35: 795, 1954.

## SHORT COMMUNICATION

### The Velpeau Bandage

MICHAEL C. HALL, M.D., Ph.D., F.R.C.S.[C],\* *Toronto*

**F**RACTURES in the region of the shoulder are commonly treated by bandaging the arm across the chest, reducing the movement at the site of the fracture, improving the position of the fragments, and relieving the patient's discomfort. This form of treatment is usually referred to as the application of a Velpeau bandage, but it is extraordinary to see the number of different types of swaddling or encircling bandages, usually depending strongly on adhesive tape for their integrity, and often merely hiding rather than supporting the arm, that are applied in the name of Velpeau. It is perhaps of interest then to learn who Velpeau was, and how he used this bandage himself.

Larousse<sup>1</sup> states that Alfred Armand Louis Marie Velpeau was born in the château de La Brèche in Parçay, France, in 1795. The humble circumstances of his blacksmith father would not have permitted him to become educated. However, he apparently taught himself to read, and after finding some of the forerunners of the "do-it-yourself" type of medical book, began to give opinions on his neighbours' ills. He attracted the attention of a wealthy local farmer, who gave him some education with his own family, and supported him in his medical education at Tours, but only to a degree requiring considerable frugality on Velpeau's part. He was a very able and hard-working student who impressed his teachers so much that when he went to Paris to continue his studies he received some financial help from them. In Paris he taught in the School of Anatomy, and received his doctorate in 1823. He was appointed surgeon at the Pitié in 1830, and then Professor of Clinical Surgery. In a day when public address was so much more im-

#### ABSTRACT

Many varieties of swaddling bandages for injuries of the shoulder are in use and are called Velpeau bandages. Velpeau's original description has been consulted. The injured arm is placed across the chest and turns of bandage are made from beneath the sound axilla, over the injured shoulder, in front of the injured arm, and beneath the elbow, to pass again to the sound axilla. It is completed by transverse turns. Velpeau, a blacksmith's son, was born in 1795, became professor of surgery in Paris, and died in 1867 after a distinguished career.

portant a method of communication than it is now, he was said not to be a great orator; his depth of knowledge and scientific clarity made him nevertheless a respected speaker who commanded attention. He was a prolific author, and based his works largely on his personal experiences, as was the custom in other centuries. They included articles and widely used textbooks on surgery, obstetrics, gynecology, and anatomy. A few days before his death from acute prostatic disease in 1867 he was asked why he worked so hard, and was warned "Vous mourrez à La Brèche," to which he is said to have answered, "Pourquoi ne mourrais-je pas à La Brèche? J'y suis bien né."

The art of bandaging, since abandoned, is discussed in his text on operative surgery in a 65-page chapter<sup>2</sup> (Fig. 1). The method of bandaging under

\*Department of Anatomy, University of Toronto.