

REFERENCES

1. BRODY, H.: *Arch. Path. (Chic.)*, **33**: 221, 1942.
2. EDWARDS, J. E.: *Proc. Mayo Clin.*, **28**: 441, 1953.
3. MCKUSICK, C. A. AND COOLEY, R. N.: *New Engl. J. Med.*, **252**: 291, 1955.
4. HALASZ, N. A., HALLORAN, K. H. AND LIEBOW, A. A.: *Circulation*, **14**: 826, 1956.
5. NEILL, C. A. *et al.*: *Bull. Johns Hopkins Hosp.*, **107**: 1, 1960.
6. KIRKLIN, J. W., ELLIS, F. H., JR. AND WOOD, E. H.: *Surgery*, **39**: 389, 1956.
7. COOPER, G.: *London Medical Gazette*, **18**: 600, 1836.
8. PARK, E. A.: *Proc. N.Y. Path. Soc.*, **11-12**: 88, 1911-12.
9. STEINBERG, I.: *Ann. Intern. Med.*, **47**: 227, 1957.
10. BENDER, F., HILGENBERG, F. AND JUNGEHÜLSING, G.: *Z. Kreislaufforsch.*, **46**: 172, 1957.
11. LOGAN, F. *et al.*: *Ibid.*, **48**: 136, 1959.
12. BRUWER, A. J.: *J. Thorac. Surg.*, **32**: 119, 1956.
13. STEINBERG, I.: *Amer. J. Roentgenol.*, **81**: 280, 1959.
14. COOKE, F. N. *et al.*: *J. Thorac. Surg.*, **21**: 452, 1951.
15. SNELLEN, H. A. AND ALBERS, F. H.: *Circulation*, **6**: 801, 1952.
16. MANKIN, H. T. AND BURCHELL, H. B.: *Proc. Mayo Clin.*, **28**: 463, 1953.
17. BRAUNWALD, E., LOMBARDO, C. R. AND MORROW, A. G.: *Brit. Heart J.*, **22**: 385, 1960.

Needle Biopsy as an Aid to the Precise Diagnosis of Intrathoracic Disease

M. ARONOVITCH, M.D., F.R.C.P.[C],* J. CHARTIER, M.D.,†
L. M. KAHANA, M.D.,‡ J. F. MEAKINS, M.D., F.R.C.P.[C]§
and M. GROSZMAN, M.D.,¶ *Montreal*

IN MANY cases of intrathoracic disease the usual clinical and laboratory investigations may fail to provide a definite diagnosis. When potentially dangerous modes of therapy, such as radiation or chemotherapy, are to be used, it is essential to make a definite diagnosis before treatment is instituted. Pathological examination of a piece of the involved tissue then becomes necessary. The clinical or radiological diagnoses of neoplasms by themselves are not sufficient grounds for starting potentially dangerous treatment. The following is a case in point.

CASE 1.—A.C., a 67-year-old man, was transferred to the Queen Mary Veterans' Hospital, Montreal (Q.M.V.H.), from another hospital on October 28, 1960, with a diagnosis of bronchogenic carcinoma. The latter impression was based on an 18-month history of cough, purulent sputum, wheezing, dyspnea and fatigue, associated with an irregular density in the lingular segment of the left upper lobe on his chest roentgenogram (Fig. 1). The initial diagnostic impression at this hospital was also that of bronchogenic carcinoma. Various diagnostic procedures including cytological studies, scalene node biopsy and bronchoscopy were, however, negative. A thoracotomy was deferred in view of the very frail condition of the patient, and a course of antibiotic therapy was tried with the result that not only did the patient improve symptomatically but some clearing of the radiographic density was observed. Further observation of the density during outpatient visits and in the course of a subsequent admission revealed progressive diminution

ABSTRACT

The place of needle biopsy of the lung and pleura in the diagnosis of intrathoracic disease was assessed by means of an analysis of the results of this procedure in 78 cases involving 111 separate biopsy attempts. The Vim-Silverman needle was used throughout. Needle biopsy of the lung, restricted to cases with localized radiological lesions peripherally situated and suggesting neoplasm, yielded a specific diagnosis in 29 of 48 patients. The comparison with other diagnostic aids, bronchoscopy, sputum cytology and scalene node biopsy, was favourable, at least in the case of peripheral tumours. There were eight complications, only three of which were of significance. Needle biopsy of the pleura proved to be a less rewarding procedure, a specific diagnosis being obtained in only seven of 30 cases. There were, however, no serious complications with this latter procedure. It was concluded that needle biopsy is of some value as a relatively safe addition to diagnostic techniques in chest disease.

of its size (Fig. 2), and the final impression was of a chronic (non-neoplastic) pneumonitis of undetermined etiology.

It is obvious that if the original impression of bronchogenic carcinoma had not been subjected to closer scrutiny, this patient could have been exposed to the hazards of radiation or chemotherapy. In either case more harm than good would have been done. Had there been some certain method of arriving at a diagnosis, the indications for therapy would have been more exact.

From the Chest Service, Queen Mary Veterans' Hospital, Montreal, and the Mount Sinai Sanatorium, Prefontaine, Quebec.

*Co-Chief of Chest Service, Queen Mary Veterans' Hospital; Associate Physician, Royal Victoria Hospital; and Medical Director, Mount Sinai Sanatorium.

†Pathologist, Queen Mary Veterans' Hospital.

‡Research Fellow in Chest Diseases, Queen Mary Veterans' Hospital.

§Co-Chief of Chest Service, Queen Mary Veterans' Hospital; and Physician, Royal Victoria Hospital.

¶Assistant Medical Director, Mount Sinai Sanatorium.

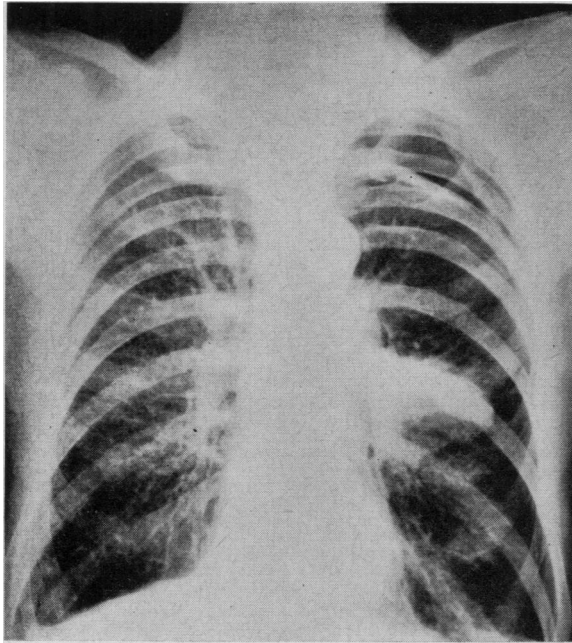


Fig. 1

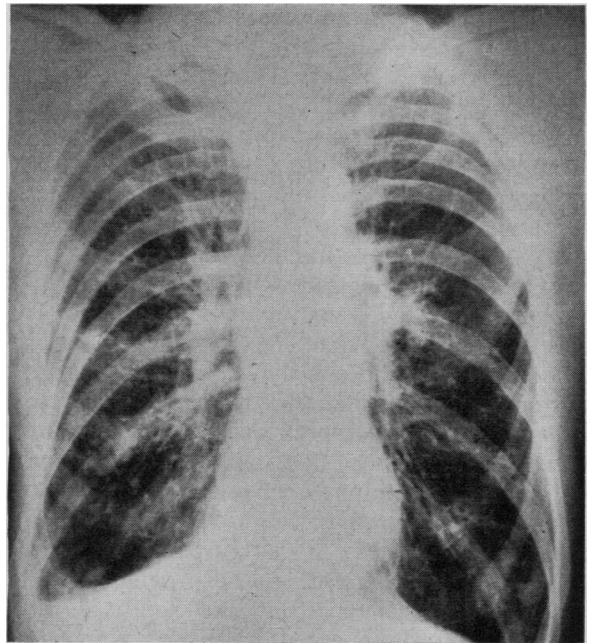


Fig. 2

Fig. 1.—Case 1. Posteroanterior chest radiograph, October 31, 1960, showing irregular density involving lingular segment of left upper lobe. Fig. 2.—Case 1. Posteroanterior chest radiograph, November 20, 1961, demonstrating almost complete clearing of the previously noted density.

If the lesion involves the bronchial tree and some abnormality can be seen through the bronchoscope, a bronchial biopsy may furnish the answer. Where lesions are more peripherally situated however, beyond the bronchoscopic field of vision, other measures may become necessary.

Open thoracotomy, as was contemplated in the aforementioned case, may then be performed. When this procedure is contraindicated or considered unnecessary for any particular reason, the other measures which may be considered should include needle biopsy of the lung or pleura.

Despite many years of trial the technique of lung puncture to obtain tissue for histological examination does not seem to have become firmly established as a diagnostic aid. Two reasons may be advanced for this. On the one hand there is the fear of complications from the procedure itself, and on the other hand there is the feeling that the specimens obtained may be insufficient or unsatisfactory for diagnoses.^{1,2} If the complications could be avoided, the second objection would not be as valid, since even a proportion of diagnoses from a harmless procedure would be of some value.

Needle biopsy of the pleura, though only recently introduced, has been much more favourably received. Complications are reported to be few and the risks appear to be no greater than those of thoracentesis.³ In addition, the discovery of the frequency of non-tuberculous pathology in idiopathic pleural effusions,⁴ previously usually considered tuberculous even in the absence of bacteriologic proof, has underscored the advisability of attempting to obtain pleural tissue for diagnosis in these cases.

In order to assay the validity of prevailing opinions concerning these methods, we have reviewed, in the present study, our experience going back to 1947 with lung and pleural biopsy techniques. The Vim-Silverman needle, initial reports of which, in pleural and lung biopsy, appeared in 1955 and 1960 respectively,^{5,6} was used in all cases but with modifications in technique and application from that described in the literature.

In the case of lung biopsy, the procedure has been confined generally to cases in which a tumour was suspected and in which the roentgenogram revealed a localized lesion impinging on the pleural surface or close to it in the underlying lung. It is felt that the chances of encountering serious hemorrhage are reduced by strictly avoiding cases with diffuse pulmonary pathology and limiting biopsy attempts to those with localized lesions. The site of biopsy is chosen with the help of the chest radiographs and by percussing out the area of maximum dullness. The depth of insertion of the needle is judged from the chest radiograph. Breath holding is not required during the procedure. No pre-anesthetic medication is given. Any suitable anesthetic such as procaine, 1 or 2%, may be used for local anesthesia.

The technique of using the anesthetizing needle and syringe is very important. The anesthetizing needle is, in effect, an exploring needle. Once the point of the needle is judged to be at the pleural surface, if the anesthetic flows in very rapidly from the syringe, there is a good possibility that a free pleural space exists. On disengaging the needle from the syringe at this point, if one can hear the hiss of air entering the needle with the patient's

inspiration, then a pneumothorax will be induced and there will be no point in proceeding further with the attempted biopsy. The presence of a pneumothorax, it should be explained, makes it difficult if not impossible to obtain a bite of lung tissue and is associated with the added hazard of increasing the size of the pneumothorax by further lung puncture.

If no pneumothorax is induced, the needle is inserted further and penetrates the lung. On applying suction, air bubbles may enter the syringe. If there is a free pleural space, this will again result in a pneumothorax, and one should again disengage the syringe and listen for possible air entry into the chest. If a pneumothorax does not result, one may proceed with the biopsy. If, however, on pulling back on the plunger of the syringe, a flow of blood is encountered, it would be dangerous to proceed with the biopsy in this particular location for fear of hemorrhage. If the exploring needle seems to enter resistant tissue, the depth of the needle should then be noted, since this is a safe depth for insertion of the biopsy needle and is an indication that the procedure may produce a satisfactory piece of tissue.

With regard to the manipulation of the Vim-Silverman needle itself, the trocar with the obturator in place is first inserted to the desired depth, the obturator is then withdrawn and the biopsy shaft is introduced into the trocar to its full depth. The trocar and contained biopsy shaft are then rotated together through two or three full turns. Finally, the trocar is advanced about 2 cm. over the biopsy shaft and the whole unit is withdrawn, a cylinder of tissue presumably being trapped in the biopsy shaft.

The illustration in Fig. 3 indicates the steps in the procedure.

Cases selected for pleural biopsy are not so limited and include those with any diagnostic problem, with either effusion or pleural thickening, except for individuals with a hemorrhagic diathesis. As in lung biopsy, local anesthesia is used, and the procedure is performed in either the sitting or recumbent position. The distance from skin to pleural surface is measured on the anesthetizing needle. The biopsy needle is then introduced at a tangent to the chest wall for a little less than this distance. The tangential insertion, it is thought, produces a more extensive bite of pleura than would a perpendicular insertion. The subsequent operation of the needle is then carried out as for lung biopsy.

The complications which might be encountered in the performance of lung or pleural biopsy may be listed as: (1) hemorrhage, (2) air embolism, (3) spread of malignancy or infection in the needle track, and (4) tension pneumothorax.

1. *Hemorrhage* is a potentially serious complication, particularly in needle biopsy of the lung. A small hemoptysis is of no consequence, but very

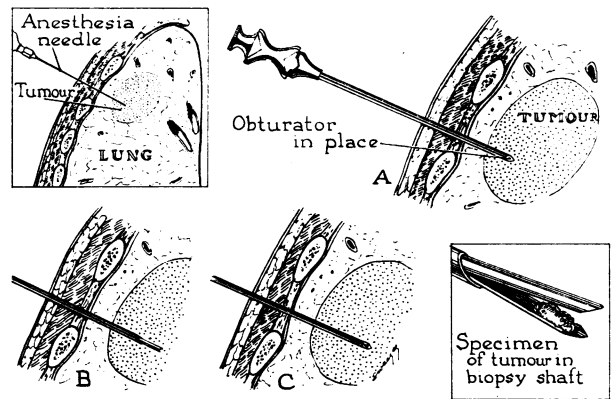


Fig. 3.—Steps in the technique of lung biopsy using the Vim-Silverman needle. The required depth of insertion is gauged from the anesthetizing needle (upper left insert). (a) The trocar is inserted into tumour with obturator in place. (b) Obturator removed and biopsy shaft inserted into trocar to its full depth. The whole unit is rotated through two or three full turns. (c) The trocar is advanced over the biopsy shaft for approximately 2 cm. before removal of the entire unit. The specimen of tissue is trapped between the blades of the biopsy shaft (lower right insert).

rare fatal hemorrhages have been reported by other observers. In order to avoid hemorrhage the following types of cases should not be subjected to this procedure: (a) The patient who has had a definite large hemoptysis is a poor risk, since one may dislodge a soft clot which is preventing further bleeding. (b) The patient who is a known bleeder for any reason, e.g. low prothrombin content, platelet deficiencies, receiving anticoagulants. (c) The person with a diffuse lesion, e.g. of miliary nodular distribution (Fig. 4). (It should be emphasized

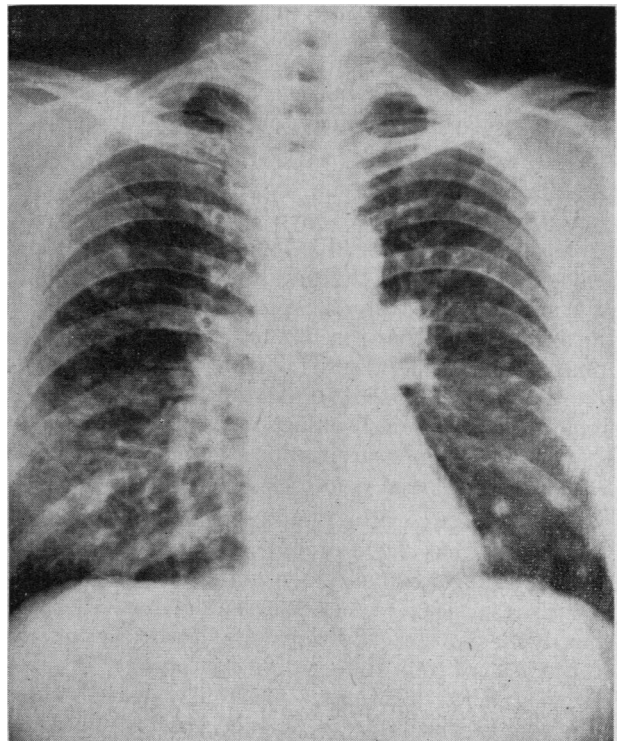


Fig. 4.—Posteroanterior chest radiograph showing diffusely scattered multiple nodular densities. Examination of a specimen of lung obtained at open lung biopsy revealed an adenocarcinoma.

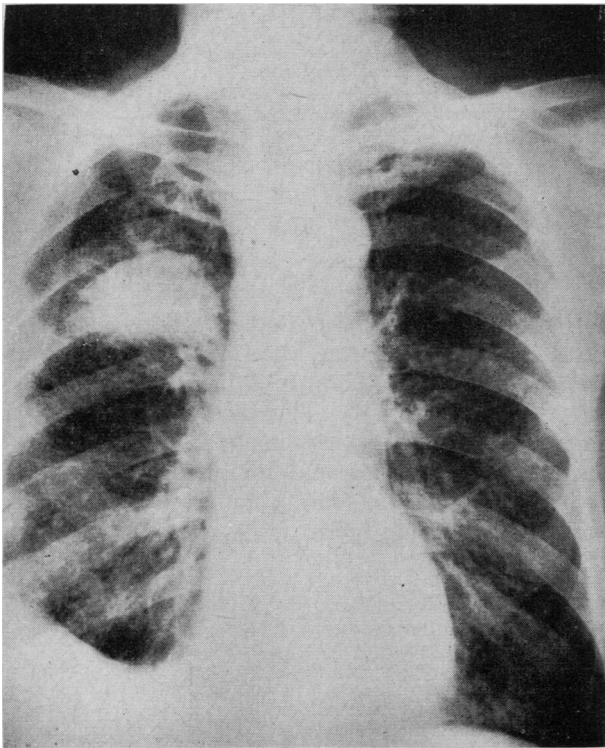


Fig. 5.—Posteroanterior chest radiograph demonstrating small right apical pneumothorax resulting from attempt to biopsy right upper lobe density.

that a biopsy in such a patient would be unsatisfactory in any case, since it is very difficult to biopsy spongy lung with a needle though it is relatively easy to penetrate and obtain a good specimen from a solid nodule of even small magnitude, down to 2 cm. in diameter.) (d) The person in whom there is the possibility or suspicion of aneurysm. (e) The person with a lesion close to the hilus or mediastinum where large vessels might be encountered and damaged.

2. *Air embolism* can be avoided by making certain with the exploring anesthetizing needle that no blood is drawn back from any point along the track along which the cutting biopsy needle will be inserted. This complication has never occurred in our series of cases.

3. *Spread of malignancy* along the needle track or in the lung after the procedure occurs. In the authors' experience it occurs more frequently after repeated aspirations of malignant effusions than after attempts at biopsy. The reason for this may be the fact that the cutting shaft of the Vim-Silverman needle is completely covered by advancing the trocar down over the cutting needle before the whole unit is withdrawn. This leaves the needle track clear of any contaminating organisms or cells.

4. With regard finally to *tension pneumothorax*, as will be seen from the results in the present series of cases, this is an infrequent occurrence. A small and asymptomatic pneumothorax (Fig. 5), which requires no special therapy, is seen not infrequently with attempted needle biopsy. As has already been suggested, both of the latter complications can be

TABLE I.—OVERALL RESULTS.

	Lung biopsies		Pleural biopsies	
	No. of cases	%	No. of cases	%
Total No. of cases.....	48		30	
	(69 biopsy attempts)		(42 biopsy attempts)	
Specific diagnosis from biopsy.....	29 (60.5%)		7 (23.3%)	
Cancer.....	29		3	
Bronchogenic cancer..	26		2	
Metastatic cancer....	2		0	
Mesothelioma.....	1		1	
Tuberculosis.....	0		4	
Biopsy non-contributory...	19 (39.6%)		23 (76.7%)	
Non-specific inflammation or fibrosis....	10 (20.8%)		9 (30%)	
Normal tissue.....	4 (8.3%)		0 (0%)	
Inadequate or no specimen.....	5 (10.8%)		14 (46.8%)	
Complications.....	8 (16.6%)		4 (13.3%)	
Asymptomatic pneumothorax.....	4		2	
Tension pneumothorax..	2		0	
Spread of tumour along needle track....	1		0	
Aspiration of liver tissue	1		2	

reduced to a minimum by restricting lung biopsies to those densities or tumours that are peripherally located in the lung.

RESULTS

The overall results are summarized in Table I. As can be seen, a specific diagnosis of either cancer or tuberculosis (other specific entities were not seen in this series) was obtained in a much higher percentage of lung biopsies, 60.5%, than in the case of pleural biopsy, in which the percentage of positive or contributory results was only 23.3%. Differentiation between primary and secondary neoplasms or between the different cell types of bronchogenic carcinoma was not usually possible on the basis of the needle biopsy specimen. The higher yield of non-contributory results in the case of pleural biopsy can be ascribed to several factors, among which are (1) the technical difficulty in locating the relatively thin pleural surface with the cutting shaft of the Vim-Silverman needle, (2) a less rigid selection of cases for pleural biopsy as compared with lung biopsy, resulting in a varied and often non-specific group of etiologies (Table II), and (3) patchiness or remoteness of the pathological lesion underlying a pleural effusion, so that the needle misses the pathological process but takes a piece of uninvolved pleura.

The number of complications has been expanded in the case of both lung and pleural biopsy by the inclusion in the list of minor or only potentially serious mishaps such as asymptomatic pneumothorax and liver puncture. As can be seen in Table I, there were actually no serious complications resulting from pleural biopsy and only three such complications (6.2%) in those subjected to needle biopsy of the lung. No deaths resulted, in this series, from needle biopsy.

TABLE II.—FINAL DIAGNOSES IN 29 CASES PRESENTING WITH PLEURAL EFFUSION OR THICKENING, WITH AVERAGE AGES AND TYPE OF EFFUSION

Final diagnosis	No.	Average age	Type of effusion			Thickening only
			Bloody	Serous	Unknown	
Idiopathic pleural disease	10	59	2	5	2	1
Malignancy	9	60	2	1	3	3
Tuberculosis	6	44	2	3	0	1
Non-specific inflammation	2	46	1	0	0	1
Traumatic effusion	1	63	1	0	0	0
Pulmonary infarction	1	64	1	0	0	0

These results are in contrast to the opinions of other investigators as to the relative value and safety of lung and pleural needle biopsy. In contrast to earlier unfavourable impressions, needle biopsy of the lung in our hands has been a fairly safe procedure and resulted in a high yield of specific diagnoses. On the other hand, in the case of pleural needle biopsy, though this is also demonstrated to be without significant risk, the percentage of contributory results is disappointingly low, at least when the procedure is performed with the Vim-Silverman needle.

TABLE III.—COMPARISON OF DIAGNOSTIC METHODS IN THE 38 CASES OF BRONCHOGENIC CARCINOMA FROM THIS SERIES

	Cytology	Broncho- scopy	Scalene biopsy	Needle biopsy
No. of cases	36	28	13	38
Positive tissue diagnosis of malignancy	11	5	3	26
% positive tissue diagnosis	30%	17%	23%	68%

In Table III the efficacy of needle biopsy as a diagnostic aid is contrasted with other methods of achieving a tissue diagnosis in the 38 cases of bronchogenic carcinoma seen in the present series. The results with each method are not, it should be emphasized, strictly comparable and are weighted against both bronchoscopy and scalene node biopsy which was performed in only a minority of cases. In the case of bronchoscopy, this was being performed in a series composed of either peripheral lung tumours or those producing a pleural effusion. In these cases this method is therefore less likely to be of value than in cases of tumours located near the hilum. The relatively high percentage of positive results obtained with needle biopsy suggests, however, that needle biopsy of the lung or pleura has definite value as a diagnostic aid in the case of bronchogenic carcinoma, particularly in those tumours which are beyond the reach of the bronchoscope.

In the past few years improvement has occurred in cytological methods. Cytological diagnosis was not as accurate in the earlier cases of this series as it is at the present time.

Results in another series have suggested that the report of non-specific inflammation or fibrosis, in the case, at least, of pleural biopsy, did not exclude the possibility of more serious pathology.³ Because

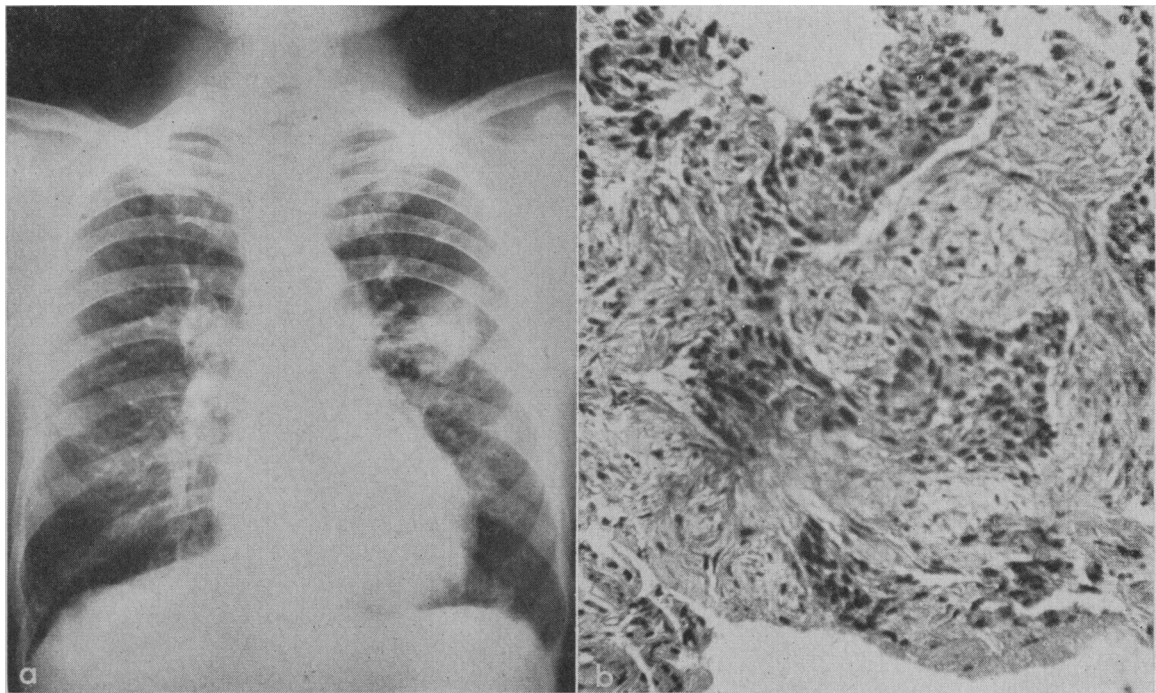
of this, an analysis was made of the 19 cases, in both lung and pleural biopsy series, in which a report of non-specific fibrosis or inflammation was obtained (Table IV). The fact that a final diagnosis of malignancy was made in no less than 10 of these suggests the need for further study of any such cases, with, in some instances, repeat biopsies or even open lung biopsy.

TABLE IV.—FINAL DIAGNOSIS IN CASES WHICH REVEALED ONLY NON-SPECIFIC INFLAMMATION OR FIBROSIS ON NEEDLE BIOPSY OF LUNG OR PLEURA

	No.
Total No. of cases	19
Final diagnosis, obtained through autopsy or other tissue evidence	10
Bronchogenic carcinoma	7
Metastatic carcinoma of lungs	2
Pulmonary infarction	1
Final diagnosis, arrived at through clinical impression (response to therapy, gross bronchoscopic appearance, etc.)	4
Bronchogenic carcinoma	1
Pulmonary tuberculosis	1
Traumatic pleural effusion	1
Lung abscess	1
Final diagnosis—uncertain	5

ILLUSTRATIVE CASE REPORTS

CASE 2.—W.B., a 48-year-old man, was admitted to the Q.M.V.H. on February 15, 1961, subsequent to the discovery on a chest roentgenogram of a well-circumscribed density in the left mid-lung field (Fig. 6a) which had in retrospect been present since 1959 and had become larger. He carried a diagnosis of chronic bronchitis with a history of chronic cough and dyspnea going back to 1941, with no recent change in his condition. Physical examination revealed only restricted expansion of the chest, with diffuse respiratory rhonchi on auscultation. He was afebrile. The hemogram was normal; the hemoglobin value was 15.4 g. %, leukocyte count 10,500 per c.mm. and sedimentation rate 15 mm. per hour (Wintrobe). Sputum smear and culture revealed only "usual flora" and were negative for acid-fast bacilli. Three sputum specimens were positive on cytological examination for malignant cells. Bronchoscopy on March 8, 1961, disclosed slight thickening of the segmental divisions of the right upper lobe bronchus. A bronchogram was reported as showing distortion and incomplete filling of the anterior segmental branch of the left upper lobe bronchus. On March 18, 1961, a needle biopsy of the left mid-lung field mass was performed. Examination of the microscopic specimen obtained was reported as revealing "dense fibrous tissue and some lung tissue which has been invaded by a malignant epithelial new growth. This tumour is constituted of small solid masses



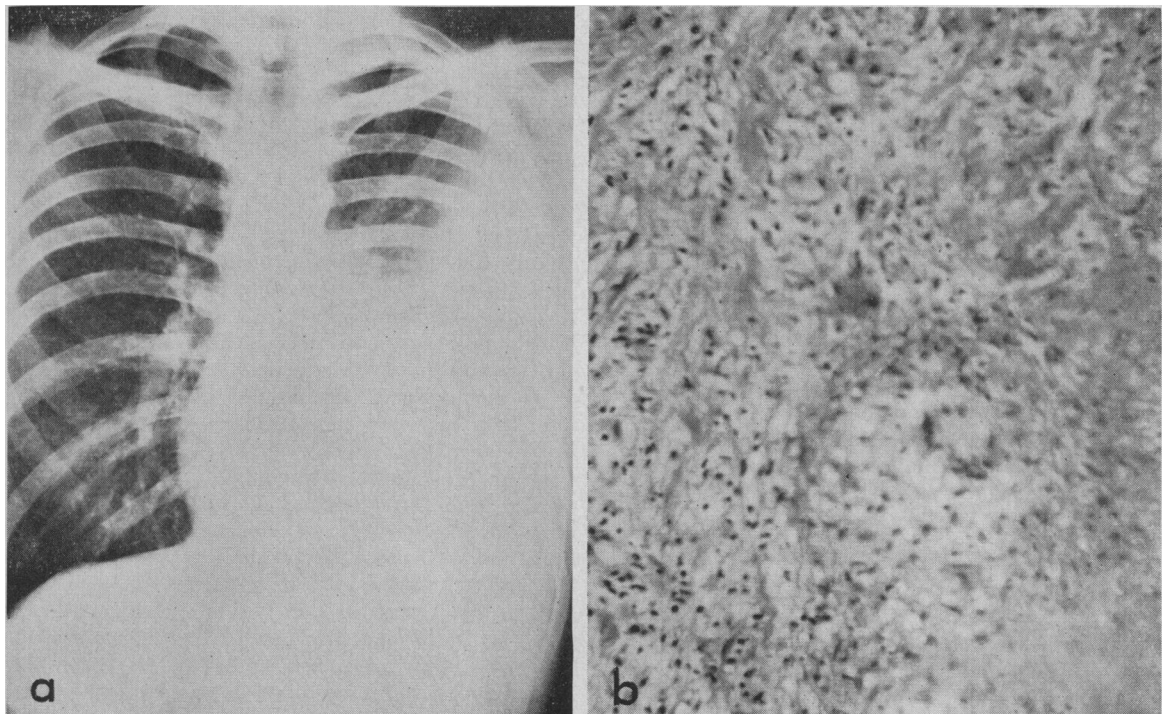
Figs. 6a and b.—Case 2. (a) Posteroanterior chest radiograph with well-circumscribed lesion in left mid zone. (b) Photomicrograph of specimen obtained by needle biopsy of this lesion (hematoxylin, eosin and saffron, $\times 400$). The section shows a dense fibrous reaction in lung tissue with infiltration by vaguely epidermoid malignant cells in solid masses.

of epithelial cells, vaguely epidermoid in type.” The pathological diagnosis was bronchogenic carcinoma, epidermoid in type (Fig. 6b).

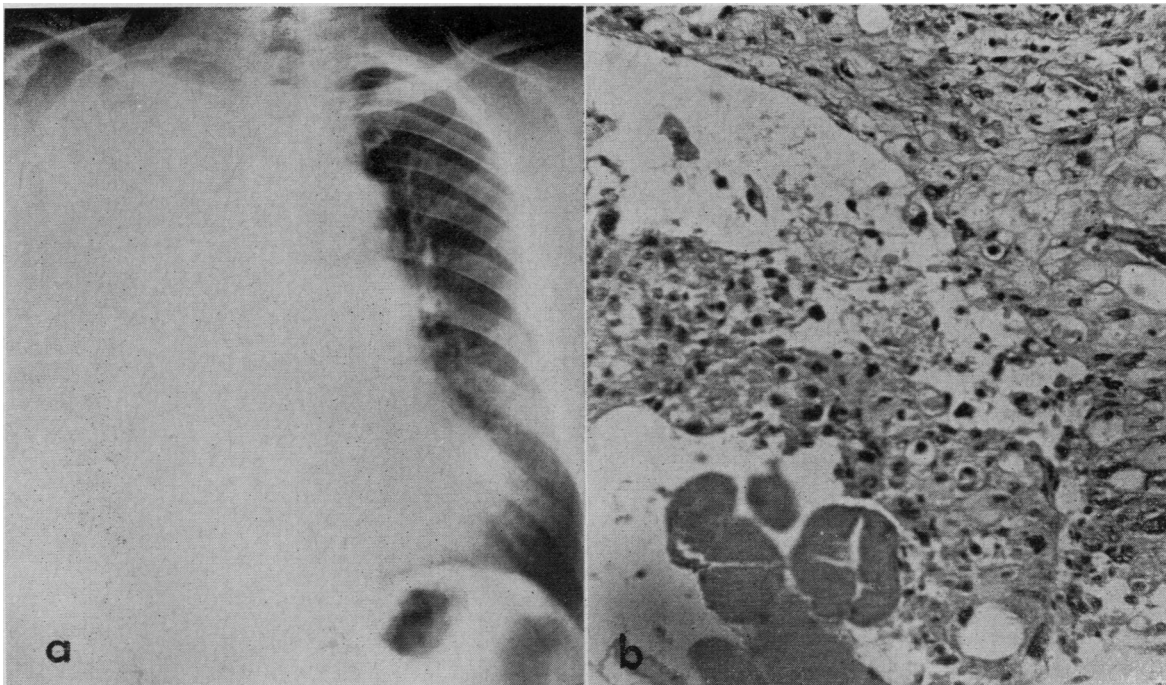
After a left scalene node biopsy was performed and was reported negative for malignancy, the patient underwent thoracotomy on April 24, 1961. At operation a firm tumour mass was found in the apex of the left

lung with spread to involve the pleural dome. Two large mediastinal nodes, apparently infiltrating the arch of the aorta, were also noted. The patient was considered inoperable, and the operative incision was closed without further intervention.

Radiographs taken subsequently have suggested slow growth of the tumour.



Figs. 7a and b.—Case 3. (a) Posteroanterior chest radiograph showing massive left pleural effusion. (b) Photomicrograph of pleural biopsy specimen (hematoxylin, eosin and saffron, $\times 400$). Tuberculous granulation tissue with a Langhans' giant cell.



Figs. 8a and b.—Case 4. (a) Posteroanterior chest radiograph showing massive opacification of the right hemithorax due to fluid. (b) Photomicrograph of specimen obtained by needle biopsy of the pleura (hematoxylin, eosin and saffron, $\times 400$). The section shows striated muscle fibres in the lower left corner and above this collections of malignant epithelial cells infiltrating the pleura.

CASE 3—J.F., a 33-year-old mariner, was admitted to the Q.M.V.H. on August 2, 1960, with the complaints of fever, anorexia, mild dry cough and poorly localized chest pain on deep breathing, all of one week's duration. His temperature on admission was 102.5° F. There was flatness on percussion, diminished tactile fremitus and diminished breath sounds over the lower half of the left chest. A chest radiograph confirmed the presence of a massive left-sided pleural effusion (Fig. 7a).

His hemoglobin was 15 g. % with a leukocyte count of 11,400 per c.mm. and a sedimentation rate of 31 mm./hr. (Wintrobe). A thoracentesis was performed and serous straw-coloured fluid was obtained, which on examination had a specific gravity of 1.025 and contained 3.25 g. % of protein and 1500 leukocytes per c.mm., of which 90% were mononuclears. Smear examination and culture of the pleural fluid for ordinary pathogens were negative, and smears for acid-fast bacilli were negative.

On August 8, 1960, needle biopsy of the left parietal pleura was performed. Microscopic examination of the specimen revealed fibrous tissue infiltrated with lymphocytes; multinucleated giant cells with nuclei in a horseshoe formation were seen (Fig. 7b). The picture was consistent with a diagnosis of tuberculosis, and on this basis the patient was started on INH, PAS and adrenal steroids.

The diagnosis of tuberculosis was confirmed by positive pleural fluid cultures and guinea-pig inoculations, which were reported in November 1960 and February 1961, respectively.

CASE 4.—C.H., a 66-year-old man, entered the Q.M.V.H. for the first time on February 11, 1960, with complaints of shortness of breath, profuse perspiration and pain in the right shoulder tip for one

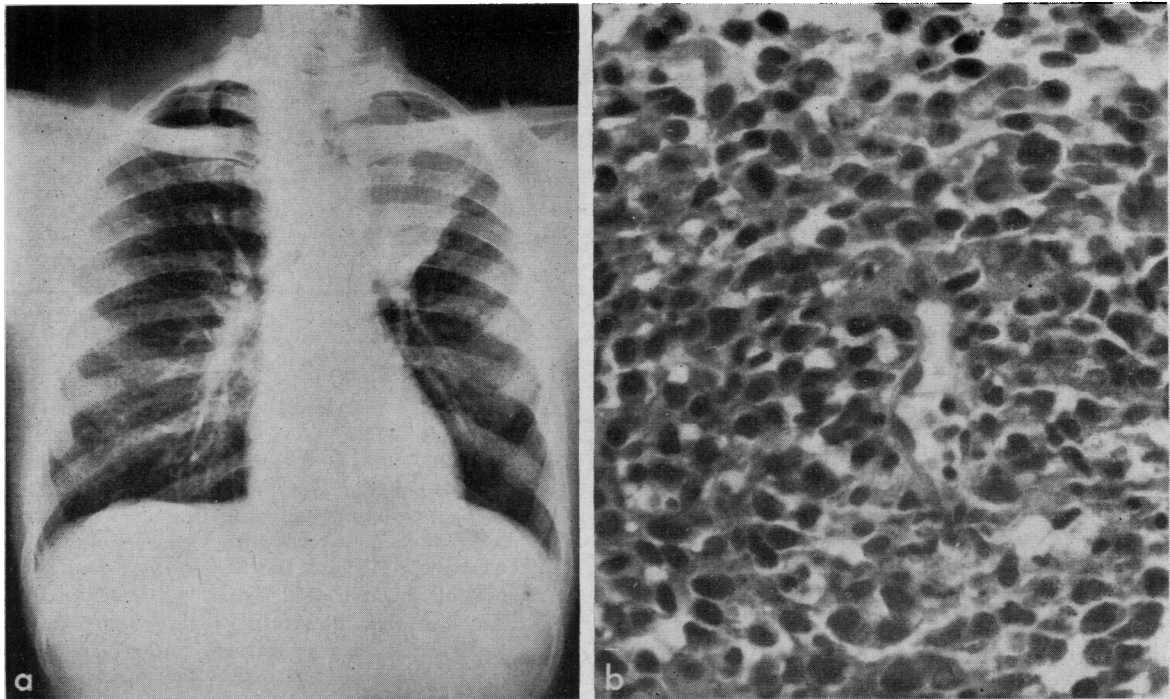
week. He gave a history of rheumatic fever at the age of 10 years. On examination his temperature was 101° F. per rectum, and his blood pressure was 180/100 mm. Hg. He was dyspneic and cyanosed. The right chest moved poorly and displayed generalized dullness, diminished breath sounds and diminished tactile fremitus. The cardiac apex was palpated in the sixth interspace, 4" from the midline. A grade III systolic murmur was present, heard loudest at the apex. The liver edge was palpated four fingerbreadths subcostally.

The chest roentgenogram showed marked opacification of the right hemithorax, thought to be due chiefly to fluid (Fig. 8a).

His hemoglobin was 16 g. %, leukocyte count 13,450 per c.mm. and sedimentation rate 6 mm./hr. (Wintrobe). Sputum cytology was positive for malignant cells. Pleural tapping yielded straw-coloured fluid with a protein content of 3.5 g. %. Smear examination and culture for ordinary pathogens and smear examination for acid-fast bacilli were negative. Cytological study revealed malignant cells.

On bronchoscopic examination (March 9, 1960) the carina was found to be deviated to the right. The separation between the right intermediate and middle lobe bronchus was thickened. The posterior segmental bronchus of the right lower lobe could not be seen, but a slight projection of tissue which might have been arising from the bronchial division was seen and was biopsied. The specimen was reported as showing normal bronchial wall tissue. Cytological examination of bronchial secretions was also negative for malignant cells.

A needle biopsy of the parietal pleura on the right side was performed on March 17, 1960, and a specimen was obtained which consisted of dense fibrous tissue heavily infiltrated by small collections of epithelial cells. These had hyperchromatic nuclei that varied in size and shape and indicated a diagnosis of carcinoma in the pleura (Fig. 8b).



Figs. 9a and b.—Case 5. (a) Posteroanterior chest radiograph showing density involving apical segment of left upper lobe. (b) Photomicrograph of specimen obtained by needle biopsy of this lesion (hematoxylin, eosin and saffron, $\times 450$). The section shows a collection of epithelial cells with darkly staining nuclei and little cytoplasm, suggesting an oat cell carcinoma.

No specific palliative therapy was given and the patient died on April 15, 1960. An autopsy was not performed, but the final impression was of bronchogenic carcinoma with secondary involvement of the pleura.

CASE 5.—F.B., a 58-year-old man, was admitted to the Q.M.V.H. on August 4, 1947, for treatment of an ulcer on the right knee of five weeks' duration. The cause of this was not determined and it healed spontaneously. While in hospital he complained also of a chronic cough of seven years' duration, with hemoptysis occurring in the two months before admission. Examination of the chest revealed only scattered expiratory rhonchi, but a chest radiograph disclosed a density over the apical portion of the left upper lobe with retraction of the trachea (Fig. 9a).

The admission hemogram revealed a sedimentation rate of 78 mm./hr. with a normal hemoglobin (90%) value and a leukocyte count of 8850/c.mm. Smear examinations and cultures of the sputum for ordinary pathogens and acid-fast bacilli were negative. A barium series was negative.

Bronchoscopy on August 25, 1947, revealed a normal bronchial tree.

A needle biopsy of the density at the left apex, performed on October 2, 1947, revealed two clumps of epithelial cells arranged around a blood vessel, with darkly stained nuclei and very little protoplasm. The appearance was thought to be compatible with a diagnosis of oat cell carcinoma (Fig. 9a).

On October 23, 1947, a left pneumonectomy was performed, with removal at the same time of two large hilar lymph nodes. Pathological examination of the resected lung revealed a tumour of the left upper lobe which on microscopic study was found to be an epidermoid carcinoma. Some hemoptysis and chest

pain occurred in the immediate postoperative period, but the patient's recovery was otherwise uneventful.

Subsequently he required further hospitalization for active pulmonary tuberculosis involving the right apex, from 1950 to 1954, and in 1957 for basilar artery thrombosis. Evidence of recurrence of malignancy has, however, not been found, and he is still living and aside from complaints of cough and exertional dyspnea is relatively well, 14 years after operation.

SUMMARY AND CONCLUSIONS

An analysis has been presented, with illustrative case reports, of 78 cases in which needle biopsy of the lung or pleura was performed, using the Vim-Silverman needle. The procedure is a relatively safe one, only three serious complications having occurred during or resulting from a total of 111 separate biopsy attempts. A fairly high yield of biopsy specimens enabling specific diagnosis was obtained in the case of peripheral localized lung lesions, contrasting with a lesser degree of success in the case of biopsy of pleural effusions or thickening. The results suggest that needle biopsy is of value as a diagnostic aid in certain cases of lung or pleural disease.

Our thanks are due Miss E. M. Swezey of the Medical Illustration Department for the illustrations, Mr. V. Frechette for the photographic reproductions of roentgenograms, and Miss V. Davidson for clerical assistance.

REFERENCES

1. ROSENBLATT, M. B. AND LISA, J. R.: *Cancer of the lung: pathology, diagnosis and treatment*, Oxford University Press, New York, 1956.
2. STOREY, C. F. AND REYNOLDS, B. M.: *Dis. Chest*, 23: 357, 1953.
3. DONOHUE, R. F., KATZ, S. AND MATTHEWS, M.: *Amer. J. Med.*, 22: 883, 1957.
4. HELLER, P., KELLOW, W. F. AND CHOMET, B.: *New Engl. J. Med.*, 255: 684, 1956.
5. DE FRANCIS, N., KLOSK, E. AND ALBANO, E.: *Ibid.*, 252: 948, 1955.
6. SABOUR, M. S. *et al.*: *Lancet*, 2: 182, 1960.