

the state of shock produced experimentally by the infusion of large doses of adrenaline and noradrenaline.

Treatment consisted of withdrawal of metaraminol bitartrate, restoration of the plasma volume with infusions of dextran and blood, and support of the blood pressure with minimal amounts of noradrenaline until the peripheral circulation recovered. Three of the four patients recovered completely from this shock syndrome, though two of these died later of their original disease.

The authors are indebted to Drs. B. L. Hession, J. H. Walker and C. G. Drake for permission to use the case histories. Dr. J. A. F. Stevenson's assistance in the preparation of this report was much appreciated. The assistance received through the Ruth Herman Knox Fellowship is gratefully acknowledged.

REFERENCES

1. CAMPBELL, G. S. *et al.*: *Dis. Chest*, 33: 18, 1958.
2. CORDAY, E. AND WILLIAMS, J. H., JR.: *Amer. J. Med.*, 29: 228, 1960.
3. ERLANGER, J. AND GASSER, H. S.: *Amer. J. Physiol.*, 49: 345, 1919.
4. FREEMAN, N. E.: *Ibid.*, 103: 185, 1933.
5. FREEMAN, N. E., FREEDMAN, H. AND MILLER, C. C.: *Ibid.*, 131: 545, 1941.
6. LANSING, A. M. AND STEVENSON, J. A. F.: *Ibid.*, 193: 289, 1958.
7. LILLEHEI, R. C., LONGERBEAM, J. K. AND ROSENBERG, J. C.: The nature of irreversible shock. *In*: Shock, pathogenesis and therapy, an International Symposium, edited by K. D. Bock, Springer-Verlag, Berlin, 1962, p. 106.
8. MOYER, J. H. AND BEAZLEY, H. L.: *Amer. Heart J.*, 50: 136, 1955.
9. NICKERSON, M.: Drug therapy in shock. *In*: Shock, pathogenesis and therapy, an International Symposium, edited by K. D. Bock, Springer-Verlag, Berlin, 1962, p. 356.
10. WEIL, M. H.: *Circulation*, 16: 1097, 1957.
11. YARD, A. C. AND NICKERSON, M.: *Fed. Proc.*, 15: 502, 1956 (abstract).

Renal Failure in Cirrhosis of the Liver

CARL A. GOESKY, M.D., C.M., F.R.C.P.[C]* and
GANRAJ KUMAR, M.D., C.M.,† *Montreal*

WITH the advent of knowledge which has enabled patients with cirrhosis of the liver to live through episodes of gastrointestinal bleeding and hepatic coma, death in acute renal failure has become common and will become increasingly more so. Three cases with cirrhosis of the liver terminating fatally in renal failure are reviewed here and the pathophysiology relating to the occurrence of this syndrome is considered.

CASE REPORTS

CASE 1.—Mr. B.J., a 58-year-old white photo-engraver, was admitted to hospital for the third and final time on November 18, 1960, with complaints of a 20-lb. weight gain over six months, anorexia and swelling of the ankles for two weeks, and a scant output of urine for five days. He had first been admitted to the hospital in 1951 with a history of drinking 12 quarts of beer per day. Physical examination at that time demonstrated an enlarged, palpable liver and ascites. The ascites resolved and the patient was well until 1958, when he developed pneumococcal pneumonia involving his right lower lobe. This responded rapidly to penicillin therapy in the hospital. His liver was palpable but no ascites was present. He continued drinking. Some weeks before his final admission he visited a brother convalescing from infectious hepatitis.

Physical examination showed a jaundiced male with a protuberant abdomen and an everted umbilical hernia, with prominent spider nevi over his upper trunk. He was quite alert on admission. The liver was palpable one and a half hands' breadth below the right costal margin and in the epigastrium. The flanks

ABSTRACT

The clinical course and autopsy findings of three patients with acute renal failure terminating the course of cirrhosis of the liver are presented. Review of the literature demonstrated that where decompensated cirrhosis is present the renal blood flow is characteristically low, although the total cardiac output is elevated. This circulatory disturbance results in the production of urine low in sodium, although normal in solute content. It also renders the kidney more vulnerable to further, sometimes minor, reductions in renal blood flow. As more patients with hepatic cirrhosis live through episodes of gastrointestinal bleeding and hepatic coma, death in acute renal failure will undoubtedly become more common.

were bulging, and shifting dullness was demonstrable in the abdomen. Pitting edema was present up to the knees.

The patient became less alert and more jaundiced, and then developed a liver "flap". His urinary output diminished further and by November 26 he was anuric. There was little response to therapy and he died on December 3. The serum bilirubin rose from 6 to 18.4 mg. %, the blood urea from 11 to 110 mg. %; and the serum bicarbonate fell from 27 to 18 mEq./l.

At autopsy, there was marked icterus, mild pitting edema, and 3 l. of ascitic fluid. The liver (2170 g.) presented the characteristics of postnecrotic cirrhosis, added to which there were the features of a patchy

*McGill University Medical Clinic, Montreal General Hospital, Montreal.
†Department of Pathology, Montreal General Hospital, Montreal.

but marked hepatocellular fatty vacuolization, patchy acute liver cell necrosis and degenerative swelling, together with marked intrahepatic bile stasis. The kidneys were grossly swollen and bile-stained (right 240 g., left 230 g.), and showed evidence of interstitial edema, with normal glomeruli and generally swollen tubules, a number of which exhibited coarse granular or finely vacuolar hydropic degeneration. There were many bile-stained casts, and the epithelium in occasional tubules was necrotic.

CASE 2.—Mrs. N.D., a 51-year-old French Canadian housewife, was admitted to hospital on August 4, 1962, semistuporous, jaundiced, and with ascites. She drank no alcoholic beverages. She had been admitted to another hospital with mild jaundice and ascites on May 11, 1962. A laparotomy and liver biopsy were performed. The biopsy was compatible with a diagnosis of postnecrotic cirrhosis. She was discharged on a diuretic regimen.

Ascites reaccumulated and she was admitted again on July 4. Multiple paracenteses and a stringent diuretic regimen were carried out, and she was discharged, to be admitted to the Montreal General Hospital five days later. Bilateral pleural effusions, ascites, icterus, absence of palpable liver and spleen, and extreme somnolence were noted. With hydration and the administration of salt-poor albumin she improved temporarily. The serum sodium was 114 mEq./l. On August 12, after paracentesis of 2 l., during the infusion of 25 g. salt-poor albumin, she became virtually anuric. Daily urinary volumes dropped from 600 ml. to less than 100 ml. She became more drowsy, and died on August 16. The serum albumin was 2.7 g. %; the serum glutamic oxalacetic transaminase, 280 units; the serum bilirubin rose from 2.8 to 18.0 mg. %; the urea nitrogen, from 28 to 47 mg. %; the serum potassium, from 3.8 to 6.7 mEq./l.; and the serum bicarbonate fell from 26 to 19 mEq./l.

Autopsy showed marked icterus, mild purpura, minimal peripheral edema, a protuberant abdomen containing 5.5 l. of ascitic fluid, and bilateral pleural effusions. The liver (660 g.) presented gross and microscopic features of postnecrotic cirrhosis, and minimal focal hepatocellular cytoplasmic fatty vacuolization. There was marked intrahepatic cholestasis without

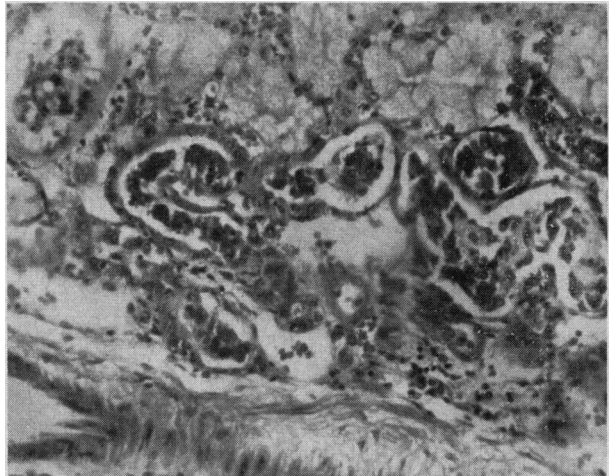


Fig. 2.—Case 2. Kidney, illustrating the hydropic or osmotic degeneration of convoluted tubules, the focal severe tubular degeneration and necrosis and bile-stained casts within these tubules, together with related focal interstitial edema and inflammatory cell reaction. (Original magnification, $\times 100$.)

extrahepatic duct obstruction (Fig. 1). The kidneys had a finely granular cortical surface (right 195 g., left 150 g.), were bile-stained and swollen. The tubules were diffusely swollen, the epithelium being finely granular and vacuolated, and there was interstitial edema. Pigmented casts (positive for bile) were numerous in the convoluted and collecting tubules. The glomeruli were normal (Fig. 2). There was chronic passive congestive splenomegaly (265 g.). Esophageal varices were present on microscopic examination.

CASE 3.—Mr. L.G., a 54-year-old salesman, was admitted to hospital for the last time on November 5, 1962, with confusion, somnolence, jaundice, and bleeding from esophageal varices. He had had an episode of jaundice as a boy, and a continuously large alcohol intake over the years. He was first admitted to hospital in 1957 with upper gastrointestinal bleeding and pneumonia involving the left lower lobe. Physical examination then showed the findings of pneumonia, a liver and spleen palpable to 4 cm. below the costal margin, a caput medusae with a venous hum, psoriasis, and mild rheumatoid type of arthritis. The pneumonia cleared and the bleeding ceased. He was admitted to hospital in 1960, and again in 1961, for acute alcoholism, and thereafter from June 1962 was continuously either in the acute ward or a convalescent hospital. He was admitted at that time with bleeding from esophageal varices and impending hepatic coma. The bleeding was controlled with an esophageal compression tube, and the impending coma with neomycin, enemas, and a low protein diet. Bleeding recurred in July and twice in August, 1962. The patient became icteric and increasingly confused during these episodes. He developed right lower lobe pneumonia which resolved under therapy. Finally, he was admitted for the last time with confusion, icterus, and bleeding esophageal varices. Esophageal compression stopped the bleeding and he improved briefly. His urinary output continued at levels of about 1 l. a day until November 24, when another massive hemorrhage occurred. Confusion became marked and his urinary output became scanty. He died on November 27, 1962. Prior to death his urea nitrogen, originally 16 mg. %, rose to 160 mg. %, and his bilirubin to 15 mg. %.

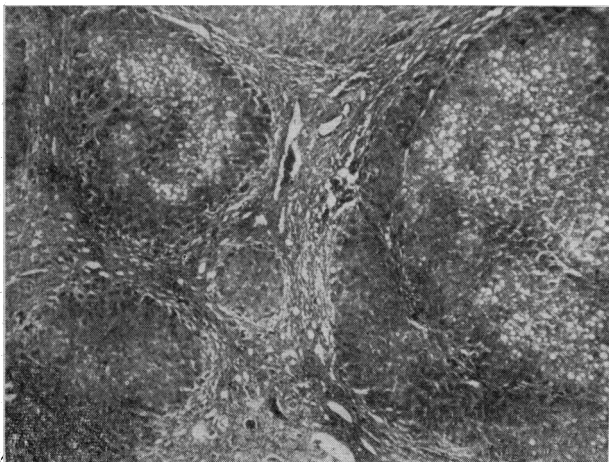


Fig. 1.—Case 2. Liver, showing widely variable nodules of parenchyma and extensive fibrosis, together with patchy hepatocellular fatty vacuolization. (Original magnification, $\times 25$.)

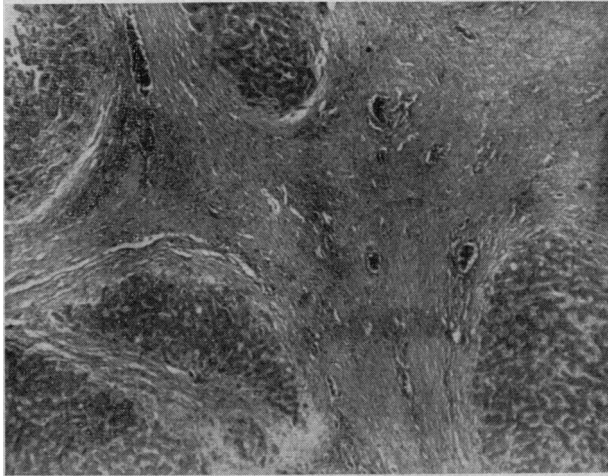


Fig. 3.—Case 3. Liver, with a broad fibrous scar and variable-sized nodules of parenchymal cells. (Original magnification, $\times 25$.)

At autopsy the findings were icterus and external hemorrhoids, esophageal varices with overlying mucosal erosion, and a large amount of blood, fresh and altered, throughout the gastrointestinal tract. Ascites was not present. The liver (1070 g.) showed a postnecrotic cirrhosis, with foci of fatty parenchymal vacuolization. There was no cholestasis, and bile pigmentation was not apparent. Many of the liver cells contained a coarse brown pigment shown to be hemosiderin (Fig. 3).

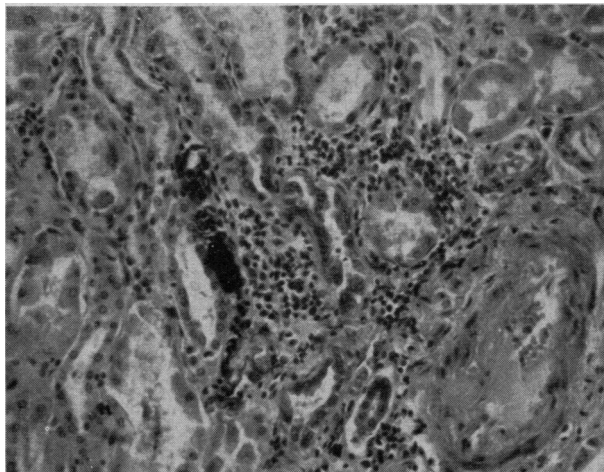


Fig. 4.—Case 3. Kidney, showing focal acute tubular degeneration with interstitial inflammatory reaction and older nephrocalcinotic degeneration of a renal tubule. (Original magnification, $\times 100$.)

Chronic congestive splenomegaly (530 g.) and multiple old splenic infarcts were present. The kidneys were uniformly enlarged (right 210 g. and left 230 g.) and swollen. Glomerular disease, significant vascular lesions, and bile pigmentation were not apparent. There was recent and remote tubular degeneration and necrosis, with zones of well-defined nephrocalcinosis (Fig. 4). To this was added a marked degree of hemosiderosis. Hemosiderin was also present in the pancreas, adrenals, and myocardium (probably post-transfusional).

DISCUSSION

The three cases described above illustrate a common final sequence of events in patients with

cirrhosis of the liver,¹ now that they more commonly survive acute bleeding episodes and episodes of coma, both spontaneous and induced by hemorrhage. The presence of nephrocalcinosis in the third case may indicate that areas of renal tubular necrosis had occurred at some time previous to the short terminal episode.

Papper, Belsky and Bleifer² have reviewed 22 patients with Laennec's cirrhosis of the liver who died in renal failure. In nine of these, mild gastrointestinal bleeding, insufficient to produce clinical evidence of shock, was the apparent precipitating cause; in three, abdominal paracentesis for tense ascites; in five, severe and progressive jaundice; and in the others, no precipitating cause was evident. In patients such as these, the only functional renal abnormality apparent prior to the onset of acute renal failure usually is oliguria and the output of urine which, although it may be 2 to 3.5 times as concentrated as plasma,³ may contain an extremely low content of sodium and chloride. Sodium excretion is greatly reduced, especially when ascites is forming, so that regardless of the intake, no more than 1 to 5 mEq. of sodium per day is usually excreted in the urine.⁵ During the early phase of acute renal failure, the urinary output may remain at its former level despite a steadily increasing azotemia.²

Lancetremere *et al.*⁵ measured simultaneously the cardiac output and the clearances of inulin or endogenous creatinine and para-aminohippurate in 21 patients with Laennec's cirrhosis. An elevated cardiac output was observed in these patients. Despite this, the glomerular filtration rate was less than 60 ml. per minute in seven of these patients, and there was a corresponding reduction in estimated renal blood flow. The renal fraction of cardiac output (calculated as [estimated renal blood flow]/[cardiac output]) was low for those patients who did not exhibit reduced renal hemodynamics as well as for those who did. The low renal fraction of the total cardiac output indicates that there is either a disproportionate increase in the renal vascular resistance or a gross decrease in the total peripheral vascular resistance, or both. The high cardiac output indicates that the total peripheral vascular resistance must be low; the circulation is hyperkinetic. Measurement of renal blood flow using the nitrous oxide technique confirms that in severe cirrhosis the renal blood flow is low, and that it may be even lower during acute renal failure.⁶

The changes in urine excretion produced by partial obstruction of the renal artery mimic those found in the patient with severe cirrhosis and apparently intact renal function. Davidson, Levinsky and Berliner⁷ constricted the right renal artery in a conscious dog, using a previously implanted device. The urine flow from the right side diminished, the rate of sodium excretion dropped disproportionately so that the urinary sodium concentration was much lower than on the control

side, yet the inulin clearance showed only a moderate decrease, compared to that on the experimental side. On restoration of renal blood flow to normal, the differences between the urine from the two sides disappeared. In light of the foregoing it is of interest that the administration of the pressor amine, metaraminol, is followed by an increase in urine flow, total solute excretion and sodium excretion in patients with cirrhosis.⁸ These observations suggest, then, that the changes in renal function observed in cirrhosis are responses to a change in the renal circulation and that this response is closely analogous to that observed after partial renal arterial obstruction.

The apparently increased susceptibility of these patients to acute renal failure may well have a functional basis. In those patients with already reduced renal hemodynamics, minor episodes which produce transient alterations in the renal circulation may impair the nutrition of the renal tubules to such a degree that acute renal failure results. In this context, the effect of the milieu upon the resistance of the tubule to deprivation of nutrition must be examined. In some of these patients, bilirubin levels are high, and a large proportion of the pigment present in the blood is in the unconjugated form. In infants, high levels of the unconjugated pigment result in kernicterus. Experimentally this pigment has been shown to uncouple phosphorylation from respiration in mitochondria.⁹ However, to exert toxicity at this site, the pigment must enter cells. Unconjugated bilirubin is sparingly soluble in aqueous media in the physiological pH range; it is carried in plasma bound to albumin. Using bilirubin-C¹⁴, Ostrow and Schmid¹⁰ demonstrated that, at concentrations encountered in clinical circumstances, bilirubin is virtually all bound and is not dialyzable. The toxic unconjugated pigment¹¹ will not be filtered at the glomerulus and does not appear in urine to any extent. In contrast, when obstructive jaundice is present, the conjugated glucuronide appears in the urine. Under these circumstances, Fulop and Brazeau¹² have been unable to produce changes

in bilirubin clearance which do not parallel the glomerular filtration rate. These observations suggest that unconjugated bilirubin is not transported by the renal tubular cell and that the pigment will not penetrate the undamaged cell, and so will have no effect. However, the circulatory changes accompanying severe cirrhosis may damage the renal tubular cells and break down the permeability barrier to unconjugated bilirubin. If this were to occur, the toxic effects consequent to high bilirubin concentrations would exaggerate the effects of anoxia.

SUMMARY

Three cases of acute renal failure in patients with severe cirrhosis of the liver have been presented. The pathophysiology preceding the onset of the syndrome has been reviewed. Two basic abnormalities in the circulatory pattern appear at this stage in cirrhosis—a high cardiac output coupled with a low total peripheral resistance, and a decreased renal blood flow. The renal circulatory changes lead to a characteristic pattern of urine production and also make the kidney more vulnerable to any further reduction in renal blood flow. The mechanism by which these circulatory changes come about is unknown.

We are indebted to Dr. W. H. Mathews, Pathologist-in-Chief, Montreal General Hospital, for his advice and helpful suggestions in the preparation of this manuscript.

REFERENCES

1. CHALMERS, T. C.: *New Eng. J. Med.*, 263: 23, 1960.
2. PAPPER, S., BELSKY, J. L. AND BLEIFER, K. H.: *Ann. Intern. Med.*, 51: 759, 1959.
3. PAPPER, S.: *Medicine (Balt.)*, 37: 299, 1958.
4. DAVIDSON, C. S.: Hepatic coma. In: *Advances in internal medicine*, vol. 7, edited by W. Dock and I. Snapper, Year Book Publishers, Inc., Chicago, 1955, p. 33.
5. LANCESTREMERE, R. G. et al.: *J. Clin. Invest.*, 41: 1922, 1962.
6. TYLER, J. M., JEFFRIES, J. L. AND WILDER, C. E.: *Clin. Res.*, 10: 194, 1962 (abstract).
7. DAVIDSON, D. G., LEVINSKY, N. G. AND BERLINER, R. W.: *J. Clin. Invest.*, 37: 548, 1958.
8. GORNEL, D. L. et al.: *Ibid.*, 41: 594, 1962.
9. ERNSTER, L.: The mode of action of bilirubin on mitochondria. In: *Kernicterus*, edited by A. Sass-Kortsák, University of Toronto Press, Toronto, 1961, p. 174.
10. OSTROW, J. D. AND SCHMID, R.: *Clin. Res.*, 10: 190, 1962 (abstract).
11. Editorial: *New Eng. J. Med.*, 267: 308, 1962.
12. FULOP, M. AND BRAZEAU, P.: *Clin. Res.*, 11: 240, 1963 (abstract).

PAGES OUT OF THE PAST: FROM THE JOURNAL OF FIFTY YEARS AGO

SMALLPOX AND CHICKENPOX

The spread of smallpox depends in part on wrong diagnoses; in part on concealment of cases; in part on the failure to report known or suspected cases; but chiefly on the neglect of vaccination. Mild cases often are confused with chicken-pox and, in general, many may not be seen by a physician unless a severe case calls for a general "round up," while many are never seen by physicians at all. Hence many alleged chicken-pox cases are smallpox and some alleged smallpox is really chicken-pox. The occasional failure to distinguish between mild smallpox and chicken-pox is due less to lack of information concerning smallpox than to unfamiliarity with, or disregard of, chicken-pox. The physician who has the chance to see either smallpox or chicken-pox should not fail to study minutely the lesions of the cases he encounters in correlation with the age of the lesions, especially during the acute stages.

Smallpox of the now prevailing type is regarded as a very trivial disease, because its physical injuriousness is far less than that of whooping-cough or measles; but from the standpoint of the future, its importance is enormous. Its existence means a large contempt for the disease, coupled with much disregard of vaccination. For example, too often the attempt is made to "size up" mild cases of smallpox on general principles and to regard it as not smallpox, merely because the symptoms are mild, the lesions few, and the course short. This policy throws all expert differentiation to the winds, abandons all exercise of professional observation, and adopts the lay attitude: "It is too mild for smallpox, therefore it is chicken-pox." As well might we follow the slogan of thirty years ago with regard to diphtheria: "The cases that die are diphtheria; the others are not."—H. W. Hill: *Canad. Med. Ass. J.*, 4: 115 and 118, 1914.