

Systemic dissemination of *Pneumocystis carinii* pneumonia

CHARLES F. AWEN, M.D., C.R.C.P.[C], F.A.C.P. and
M. A. BALTZAN, M.D., F.R.C.P.[C], Saskatoon, Sask.

Extrapulmonary dissemination of *Pneumocystis carinii* pneumonia is uncommon. Although *P. carinii* pneumonia has been frequently reported in the literature, a widespread case of this infection was first reported in 1968 by Jarnum *et al.*¹ and in the following year Barnett *et al.*² reported three additional cases. Although not a disseminated form, peribronchial involvement by this infection was first noted in 1960 by Anderson and Barrie.³

We report a case of generalized *P. carinii* infection which became manifest clinically 108 days after a renal homograft and immunosuppressive therapy.

Case history

A 54-year-old printer was first admitted to the University Hospital on December 11, 1967. He gave a history of hematuria, edema and malaise at age 10 years and a recurrence of these symptoms at 31 and 37 years of age. He then continued well until two years ago, when he developed left renal colic and passed a urinary calculus. Immediately thereafter he developed progressive fatigue, lethargy, nocturia and polyuria.

Physical examination showed a well-developed, well-nourished white man with a blood pressure of 160/90

and weighing 164 lbs. Funduscopic examination showed grade I retinal arteriosclerosis. The remainder of the physical examination was unremarkable.

Repeated urinalyses showed pH 5.0, specific gravity 1004 to 1010, protein 30 to 300 mg. per 100 ml., red blood cells 0 to 5 per high-power field and white cells 0 to many per high-power field. Twenty-four-hour urine protein varied from 1.8 to 2.9 g. per day. Mid-stream urine culture showed no growth. Blood urea was 284 to 300 mg. and serum creatinine was 9.3 to 10.0 mg. per 100 ml. Creatinine clearance was 8 ml. per minute. Serum electrolytes were Na 129, K 3.9, Cl 97 and CO₂ 17 mEq. per litre. Serum calcium was 10.2 and phosphorus 5.2 mg. per 100 ml. Blood uric acid was 7.3 mg. Hemoglobin was 10.1 g. per 100 ml., leukocyte count 8200 and platelet count 221,000 per c.mm. Differential white blood count was normal. Chest radiograph was normal.

The patient was treated with forced fluids, a 40-g. protein, *ad lib.* sodium diet, multivitamins, fluoxymesterone (Halotestin) 5 mg. daily and sodium bicarbonate 4 g. daily. On this regimen he improved and felt reasonably well.

Renal radiologic investigations, including renal angiography, strongly suggested the possibility of a malignant tumour in the left kidney. Accordingly, left nephrectomy and splenectomy were carried out on January 26, 1968. The removed kidney was markedly hydronephrotic, containing multiple retention cysts and revealing adenocarcinoma of the cortex. Marked nephrosclerosis was also seen. The postoperative course was complicated by decreased urinary output, pulmonary edema and a re-

duction in creatinine clearance to 2 ml. per mm. Because of these developments, a Scribner arteriovenous shunt was introduced in the left forearm on February 2, 1968, and the patient was started on regular hemodialysis the following day. This was continued once or twice a week until August 25, 1968.

At this time the patient received a cadaveric renal transplant. The donor's left kidney was placed in the patient's right iliac fossa and the patient's remaining right kidney was removed. The latter showed advanced nephrosclerosis with multiple retention cysts. Postoperatively a heavy urine flow was evident within minutes. A ureterocutaneous fistula developed on the fourth transplant day and persisted until death.

During the first post-transplant week the serum creatinine fell from 14 to 4 mg. per 100 ml. and subsequently ranged from 1.0 to 2.0 mg. per 100 ml., increasing only terminally to 4.5 mg.

The leukocyte count varied from 12,000 to 30,000 during the first four weeks post transplant and subsequently from 8000 to 14,000 per c.mm. until the fifteenth week. It then decreased to 4600 per c.mm. and during the final week it fell to the range 1300 to 2700 per c.mm. The platelet count consistently varied from 200,000 to 300,000 until the fifteenth week, when it decreased to 150,000, while during the final week it decreased to 90,000 per c.mm. The highest daily diastolic pressure was consistently under 100 mm. Hg throughout the entire post-transplant course. The body temperature remained under 100° F. until the seventh transplant day, when it increased to 102° F.; on the ninety-third day it increased to 102° F. and

From the Departments of Pathology and Internal Medicine, University Hospital, Saskatoon, Saskatchewan.
CHARLES F. AWEN, M.D., C.R.C.P.[C], F.A.C.P., Department of Pathology, University Hospital, Saskatoon.
M. A. BALTZAN, M.D., F.R.C.P.[C], Department of Internal Medicine, University Hospital, Saskatoon.
Reprint requests to: Dr. Charles F. Awen, Department of Pathology, University Hospital, Saskatoon, Saskatchewan.

remained in the range 102° to 104° F. until the patient died.

His weight at the time of the transplant was 160 lbs.

The patient received ampicillin for the first eight days after the implant. Subsequently, from days 8 to 17, he received chloramphenicol (Chloromycetin) and from days 11 to 26 he was given Coly-Mycin, 150 mg. daily. Ampicillin was restarted on the forty-first post-transplant day and continued until the fifty-seventh day; it was given again from the eighty-fourth until the ninety-fifth days. Further courses of Coly-Mycin were given from the fifty-fifth to the fifty-seventh days, from the eighty-fourth to the eighty-ninth days, and from the one hundred and fourth day until death.

Hydrocortisone in the prednisone-equivalent dosage of 400 mg. was given on the first post-transplant day. This was progressively reduced to 80 mg. per day by the end of the first week and to 60 mg. by the end of the second week. At the end of the fourth post-transplant week the dose was further reduced to 40 mg. daily and thereafter by 10-mg. decrements until the end of the sixth week it was 20 mg. daily. At the end of the seventh week it was reduced to 15 mg. daily, and this dosage was continued until the eighty-sixth transplant day, when it was increased to 40 mg. This was subsequently reduced to 20 mg. daily on the one hundredth day and continued in this range until death.

The patient also received 150 mg. of azathioprine daily throughout his post-transplant course. During the first 10 days following the transplant he was given radiation, 600 R., to the transplant site.

Two days before death the patient developed high fever with diffuse pulmonary infiltrate, as shown by the chest radiograph. There was marked arterial hypoxemia which was almost completely reversible with administration of oxygen, suggesting a diffusion defect. The posterior iliac crest bone-marrow aspirate revealed the *P. carinii* organism. The next day, before one could initiate any treatment for this infection, the patient became hypotensive and oliguric. He died on December 12, 1968.

Autopsy findings

Macroscopic findings

At autopsy, the body was that of a 54-year-old man measuring 130 cm. in length and weighing 145 lbs. The skin was pale. The right lateral half of the hard palate was ulcerated and covered with dirty greyish-brown exudate. The thymus was atrophic.

The heart weighed 400 g. and no gross abnormality was seen apart from left ventricular hypertrophy.

The left lung weighed 1050 g. and the right 1250 g. The appearance of the lungs was identical. The visceral pleurae were diffusely dotted with myriads of pale, yellowish-grey, miliary lesions which sometimes became confluent, giving rise to raised and firm larger nodules. The cut surface of the lung was very edematous, firm and pale grey, showing numerous yellowish-grey lesions as seen on the pleural surface measuring up to 2.0 mm. in diameter. There were many such lesions focally confluent (Fig. 1). There was bilateral hydrothorax amounting to 120 ml. on the left and 50 ml. on the right. There was also ascites amounting to 200 ml. The gastrointestinal tract was unremarkable except for chronic diverticulitis of the ascending colon with localized peritonitis. The liver weighed 1400 g. No grossly recognizable lesions were seen in the liver or pancreas. The transplanted cadaveric kidney weighed 200 g. The cortical surface was smooth, pale and shiny with areas of reddish mottling. On section the cortex was edematous and pale and the medulla was markedly congested. On close observation a few yellowish-grey miliary lesions were seen. The transplanted ureter was distorted by ureterocutaneous fistula formation. The marrow tissue of the vertebrae, ribs and sternum was pale.

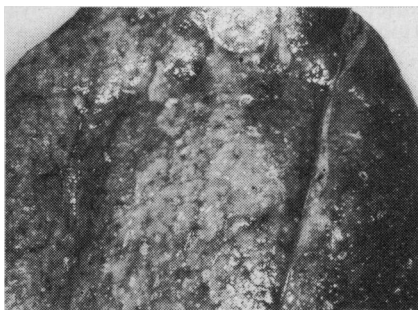

FIG. 1—The cut surface of lung showing myriads of tiny whitish infiltrating nodules.

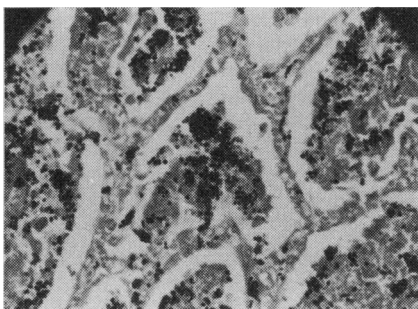


FIG. 2—Lung tissue shows intra-alveolar foamy exudate containing numerous *P. carinii* organisms and a clear, empty space between the exudate and alveolar linings. (Gomori's methanamine silver stain, $\times 100$.)

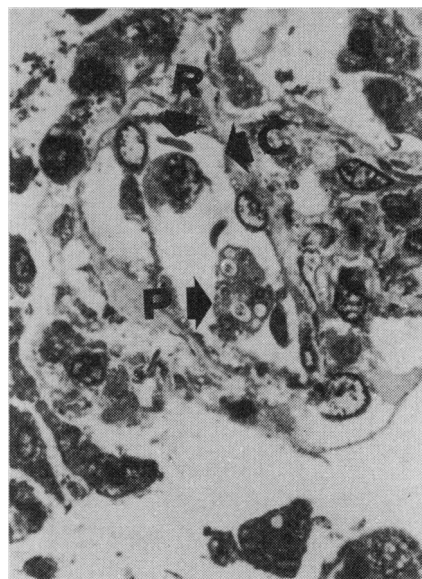

FIG. 3—Intravascular invasion by the organism in a pulmonary capillary: (C) capillary lumen; (R) red blood cell; (P) *P. carinii* organism. (One-micron section. Richardson's stain, $\times 400$.)

Microscopy

Both lungs were the site of full-blown *P. carinii* pneumonia (Fig. 2). Characteristic intra-alveolar foamy exudate containing *P. carinii* organisms was apparent. Sometimes the alveolar involvement was patchy and at other times it was confluent with foci of coagulation necrosis. Destruction of alveolar septa and invasion of blood-vessel walls by the microorganisms were a frequent feature, and the presence of microorganisms in these structures was demonstrated by special stains, PAS and Gomori's methenamine silver. This observation was further confirmed by the demonstration of the intravascular organism in a one-micron section specimen (Fig. 3). The organisms tended to be arranged in clusters. The endothelium of the blood vessel displayed rather plump nuclei, and intracytoplasmic endothelial invasion by the organ-

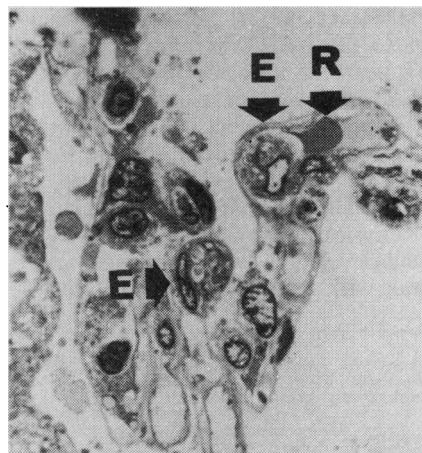


FIG. 4—Invasion by the organisms of the endothelium in pulmonary capillary walls: (E) endothelium; (R) red blood cell. (One-micron section. Richardson's stain, $\times 400$.)

ism was evident (Fig. 4). Neither plasmacytic infiltrate nor granulomatous response was noted in this case. However, alveolar lining cell hyperplasia was a prominent feature (Fig. 5). On PAS stain, the micro-organisms had definite cyst walls and intracyclic PAS-positive bodies. By Gomori's methenamine silver stain, the typical feature of *P. carinii* was demonstrated.

Ultrastructural study revealed a fairly well preserved oval to round cystic form surrounded by cellular debris. The cysts averaged 3.4μ . in diameter. The cyst wall of the organism was composed of outer and inner electron-dense layers with an electron-lucent middle layer interposed. Within the cyst there were three or four round to ovoid intracyclic daughter cysts in the plane of cut shown in the photograph. Some daughter cysts were electron-dense and others were electron-lucent with distinct double-layered membranes (Fig. 6). Organ-

elles were difficult to outline in this autopsy specimen.

Extrapulmonary involvement by these organisms included hilar lymph nodes (Fig. 7), pericardium, thymic capsule, ascending colon, liver (Fig. 8), pancreas, homograft kidney, periureteral retroperitoneal tissue, hard palate of the mouth and hemopoietic bone marrow of vertebrae (Fig. 9), ribs and sternum. Intrahistiocytic invasion by the organism was demonstrated in the sternal marrow (Fig. 10).

Main accompanying features were marked pulmonary edema and marked secondary hyperplasia of parathyroid glands associated with osteoporosis of bone and metastatic calcification of visceral organs.

Culture and animal study

In view of more than one opportunistic infection frequently associated with such a case, bacterial, fungal and viral cultures were attempted.

P. aeruginosa was cultured from the lung, heart blood and cerebrospinal fluid. Mycobacterial culture of specimens of lung, cerebrospinal fluid and kidney was negative. Viral cultures made from the brain, heart, lung, intestine, adrenal, kidney and liver, and from tracheal washings, using human embryonic lung tissue, monkey kidney tissue and suckling mice, were negative. Fungal culture from lung tissue was overgrown by bacteria.

Lung tissue suspension was injected intraperitoneally into three mice with the hope of transmission of the organism. One week later, autopsies were performed and the organs were grossly examined. No gross lesions could be seen and therefore no culture was attempted. However, the tissue sections from one of the mice were stained with hematoxylin and eosin and Gomori's methenamine silver stain and examined. No *P. carinii* organism was demonstrated in the tissue sections.

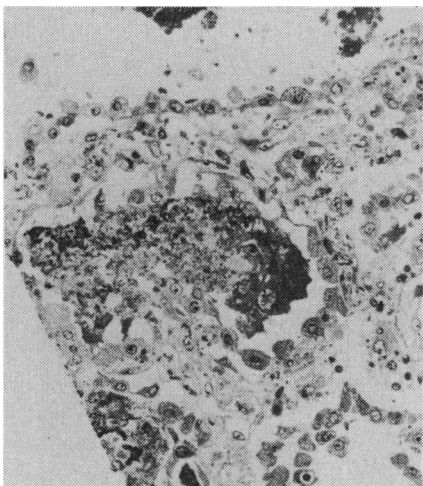


FIG. 5—Hyperplasia of alveolar lining epithelium. (One-micron section. Richardson's stain, $\times 400$.)

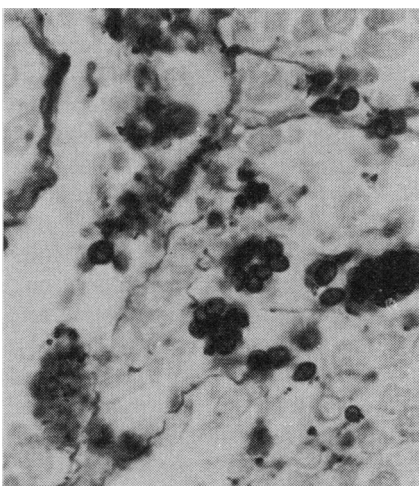


FIG. 7—Hilar lymph node. The sinusoids are invaded by organisms. (Gomori's methanamine silver stain, $\times 400$.)

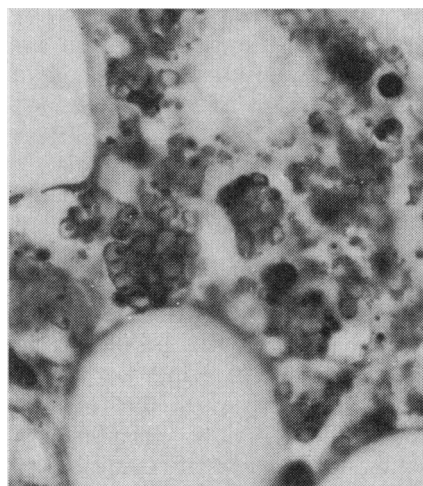


FIG. 9—Vertebral marrow showing intracyclic bodies of the organisms. (Periodic acid-Schiff stain, $\times 400$.)

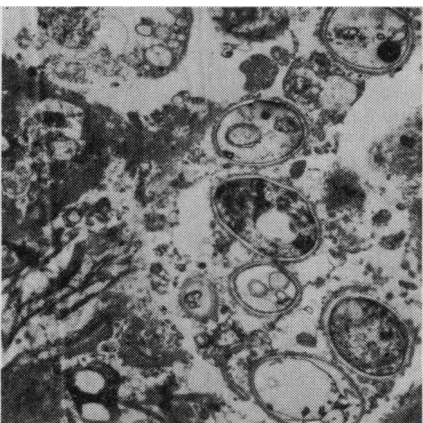


FIG. 6—*P. carinii* organism seen under electron microscope. The organisms are cystic and reveal the outer and inner electron-dense layers with an electron-lucent middle layer. A few daughter cysts are apparent within each main cyst. (Electron microscopy, $\times 3300$.)

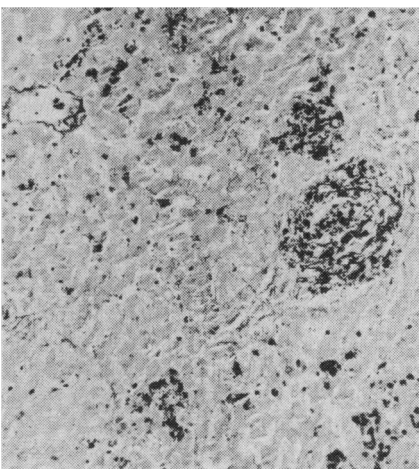


FIG. 8—Liver section showing permeation of the organisms through the portal tracts and intralobular sinusoids. (Gomori's methanamine silver stain, $\times 400$.)

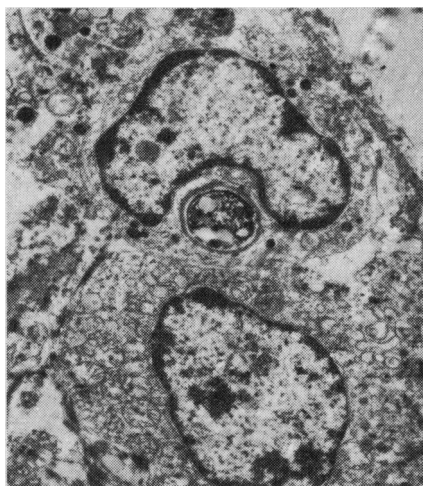

FIG. 10—Sternal marrow displays a marrow histiocyte with ingested organism. (Electron microscopy, $\times 3300$.)

Discussion

Hitherto the *P. carinii* organism has been considered as a protozoan in nature by the majority, although Minielly, Mills and Holley⁴ believe that it may be related to mycological organisms because *P. carinii* has a definite affinity for silver stains, as do most fungi. The organism, while the immune mechanism is undisturbed, rarely flourishes in the human body to cause pneumonia or systemic infection. Whether primary or secondary, this infection is almost always associated with a lowered immunity or general health status.

Frenkel, Good and Shultz⁵ indicate the decisive importance of corticosteroids in the pathogenesis of *P. carinii* infection in rats and man, and this view is clinically well verified in 10 cases of *P. carinii* pneumonia observed in 111 renal transplantation cases reported by Rifkind, Faris and Hill.⁶ They report that the patients who received prednisone therapy in a dosage as high as 40 mg. per day for a median duration of 113 days developed *P. carinii* pneumonia.

Azathioprine, 150 mg. daily, was administered to our patient throughout his post-transplant course. This dosage is lower than the average given to other transplant patients in this hospital, who generally receive 3 mg. per kg. of body weight unless the platelet count falls below 100,000 per c.mm. or the leukocyte count below 3500 per c.mm. When these levels are reached, the dose is reduced to 2.5 mg. per kg. daily. For the average transplant patient in this hospital, 500 mg. of hydrocortisone is administered immediately prior to operation. On the first post-transplant day a total of 2000 mg. is given. This is then reduced by 50% daily until the dosage equivalent of 100 mg. of prednisone is reached at the end of the first week. This is decreased to 80 mg. daily, and is then progressively reduced so that by four months the permanent long-term maintenance dosage of 15 mg. per day is reached. In our case the initial dosage of prednisone was lower than that of other transplant patients and the maintenance dose was the average. Though the average daily dosage of prednisone was

not large in this case, the duration of medication closely approached the median duration of the cases with *P. carinii* pneumonia reported by Rifkind and his colleagues.⁶

The case of generalized *P. carinii* infection reported by Jar-num *et al.*¹ showed extrapulmonary involvement, namely of the liver, spleen, lymph nodes and bone marrow. It was believed that the operative procedure (lobectomy) caused dissemination of the disease. The lungs and the liver showed numerous small abscesses. Barnett *et al.*² reported three cases of extrapulmonary infection involving hilar lymph nodes and spleen. In their first case there was granulomatous reaction associated with the infection. A plasmacytic, lymphocytic and eosinophilic cellular infiltrate was also described. Calcification and fibrosis of this lesion were associated findings.

In our case both lungs were diffusely involved in the form of miliary nodules, although focally confluent areas were frequent and even large yellow necrotic lesions were noted bilaterally. Vascular wall involvement and the presence of the organism in capillaries and in the cytoplasm of endothelium were evident in paraffin sections, and this finding was more definite in one-micron sections (Fig. 4). The infection caused by the European strain of this organism, which is allegedly serologically different from that of North American type, usually shows plasmacytic infiltrate. However, our case showed hardly any inflammatory cell infiltrate. Perhaps this is the result of immune suppression and conditioning to corticosteroids or is due to the profound leukopenia which this patient experienced. The lesions found in the liver, pancreas, homograft kidney and hemopoietic bone marrow of the vertebrae, ribs and sternum were widely disseminated in a miliary pattern. In the liver the organisms diffusely permeated the portal veins and sinusoids, whereas the lesion seen in the hard palate was of an ulcerative type. The mode of generalization of *P. carinii* infection was very much reminiscent of generalized miliary tuberculosis. The failure of transmission of the organism to mice in our case is perhaps due

to the fact that the animal was not subjected to prior corticosteroid conditioning and the lung tissue suspension was postmortem material. Frenkel and his colleagues⁵ were also experimentally unable to transmit the infection of rats to mice and hamsters even after corticosteroid conditioning. Successful culture of this organism has never been reported.


We are grateful to Dr. M. Takeda, Jefferson Medical College, Philadelphia, Pa., for the electron microscopic preparation, and to Drs. F. Holden, Bacteriologist, and K. Y. Chung for their microbiological animal study.

References

1. JARNUM S, RASMUSSEN EF, OHLSEN AS, *et al*: *Ann Intern Med* 68: 138, 1968
2. BARNETT RN, HULL JG, VORTEL V, *et al*: *Arch Path (Chicago)* 88: 175, 1969
3. ANDERSON CD, BARRIE HJ: *Amer J Clin Path* 34: 365, 1960
4. MINIELLY JA, MILLS SD, HOLLEY KE: *Canad Med Ass J* 100: 846, 1969
5. FRENKEL JK, GOOD JT, SHULTZ JA: *Lab Invest* 15: 1559, 1966
6. RIFKIND D, FARIS TD, HILL RB: *Ann Intern Med* 65: 943, 1966

When you think digoxin ... write

*
LANOXIN
THE ORIGINAL DIGOXIN

 Trade Mark M2612

Burroughs Wellcome & Co. (Canada) Limited