

CHRONIC LEPTOMENINGITIS AND EPENDYMITIS CAUSED BY
USTILAGO, PROBABLY U. ZEAE (CORN SMUT)

USTILAGOMYCOSIS, THE SECOND REPORTED INSTANCE OF
HUMAN INFECTION *

MORRIS MOORE, PH.D., WILLIAM O. RUSSELL, M.D., and ERNEST SACHS, M.D.
(From the Departments of Dermatology, Pathology and Surgery (Neurosurgery) of the
Washington University School of Medicine and The Barnard Free Skin and
Cancer Hospital, St. Louis, Mo.)

It is well known that certain fungi which are saprophytic in their more common or natural habitat are pathogenic for man, and at times produce significant disease. The following saprophytic fungi are proved pathogens for man: *Coccidioides immitis* (coccidioidomycosis) may be found in the air or in the soil; *Candida* (*Monilia*) *albicans* (moniliasis) may be a saprophyte in nature; species of *Actinomyces* or *Nocardia* (actinomycosis) can be isolated from the soil; *Zymonema* (*Blastomyces*) *dermatitidis* (North American blastomycosis) is in all probability a saprophyte; *Paracoccidioides brasiliensis* and *P. cerebriiformis* (South American blastomycosis or Lutz-Splendore-de Almeida disease) can be found as saprophytes on coffee plants; *Phialophora verrucosa* and other organisms which cause chromomycosis (chromoblastomycosis) can be found growing saprophytically on logs or decaying wood; *Sporotrichum schenckii* (*sporotrichosis*) has been found on barberry bushes and other plants as a saprophyte; *Aspergillus*, *Mucor*, and other fungi which produce human diseases are air-borne; *Rhinosporidium seeberi* (rhinosporidiosis) in all probability is water-borne. There are, no doubt, other pathogenic fungi producing human disease that have saprophytic existences, the sources of which are unknown.

It has been frequently suggested, but seldom proved, that fungi pathogenic to plants might, under favorable conditions, parasitize man. It is a well known fact that certain mycotic phytopathogens can act as antigens to produce sensitization in man. Cadham,¹ in 1924, had three patients who developed asthma from contact with grain rusts. The chief fungus thought to be responsible for the disease was the wheat rust, *Puccinia graminis*. Hopkins, Benham, and Kesten² reported a case of asthma in which the inciting cause was an *Alternaria*. Several species of *Alternaria* produce diseases in plants. Among these may be listed *A. mali* (apple leafspot disease), *A. solani* (early blight of potatoes), and *A. panax* (ginseng blight). Other investigators found, as did Brown,³ that patients were sensitive to numerous fungi that in certain instances were plant pathogens.

* Received for publication, July 23, 1945.

Actual invasion of human tissues by plant pathogenic fungi, however, is rare, in spite of the large number of fungi saprophytic on plants which may affect man. Of particular interest is the case reported by Preininger⁴ of a 31-year-old farmer who spent the night in a corn field in a drizzling rain after working in the field under a scorching sun. An examination of the patient revealed that he had a symmetrical arrangement of skin lesions which corresponded to the areas in contact with the wet clothing. These consisted of infiltrated, hyperemic patches on the chest, back, arms, inguinal region, and legs, with scaly plaques in the axillae, on the neck, elbows, and dorsum of the feet. There were scattered red papules on the chest, legs, and buttocks. The hyperkeratotic epidermis of the palms and soles was raised in the form of large sheets of lamellae and revealed an infiltrated corium. A microscopic examination of scrapings from the lesions disclosed spores which were similar to those seen in the black, smutty areas on corn leaves brought from the field in which the patient had slept. The cutaneous disease was thus identified as being caused by the corn smut, *Ustilago zea* (*U. maydis*).

The above-described case is of interest for two reasons. The first is that it conclusively proves that fungi pathogenic for plants can cause human disease and, secondly, because we have been unable to find in the literature any other case of human infection with *Ustilago*. It is probably the first proved instance of human infection by *U. zea*.

Because of the rarity of human disease caused by *U. zea*, for which the term ustilagomycosis is suggested, it is thought that the following case of chronic leptomeningitis and ependymitis caused by *Ustilago* is worthy of recording. It is, to the best of our knowledge, the second instance of human infection with this organism and the first in which the infection has involved an internal organ, the brain.

REPORT OF CASE

Clinical History. The patient was a white married man, 55 years old, who was admitted to Barnes Hospital on April 29, 1942, and died on May 7, 1942. He complained of a swimming sensation in his head and a staggering gait that had become worse during the 4 months prior to his admission.

The past history revealed that in 1937 he had had an attack of nausea and vomiting for which an operation was performed and a midline epigastric incision was made, but nothing was found. In 1938 he was admitted to a hospital in Louisville, Kentucky, because of staggering, nausea, slight headaches, and attacks of vomiting of 2 years' duration. A cerebellar craniotomy was performed, but no tumor was found and a diagnosis of "chronic cystic arachnoiditis" was made without biopsy. The craniotomy wound did not heal normally and there was continuous drainage from the wound for approximately 4 months. The patient had had defective hearing for a long period. There was no history of meningitis.

Following the cerebellar craniotomy the patient felt well and returned to work as

a farmer which included, among his chores, that of husking corn. He continued to feel well until 4 months before entering Barnes Hospital.

Physical examination revealed a somewhat gruff, almost deaf farmer. At times he seemed unable to understand well, but otherwise he was clear, oriented, cooperative and did not appear to be acutely ill. There was a right lateral nystagmus. Hearing was definitely impaired, more so in the left ear. Since his first illness he had had trouble with his memory and there had been blurring of vision. Adiadokinesis was present in the left arm. The Romberg test revealed a tendency to fall forward and to the left. The ocular fundi were normal. The reflexes were normal except the abdominal reflexes which were absent. The pulse rate on admission was 56 beats per minute, and the blood pressure was 125/70 mm. Hg. Subsequently the pulse rate increased to 72 beats per minute. On the day before death the pulse varied between 100 and 126, and finally rose to 130 shortly before death. The blood pressure was 125/70 mm. of Hg on admission, reached 138/88, and was 86/74 shortly before death. The temperature fluctuated between 37° and 38° C. and terminally rose to 39° C.

The routine laboratory studies were not remarkable.

On May 5, 1942, a ventriculogram was made, air being injected through a previous perforator opening after 110 cc. of clear fluid were removed from the ventricle. Plates showed the air only in one ventricle. Air was then injected into the left ventricle, following the removal of 60 cc. of fluid. The plates revealed a moderate, symmetrical dilatation of the lateral ventricles, of the third and fourth ventricles, and a prominent aqueduct of Sylvius. Because the ventriculographic studies showed only moderate dilatation of the ventricular system and there were no signs of pressure, it was thought that surgical intervention was not indicated. Thirty-six hours after these studies, the patient developed irregular breathing, became cyanotic and unconscious, and died. Terminally, there were clinical signs of bronchopneumonia that did not respond to chemotherapy and oxygen.

The final clinical diagnoses were hydrocephalus, probably of degenerative type, and bronchopneumonia.

NECROPSY

The external examination of the body disclosed the healed surgical wound in the posterior occipital region, but otherwise nothing remarkable was noted.

The weight of the lungs was moderately increased, the combined weight being 1250 gm. There were scattered fibrous adhesions over the surfaces of both lungs. Irregularly outlined foci of gray, brown and red consolidation, varying from a few mm. to 2 cm. in diameter, were found in all lobes of the lungs. The intervening parenchyma was subcrepitant and gray to pinkish red. A small amount of frothy mucus was present in the trachea and bronchi. A calcified nodule, 2 mm. in diameter, was present in the pulp of the spleen. There were small yellow foci in the intima of the pulmonary, cerebral, and coronary arteries. Similar foci were present beneath the endocardium of the anterior leaflet of the mitral valve. In the wall of the aorta and the splenic arteries there were raised yellow plaques. Except for small deposits of fat beneath the endocardium of the left ventricle, there was nothing remarkable in the heart. There were no gross pathologic changes in the liver, spleen, skin, kidney, or gastrointestinal tract.

Examination of the Brain. The occipital bone showed the trephine openings and the occipital craniotomy. The dura mater was unusually tense and the cerebral convolutions were flattened. A pointed glass tube was inserted into the right lateral ventricle and clear fluid was obtained under pressure. There were fibrous adhesions between the cerebellum and the dura mater. There was a herniation of the cerebellar tonsils into the foramen magnum. The leptomeninges over the cerebral hemispheres and over the base of the brain were slightly thickened and light grayish white. No pathologic change was noted in the basilar arteries.

Following fixation in 3 per cent neutral formaldehyde, the brain was sectioned in a coronal plane, the sections being taken at distances of from 1 to 4 cm. apart. There was moderate symmetrical dilation of the lateral, third, and fourth ventricles. The aqueduct of Sylvius was widely patent, measuring 4 mm. in diameter. The foramina of Luschka and Magendie were obliterated by fibrous adhesions in the subarachnoidal space. There was a faintly visible fine granularity of the ventricular ependyma. There was no gross pathologic change in the brain tissue.

Microscopic Examination

Lung. Several sections taken from the foci of consolidation showed essentially the same pathologic change. The alveoli and bronchi contained polymorphonuclear leukocytes, fibrin, macrophages, and scattered red blood cells. The alveoli in the remaining parenchyma were partially filled with a lightly eosinophilic-staining precipitate which appeared finely granular.

Brain. Sections from the cerebral cortex, cerebellum, and pons (stained with hematoxylin and eosin) showed a chronic inflammatory change in the leptomeninges. Moderate numbers of lymphocytes, plasma cells, and macrophages were present, with a moderate increase in connective tissue. Occasionally a grouping of a multinucleated giant cell and macrophages suggested a tubercle. In the perivascular spaces of Virchow-Robin, adjacent to the pia-gliar membrane, there were lymphocytes and plasma cells, in certain instances filling the space.

The section through the medulla including the fourth ventricle disclosed a broad zone of chronic granulation tissue replacing the normal ependymal surface (Fig. 1). In the granulation tissue were large numbers of lymphocytes, plasma cells, large mononuclear macrophages, epithelioid cells, and multinucleated giant cells of the Langhans' type. There were scattered eosinophils and polymorphonuclear leukocytes. The giant cells demonstrated a remarkable variation in size and shape. The peripherally arranged nuclei were usually vesicular and the cytoplasm in most instances was homogeneous, but occasionally contained

fine vacuoles. The chronic inflammatory tissue lining the ventricle contained branching, yeast-like forms of a fungus within many of the giant cells, occasionally in macrophages, and scattered among the inflammatory cells in the granulation tissue. In the sections stained with hematoxylin and eosin the fungi were seen in faint outline, giving the cell a vacuolated appearance, suggestive of phagocytized fat (Fig. 5). In sections stained by the Gram-Weigert method, the fungi were intensely colored and were seen clearly as hyphae or chains of budding or sprouting mycelium. Some of the fungi showed branching (Figs. 2, 3, 13, and 14) and others presented a whorling configuration (Fig. 4). Clear zones surrounded the fungus within the giant cells in practically all instances. These zones were interpreted as the result of a lytic action on the part of the growing fungus.

A post-mortem culture of blood from the heart on blood agar revealed only diphtheroids, regarded as contaminants.

Anatomic Diagnoses

Chronic mycotic leptomeningitis and ependymitis; moderate internal hydrocephalus; healed wound of an occipital craniotomy; cerebellar pressure cone; bronchopneumonia of all lobes of the lungs; lipoidosis of the pulmonary, cerebral, and coronary arteries; arteriosclerosis of the aortic and splenic arteries; and fatty infiltration of the myocardium.

MYCOLOGY

The classification of a pathogenic fungus is usually determined by studying the evolution of the organism in artificial mediums and by identifying the various morphologic and physiologic entities which comprise the genus and species. For one trained in mycology, it is usually not difficult to identify, at least generically, most fungi in tissue. An exact identification of the fungus causing the intracranial disease in this case was difficult chiefly because the organism could not be studied on artificial mediums. A chronic infection, especially one due to a fungus, was not suspected at the time of necropsy to account for the slight opacity and thickening of the leptomeninges. Consequently, the entire brain was fixed in formaldehyde, making cultures impossible. Moreover, the appearance of the cells in the tissue, when first examined, gave no clue to their identity. The examination of serial sections of the block of tissue taken from the fourth ventricle, where the organisms were found, revealed that these mycotic structures were apparently morphologic forms known as sprout mycelium. Sprout mycelium is a form of vegetative mycelial growth which develops under certain conditions of nutrition and environment.

A review of the known human mycoses failed to reveal sprout my-

celium in parasitized human tissue of the type observed in this case. The fungi of such granulomatous diseases as blastomycosis, paracoccidioidal granuloma, and histoplasmosis are seen in tissue chiefly as budding cells, either simple or multiple. The organisms causing chromomycosis are seen as simple or multiple cells with septum or cross-wall formation, but no buds, while the characteristic structure of the organism of sporotrichosis is a cigar- or oval-shaped cell. The fungus of coccidioidomycosis or the progressive form of the disease, coccidioidal granuloma, is seen as an endosporulating structure. The fungi causing actinomycosis and maduromycosis when observed in tissue are in the form of branching fine filaments, bacillary cells, or granules composed of filaments and spores. *Candida* (*Monilia*) *albicans* and its related organisms, the cause of moniliasis, a disease which may have a systemic distribution but is usually cutaneous, shows budding, yeast-like cells in tissue. Under certain conditions, *C. albicans* may show filaments or pseudomycelium, but never of the type seen in the case described here. The dermatophytes, including such fungi as produce microsporosis, trichophytosis, epidermophytosis, endodermophytosis or tinea imbricata and favus, present filaments, spores, or chains of cells which may be branching, but are not sprout cells of the type found in this case. Furthermore, the dermatophytes cannot be considered as systemic invaders in the sense that they produce internal lesions of a serious nature, particularly of the brain. Likewise, there is a marked difference in appearance of the hyphae and spores of *Aspergillus*, *Mucor*, *Penicillium*, and other genera of the so-called "weeds of mycology" which may produce systemic disease.

A clue to the probable identity of the fungus was found only after studying the organism in all its forms in the serial sections. This clue was a germinating spore which was engulfed by a giant cell (Fig. 6). The outer wall of the spore appeared thick and had surface markings which consisted of small excrescences or spines. The germinating portion of the structure appeared to be protruding through a split wall, was thin-walled, nonstaining or hyaline in character, and blunt at the growing tip. A combination of the sprout mycelium plus the spiny, germinating cell suggested the characteristics of a smut organism. This supposition was further strengthened by the finding of a spore in a clear space within a macrophage which was characteristic of an immature or young smut spore with the thick, dark wall and the single nucleus (Fig. 7). Further search in other slides from the fourth ventricle and also in the choroid plexus of the fourth ventricle was rewarded by the finding of an elongated, irregularly elliptical, spiny or echinulate spore (Fig. 8), a chain of echinulate spores (Fig. 10), and

masses of spiny spores and germinating forms in the choroid plexus (Figs. 11 and 12). For the most part, the spiny spores were globose (spherical) with the exception of a few which were subglobose to ellipsoid or irregular. The mature globose spores that were observed measured approximately 7 to 10 μ in diameter, whereas the elongated spores were approximately 11 μ in the long axis.

The Ustilaginales or smuts include several hundred species which parasitize higher plants.⁵ Of this large number, many can be eliminated in an attempt to classify the fungus in the case presented here on the basis of spore size and spore surface markings or absence of markings. The cereal smuts are the more common forms encountered on farms. The work of Stakman⁶ has been of great help in eliminating certain cereal smuts on the basis of spores and spore germination.

Ustilago hordei, the covered smut of barley, can be eliminated since the mature spores are smooth and do not have spines. *Tilletia foetens*, the stinking smut of wheat, likewise has smooth-walled spores. In *Ustilago tritici*, the loose smut of wheat, the spores are lighter on one side than on the other and the spines are usually seen on the lighter side, sometimes along the edge on optical section and sometimes covering only half the spore. The spore wall is rarely split by the promycelium and usually the promycelium is constricted at the base, precisely where it emerges from the spore. Since the spores observed in our sections showed spines over the entire wall, splitting of the spore wall and no constriction of the germination at the base, it is safe to eliminate this organism. *U. nuda*, the cause of loose smut of barley, has spores which resemble those of *U. tritici*. The spores of this organism appear hollowed out in the center, giving them a concave appearance. This feature was not observed in the spores seen by us. The spores of *U. avenae*, the smut of oats, resemble those of *U. tritici* and *U. nuda*. The spores of *U. zaeae*, also known as *U. maydis*, the cause of corn smut, have characteristics similar to those of the organism noted in the sections from our case.

In plants, *U. zaeae* produces what is known as a smut tumor. The tumor is covered with a thin membrane which encloses the mass of powdery spores in addition to the parenchymal cells and fibrovascular bundles of the host. When the membrane ruptures, the mature spores are set free and scattered by the wind or drop down to contaminate the soil in the vicinity. The mature spores measure approximately 7 to 12 μ in diameter, are usually spherical, but may be ellipsoid or irregular in shape and vary less from the normal than do the spores of *U. tritici* and *U. nuda*. The spores are brown, and are not lighter on one side than on the other, but the individual spores may vary some-

what in density, some being darker around the edges, especially on optical section, appearing dark brown to black. The outer wall or *episore* is covered with prominent spines or warty excrescences which show distinctly on all sides. Under satisfactory conditions of temperature and moisture the spores will germinate, but when unfavorable they will remain dormant, retaining their viability for several years or until such time as growth conditions are again favorable.

The relation of temperature to germination was studied by Jones⁷ who found the optimum temperature for corn smut to be between 26 and 34° C., the maximum between 36 and 38° C., and the minimum 8° C. The optimum is higher than for most smuts and helps make clear two important points. The first is that this tolerance to high temperature explains why corn smut is more severe in the warmer regions where corn is grown, and the second is that that may be the reason why the fungus is able to produce lesions in the human body.

When the mature spore germinates, it forms a special structure known as the *promycelium* which is made up of four somewhat elongated cells. From these promycelial cells there develop, laterally and terminally, secondary structures termed *sporidia* which are fusiform and vary in size. Under continued favorable conditions, the promycelium will branch and produce a large number of sporidia. Some of the sporidia will become elongate to form so-called infection threads, while others will bud as do yeasts to produce secondary sporidia or sprout cells. When the budding cells reach the air or when there is a changed oxygen tension, the sprout cells form branches or chains of cells, many irregular in shape and size. These break off and are scattered by the wind to germinate and produce localized tumors when they reach young corn plants. The time for the development of mature spore sacs, depending upon the environment, varies from approximately 1 to 3 weeks. More information can be had by reading one of the standard texts on plant diseases such as that of Heald.⁸

It is apparent from the foregoing that the various stages of the fungus that we have observed in human tissue strongly suggest *Ustilago*, probably *U. zaeae*, as the causative agent of the infection. In summary, these stages consist of: the sprout mycelium which grows under altered conditions of nutrition and oxygen tension; the young or immature spore which shows the characteristic thick wall and nuclear structure; and finally the mature, germinating spores with the varied shapes and sizes, and spines or warty excrescences. Unfortunately, conclusive proof of the identity of the pathogen, namely, its cultivation on artificial mediums, was not possible since the brain was fixed in formaldehyde before it was known that the disease was caused by a

microorganism. However, in spite of the lack of cultural studies we feel justified in considering this case as an example of systemic disease caused by a smut organism that was in all probability that of corn, *U. zeae*.

DISCUSSION

It is difficult to hazard a reasonable guess as to the portal of entry of the fungus. A review of the case history, however, suggests at least two possibilities. The first possibility is that of contamination through the drainage tract following cerebellar exploration, and the second is by way of the gastrointestinal tract. In favor of the first is that shortly after the operation the patient went to work on the farm, and included among his chores was that of husking corn. Although on first thought this appears as a plausible explanation, it does not explain the genesis of the patient's intracranial disease prior to the operation upon which a diagnosis of chronic cystic arachnoiditis was made. Moreover, the draining wound following craniotomy would suggest that the disease was present before the operation, a reasonable explanation for the failure of the wound to heal normally. In favor of the second possibility is that prior to the cerebellar craniotomy the patient had had an attack of nausea and vomiting of such severity as to lead to a laparotomy. It would seem, therefore, that conclusive evidence is lacking to substantiate either of these possibilities, but that the gastrointestinal tract appears to be the more likely portal.

It has been known for a long time that corn smut contains an active principle, probably an alkaloid, which exerts an action similar to that of ergot. The alkaloid, when ingested by cattle, affects the nervous system to produce what is known as "staggers" (grass staggers or stomach staggers).⁹ Highly nitrogenous feeds have also been blamed for causing this disease. In this respect it is worth while to mention that analyses of corn smut have shown that it has a high carbohydrate content and more protein than is found in corn, oats, or clover hay. The symptoms of staggers vary, but generally they indicate involvement of the nervous system. The first symptoms are somnolence and hypoactivity with subsequent general signs of frenzy. The animal is constipated and the output of urine is small. The urine is darker than usual. There may be trembling and spasms of muscles in different parts of the body. In the dull stage, respirations are depressed and each expiration may be accompanied by a sound like snoring. The pulse rate is low, but the volume is good. When aroused suddenly from the drowsy state, the animal appears startled and stares wildly. When moving about it may stagger, with the hind quarters swaying from side to side.

In the advanced stage, when delirium sets in, a cow is said to be mad, having such symptoms as bellowing, stamping of feet, running about wildly, grating of teeth, and frothing at the mouth. There is muscle twitching and jerking and the body may become covered with perspiration. These symptoms are frequently accompanied by convulsions followed by a prolonged period of coma. When consciousness is regained, the animal may get up on its feet, quietly eat some food, or blindly stagger about. Not all of these symptoms, however, are always present in the same animal. When the symptoms of drowsiness are present it is called "sleepy staggers," and when the symptoms are those of frenzy it is called "mad staggers." Frequently the animal will be paralyzed and remain so until death. Post-mortem examination reveals congestion of the brain, meninges, and lungs.

Ergotism is a rare disease in man and is uncommon in America. Ergot-like symptoms caused by *U. zae* (*U. maydis*) and termed ustilaginism by Mayerhofer¹⁰ likewise are rare. Von Storch,¹¹ in 1938, listed the symptoms and signs of the *gangrenous* and *convulsive* or *neurogenic* types of ergotism in man following the use of ergotamine tartrate in the treatment of migraine headache. As described, the two types when combined bear a striking similarity in many respects to the combined symptoms of ustilaginism described by Mayerhofer¹² in children.

According to von Storch,¹¹ the symptoms and signs of 42 cases of ergotism showed with the gangrenous type lassitude, dullness, vague lumbar pains, cramps in the calves of the legs, and dull burning pain in the extremities followed by waves of heat or cold leading to numbness. There were also noted vomiting, and swelling of the feet with the skin of the extremities becoming cold and reddish violet, and developing vesicles which preceded the blackening of the gangrene which was usually dry. Jaundice was commonly observed. The convulsive or neurogenic type was characterized by fatigue, heaviness of head and limbs, giddiness, insomnia, excitement leading to delirium and mania, with impaired sight or hearing and fornication. There were painful spasms of the face, throat, and diaphragm; tonus, clonus, myoclonus, contractures, myopia, myosis, vomiting, diarrhea and amenorrhea. Pseudotabetic, hemiplegic, or paraplegic symptoms have been described.

The symptoms observed in a number of cases of ustilaginism by Mayerhofer^{10, 12} are remarkably similar to the symptoms of ergotism described by von Storch.¹¹ Mayerhofer described intense itching of the body and the extremities; itching, redness, and swelling of the nasal and buccal mucous membranes; marked scaling of thick, dry

crusts on the soles and palms; either intense sweating or none, with usually an elevated temperature in the beginning; muscle weakness and rheumatic types of pains; redness, swelling, and heat in the distal part of the extremities followed by pigmentation of the affected parts; gastrointestinal disturbances following the ingestion of corn flour containing corn smut or ergot; diminishing desire to eat and strong feeling of thirst; gastro-enteritis and colic; gangrene of the extremities, usually dry; latent or manifest tendency toward spasms, eclampsia-like symptoms, cramps, contractures, catatonia, delirium, mania; increased blood pressure with tachycardia preceded in the beginning by bradycardia; exacerbation of symptoms by sunlight; rapid cure if diagnosed early; severe disease in the late stages, with possible death.

It is easily seen from the foregoing that ergotism and ustilaginism in man and animals have enough symptoms and signs in common so that they may be regarded as similar toxic phenomena. In addition to the clinical aspects, post-mortem findings in cases of ergotism in man usually reveal hyperemia, edema, and hemorrhage in the gastrointestinal tract, lungs, and brain. These observations, although not diagnostic of the disease, are generally those seen in animals dying from eating corn smut.

It is interesting to note that there were observed in the patient studied here symptoms similar in many respects to those described for "staggers" in animals. The patient's chief complaint was staggering; he had had gastrointestinal disturbances of a proportion to necessitate an abdominal operation. Other complaints suggesting ergotism included nausea, vomiting, and some neurologic signs. The general clinical picture, however, was not that observed in the most advanced cases of ergotism or ustilaginism. Gangrene of the extremities, marked scaling of the skin, redness and swelling of the mucous membranes, and the more advanced neurologic signs were not observed in this patient. It should be noted, however, that the severest symptoms and the most advanced lesions were not observed in all cases of ergotism and ustilaginism.

The pathologic changes produced by the ingestion of the toxic principle of *Ustilago* in animals are most marked in the brain (leptomeningitis) with an accompanying edema and congestion of the lungs. In rats, Tichomirov and Bogdanovic¹³ observed fatty degeneration of the myocardium with some fragmentation of the fibers, degenerative changes in the kidneys with foci of calcification, and thickening of the intimal layer of blood vessels with hyalinization of the cells. In human ergotism the changes noted are hyperemia, edema and hemorrhage in the brain, lungs, and gastrointestinal tract.

The pathologic changes observed in the case reported here are compatible with the aforementioned changes observed in spontaneous and experimental *Ustilago* poisoning in animals. However, it should be emphasized that the observed pathologic changes described for *Ustilago* intoxication are not in any way to be regarded as in themselves sufficiently characteristic to be diagnostic of this particular intoxication. In the patient studied here there were observed pathologic changes in the leptomeninges and the ependyma which were the site of an inflammatory disease produced by the microorganism. At best, congestion and edema of the brain are difficult to evaluate properly when the examiner is looking for them. These changes were not looked for specifically at the necropsy.

It is interesting to note that there was a deposition of lipid material in the intima of several arteries and beneath the endocardium of the left ventricle. Comparable changes have been described by Tichomirov and Bogdanovic¹³ for their rats with experimentally induced ustilagism. However, it is impossible to attach great significance to these pathologic changes since they are so frequently seen in routine autopsies.

SUMMARY

A case of chronic leptomeningitis and ependymitis caused by a species of the genus *Ustilago*, *U. zaeae*, the corn smut fungus, is described. No other focus of infection was found in the body and it was not possible to determine with certainty the portal of entry and how the leptomeninges and ependyma became infected. The microorganism was identified by the finding of characteristic germinating spores in the fourth ventricle. Histologically, the fungus produced a granulomatous reaction in the leptomeninges and the ependyma with giant cells of the Langhans' type within which the fungus frequently produced sprout mycelium. Clinically, the patient manifested some of the signs and symptoms that have been described in man and animals affected with ergotism and ustilagism.

This case is believed to be the first instance of systemic infection produced by *Ustilago* to be reported, and the second proved case of human infection with an organism of this genus. The term, ustilagomycosis, is suggested for the granulomatous tissue change produced by fungi of the genus *Ustilago*.

REFERENCES

1. Cadham, F. T. Asthma due to grain rusts. *J. A. M. A.*, 1924, 83, 27.
2. Hopkins, J. G., Benham, R. W., and Kesten, B. M. Asthma due to a fungus—*Alternaria*. *J. A. M. A.*, 1930, 94, 6-10.
3. Brown, G. T. Sensitization to fungi. *Ann. Int. Med.*, 1932-33, 6, 655-671.

4. Preininger, T. Durch Maisbrand (*Ustilago maydis*) bedingte Dermatomykose. *Arch. f. Dermat. u. Syph.*, 1937-38, 176, 109-113.
5. Gäumann, E. A., and Dodge, C. W. Comparative Morphology of Fungi. McGraw-Hill Book Co., Inc., New York & London, 1928, pp. 596-613.
6. Stakman, E. C. Spore germinations of cereal smuts. *Minn. Agr. Exper. Sta. Tech. Bull.*, 1913, no. 133, 9-77.
7. Jones, E. S. Influence of temperature on the spore germination of *Ustilago zeae*. *J. Agr. Res.*, 1923, 24, 593-597.
8. Heald, F. D. Manual of Plant Diseases. McGraw-Hill Book Co., Inc., New York, 1926.
9. Harbaugh, W. H., and Mohler, J. R. Diseases of the Nervous System. Special Report on Diseases of Cattle. U. S. Department of Agriculture, Bureau of Animal Industry, Government Printing Office, Washington, D.C., 1916, pp. 101-104.
10. Mayerhofer, E. Ustilaginismus, eine bisher unbekannte Form alimentärer Maisschädigung im Kindesalter. *Wien. klin. Wchnschr.*, 1930, 43, 1077-1079.
11. von Storch, T. J. C. Complications following the use of ergotamine tartrate. Their relation to the treatment of migraine headache. *J. A. M. A.*, 1938, 111, 293-300.
12. Mayerhofer, E. Über Fälle von kindlicher "Akrodynie" (Akropathie) und ihre ätiologische Beziehung zu *Ustilago maidis* sowie über ihre Stellung zur Feerschen Neurose. *Ztschr. f. Kinderh.*, 1930, 49, 579-588.
13. Tichomirov, D. M., and Bogdanovic, S. B. Einige pathologisch-anatomische und pathologisch-histologische Veränderungen bei Ratten, die mit *Ustilago maydis* vergiftet wurden. *Frankfurt. Ztschr. f. Path.*, 1941, 55, 7-13.

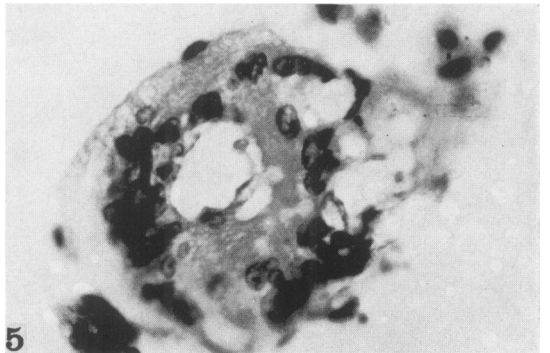
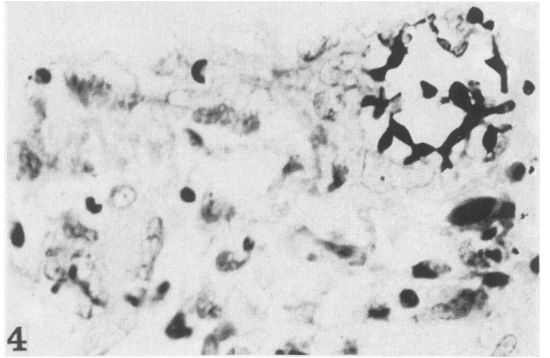
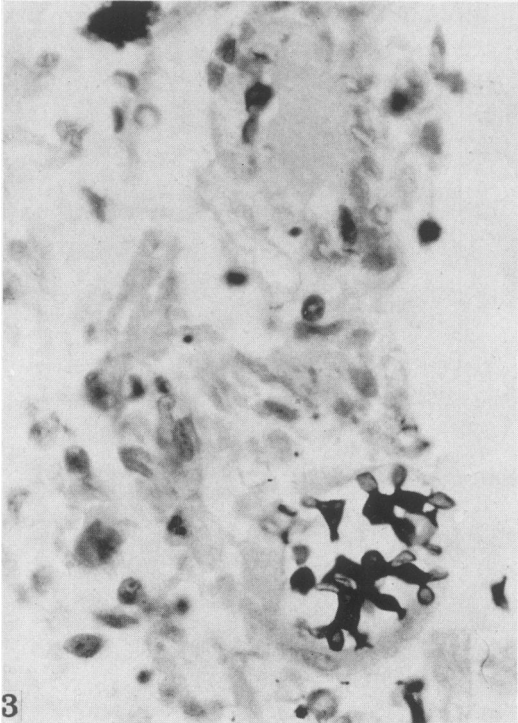
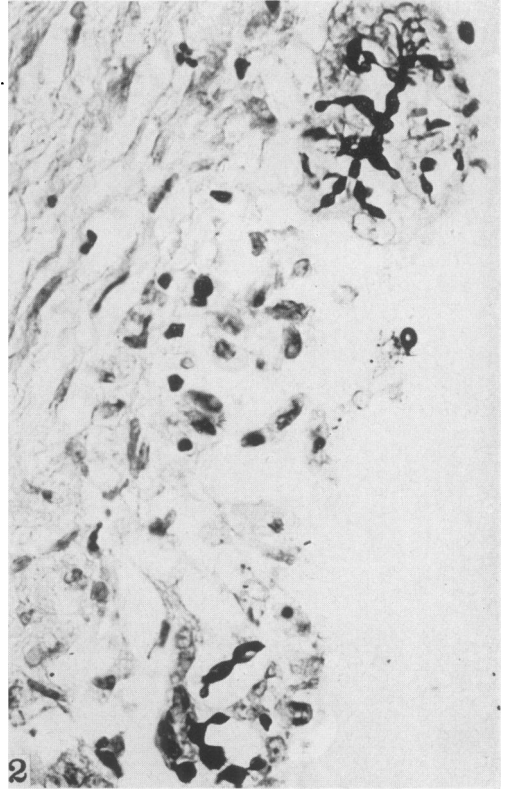
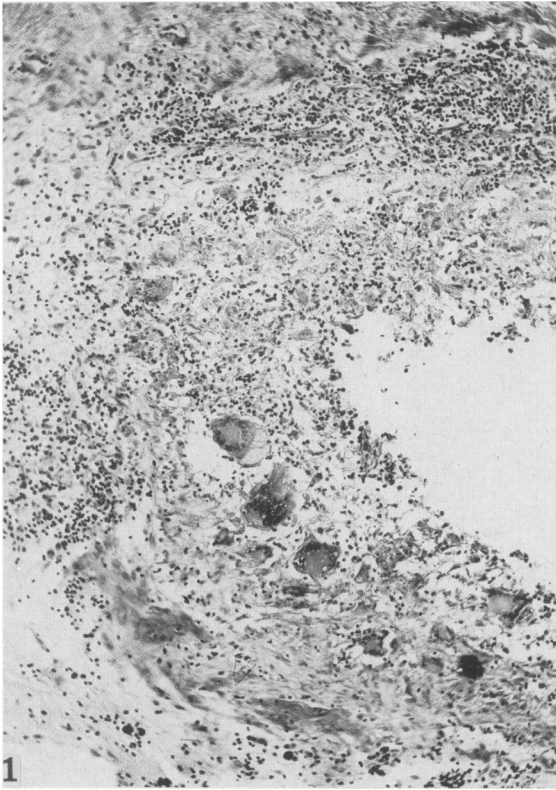
[Illustrations follow]

DESCRIPTION OF PLATES

PLATE 148

All photomicrographs were made from sections of the posterior portion of the fourth ventricle.

- FIG. 1. Granulomatous reaction in tissue, showing giant cells and cellular infiltrate. Gram-Weigert stain. $\times 95$.
- FIG. 2. Giant cells in meningeal tissue showing sprout mycelium. Gram-Weigert stain. $\times 480$.
- FIG. 3. Giant cells engulfing organisms. Gram-Weigert stain. $\times 650$.
- FIG. 4. Giant cells engulfing organisms. Gram-Weigert stain. $\times 495$.
- FIG. 5. Giant cell showing clear zones within which are faintly stained fungus cells. Hematoxylin and eosin stain. $\times 530$.



Moore, Russell, and Sachs

Ustilagomycosis

PLATE 149

All photomicrographs were made from sections of the posterior portion of the fourth ventricle.

FIG. 6. Germinating, mature spore of *Ustilago* in giant cell. Of note are the thick, spiny episore and faint, blunt beginning of the promycelium. Gram-Weigert stain. $\times 1510$.

FIG. 7. Young, immature spore in macrophage. Of note are the thick wall and clear zone around the fungus cell. Gram-Weigert stain. $\times 1510$.

FIG. 8. Elongated, spiny or echinulate spore. Gram-Weigert stain. $\times 1510$.

FIG. 9. Germinating cell showing development of promycelium. Gram-Weigert stain. $\times 1510$.

FIG. 10. Chain of echinulate spores. Gram-Weigert stain. $\times 1510$.

FIGS. 11 and 12. Groups of mature germinating cells in the choroid plexus. Gram-Weigert stain. $\times 1510$.

FIG. 13. Sprout mycelium. Gram-Weigert stain. $\times 1290$.

FIG. 14. Sprout mycelium, showing budding. Gram-Weigert stain. $\times 1290$.

