

# THE AMERICAN JOURNAL OF PATHOLOGY

---

---

VOLUME XXXIV

NOVEMBER-DECEMBER, 1958

NUMBER 6

---

---

## EFFECTS OF ANTIHYPERTENSIVE TREATMENT ON THE EVOLUTION OF THE RENAL LESIONS IN MALIGNANT NEPHROSCLEROSIS\*

LAWRENCE J. McCORMACK, M.D.; JEAN E. BÉLAND, M.D.;  
ROLAND E. SCHNECKLOTH, M.D., and ARTHUR C. CORCORAN, M.D.

*From the Division of Pathology and the Division of Research,  
The Cleveland Clinic Foundation and The Frank E. Bunts  
Educational Institute, Cleveland, Ohio.*

Malignant nephrosclerosis is a well-characterized renal vascular lesion, first described by Fahr<sup>1</sup> in 1919. It is nearly always associated with severe, persistent elevation of average levels of resting diastolic arterial pressure and with other symptoms and signs of the syndrome of malignant hypertension. It usually appears in patients less than 50 years of age, in whom it is often a complication of pre-existing, less severe hypertensive disease.<sup>2</sup> If treatment does not restore arterial pressure to normal levels, the course of the disease is usually marked by rapidly progressing renal failure, terminating in death of some 80 per cent of patients within one year of the onset, and of virtually all by the end of 5 years. It has now been abundantly demonstrated that remissions of this syndrome can be brought about by a variety of measures—lumbodorsal sympathectomy, treatment with bacterial pyrogens or tissue extracts and, during the past 6 years, the administration of one of a variety of potent antihypertensive drugs that have in common the capacity to lower diastolic arterial pressure. In one group of patients treated with these drugs a retrospective study<sup>3</sup> at 4 years showed that the incidence of survival had been increased from 3 to about 30 per cent. With present techniques it is anticipated that this survival can be doubled.

At necropsy, patients who had been under intensive antipressor therapy showed hitherto undescribed changes in the evolution of the renal lesions of malignant nephrosclerosis. The purpose of this report is to describe these changes and to contrast them with lesions of necropsied patients who had had little or no effective antihypertensive treatment.

\*Presented at the Fifty-fourth Annual Meeting of the American Association of Pathologists and Bacteriologists, Washington, D.C., April 13, 1957.

Received for publication, February 7, 1958.

### MATERIAL AND METHODS

One hundred patients with the clinical diagnosis of severe essential or malignant hypertension were studied at necropsy. All demonstrated various stages in the evolution of the renal lesions of malignant nephrosclerosis. Multiple blocks of the kidneys were fixed, usually in a modified Zenker's or a 4 per cent formalin solution, and multiple paraffin sections were prepared. These were stained with hematoxylin-eosin-methylene blue (HEM), Mallory's phosphotungstic acid hematoxylin (PTAH), Mallory-Heidenhain (MH), Masson's trichrome (MT), and Verhoeff's and Gomori's elastic tissue stains. Frozen sections prepared from formalin-fixed blocks of tissue were stained with Sudan IV.

The initial microscopic study of these sections was made without reference to or knowledge of the clinical course, although the sections of treated cases had been recognized as such prior to this critical evaluation. To enhance further the objectivity of the review, sections considered to show the influence of effective antihypertensive therapy were intermingled with those from other patients with arteriolar nephrosclerosis, untreated malignant nephrosclerosis, and with sections from patients who had no renal lesions. Repeated evaluations of the intermingled sections showed that the several groups could be recognized with a high degree of accuracy and, especially, that the sections showing the changes indicative of treated malignant nephrosclerosis were distinguishable.

### CLINICAL OBSERVATIONS

Of the 100 cases, 19 were found to show evidences of "healing" or regression of the acute, destructive lesions of malignant nephrosclerosis. All 19 patients had been under treatment with potent anti-pressor drugs, the majority with ganglionoplegic agents (hexamethonium, pentolinium bitartrate, chlorisondamine, or mecamlamine, alone or in combination with reserpine), while some had been treated with hydralazine, alone or in combination with other drugs.

The lesions in 14 of the 19 treated patients differed greatly from those of untreated patients. The 14 constitute our group I. These patients had been under treatment for periods of 4 to 48 months, and 10 of them for more than 12 months. Their mean age was 44 years; the range from 28 to 66 years. The remaining 5 cases (group II) revealed microscopic evidences of moderate regression of lesions. Correspondingly, the duration of antihypertensive treatment in these was found to be relatively short, ranging from 3 days to 15 weeks. The shortest period of treatment consisted of an infusion of sodium nitroprusside which had maintained an average diastolic pressure of 97 mm.

of Hg for 3 days before death. The age range in group II was 44 to 55 years; the mean, 48 years. The 81 cases in group III showed typical lesions of active malignant nephrosclerosis. The age range here of 27 to 68 years (mean age 44 years) was comparable to that of the other two groups. Group III served as a control, since none of the patients had received effective antihypertensive treatment. Some had been given bacterial pyrogens or had been subjected to lumbodorsal sympathectomy or even total adrenalectomy, but these procedures had not resulted in significant, sustained lowering of diastolic pressure.

In order to detect the association between the efficacy of treatment and the nature of the renal vascular lesions, responses to treatment were graded as "good" (average supine diastolic pressure less than 100 mm. of Hg and evidence of clinical improvement), "fair" (moderate decrease in supine diastolic average pressure but to levels greater than 100 mm. of Hg and some clinical improvement) and "poor" (no decrease in blood pressure or a decrease only in standing diastolic pressure, often in association with remission of the syndrome of malignant hypertension and minor improvement). Of the 19 patients in groups I and II, 17 had maintained diastolic pressure averages of more than 126 mm. of Hg prior to treatment. Good responses occurred in 7 and were maintained for from 5 to 26 months; 11 showed only fair responses for periods of 1 to 24 months; 1 patient had a poor response. At the time of death, while still under treatment, only 4 of the 7 patients responding well initially continued to do so, and at that time 7 of the 19 patients were responding poorly to therapy.

In 14 of the 19 treated patients, papilledema was present when treatment was started. All, however, had evidences of progressive, severe hypertensive vascular disease, compatible with a diagnosis of malignant hypertension. At the time of death, papilledema was present in 6 and absent in 13 patients.

Of the 19, 6 had pretreatment evidences of moderate to severe renal damage, manifested by proteinuria and by urea or creatinine retention. At the time of death, 15 had severe renal failure and most of these demonstrated the uremic syndrome. Pretreatment blood urea levels of these 19 patients averaged 59 mg. per 100 ml., with levels of more than 100 mg. per 100 ml. in 3 patients. Progression of renal damage can be inferred from the fact that at the time of death the mean blood urea nitrogen value for the group was 199 mg. per 100 ml., and the level was greater than 100 mg. in 15. Renal failure was the primary cause of death of 14 patients; one patient each died of cardiac failure, pulmonary fibrosis, meningitis, hypertensive encephalopathy, and dissecting aortic aneurysm.

## MORPHOLOGIC OBSERVATIONS

The kidneys of treated patients (groups I and II) did not differ appreciably in gross appearance from those of patients who had not received treatment or in whom treatment had been ineffective in lowering arterial pressure (group III).

However, as noted above, the histologic sections showed substantial differences between groups I and II on the one hand and group III on the other (Table I). These were most strikingly delineated in sections stained with PTAH. In panoramic scanning under low power, a greater amount of tissue staining brown was present in groups I and II than in group III. The difference was due to an apparent increase in connective tissue in the renal parenchyma in groups I and II. While in some this change was focal only (Fig. 1), in most cases it was diffusely distributed (Fig. 2). Focal fibrosis occurred in association with parenchymal tubular atrophy, whereas diffuse fibrosis was accompanied by a less severe but generalized reduction in the total mass of renal tubules. In addition, large amounts of purple-staining intratubular cast material were only rarely demonstrable in the treated groups. Instead, the tubules appeared dilated and lined by flattened epithelium. This appearance of tubular atrophy was most pronounced in both the proximal and distal convoluted segments. If the term "tranquillity" may be applied to a morphologic pattern, it describes the over-all histologic appearance seen in treated malignant nephrosclerosis when contrasted with the violent aspect of sections from the control group.

The most significant differences were in the renal arteries and arterioles. Thus, renal hilar and interlobar arteries in group III showed few abnormalities (Fig. 3) while, in contrast, corresponding vessels in groups I and II exhibited extensive subintimal fibrosis (Fig. 4) and, occasionally, complete occlusion. The arcuate and interlobular arteries in group III were thickened, with fragmentation, reduplication of the elastica, and some proliferation. The musculature contained many foci of necrosis which took a brilliant red stain with MH and stained positively for fibrin with PTAH (Fig. 5). Some of these vessels showed evidence of recent and, occasionally, old thrombosis, with hemorrhage extending through the vascular wall. Corresponding vessels in groups I and II revealed a considerable reduction in the extent of vascular damage. Indeed, in group I, the only common residua of this damage were the occurrence of thickened vascular walls and, here and there, of luminal obliteration by fibrous tissue, at times resembling healed lesions of polyarteritis nodosa (Fig. 6). Sections stained with PTAH contained rare foci exhibiting intramural deposition of fibrin; the red

masses observed in group III sections stained with MH were rare. Lesions in group II were intermediate in degree between those of groups I and III.

The intralobular arteries and arterioles (less than 100  $\mu$  in diameter)

TABLE I  
*Summary of Renal Arterial and Glomerular Lesions in 100 Patients with Malignant Nephrosclerosis*

Type of lesion	Treated patients (19)		Untreated patients (81)
	Group I No. of cases	Group II No. of cases	Group III No. of cases
<b>Necrotic arterioles per 100 arterioles</b>			
None	3	0	2
1 - 5	11	3	14
6 - 10	—	2	21
11 - 20	—	—	23
21 - 30	—	—	16
31 - 40	—	—	5
	(Maximum-2)	(Maximum-10)	(Maximum-34)
<b>Necrotic glomeruli per 100 glomeruli</b>			
None	9	0	8
1 - 5	5	4	26
6 - 10	—	0	12
11 - 20	—	1	33
21 - 30	—	—	2
	(Maximum-2)	(Maximum-14)	(Maximum-28)
<b>Atheroma of arterioles per 100 arterioles</b>			
None	14	2	55
1	—	2	11
2	—	1	9
3	—	—	6
<b>Arteriosclerosis of large arteries</b>			
Absent	0	1	12
Slight	2	2	57
Moderate	4	1	9
Marked	8	1	3

in group III invariably showed extensive and typical changes of malignant nephrosclerosis. Corresponding vessels in groups I and II differed in several respects, although the so-called "onion peel" or lamellar fibroelastic hyperplastic lesions were present also in group III. One difference was that the hyperplastic vessels seemed less

swollen and edematous in groups I and II. A greater difference, however, was in the frequency of arteriolar necrosis and occlusion. Thrombosis and thrombonecrosis occurred with an average incidence of 12 in 100 counted arterioles in each case in group III, but was detected in fewer than 2 in 100 arterioles and often in none at all in group I. There was an average maximum incidence of 9 lesions in 100 vessels in group II. The smaller arterioles were often visualized with difficulty in groups I and II; occasionally all that could be seen was thickening of their walls.

Small focal accumulations of lipid-laden histiocytes were evident within the interstices of the thickened walls of small arteries and arterioles in 33 of the 81 cases in group III, but were not manifest in any of the vessels in groups I and II. This lesion is believed to represent an initial phase of atheroma formation. The fact that it was not seen in groups I and II is evidence that the process is reversible.

Necrosis of preglomerular arterioles observed in group III was commonly associated with glomerular lesions of focal or total necrosis (Fig. 7). This occurred with an average incidence of 7 per 100 glomeruli in group III; in one case the incidence was 28 in 100. Glomeruli in groups I and II showed a high incidence of scarring (Fig. 8), but the frequency of necrosis was low, varying from 0 to 2 per 100 counted. Over-all glomerular hyalinization was not associated with arteriolar lesions; when it was present, clusters of glomeruli were affected and the lesion was often traced to old thrombosis in an adjacent interlobular artery.

#### DISCUSSION

The data demonstrate that the clinical remission effected in patients with malignant nephrosclerosis by intensive treatment with antihypertensive drugs is associated with a corresponding remission in the histologic lesions of renal vascular disease and with a change in their nature. The most obvious alteration was cessation of activity and regression in both arteriolar necrosis and thrombonecrosis. This was associated with disappearance of most of the foci of fibrin accumulation and of the evidence of acute vascular damage. The change was best demonstrated in the patients in group I, all of whom had shown at least an initially favorable response to treatment. In most of these patients treatment had been continued for longer periods than in the case of patients in group II.

A second major difference in lesions was the appearance of parenchymal and perivascular fibroplasia with focal or diffuse renal parenchymal atrophy in treated patients. These were not manifest in the ineffectually treated controls.

A third, highly significant difference was in the distribution of vascular lesions. In group III the lesions appeared primarily in arterioles and small arteries, leaving large arteries intact; in groups I and II the large arteries showed extensive subintimal fibrosis which, in some instances, progressed to vascular occlusion. Medium-sized arteries, such as the arcuate and interlobular vessels, of the treated groups showed regression of the manifestations of acute vascular injury. Here, again, in some lesions there were evidences of fibrous vascular occlusion which resembled healed periarteritis nodosa. As observed elsewhere,<sup>4</sup> these lesions resembled those encountered in hypertensive vascular disease induced in rats which were subsequently treated with an antipressor agent.

In a previous paper,<sup>3</sup> which included many of the patients listed in groups I and II, it was emphasized that the severely hypertensive patient when treated effectively does not die as the result of the hypertensive disease *per se*, but succumbs to complications of progressive atherosclerosis. Among these were listed cerebral hemorrhage and thrombosis, myocardial infarction, dissecting aneurysm, and slowly progressive renal failure. These complications usually occurred in patients with the more severe forms of hypertension prior to treatment and in those whose responses to treatment were poor. The nature of the renal lesion leading to failure has been described in the present paper. Although the acute lesions of malignant hypertension may be almost completely reversible and proceed to healing, the hypertensive state results in damage to large and medium-sized arteries. This may, in part, contribute to the subsequent appearance of atherosclerosis and fibrous intimal hyperplasia even though arterial pressure is more or less controlled. This lesion, which affects renal vessels diffusely, would account for the progressive renal failure occurring in the majority of the patients in the treated group. Moreover, since in some patients treatment was not wholly suppressive, minimal active lesions of malignant nephrosclerosis persisted and were apparently progressive, although at a much slower rate than in cases not treated with antihypertensive drugs. This, too, might eventuate in renal failure. Lastly, the data compiled support the conclusion derived from experimental studies<sup>4</sup> that the acute destructive vascular lesions of malignant nephrosclerosis are caused by increased arterial pressure.

#### SUMMARY AND CONCLUSIONS

1. Treatment of malignant hypertension with potent antihypertensive drugs greatly alters the evolution of renal vascular lesions in this disease.

2. The lesions were studied in large numbers of sections procured from kidneys of 100 necropsied patients who had had malignant nephrosclerosis. Nineteen of these had been under treatment with antipressor drugs.

3. Treated patients, especially those who had been under therapy for long periods of time, almost always exhibited remission and healing of the acute arteriolar lesions: thrombosis, thrombonecrosis and glomerular necrosis.

4. These patients also showed a noteworthy alteration in the nature of the vascular disease. Large and medium-sized renal arteries revealed subintimal fibroplasia with progression to occlusion in some vessels. It is this lesion which presumably leads to the slowly progressive renal failure which was the cause of death in a majority of the treated patients in the group.

5. The observations substantiate the clinical inference that patients with therapeutically induced remission of malignant hypertension exhibit an increased incidence of arteriosclerosis and its complications. This presumably reflects the damage inflicted upon the arteries during the pretreatment period of uncontrolled hypertension. The lesions observed in treated patients correspond to those encountered in hypertensive rats receiving a potent antipressor agent.

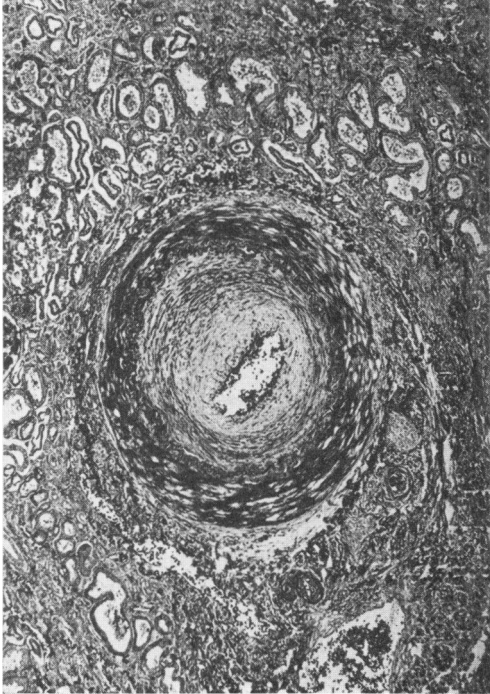
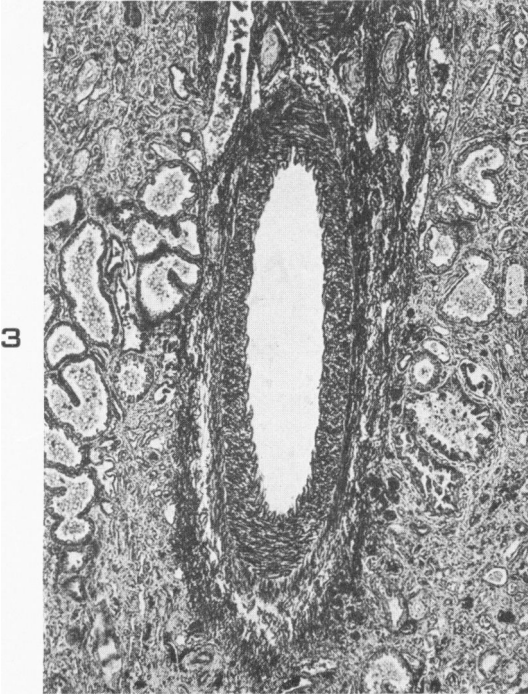
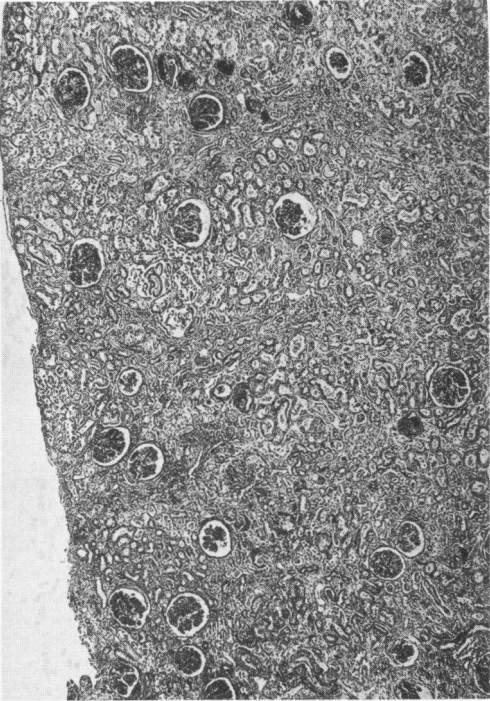
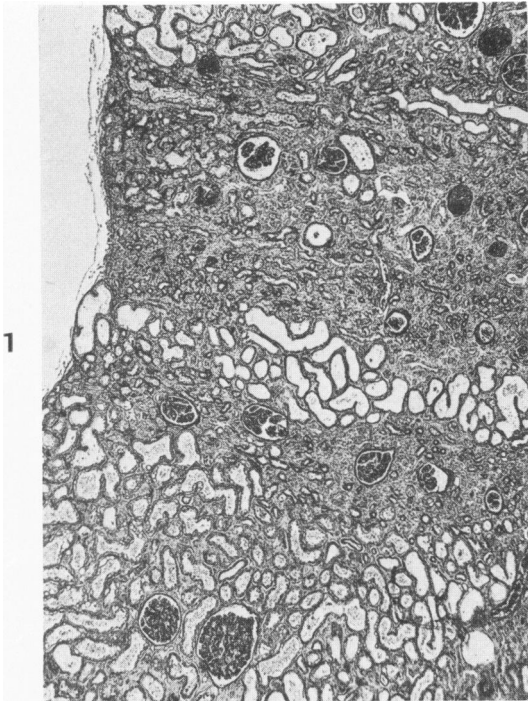
#### REFERENCES

1. Fahr, T. Über Nephrosklerose. *Virchows Arch. path. Anat.*, 1919, 226, 119-178.
2. Keith, N. M.; Wagener, H. P., and Barker, N. W. The problem of prognosis in essential hypertension: a follow-up study in 219 cases. *Tr. A. Am. Physicians*, 1938, 53, 81-87.
3. Corcoran, A. C.; Dustan, H. P., and Page, I. H. Antidiuresis and other renal responses to piperoxan in pheochromocytoma. *Circulation*, 1956, 14, 221-226.
4. Masson, G. M. C.; McCormack, L. J.; Dustan, H. P., and Corcoran, A. C. Hypertensive vascular disease as a consequence of increased arterial pressure. Quantitative study in rats with hydralazine-treated renal hypertension. *Am. J. Path.*, 1958, 34, 817-833.

#### LEGENDS FOR FIGURES

- FIG. 1. Renal cortex showing focal but severe atrophy with interstitial fibrosis. Note tubular dilatation and lack of casts. Phosphotungstic acid hematoxylin (PTAH) stain.  $\times 40$ .
- FIG. 2. Diffuse atrophy of renal cortex with interstitial fibrosis and loss of tubules. PTAH stain.  $\times 40$ .
- FIG. 3. Interlobar artery in patient with untreated malignant nephrosclerosis showing no major histologic lesions. PTAH stain.  $\times 65$ .
- FIG. 4. Interlobar artery in patient with treated malignant nephrosclerosis. Subintimal fibrosis and marked narrowing of the lumen are present. Mallory-Heidenhain stain.  $\times 65$ .





- FIG. 5. Interlobular artery in patient with untreated malignant nephrosclerosis showing mural necrosis and subintimal accumulation of fibrin. PTAH stain.  $\times 170$ .
- FIG. 6. Interlobular artery in treated malignant nephrosclerosis. The arterial wall is partially destroyed with resultant dilatation. The lumen is filled by an organized thrombus. PTAH stain.  $\times 170$ .
- FIG. 7. Afferent arteriolar and lobular glomerular necrosis in untreated malignant nephrosclerosis. Fibrin deposition is prominent. A small juxtaglomerular arteriole is also affected. Note the absence of tubular dilatation and the partial retention of tubular architecture in proximal convoluted segments. PTAH stain.  $\times 170$ .
- FIG. 8. Lobular glomerular sclerosis believed to result from healing of lobular necrosis. Note the tubular dilatation and marked flattening of tubular epithelium. PTAH stain.  $\times 170$ .

