

Hereditary sensorineural hearing loss associated with onychodystrophy and digital malformations

H. Moghadam, M.D., M.P.H., C.R.C.P.[C] and P. Statten, M.D., C.R.C.S.[C],
Toronto

Hereditary hearing loss is frequently associated with other congenital malformations¹⁻³ such as disorders of the integumentary system^{4, 5} or skeletal malformations.^{6, 7} The purpose of this paper is to report a case of hereditary deafness in association with onychodystrophy and digital malformations and to review the relevant literature.

Case report

A 3½-year-old Filipino boy was brought to the Hearing Clinic of The Hospital for Sick Children for assessment. Birth had been normal following an uncomplicated pregnancy and the baby (birth weight 6 lb.) had not been cyanotic or jaundiced. The parents had noticed malformation of his nails at birth but were not alarmed

H. MOGHADAM, Staff Pediatrician, Hospital for Sick Children and Associate Professor, Department of Health Administration, School of Hygiene, University of Toronto.
P. STATEN, Senior Surgeon, Department of Otolaryngology, Hospital for Sick Children and Assistant Professor, Department of Otolaryngology, University of Toronto.
Reprint requests to: Dr. H. Moghadam, School of Hygiene, University of Toronto, Toronto 5, Ontario.

since the mother had similar deformities. At the time of the child's birth his father was 36, and his mother 26 years old. The patient had been brought to Canada by his parents when he was two months old.

The parents had first noticed the child's unresponsiveness to sound when he was about one year old; otherwise his development appeared normal. He was first seen at the outpatient department of The Hospital for Sick Children at 2½ years of age with an upper respiratory tract infection. At that time delayed speech development was noted but deafness was not suspected. At 3 years of age he was admitted to the hospital with aseptic meningitis from which he recovered fully. Virological investigation resulted in isolation of echovirus, type 9, from the cerebrospinal fluid. Deformities of nails were recorded at that time and deafness was suspected, but no further investigations were undertaken until the patient was 3½ years old.

When he was seen at the Hearing Clinic he appeared a healthy and well-developed child who was quite alert but clearly oblivious to all environmental sounds and who communicated by gesture. The only abnormal physical findings were in his hands and feet. He had abnormally long thumbs and absent or dystrophic finger-nails and toe-nails (Figs. 1-3). Each thumb had three phalanges instead of two

and all terminal phalanges of his hand showed bulbous swellings.

There was no consanguinity in the parents. The child's two older siblings and one younger sibling were reported to be normal. The parents could recall no deafness, integumentary or digital malformations in their own siblings, parents or relatives, although the mother demonstrated similar nail abnormalities.

The laboratory investigation included tests on both the child and his mother in some instances. The child's urinalysis was normal, and his hemoglobin was 12.1 g. per 100 ml. Parallel rubella HI antibody titers in both mother and child were less than 1:10. Electrocardiograms and chest roentgenograms of the child and his mother were normal. Roentgenograms of the hands and feet of the mother revealed abnormally formed and pointed end-phalanges. The roentgenograms of the child's hands showed somewhat similar but less pronounced abnormalities of the end-phalanges and a supernumerary phalanx in each thumb. The roentgenograms of his feet disclosed only rudimentary centers of ossification in the end-phalanges, so that no deformities could be seen.

Tomograms of the petrous pyramids of the child revealed normal structures of the middle and inner ears. His intelligence quotient on the Merrill Palmer Scale was 100 and his social quotient on the Vineland Social Maturity Scale was 90. All members of the family were investigated audiologically. The patient's lack of response to any sound stimulus was confirmed both by sound field testing and cortical audiometry. The mother, who had never been aware of any hearing loss, had a bilateral low-tone moderate sensorineural hearing loss averaging 32 db. in the right ear and 37 db. in the left ear. The father and siblings had normal audiograms. Although we would have liked to carry out vestibular and dermatoglyphic studies on the child and his mother, the parents refused further investigation.

Discussion

Hereditary syndromes with auditory and ectodermal manifestations were

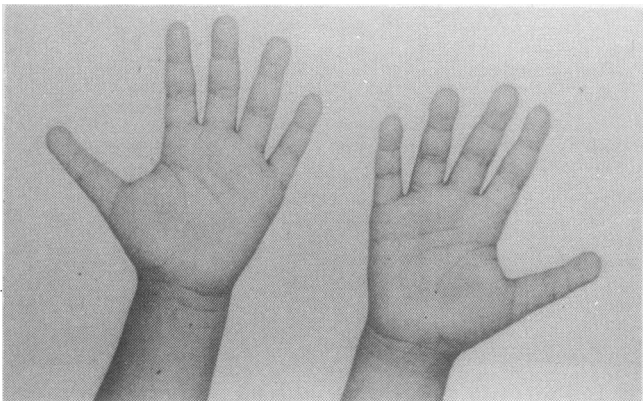


FIG. 1—The proband's hands. Note long triphalangeal thumbs.

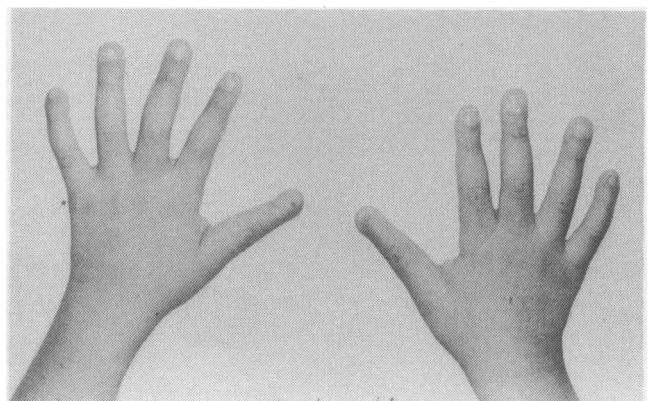


FIG. 2—Dorsal view of the proband's hands.

summarized by Reed and his co-workers⁵ in 1967. During the past decade a number of authors have reported hereditary sensorineural deafness associated with onychodystrophy and other ectodermal dysplasia and digital malformations. In 1961 Feinmesser and Zelig⁸ reported two sisters, in a family of five sibships, with onychodystrophy and sensorineural deafness but no skeletal malformation of the hands. The parents were consanguineous and the inheritance pattern was autosomal recessive. In 1962 Robinson, Millar and Bensimon⁴ reported five cases in three generations of a family with sensorineural deafness of varying degree, onychodystrophy, dental malformations, polydactyly and syndactyly. In this family the hereditary pattern was autosomal dominant. In 1969 Goodman, Lockareff and Gwinup⁹ reported the case of a 61-year-old woman and her 33-year-old son with sensorineural deafness, onychodystrophy, triphalangeal thumbs and malformed or missing end-phalanges. The proband's husband and his sister were also deaf but did not show ectodermal dysplasia. The proband and her husband were not consanguineous. The authors concluded that the mode of transmission was autosomal dominant with mutation in the proband.

In 1970 Walbaum and his co-workers¹⁰ reported a 13-year-old girl and her 3½-year-old brother with sensorineural deafness, onychodysplasia, triphalangeal thumbs, hypoplastic end-phalanges, clinodactyly, camptodactyly and mental retardation. The parents were not consanguineous. The authors concluded that the mode of inheritance was autosomal recessive.

Striking similarities exist between our case and those reported by Goodman, Lockareff and Gwinup⁹ and Walbaum, Fontaine and Lienhardt.¹⁰ While the pattern of transmission in our case appears to be autosomal

dominant with variable expressivity and with a new mutant in the proband's mother, it could also resemble that in the cases reported by Walbaum, Fontaine and Lienhardt¹⁰ where the mode of transmission is autosomal recessive. If so, we would postulate that the proband's mother is a homozygote and his father a heterozygote for the recessive gene.

The pattern of transmission in this syndrome is not clearly established and clarification will have to await publication of further similar cases. Until then it will remain difficult to provide an estimate of the recurrence

risk in later born sibs or in offspring of the affected children. For sibs we can predict that the risk is at least 25% (if recessive) and may be as high as 50% (if dominant). The risk for the affected children's offspring cannot yet be determined.

One cannot overstate the fact that congenital hearing loss often escapes detection for some time after birth. Since the development of language in the deaf child depends so much on the early institution of appropriate remedial measures, it is important to detect hearing loss very early in life. The presence of visible con-

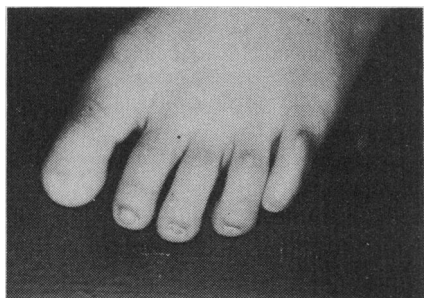


FIG. 3—The proband's left forefoot (the right foot is similar).

Prenavite provides your patient with the basic nutritional needs of pregnancy and lactation.

Prenavite Prenavite Forte



Prenavite Forte provides your patient with 50% more iron as well as the basic nutritional needs of pregnancy and lactation.

Each Prenavite film coated tablet contains:
Vitamin A4,000 I.U.
Vitamin D400 I.U.
Ascorbic Acid100 mg.
Folic Acid2.5 mg.
Iron50 mg.
(as Ferrous Fumarate)
Calcium125 mg.
(as Calcium Carbonate)

Now there are two Prenavite prenatal formulas.
Full information is available on request.



BDH PHARMACEUTICALS
a Glaxo Canada Ltd. Company

TORONTO, MONTREAL, VANCOUVER, WINNIPEG

MEMBER



genital malformations in a child should alert physicians to the possibility of congenital hearing loss. When such a child shows delayed language development as well, congenital hearing loss is not only probable but likely. A physician who is confronted with such a case is well advised to refer him immediately for audiological investigation.

We wish to thank Dr. Margaret Thompson for advice on the genetics of this syndrome, and the Department of Medical Publications, The Hospital for Sick Children, for assistance with the manuscript.

Résumé:

Surdité neurosensorielle héréditaire accompagnant une onychodystrophie et des malformations digitales

Les auteurs présentent un cas de surdité héréditaire accompagnant des malformations tégumentaires et digitales. La mère du patient présentait des anomalies similaires, bien qu'elle ne se soit pas rendue compte de sa surdité. Après avoir passé en revue la littérature pertinente, les auteurs soulignent l'importance de signaler de pareils cas. Ils conseillent de rapporter le maximum de cas semblables, en vue de tenter de clarifier le mode de transmission génétique et d'établir pour les parents des enfants atteint le risque d'apparition de la tare chez des enfants subséquents.

References

1. KONIGSMARK, BW: Hereditary deafness in man (first of three parts). *N Engl J Med* 281: 713-720, 1969
2. Idem: Hereditary deafness in man (second of three parts). *Ibid* pp 774-778
3. Idem: Hereditary deafness in man (third of three parts). *Ibid* pp 827-832
4. ROBINSON GC, MILLER JR, BENSIMON JR: Familial ectodermal dysplasia with sensori-neural deafness and other anomalies. *Pediatrics* 30: 797-802, 1962
5. REED WB, STONE VM, BODER E, et al: Hereditary syndromes with auditory and dermatological manifestations. *Arch Dermatol* 95: 456-461, 1967
6. STEWART JM, BERGSTROM LAV: Familial hand abnormality and sensori-neural deafness: A new syndrome. *J Pediatr* 78: 102-110, 1971
7. DUDGING BA, GORLIN RJ, LANGER LO: The oto-palato-digital syndrome. *Am J Dis Child* 113: 214-221, 1967
8. FEINMESSER M, ZELIG S: Congenital deafness associated with onychodystrophy. *Arch Otolaryngol* 74: 507-508, 1961
9. GOODMAN RM, LOCKAREFF S, GWINUP G: Hereditary congenital deafness with onychodystrophy. *Arch Otolaryngol* 90: 474-477, 1969
10. WALBAUM R, FONTAINE G, LIENHARDT J, et al: Surdit  familiale avec ost o-onychodysplasie. *J Genet Hum* 18: 101-108, 1970

Lupus-like syndrome, with persistent immunological abnormalities, related to procainamide therapy

Tassos P. Anastassiades, M.D., C.M., M.Sc., Ph.D., C.R.C.P.[C] and John A. Milliken, M.D., F.R.C.P.[C], F.A.C.P., Kingston, Ont.

Procainamide has long been considered to have a place in the management of cardiac arrhythmias^{1, 2} and has also been used in the treatment of myotonic dystrophy.^{3, 4} However, the appearance of a systemic lupus erythematosus-like syndrome during procainamide therapy is now well recognized.⁵⁻⁷ The present report describes the occurrence of such a syndrome with serological abnormalities, including a positive anti-nuclear factor and elevated concentrations of serum IgG, following procainamide therapy in a case of myotonic dystrophy. The serological abnormalities have persisted for over two years after discontinuing the procainamide and the disappearance of related clinical symptoms.

Case report

A 37-year-old housewife was seen by her family physician in March 1968 because of a three-month history of attacks of weakness, dizziness and perspiration relieved by lying down. There had been a weight loss of 10 pounds over the past two years and blurring of vision which had been corrected with glasses.

Physical examination at that time revealed a thin woman (118 lbs.) with a blood pressure of 105/80 and a trigeminal pulse. An electrocardiogram showed trigeminal ventricular premature contractions. It was considered that these premature beats might be related to her episodes of dizziness. She was started on diphenylhydantoin, 100 mg. t.i.d., which was subsequently reduced to 100 mg. b.i.d.

In June 1968 an ophthalmologist

From the Department of Medicine, Queen's University and the Hotel Dieu Hospital, Kingston, Ontario.

Reprint requests to: Dr. T. P. Anastassiades, Department of Medicine, Queen's University, Kingston, Ontario.

noted that the anterior portion of her lens contained very fine blue, green and red crystal-like changes, indicative of myotonic dystrophy. On careful questioning it was apparent that generalized fatigue and difficulty in relaxing her grip had been present for several years. On examination at that time there was sternocleidomastoid weakness bilaterally, but no ptosis or percussion myotonia. It was believed that there was some distal muscular atrophy of her arms and legs and decreased deep tendon reflexes. Diphenylhydantoin was discontinued and procainamide, 250 mg. q.i.d., was started. A subsequent electromyographic examination revealed a great deal of abnormal involuntary activity with profuse fibrillation, numerous positive waves and many high frequency discharges, several of the typical dive bomber variety. Voluntary movement exhibited many small amplitude potentials, all less than 500 microvolts.

By July 1969 her strength was further reduced and she was unable to raise her eyebrows or wrinkle her forehead. Procainamide was increased to 500 mg. q.i.d.

In October 1969 she was admitted to hospital because of stiffness and soreness of many of her joints (including the proximal interphalangeal and metacarpophalangeal joints of her hands) and muscle soreness, particularly in her thighs, upper arms and neck. Functional inquiry elicited that in addition to her musculoskeletal problems, she had noted partial frontal alopecia of two years' duration. She was not aware of a family history of muscle or eye disease. However, a careful review of her family tree through five generations has revealed several affected members.

Examination revealed a thin woman with sparse frontal hair and a relatively fixed facial expression. She was unable to sit up in bed by herself and had great difficulty in walking. There was wasting of the temporal, facial, sternocleidomastoid, distal forearm and hand muscles and those of the thighs, especially the