

An improved radiological method for the evaluation of Achilles tendon xanthomatosis

Antoine Gattereau, M.D., M.Sc., F.R.C.P.[C], F.A.P.H.A., Jean Davignon, M.D., M.Sc., F.R.C.P.[C], F.A.C.P., Michel Langelier, M.D. and Henri Paul Levesque, M.D., C.R.C.P. [C], *Montreal*

Summary: Xanthomatous infiltration of tendons is a clinical feature common to many cases of hyperlipidemia. The xanthomas can be detected and only grossly assessed by palpation. This report describes a radiological technique used to assess these lesions at the Achilles tendon level. The "mammography technique" applied to the study of Achilles tendons was used in 32 normolipemic subjects and 32 hyperlipidemic patients. Both tendons could be observed in their entire length and their thickness, greatly increased in xanthomatosis, could be accurately measured. The results of this survey suggest that the radiological approach may provide a useful tool for the routine evaluation and follow-up of tendon xanthomas.

Résumé: Méthode radiologique améliorée pour l'évaluation de la xanthomatose du tendon d'Achille.

L'infiltration xanthomateuse des tendons est un signe clinique courant en de nombreux cas d'hyperlipémie. Jusqu'à présent, on ne pouvait déceler les xanthomes que par la palpation et cette évaluation était grossière. Le présent article décrit une technique radiologique qui a été employée pour déceler et évaluer ces lésions sur le tendon d'Achille. On a appliqué la "technique mammographique" à l'étude du tendon d'Achille chez 32 sujets normolipémiques et 32 malades hyperlipémiques. Grâce à ce moyen, on a pu observer les deux tendons dans toute leur longueur et mesurer avec précision leur épaisseur, qui est considérablement augmentée dans la xanthomatose tendineuse. Il ressort de ces essais que la radiologie peut être une arme utile pour l'évaluation courante des xanthomes tendineux et pour les observations ultérieures.

From the Departments of Nutrition and of Lipid Metabolism and Atherosclerosis Research, Clinical Research Institute of Montreal, and the Department of Radiology, Hôtel-Dieu Hospital, Montreal.

This work was supported in part by a grant from the Quebec Heart Foundation.

Reprint requests to: Dr. Antoine Gattereau, Clinical Research Institute of Montreal, 110 Pine Avenue West, Montreal 130, P.Q.

In a preliminary report¹ a rapid, simple and reliable radiological method of assessing the extent of xanthomatous infiltration of the Achilles tendon has been proposed. This paper describes the details of this method and reports the results of its application to the routine investigation of hyperlipidemia.

Tendon xanthomas are frequently present in hyperlipidemic patients and may be the only clinical manifestation of hyperlipidemia. They are usually found over the extensor tendons of the fingers and toes as well as in the Achilles tendons. Their presence may direct the diagnosis towards a specific type of hyperlipoproteinemia, for they are more likely to be found in types II and III of Fredrickson's classification.² Progression or regression in their size will reflect the effectiveness of treatment. It is therefore important, for evaluation and follow-up of hyperlipoproteinemia, to be able to measure their size with some accuracy. Clinical evaluation alone is rather unsatisfactory as a reference index. Achilles tendon xanthomas, because of their frequency and ease of access, provide an ideal site for such precise measurements. We have used a modification of the mammography technique to study these lesions.³

Material and methods

The mammography technique was successfully applied to soft tissue measurements and to the study of xanthomatous lesions of Achilles tendons.³ Each ankle was radiographed by a single exposure in true lateral position with the lateral malleolus resting on the pack-film holder and the foot flexed at 90°. To avoid motion during exposure the patient was laid on the side being radiographed with the knee semiflexed and resting upon a couch. The 8 x 10-inch mammographic films (Superay "AB" Sandwich Pak by General Aniline & Film, Canada, Ltd.) easily included the lower third of the leg and the back of the foot. Our mammographic unit bears the trade name of Mammo-Rex (Picker X-Ray Manufacturing Ltd., Canada). Its rotating molybdenum anode provides a choice of two focuses, 0.5 and 1 mm.

The large cone used for breast studies was found to be satisfactory for field coverage and collimation. The target-film distance is constant at 68 cm. The kilovoltage was set at 32, 35 or 40 according to the size of the ankle (small, medium or large). A 150 mA current was used. The time exposure varied from 1.25 secs. for a small ankle to 1.75 secs. for a large one. The films were manually developed at 20°C. for seven minutes. The radiographs thus obtained provide a good contrast and excellent soft tissue detail, owing to the small photographic grain size and the small focal spot. The anterior outline of the Achilles tendon is always well demarcated by its immediate apposition to the radiolucent adipose tissue of the spacium subtendinum calcaneare. Its posterior margin is usually also well delineated by the subcutaneous fat, which we found to be thicker in xanthomatosis. The antero-posterior diameter of both Achilles tendons was measured at 8 cm. above the lowest point of the tuber calcanei, using an accurate transparent ruler (Linex Super 50 M., Denmark). This level corresponds approximately to the most prominent part of the lateral malleolus.

In each case the darker of the "sandwich pak" films provided high contrast which was ideal for calculation of the smallest diameter of the calcaneal neck and for detection of vascular calcifications. The lighter of the twin films was more suitable for precise measure-

ment of the Achilles tendon. The size of the calcaneum provides an excellent index of body frame size and also is a reliable reference value for adults. It is used in follow-up studies to verify the reproducibility of the technique. This was assessed by submitting four sets of two films taken three months later on four subjects to four independent examiners. Measurements of both the Achilles tendons and the calcaneum neck were carried out. Treatment of the data by analysis of variance did not disclose any significant difference between the examiners nor between the films of the same subject after the three-month period ($\alpha = 0.01$).

This technique was used in a survey of 64 subjects. Thirty-two men and women, evaluated for hyperlipidemia at the Clinic of Nutrition, Metabolism and Atherosclerosis of the Clinical Research Institute of Montreal, were classified as having type II hypercholesterolemia according to the criteria of Fredrickson, Levy and Lees.³ They were paired with 32 individuals of the same sex and comparable body build and age who were classified as normolipemic (plasma cholesterol and triglyceride ≤ 240 and 140 mg./100 ml., respectively, and a normal lipoprotein pattern on paper electrophoresis). Table I summarizes the main characteristics of the two groups studied: the normolipemic subjects and hypercholesterolemic patients are comparable for age, weight and height when males and females are studied separately.

Table I
Characteristics of two groups of subjects

	Males		Females	
	Normolipemic	Type II	Normolipemic	Type II
Number of subjects	18	13	14	19
Age (years)	33.0 \pm 4.0*	32.0 \pm 5.4	35.1 \pm 8.8	37.2 \pm 7.4
Weight (pounds)	157.3 \pm 12.5	144.8 \pm 11.8	133.5 \pm 19.8	117.5 \pm 8.6
Height (inches)	68.9 \pm 1.4	67.8 \pm 1.4	61.7 \pm 1.2	61.6 \pm 1.1
Plasma cholesterol (mg./100 ml.)	171.1 \pm 13.9	307.5 \pm 40.9	172.4 \pm 19.8	374.8 \pm 66.6
Plasma triglycerides (mg./100 ml.)	84.9 \pm 18.5	114.4 \pm 26.2	68.5 \pm 19.3	101.2 \pm 18.8

*Mean \pm 95% confidence limits

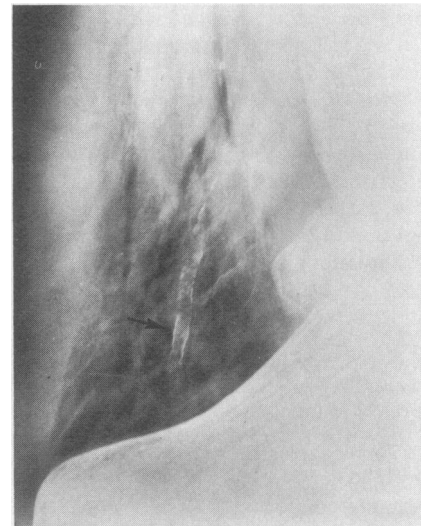
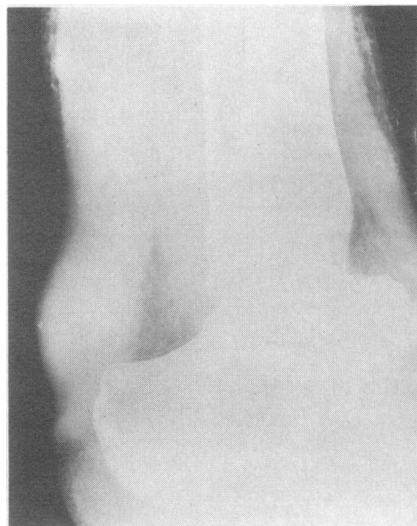
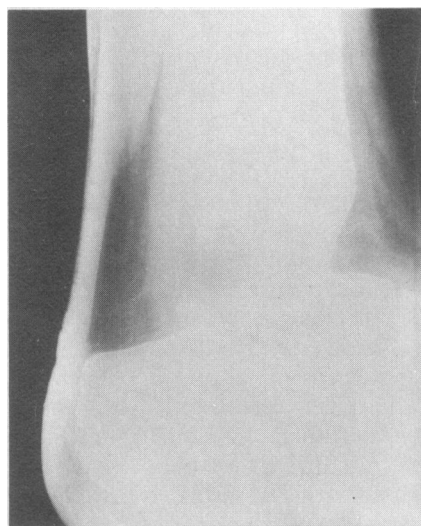


FIG. 1A—Ankle of normal female, age 15, shown for comparison of Achilles tendon and adipose triangle.

FIG. 1B—Ankle of a type II female, age 19. Similar changes (see text) observed in opposite ankle.

FIG. 2—Calcaneous deposits along the walls of the posterior tibial artery of type II male, age 24.

Results

Roentgenograms of the soft tissue of the ankle are shown in Figs. 1A and 1B. The Achilles tendon is always sharply defined and well visualized along its entire length. The tendon is easily recognized because of the good contrast provided by the radiolucent adipose tissue of the spacium subtendinum calcaneare anterior to it and the overlying subcutaneous adipose tissue layer posterior to it. In a normolipemic individual (Fig. 1A) the tendon is rather thin and its outlines are regular. The adipose triangle anterior to the tendon is much wider and much more radiolucent than that of Fig. 1B. In this hyperlipidemic patient the pattern is strikingly different: a significant increase in the anteroposterior diameter of the tendon is seen. The tendon bulges into the nearby adipose tissue which in turn is infiltrated by coarse connective tissue. Although in most abnormal cases the tendon is diffusely involved, localized xanthomas are frequently found at different levels, as in Fig. 1B in which a localized xanthoma is seen on the posterior aspect of the tendon, directly above the tuber calcanei. As shown in Fig. 2, in some hyperlipidemic patients specks of calcium deposits may be observed along the course of the tibial arteries.

Blankenhorn and Meyers⁴ have pointed out that tendon thickness is symmetrical in non-xanthomatous subjects but is often asymmetrical in those with xanthomas. In 21 of the normolipemic subjects a difference was observed between the two ankles; in eight subjects the difference was 15% or more. In the type II patients the tendons were asymmetrical in 30 cases and the difference was 15% or more in 11. Soft tissue roentgenograms of tendon nodules have been reported

to show associated bone erosion.^{5,6} This was not observed in the osseous structures of the lower legs and ankles in this survey.

Fig. 3 shows the mean and 95% confidence limits for the radiological measurement of the Achilles tendon thickness obtained in the survey. Variance analysis of the data disclosed a significant difference in the anteroposterior diameter of the Achilles tendon in normolipemic subjects as opposed to hyperlipidemic patients. This held true for both males (6.52 ± 0.37 and 9.48 ± 2.8 mm, respectively) and females (5.38 ± 0.49 and 12.05 ± 3.3 mm, respectively). Therefore the suggested upper limit of normal is 6.9 mm. for males and 5.9 mm. for females (mean plus 95% confidence limits), indicated by horizontal lines in Fig. 4. When an analysis of the relationship between the main variables was carried out a highly significant positive correlation was found between the Achilles tendon thickness and the plasma cholesterol concentration with a correlation coefficient of 0.854 for females and 0.632 for males. A scattergram of this relationship is shown in Fig. 4. The equation for the line of best fit was computed with a linear least square program. No relationship was found between the Achilles tendon thickness and the diameter of the calcaneum for males or for females. It is noteworthy that abnormal thickening of the tendons was picked up in a few subjects by the roentgenological study after having been missed on clinical examination.

Discussion

Xanthomatosis has long been recognized as the most common and one of the most readily detectable signs of hyperlipidemia. However, current evidence suggests that xanthomas are far more frequent than formerly thought and that one should not rely on clinical examination alone for their detection. In 1957 March, Gilbert and Kain⁷ reported using soft tissue roentgenograms of Achilles tendon xanthomas in three cases of hypercholesterolemic tendon xanthomatosis. However, this technique was not practical because of lack of standardization. In 1969 Blankenhorn and Meyers⁴ described

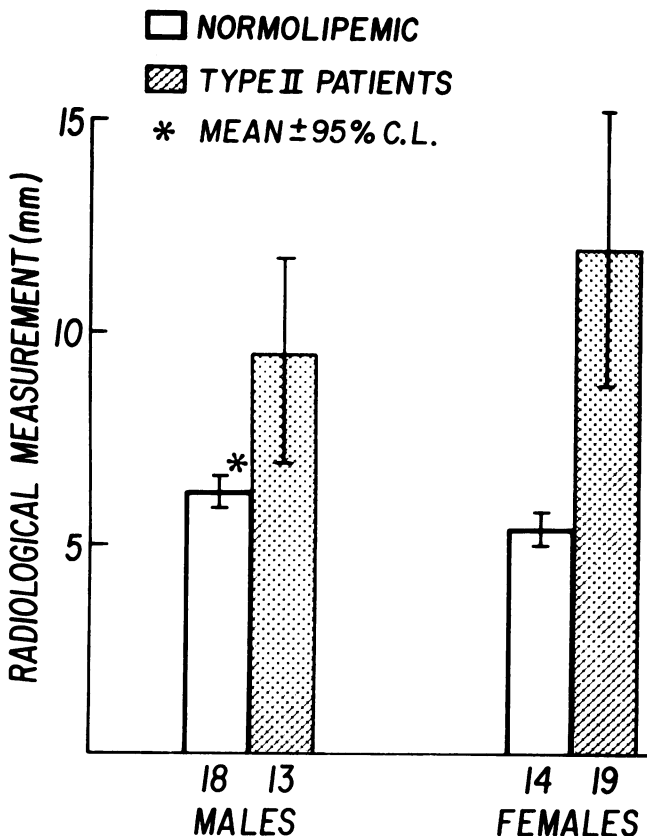


FIG. 3—Thickness of Achilles tendon.

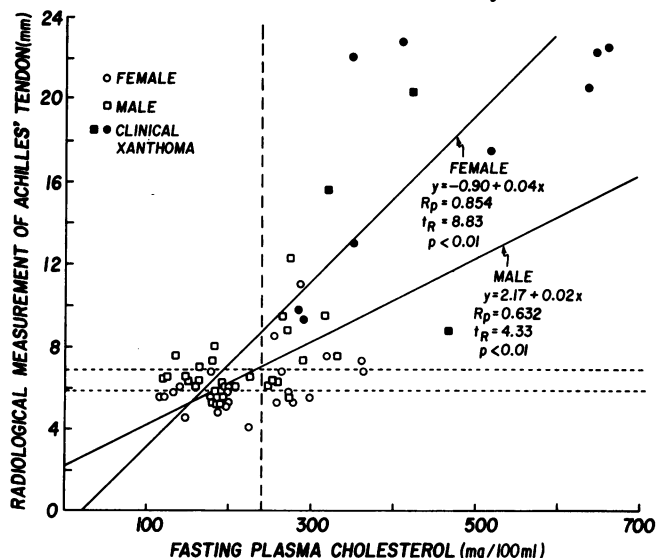


FIG. 4—Scattergram of the relationship between Achilles tendon thickness and plasma cholesterol level. The dotted lines indicate the upper limit of normal for cholesterol (vertical), for tendon thickness in males (upper horizontal) and for tendon thickness in females (lower horizontal).

a "table-top soft tissue radiological technique" to detect and measure Achilles tendon xanthomas. Although this method achieved some standardization, the outcome seems rather unpredictable since the authors reported that "several films with differing exposure factors may be required to outline some xanthomas completely". Furthermore, it appears that it was not always possible to visualize completely the tendon, since measurement was performed only where both the anterior and posterior borders of the tendon were sharply outlined. The radiological approach, using the mammography technique as described, allows one to visualize the tendon in its entire length, to measure it at a fixed point (8 cm. above the lowest point of tuber calcanei) and to analyse its morphological features. The results of this survey indicate that this improved technique is suitable for detection of sub-clinical Achilles tendon xanthomas. Standardization was achieved in such a way that duplicate tendon measurements did not differ by more than 0.5 mm.

It has been claimed that tendon xanthomas do not occur until an advanced age and that they generally do not develop extensively. However, few clinical reports indicate at what age they appear and at what rate they grow. According to Thanhauser⁸ and Borrie⁹ they occur in about 50% of cases of hypercholesterolemia. In reviewing 700 cases from the literature, Shettler¹⁰ found xanthomatosis in one third to one half of patients of all ages with hypercholesterolemia. According to this author the rate may approach 100% in some severely affected families. In 36 patients with hypercholesterolemia Leonard¹¹ described 14 with tendon xanthomas. Piper and Orrild¹² found 42 cases of xanthomas in 112 hypercholesterolemic patients. In this survey of 32 hypercholesterolemic patients 22 (66.6%) were found to have a significant increase in the anteroposterior diameter of the Achilles tendon as measured on the roentgenograms. We believe this to indicate xanthomatous infiltration of the tendon. The higher prevalence observed in this series may be the result of a better means of detection as provided by our technique.

The difficulty or impossibility of inducing a regression in tendon xanthomas has been repeatedly commented upon in the literature. Hood and Angervall¹³ reported a 50-year-old hyperlipidemic man who responded, after 13 months on a combined regimen of fat-poor diet, intravenous heparin and ethinyl estradiol, by a disappearance of xanthomas in both dorsal tendons of the hands and Achilles tendons. Reduction in size of tendon xanthomas has also been reported by Scott and Hurley¹⁴ but the change has not been documented by measurement. It is our view that this more refined technique may be suitable for assessing reduction of xanthoma size where it would otherwise escape clinical evaluation alone. Repeated attempts have been made to relate the degree of hypercholesterolemia to the development of xanthomas.^{11-13,15-17} According to these studies only 1 of 20 patients less than 50 years of age exhibited xanthomas when plasma cholesterol level was between 300 and 350 mg./100 ml. Conversely, when cholesterol concentration was between 400 and 450 mg./100 ml., xanthomas were observed in three of five patients in the third decade and five of six in the fourth decade. In this survey of 32 type II hyper-

cholesterolemic patients a good correlation was found between the high serum concentrations and the radiological index. However the small size of the sample and the wide range of ages studied did not permit us to draw any conclusion about the distribution of abnormal tendons in relation to specific age groups. As expected, cholesterol concentration was not related to the radiological index in the normocholesterolemic subjects. The radiological study, as described, is a useful tool for the quantitative and objective assessment of Achilles tendon xanthomatosis. Although the exact significance of vascular calcifications and the connective tissue alterations noticed at the level of the para-articular fat pads is unknown, these additional observations may eventually prove to be of importance.

Tendon xanthomatosis occurs mostly in type II and more rarely in type III hyperlipidemia. The usefulness of this technique in the follow-up of hyperlipidemic patients is therefore restricted to these two categories of xanthomatous patients. It must be kept in mind however that Achilles tendon xanthomas may be found in normocholesterolemic patients such as those affected with cerebrotendinous xanthomatosis.¹⁸ The demonstration of abnormal levels of cholestanol in plasma and tissues is needed to confirm the diagnosis of this rare disease entity.

The ease and reliability of the radiological approach as well as the need for an objective and reproducible means of assessing the effect of therapy upon the evolution of xanthomas may lead us to advocate the routine use of this technique in the investigation and follow-up of hyperlipidemia.

The authors thank Mrs. Diane Giroux, Mrs. Nicole Patard and Mr. Michel Tremblay for their excellent technical assistance. The help of Miss Isabelle Morin and Miss Huguette Blais for the illustration and typing of the manuscript is deeply appreciated.

References

1. GATTEREAU A, DAVIGNON J, LEVESQUE HP: Roentgenological evaluation of Achilles' tendon xanthomatosis. *Lancet* II:705, 1971
2. FREDERICKSON DS, LEVY RI, LEES RS: Fat transport in lipoproteins. An integrated approach to mechanisms and disorders. *N Engl J Med* 276:32, 94, 148, 215, 273, 1967
3. GERSHON-COHEN J, FORMAN M: Mammography of cancer. *Bull NY Acad Med* 40:674, 1964
4. BLANKENHORN DH, MEYERS HI: Radiographic determination of Achilles' tendon xanthoma size. *Metabolism* 18: 882, 1969
5. WEINTROB L, TRUSWELL AS: A case of type III hyperlipoproteinaemia with xanthomata. *Br J Radiol* 44:215, 1971
6. SNEIDER P: Xanthoma of the calcaneus. *Br J Radiol* 36: 222, 1963
7. MARCH HC, GILBERT PD, KAIN TM: Hypercholesterolemic xanthomata of the tendons. *Am J Roentgenol Radium Ther Nucl Med* 77:109, 1957
8. THANHAUSER SJ: *Lipidoses: Diseases of the intracellular lipid metabolism*, third ed. New York, Grune and Stratton, 1958, p 345
9. BORRIE P: Essential hyperlipaemia and idiopathic hypercholesterolemic xanthomatosis. *Br Med J* II:911, 1957
10. SCHEITLER G (editor): *Lipids and lipidoses*. New York, Springer-Verlag, 1967
11. LEONARD JC: Hereditary hypercholesterolaemic xanthomatosis. *Lancet* II:1239, 1956
12. PIPER J, ORRILD L: Essential familial hypercholesterole-

Continued on page 50

data on blood groups of renal transplant recipients and patients with glomerulonephritis.

References

1. FORREST JN, DISMUKES WE: Dialysis associated hepatitis on 108 U.S. hemodialysis units (abstract). *Clin Res* 16: 383, 1968
2. LONDON WT, DIFIGLIA M, SUTNICK AI, et al: An epidemic of hepatitis in a chronic-hemodialysis unit. Australia antigen differences in host response. *N Engl J Med* 281: 571, 1969
3. TURNER GC, BRUCE WHITE GB: S.H. antigen in haemodialysis-associated hepatitis. *Lancet* II: 121, 1969
4. HAWE BJ, GOLDSMITH HJ, JONES PO: Dialysis-associated hepatitis? Prevention and control. *Br Med J* I: 540, 1971
5. IVEY KJ, CLIFTON JA: Liver disease in patients treated with chronic hemodialysis (editorial). *Gastroenterology* 59: 630, 1970
6. PENN I, HAMMOND W, BELL P et al: Hepatic disorders in renal homograft recipients. *Curr Top Surg Res* 1: 67, 1969
7. MOORE TC, HUME DM: The period and nature of hazard in clinical renal transplantation. I. The hazard to patient survival. *Ann Surg* 170: 1, 1969
8. EVANS DB, MILLARD PR, HERBERTSON BM: Hepatic dysfunction associated with renal transplantation. *Lancet* II: 929, 1968
9. KURUVILA KC, POPOWNIAC KL, NAKAMOTO S: Serum hepatitis and Australia antigen after renal transplantation (abstract). Presented at the American Society of Nephrology, Washington, November 1970
10. TORISU M, YOKOYAMA T, AMEMIYA H, et al: Immunosuppression, liver injury, hepatitis in renal, hepatic and cardiac homograft recipients: with particular reference to Australia antigen. *Ann Surg* 174: 620, 1971
11. REED W, LUCAS ZJ, KENDSON R, et al: Renal transplantation in patients with Australia antigen. *Transplantation Proc* 3: 343, 1971
12. MACLEAN LD, DOSSETOR JB, GAULT MH, et al: Renal homotransplantation using cadaver donor. *Arch Surg* 91: 288, 1965
13. DOSSETOR JB, MACKINNON KJ, GAULT MH, et al: Cadaver kidney transplants. *Transplantation* 5: 844, 1967
14. POPPER H, SCHAFFNER F: The vocabulary of chronic hepatitis (editorial). *N Engl J Med* 284: 1154, 1971
15. BLUMBERG BS, RIDDEL RM: Inherited antigenic differences in human sera. Beta lipoproteins. A second antiserum. *J Clin Invest* 42: 867, 1963
16. PURCELL RH, HOLLAND PV, WALSH JH, et al: A complement-fixation test for measuring Australia antigen and antibody. *J Infect Dis* 120: 383, 1969
17. ROWE WP, HARTLEY JW, CRAMBLETT HG, et al: Detection of human salivary gland virus in the mouth and urine of children. *Am J Hyg* 67: 57, 1958
18. AHMED NH, HUANG SN, SPENCE L: Australia antigen and hepatitis. An electron microscopic study. *Arch Pathol* 92: 66, 1971
19. HUANG SN: "Hepatitis-associated antigen" hepatitis. An electron microscopic study of virus-like particles in liver cells. *Am J Pathol* 64: 483, 1971
20. HUANG SN, MILLMAN I, O'CONNELL A, et al: Immunoelectron microscopic study of virus-like particles in human liver with Australia antigen associated hepatitis. *Am J Pathol*, June 1972 (in press)
21. KELEN AE, HATHAWAY AE, MCLEOD DA: Rapid detection of Australia/SH antigen and antibody by a simple and sensitive technique of immunoelectronmicroscopy. *Can J Microbiol* 17: 993, 1971
22. SHERLOCK S: *Diseases of the Liver and Biliary System*, fourth ed. London, Davis Publishing Co, 1968, p 338
23. LEWKONIA RM, FINN R: ABO blood group distribution in serum hepatitis. *Br Med J* III: 268, 1969
24. SZMUNESS W, PRINCE AM, CHERUBIN CE: Serum hepatitis antigen ((SH) carrier state: relation to ABO blood groups. *Br Med J* II: 198, 1971
25. ZUCKERMAN AJ, MACDONALD JC: ABO blood groups and acute hepatitis. *Br Med J* II: 537, 1963
26. REID NCR, BRUNT PW, BIAS WB, et al: Genetic characteristics and cirrhosis: a controlled study of 200 patients. *Br Med J* II: 463, 1968
27. RANEK L, JUHL E: Blood group distribution in patients with cirrhosis of the liver. *Scand J Gastroenterol* (suppl 7): 203, 1970
28. ROBERT JAF: Cancer and human genetics. ABO blood groups and disease. *Br J Prev Soc Med* 22: 464, 1970
29. BILLINGTON BP: A note on distribution of ABO blood groups in bronchiectasis and portal cirrhosis. *Australas Ann Med* 5: 20, 1956
30. SUTNICK AL, LONDON WT, BLUMBERG BS: Australia antigen. A genetic basis for chronic liver disease and hepatoma? (editorial). *Ann Intern Med* 74: 442, 1971
31. KRUGMAN C, GILES JP, HAMMOND J: Infectious hepatitis *JAMA* 200: 365, 1967
32. ALLEN JG: Some factors regulating duration of incubation for serum hepatitis. *Arch Surg* 100: 2, 1970
33. SPENCER ES, ANDERSEN HK: Clinically evident, non-terminal infections with herpes viruses and the wart virus in immunosuppressed renal allograft recipients. *Br Med J* III: 251, 1970
34. NIELSEN JO, DIETRICHSON O, ELLING P, et al: Incidence and meaning of persistence of Australia antigen in patients with acute viral hepatitis: Development of chronic hepatitis. *N Engl J Med* 285: 1157, 1971
35. SHERLOCK S, FOX RA, NIAZI SP, et al: Chronic liver disease and primary liver-cell cancer with hepatitis-associated (Australia) antigen in serum. *Lancet* I: 1243, 1970
36. MITCHELL CG, EDDLESTON ALW, SMITH MGM, et al: Serum immunosuppressive activity due to azathioprine and its relation to hepatic function after liver transplantation. *Ibid*, p 1196
37. STARZL TE, MARCHIORO TL, PORTER KA, et al: Factors determining short- and long-term survival after orthotopic liver homotransplantation in the dog. *Surgery* 58: 131, 1965.
38. HUGGINS CE: Hepatitis in hemodialysis units (letter to the editor). *N Engl J Med* 283: 657, 1970

Continued from page 42

13. HOOD B, ANGERVALL G: Studies in essential hypercholesterolemia and xanthomatosis. Relationship between age, sex, cholesterol concentrations in plasma fractions and rise of tendinous deposits. *Am J Med* 26:30, 1959
14. SCOTT PJ, HURLEY PJ: Effect of clofibrate on low density lipoprotein turnover in essential hypercholesterolaemia. *J Atheroscler Res* 9:25, 1969
15. HARRIS-JONES JN, JONES EG, WELLS PG: Xanthomatosis and essential hypercholesterolaemia. *Lancet* I:855, 1957
16. GURAVICH JL: Familial hypercholesterolemic xanthomatosis: preliminary report. I. Clinical, electrocardiographic and laboratory considerations. *Am J Med* 26:8, 1959
17. NITTER-HAUGE S: Juvenile xanthomatosis—a recessive inherited disease. *Acta Med Scand* 179:71, 1966
18. PHILIPPART M, VAN BOGAERT L: Cholestanolosis (cerebrotendinous xanthomatosis). *Arch Neurol* 21:603, 1969