

INVOLUTING AND SCARRED GLOMERULI IN THE KIDNEYS OF INFANTS

JOHN L. EMERY, M.D., D.C.H., AND MORAG S. MACDONALD, M.D., Ch.B., D.C.H.*

From the Department of Pathology, The Children's Hospital, Sheffield, England

It was Herxheimer¹ who, in 1909, first drew attention to the presence of scarred glomeruli (Fig. 1) in the cortex of kidneys of children dying in the neonatal period. He noted the presence of such glomeruli in a very high proportion (80 per cent) of children he examined. He described the histologic appearance of the scarred glomeruli in detail and, indeed, his description could not be bettered now. He attributed their presence to a developmental imbalance between the epithelial and the mesenchymal parts of the nephron.

The scarred glomeruli show varying features. Minimal lesions consist of an increase in connective tissue around Bowman's capsule and a disappearance of vessels from part of the glomeruli. At the same time there appears to be a reversion of the epithelium of the glomerulus, first to a cuboidal appearance, and later, to columnar cells with palisading. The more severe or later lesion has fibrosis and shrinkage within the glomerulus and a gradual reduction in size of the whole glomerulus and capsule. The final lesion consists of an almost solid circular mass of connective tissue containing a few "epithelioid" cells. The changes in the glomeruli seem to occur at the same time as the scarring about Bowman's capsule.

These scarred glomeruli have aroused relatively little comment, and we have been able to locate only two later studies, that of Schwarz² and more recently, Friedman, Grayzel and Lederer.³ The latter found scarred glomeruli in a small group of infants. At first they considered them evidence of nephritis, but on carrying out a survey of 100 controls and finding the lesions to be present in a high proportion of these also, they suggested the term "congenital glomerulosclerosis." The present paper is concerned with an investigation of the incidence and distribution of scarred glomeruli; this constitutes part of a survey of the post-natal development of the kidney.

MATERIAL AND METHODS

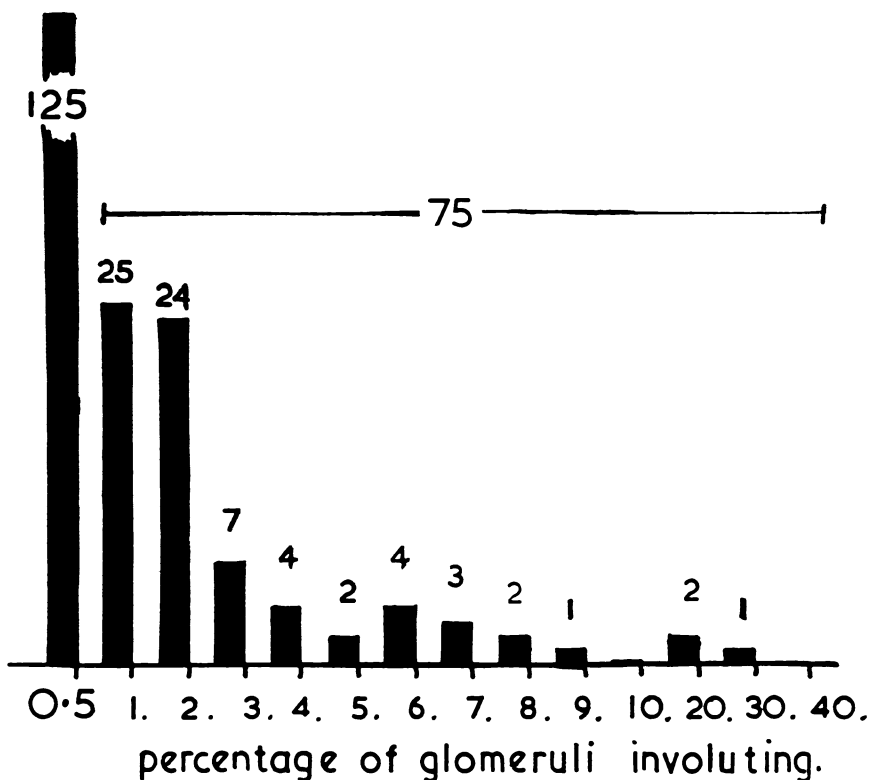
The material comes from two sets of observations. The first represents a series of 200 kidneys analyzed on the basis of the structure of

Received for publication, August 5, 1959.

* Working under a grant from the Medical Research Council.

the glomeruli. The second constitutes a separate study of 250 additional kidneys.

For the first study, kidneys were chosen by a system of random numbers from the necropsy records at the Sheffield Children's Hospital.

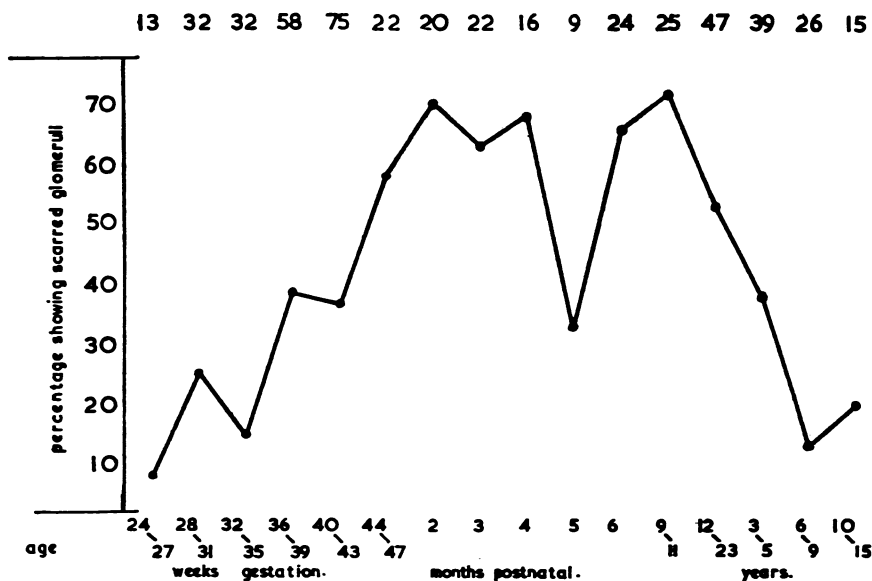


TEXT-FIGURE 1. Histogram showing the frequency distribution of involuting scarred glomeruli from differential counts of 200 glomeruli in each of 200 kidneys.

Kidney sections were procured from blocks that had been cut in true radial fashion and systematic column counts or battlement counts were carried out by using the system commonly applied in differential white cell counts on blood smears. In this case the renal cortex was surveyed from the capsule to the full depth of the cortex. The field was then moved to an adjacent area, and the area surveyed to the capsule, the procedure being repeated. The glomeruli were classified in stages of maturity,⁴ and scarred forms were recorded.

Kidneys exhibiting any naked-eye deformity of the renal tract or showing histologic abnormality, e.g., pyelonephritis, were excluded. All the kidneys had been passed previously by one of us (JLE) in routine histologic survey, as being within normal limits. In this survey, approximately 200 glomeruli from each kidney were classified.

During the course of this study, it was noted that the scarred glomeruli were not distributed in a random way throughout the cortex, and a second survey was carried out to record their location. At the same time the presence or absence of abnormally large glomeruli in the juxtamedullary or arcuate zones was noted. In the second series of 250 kidneys, systematic battlement surveys covering between 300 and 500 glomeruli were carried out. Again these kidneys were selected completely arbitrarily from the laboratory files, the ages and diseases of the children not being known to the person examining the sections.



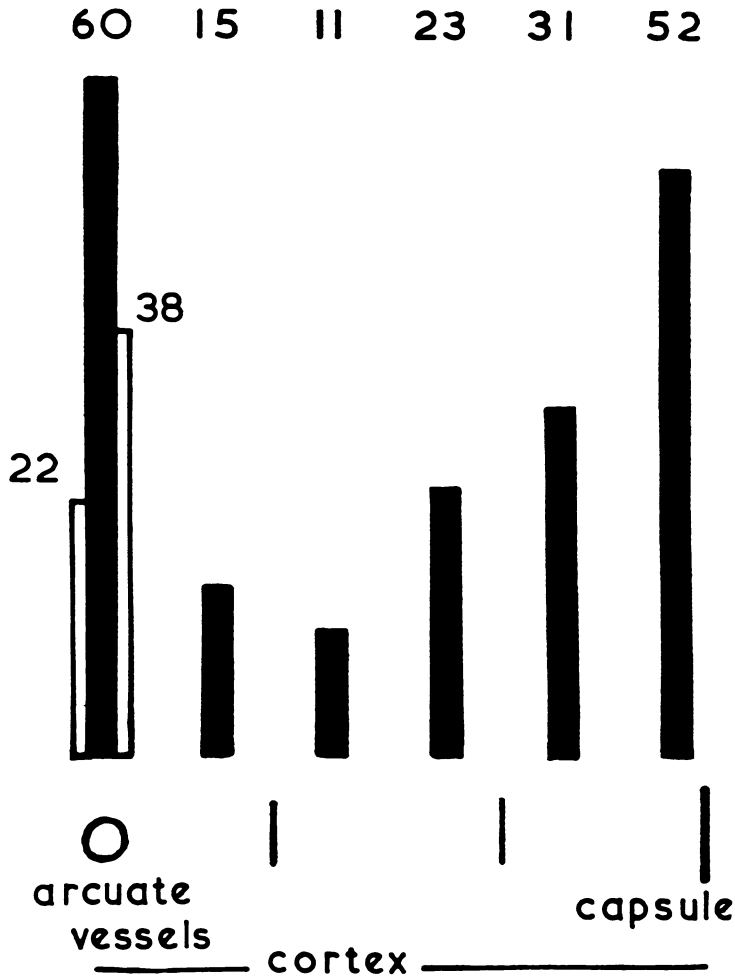
TEXT-FIGURE 2. Graph of the percentage incidence of kidneys showing scarred glomeruli, against age in a series of 475 cases. The figures along the top of the graph are the actual numbers of cases in each age group.

RESULTS

The incidence of scarred glomeruli (Fig. 1) in the 200 kidneys in which differential glomerular counts were carried out is shown in Text-figure 1. The figures represent the percentage of scarred forms found in counts of approximately 200 glomeruli in each kidney. Scarred forms were seen in 75 cases, and not noted in 125. Later inspection of sections from the latter group often revealed scarred forms outside the counted random area—i.e., these 125 represent an incidence of less than 0.5 per cent rather than the absence of scarred forms.

Most of the kidneys with scarred glomeruli showed an incidence of 1 or 2 per cent, but a few contained up to 10 per cent, and 3 kidneys contained the forms in the range of 20 to 30 per cent. The total number

containing scarred forms in a series of 475 children is presented in Text-figure 2, the percentage incidence being related to age. The ages of the children are shown here, as in all the subsequent charts, as age from conception up to 48 weeks (i.e., 2 months after birth, for a 40-week

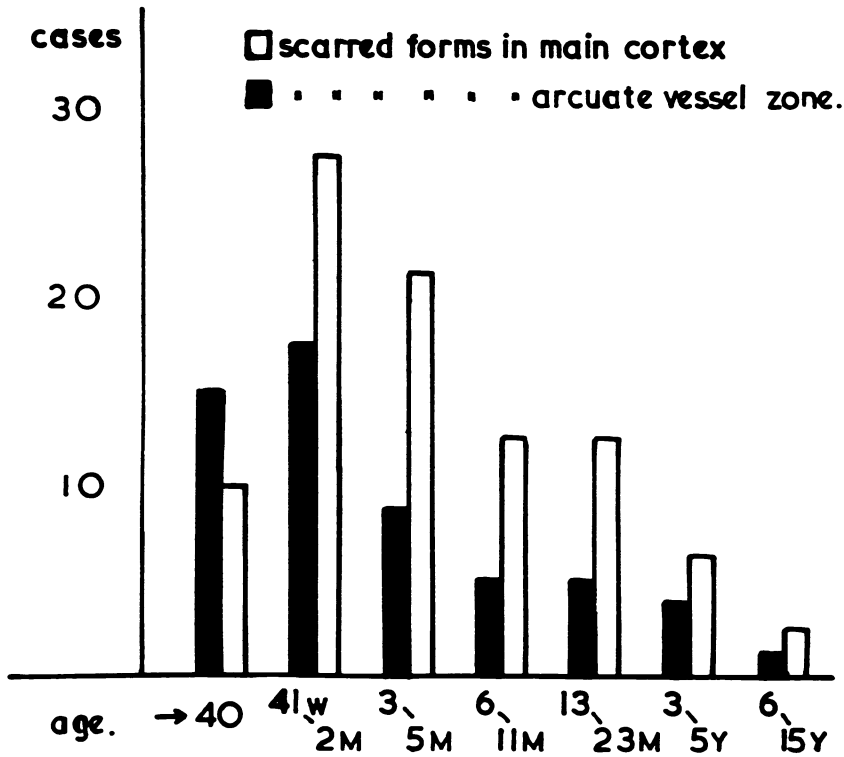


TEXT-FIGURE 3. Diagram showing the distribution pattern of scarred glomeruli in the renal cortex in a series of battlement differential counts of 275 kidneys. The unblocked columns refer to the proportion of the glomeruli on the medullary and cortical sides of the arcuate vessels.

gestation). Over this age they are given as postnatal age. The number of children within each age group is indicated above the graphs. The incidence of scarred glomeruli appeared to increase steadily during the later months of pregnancy and the first postnatal months, and then maintained a steady fall throughout childhood. The lower figures for the

4- to 5-month-old children are probably related to the small number of cases in that age group.

The location of the scarred glomeruli within the cortex is represented diagrammatically in Text-figure 3. For the purpose of this survey, the

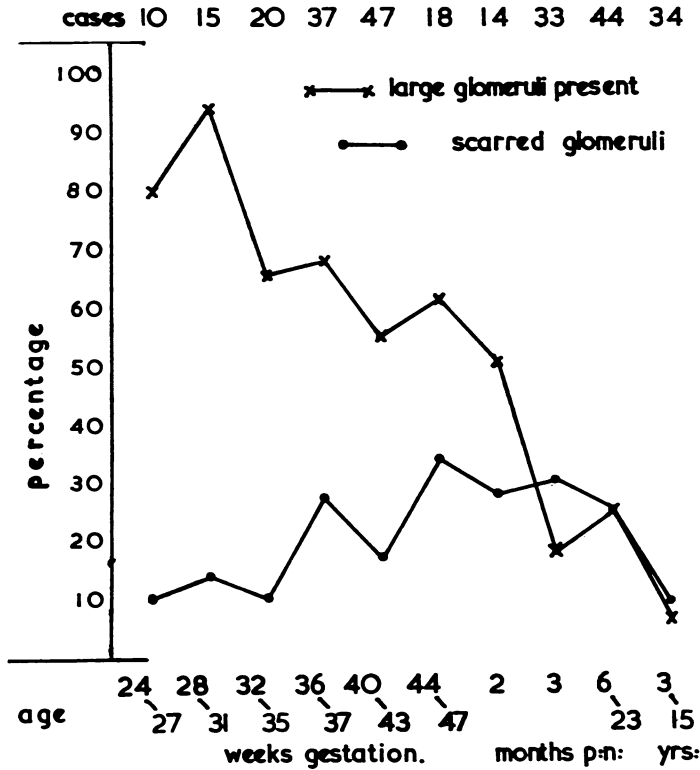


TEXT-FIGURE 4. Diagram showing the separate frequency distribution by age of scarred glomeruli in the arcuate zone and in the remainder of the cortex.

cortex was divided into 6 zones, and the scarred glomeruli in each zone were recorded. The zones were judged more on the number of glomeruli present than on the actual linear depth of the cortex (Fig. 2). This was necessary because in the very young infant, the glomeruli are much more tightly packed at the periphery than at the center, and if the cortex was divided in equal parts, there would be an apparent migration from the capsule toward the medulla in older kidneys. In Text-figure 3, each point does not represent an individual case because each zone in which scarred glomeruli were found was marked—i.e., a kidney showing scarred forms in the arcuate region and immediately beneath the capsule would be charted in both zones.

It is apparent that the scarred forms do not occur in a completely random distribution within the kidney, but are principally located in

two zones, one in the region of the arcuate vessels, and the other in an increasing number as the capsule is approached. This suggests that there are two distinct factors acting in the production of scarred glo-



TEXT-FIGURE 5. Graph showing the frequency distribution by age of large glomeruli and of scarred glomeruli in the juxtamedullary zone.

meruli; one localized about the arcuate vessels and associated with these, and the other directed toward the outer layer of the cortex.

These two zones were therefore analyzed separately, and Text-figure 4 shows the relative proportion of scarred glomeruli in the arcuate zone compared with the rest of the cortex at different ages. Scarred glomeruli in the arcuate region are relatively more common in the very young and immature children than in the older age groups.

It had occurred to us that there might be some relationship between the very large glomeruli found in the juxtamedullary and arcuate region of very young kidneys (Fig. 2) and the presence of large numbers of involuted forms in this area. In Text-figure 5 the two are correlated. The upper graph shows the percentage of kidneys in which large glomeruli were seen in the arcuate region.

These large glomeruli apparently disappear during the first few years

of extra-uterine life, and the fall in numbers appears to be fairly uniform and consistent throughout the first 2 to 3 years. In the newborn the difference in size between the large glomeruli around the arcuate vessels and the rest of the glomeruli is very marked (Fig. 2). In older children this difference is less apparent because of the growth of the other glomeruli. We were aware of the possibility of this fallacy. Thus, a deliberate attempt was made to overcome false assessment, and the ages of the kidneys were not known when examined.

The proportion of kidneys in which scarred glomeruli were found in the juxtamedullary or arcuate zone is shown in Text-figure 5. These glomeruli increase in number during the later stages of intra-uterine life, and appear to be maximal within the first 6 months, falling off rapidly with the disappearance of the large glomeruli in this same zone.

From this survey it would appear that the proportion of scarred glomeruli likely to be found depends upon the age of the kidney examined (Text-fig. 2). We have also gained the impression that an occasional scarred glomerulus would be found in the kidneys of all children if sufficient sections were examined. Also, as can be seen in Text-figure 1, in which the percentages of scarred glomeruli are shown, there is probably a complete gradation from kidneys with isolated individual scarred glomeruli to those showing sufficient scarring to be of pathologic importance.

Our observations correspond reasonably with smaller series in previously published papers, and differences can be accounted for by the numbers of sections examined and differences in age selection. Herxheimer¹ found scarred glomeruli in 38 (88 per cent) of 43 children. Schwarz² found them in 45 (56 per cent) of 80 children and infants up to the age of 17 months. When he broke these down into age groups, he found that only 30 per cent of the children under 3 weeks of age showed scarred glomeruli. He did not work out their ages on a gestational basis. Friedman, Grayzel and Lederer³ found the lesions in all of a selected group of 13 stillborn infants, and later, in an unselected group of 100 children, found 17 examples.

Kampmeier⁵ found that in the 48 mm. fetal pig, glomeruli existed near the center of the organ of a size greater than that of the general cortical glomeruli in the 250 mm. piglet. He suggested that these glomeruli were transitory structures.

The distribution of scarred glomeruli within the human renal cortex appears to be in two different areas, suggesting two different populations. One group is associated with the arcuate vessels; these appear early and apparently disappear early in the life of the child, being maximal almost immediately following birth. The second group is found

in increasing numbers as the capsule is approached, and is most prominent during the first two years after birth.

We will discuss the two groups of glomeruli separately. In studying the juxtamedullary zone, attention is quickly drawn to the presence of very large glomeruli in this area. These large glomeruli were noted by Herring,⁶ Tsuda,⁷ in his measurements of infantile glomeruli, showed that these glomeruli were virtually at adult size in the metanephric kidney in the 4-month fetus, and remained so throughout the whole of fetal life. Such glomeruli can be seen easily (Fig. 2) in the human kidney and frequently give the impression of being almost completely isolated from the rest of the cortex.

We have found that the large juxta-arcuate glomeruli are almost always present in the mid part of intra-uterine life and that they disappear progressively and become uncommon after 6 months following birth (Text-fig. 5). Their disappearance is associated with a high incidence of glomeruli apparently showing progressive fibrosis in the same area. It would seem likely that in these fibrosing glomeruli we are seeing the involution of the large glomeruli and that they are analogous to those which Kampmeier⁵ suggested were provisional metanephric structures in the pig and man. Our evidence indicates that there is a single zone of these glomeruli and not a continuous series as Kampmeier⁵ postulated.

Concerning the scarred glomeruli in the cortex, we have seen no significant difference between their method of scarring and those near the arcuate vessels. Herxheimer's original description is equally applicable to all of the lesions discussed here. There appears, however, to be an increase in the proportion of scarred glomeruli as the capsule is approached. The glomeruli in the subcapsular area are the most recently formed and are in a state of active proliferation at least until the time of birth^{8,9} and in some cases after birth.⁴ If the scarred forms in the main cortex were related to age, we would expect to find a larger number of them situated deeply in the cortex than at the periphery. It is the inverse relationship of scarring to maturity that makes the peripheral group of glomeruli seem to have a different cause from that contributing to the isolated large forms near the arcuate vessels. If glomeruli were liable to abnormal development in a random way, those in the deeper layers would be as susceptible to degeneration as those near the cortex. It is possible that this has occurred in the kidneys examined, and that the older abnormal glomeruli have disappeared completely,¹⁰ but this seems to us unlikely. The distribution of lesions suggests some factor acting late in pregnancy or in early postnatal life.

A large number of conditions are known to damage glomeruli in many ways,¹¹ and metabolic diseases, particularly diabetes,¹² cause intraglo-

merular sclerotic alterations. There are well recognized lesions in the maternal kidneys in toxemia of pregnancy,^{13,14} and the infantile kidney could be similarly affected. Von Reuss¹⁵ refers to 4 instances in which children exhibited "nephritis" in the first few days after birth, following eclampsia in the mother.

Without further evidence, any further discussion beyond this point would appear to be pure speculation. In the present series, the kidneys were deliberately selected in a random manner. Perinatal and pregnancy histories are often inadequate, so it would not be justifiable to attempt a complete correlation with clinical features. A further investigation, using only cases with adequate histories, and in which the kidneys will be assessed "blindly," is being attempted.

SUMMARY

A study has been made of the incidence and distribution of scarred glomeruli in the kidneys of a series of 475 children. Scarred glomeruli were found in a range of 10 to 70 per cent of children, depending upon the age of the child. The incidence was highest during the latter part of the first year after birth. The proportion of glomeruli affected was usually in the region of 1 per cent, but occasionally 20 to 30 per cent were affected.

The scarred glomeruli were found in two zones; one near the arcuate vessels and the other near the capsule. It is suggested that the scarred glomeruli in the arcuate vessels represent involution forms of large glomeruli which form very early in this region in intra-uterine life, and possibly represent a transitory renal structure. Peripherally situated scarred glomeruli may be related to disease processes occurring during the later development of the fetus or in the period immediately following birth.

REFERENCES

1. HERXHEIMER, G. Über hyaline Glomeruli der Neugeborenen und Säuglinge. *Frankfurt. Ztschr. Path.*, 1909, 2, 138-152.
2. SCHWARZ, L. Weitere Beiträge zur Kenntnis der anatomischen Nierenveränderungen der Neugeborenen und Säuglinge. *Virchows Arch. path. Anat.*, 1928, 267, 654-689.
3. FRIEDMAN, H. H.; GRAYZEL, D. M., and LEDERER, M. Kidney lesions in still-born and newborn infants. "Congenital glomerulosclerosis." *Am. J. Path.*, 1942, 18, 699-713.
4. MACDONALD, M. S., and EMERY, J. L. The postnatal development of the glomeruli in the human kidney. *J. Anat.* In press.
5. HERRING, P. T. The development of the malpighian bodies of the kidney and its relation to the pathological changes which occur in them. *J. Path. & Bact.*, 1900, 6, 459-496.

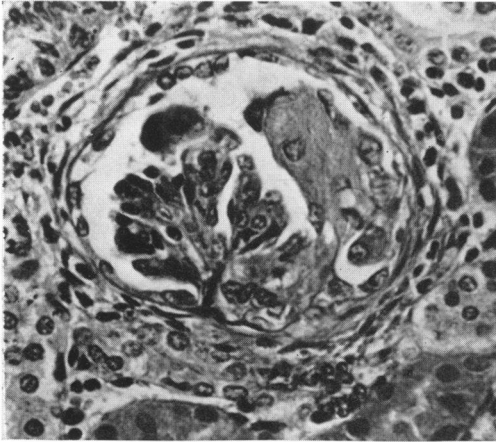
6. TSUDA, S. Histologic investigation of the foetal kidney. *Jap. J. Obst. & Gynec.*, 1934, 17, 337-341.
7. KAMPMEIER, O. F. The metanephros or so-called permanent kidney in part provisional and vestigial. *Anat. Rec.*, 1926, 33, 115-120.
8. GRUENWALD, P., and POPPER, H. The histogenesis and physiology of the renal glomerulus in early postnatal life: histological examinations. *J. Urol.*, 1940, 43, 452-458.
9. POTTER, E. L., and THIERSTEIN, S. T. Glomerular development in the kidney as an index of fetal maturity. *J. Pediat.*, 1943, 22, 695-706.
10. MORITZ, A. R., and HAYMAN, J. M., JR. The disappearance of glomeruli in chronic kidney disease. *Am. J. Path.*, 1934, 10, 505-518.
11. HORN, H. The experimental nephropathies. *Arch. Path.*, 1937, 23, 71-121; 241-264.
12. HORN, R. C., JR., and SMETANA, H. Intercapillary glomerulosclerosis. *Am. J. Path.*, 1942, 18, 93-99.
13. GOVAN, A. D. T. Renal changes in eclampsia. *J. Path. & Bact.*, 1954, 67, 311-322.
14. PIRANI, C. L.; POLLAK, V. E.; NETTLES, J. B.; KARK, R. M., and MUEHRCKE, R. C. Reversible and irreversible glomerular lesions in toxemia of pregnancy. (Abstract) *Am. J. Path.*, 1956, 32, 650-651.
15. VON REUSS, A. R. The Diseases of the Newborn. J. Bale Sons & Danielson, London, 1920, p. 332.

Much of the material used in this study came from necropsies carried out through the courtesy of Dr. A. J. N. Warrack at the City General Hospital, Sheffield. Photographs are by Mr. R. Cousins.

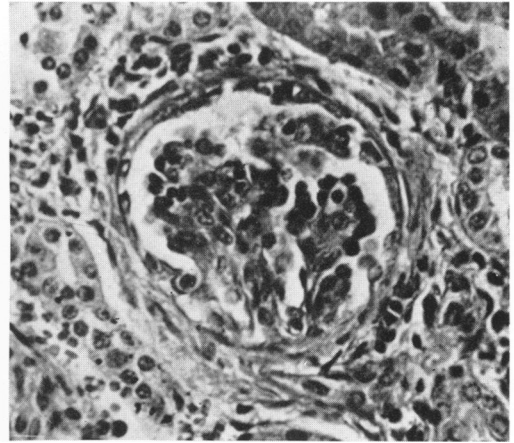
LEGENDS FOR FIGURES

- FIGS. 1A and 1B. Two examples of a glomerular tuft being replaced by large fibroblast-like cells; there is an increase in connective tissue around Bowman's capsule. Hematoxylin and eosin stain. $\times 150$.
- FIGS. 2A and 2B. The entire depth of the renal cortex in (A) a 36-week infant and (B) a 40-week infant. Primitive glomeruli are seen beneath the capsule (A; arrow). In the deepest part of the cortex adjacent to an arcuate vessel, an isolated large glomerulus can be seen (B; arrow). The circles and lines at the margins of the photographs correspond to the lines shown dividing the cortex in Text-figure 3. Hematoxylin and eosin stain. $\times 50$.

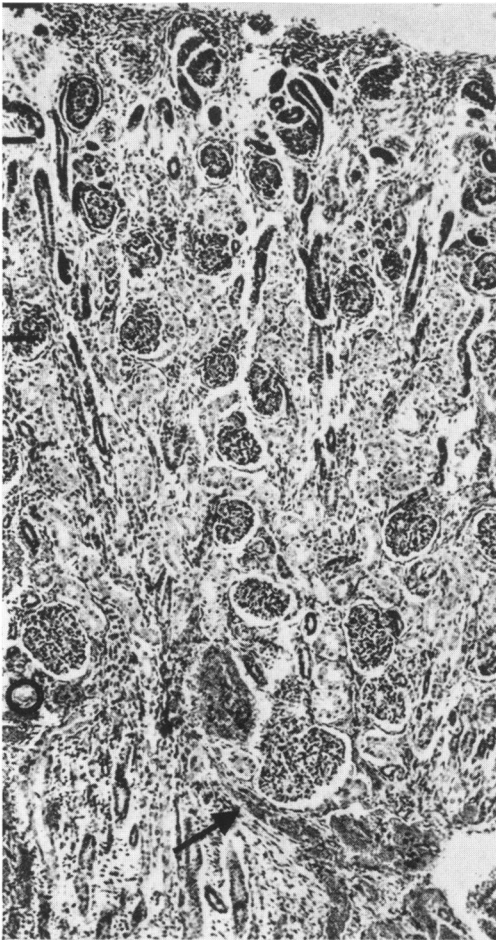
1A



1B



2A



2B

