

## AMYLOIDOSIS OF THE ISLETS OF LANGERHANS

### A RESTUDY OF ISLET HYALIN IN DIABETIC AND NONDIABETIC INDIVIDUALS

JOSEPH C. EHRlich, M.D., AND IRVING M. RATNER, M.D.

*From the Department of Laboratories, Lebanon Hospital, New York, N.Y.*

Hyalinosis of the islets of Langerhans in diabetes mellitus was reported for the first time by Opie in 1901.<sup>1a,1b</sup> He interpreted it as a degenerative change related to the pathologic physiology of the islets in this disease.<sup>1b</sup> This hypothesis was soon challenged by Ohlmacher,<sup>2</sup> Cecil,<sup>3</sup> and later Wright<sup>4</sup> and others, who reported the occurrence of hyaline deposits in the islets of nondiabetic patients. In these reports, the absence of diabetes was a presumption unsupported by glucose tolerance tests. Recent studies by Bell<sup>5</sup> disclosed a ratio of incidence of hyaline islets in patients with diabetes to those without it of 3 to 18:1 (depending on age groups). He re-affirmed the relationship of this islet change to diabetes mellitus and suggested that nondiabetic individuals presenting this alteration might represent instances of potential or unrecognized diabetes mellitus.

There have been several studies attempting to define the nature of the hyaline substance. Opie<sup>1b</sup> was struck by its histologic resemblance to amyloid but could not confirm this with amyloid stains. Mallory<sup>6</sup> thought that the deposit was closely related to amyloid. Warren and LeCompte,<sup>7</sup> at Mallory's suggestion, used methyl violet and iodine green and obtained positive stains in 14 of 51 cases of diabetes mellitus with hyaline islets. Gomori<sup>8</sup> stated that amyloidosis of the islets of Langerhans occurred occasionally in diabetes. Ahronheim<sup>9</sup> demonstrated metachromasia with gentian violet in all of his cases with hyaline islets (67 with diabetes and 5 without this disorder). Arey<sup>10</sup> demonstrated positive methyl violet staining for amyloid in all of 42 cases with and without diabetes, showing prominent hyalin in the islets of Langerhans. These investigators did not report results with Congo red. Warren and LeCompte,<sup>7</sup> Bell,<sup>11</sup> and Hartroft,<sup>12</sup> as well as standard works in pathology, continue to refer to the islet material as hyalin.

We have undertaken to restudy the nature of the hyaline material by the use of more elaborate histologic techniques than previously employed.

This investigation was supported by a research grant from Mr. Robert H. Arnow.

Presented before the Section on Pathology, 154th Meeting of the Medical Society of the State of New York, New York City, May 11, 1960.

Accepted for publication, July 12, 1960.

## MATERIAL AND METHODS

Sections of head, body and tail of the pancreas were taken as soon after the start of a necropsy as possible. These were immediately fixed in Kaiserling I. In selected cases, specimens were also fixed in Bouin's solution and formol-calcium.

Sections of pancreas from 91 cases of diabetes mellitus over the age of 50 were examined. As controls, sections of pancreas from 178 patients over the age of 60 years and not known to have diabetes mellitus were also investigated.

Sections (paraffin, unless otherwise specified) were stained with hematoxylin and eosin, Gomori's trichrome, Goldner's phosphotungstic acid hematoxylin (PTAH), silver (author's—JCE—modification of Bielschowsky's method), von Kossa, Sudan IV (frozen sections), toluidine blue, Alcian blue, Congo red (paraffin and frozen sections), crystal violet, and iodine green. Representative sections were examined in polarized light before and after staining with crystal violet, Congo red, and others. The crystal violet and Congo red stains were prepared in all our cases of islet hyalinosis; the remaining techniques were carried out in instances selected for excellence of preservation and fixation.

As controls for amyloid, sections of atrium, kidney, and spleen from cases of generalized secondary amyloidosis were examined, using all of the stains and histologic techniques listed above. Additional control tissue was obtained from cases of primary systemic amyloidosis, senile cardiac amyloidosis, and localized cutaneous amyloidosis in skin tumors.

Sections of left atrium from 20 cases which showed hyalin in the islets of Langerhans were stained with Congo red and examined for the presence of amyloid.

## RESULTS

Hyaline material was found in the islets of Langerhans in 45 of the 91 cases of diabetes mellitus examined. It was also encountered in the pancreatic sections from 7 of 178 patients not known to be diabetic (Table I). In the latter group, there were 3 patients in whom the existence of diabetes mellitus was presumed on the basis of single blood sugar determinations and family history. As recorded in Table II, all hyaline deposits in islets exhibited crystal violet metachromasia and Congo red binding (Fig. 3); positive birefringence and dichroism in polarized light were observed after staining with Congo red (Fig. 4). This phenomenon was not observed in unstained tissue or after the use of stains other than Congo red. The homogeneous islet substance showed positive staining with Alcian blue and the periodic acid-Schiff (PAS) stain; it was negative with toluidine blue.

Examination of Table II shows that the islet deposit and amyloid controls reacted in identical fashion with the techniques employed. The only exception was a negative reaction with the Alcian blue stain on secondary amyloid. Amyloid was not demonstrated in the atrial walls or kidneys of any of the cases examined. The incidence of diabetic glomerulosclerosis in the 45 patients with diabetes who showed hyalinized islets was approximately the same as in the remaining 46 cases of diabetes without hyalinized islets. The hyaline material was found (as

previously described) between capillary walls and islet cells (Fig. 1). With silver stains, the relationship of the hyalin to argyrophilic fibers was as follows: (1) Occasionally it lay between capillary endothelium and argyrophilic fibers. (2) Occasionally it appeared between argyrophilic fibers and islet cells. (3) In some instances it was noted to be within the argyrophilic network, spreading apart individual fibers or groups of fibers and occupying the interstices of the distended network (Fig. 2).

TABLE I  
HYALINOSIS OF ISLETS OF LANGERHANS.  
NECROPSY INCIDENCE

	Diabetic patients over age 50	Nondiabetic patients over age 60
Total number of cases	91*	178
Number of cases with hyalinosis of islets	45† (49.5%)	7 (3.9%)

\* Excludes 4 cases of juvenile diabetes, 1 case of hemochromatosis, and 1 case of diabetes associated with carcinoma of the body of the pancreas.

† Two cases show partial involvement of a single islet.

TABLE II  
HYALINOSIS OF ISLETS OF LANGERHANS.  
STAINS FOR AMYLOID

Stain	Islet hyalinosis				Amyloid controls			
	Diabetes mellitus (45 cases)		"Nondiabetic" (7 cases)		Secondary	Primary	Senile cardiac	Local cutaneous
	No. pos.	No. neg.	No. pos.	No. neg.				
Metachromasia with crystal violet	45	0	7	0	+	+	+	+
Congo red	45	0	7	0	+	+	+	+
Dichroic birefringence after staining with Congo red		+		+	+	+	+	+
Periodic acid-Schiff	Mod. +		Mod. +		Mod. +	Mod. +	Mod. +	Mod. +
Toluidine blue		-		-	-	-	-	-
Alcian blue		+		+	-	+	+	+

There was no predilection of the hyalin for any part of the pancreas (head, body or tail) except insofar as there were more islets present in the tail region.<sup>13</sup> The deposit was found with equal frequency in intra-lobular and periductal islets of Langerhans. In 3 cases (2 diabetic, 1 nondiabetic) the hyaline material was observed to contain pale bluish granules (Fig. 3) when stained with hematoxylin and eosin. The von Kossa reaction confirmed the calcific nature of these granules.

## DISCUSSION

The results of this study lead to the inevitable conclusion that the hyaline material in the islets of Langerhans is amyloid.

Amyloid is a hyaline substance which stains metachromatically with the rosaniline group of dyes and which binds Congo red. It is known to consist chiefly of protein plus a small carbohydrate component which includes acid mucopolysaccharide.<sup>14</sup> The mucopolysaccharide fraction is responsible for the metachromasia with rosaniline dyes as well as the staining with Alcian blue and PAS.<sup>15-17</sup> Arey<sup>10</sup> and Ahronheim<sup>9</sup> also found metachromasia with the rosaniline dyes in all their cases of islet hyalinosis. These investigators did not report results with Congo red. Congo red staining was noted by Bloom<sup>18</sup> in hyalinized islets in a cat with spontaneous diabetes mellitus, and more recently Seifert<sup>19</sup> reported positive Congo red stain of islet hyalin in human diabetes. Seifert did not mention the number of cases studied or the percentage with Congo red positivity. He concluded that the islet material was predominantly an acid mucopolysaccharide and, therefore, not an amyloid. This conclusion was based on the staining reaction with Alcian blue and astral blue. There is no evidence, however, that positive staining with Alcian blue necessarily indicates a predominance of acid mucopolysaccharide in the substance stained. Amyloid, which is known to consist chiefly of protein, reacts in positive manner to Alcian blue (senile, primary and cutaneous types<sup>17</sup>). The islet hyalin in our cases stained with Alcian blue. We interpreted this to mean only that an acid mucopolysaccharide fraction was present. Rinehart, Toreson and Abul-Haj<sup>20</sup> established the presence of acid mucopolysaccharide in islet hyalin by the use of a colloidal iron preparation. The demonstration of carbohydrate in islet material by these methods is consistent with the general histochemical behavior of amyloid.

The basis for Congo red binding has not, to our knowledge, been explained. Unstained amyloid may show very weak birefringence<sup>21</sup> in discontinuous fashion, probably depending upon fortuitous arrangement of amyloid fibrils in parallel bundles. After Congo red staining, anisotropism is exaggerated<sup>15,21-23</sup> and readily observed with ordinary polarizing filters (Figs. 3 and 4). Birefringence of amyloid has also been noted after staining with chlorantin fast red and with Evans blue.<sup>15</sup> The birefringence in polarized light after Congo red staining is dichroic,<sup>15,22,23</sup> i.e., two different colors appear in the polarized field. Amyloid bands are green in one plane and yellow-pink in the other. Rotation of the specimen through an angle of 90° reverses the colors. This phenomenon has been attributed to parallel orientation of dye

molecules along fibers and has been described by Pearse as characteristic, but not specific, for amyloid.<sup>15</sup> It has also been observed, for example, in cellulose fibers dyed with Congo red.<sup>15</sup> The fibrillar nature of amyloid has been demonstrated by electron microscopic studies of experimental as well as human amyloid.<sup>24-26</sup> In a recent study of experimental amyloid in the mouse, Gueft and Ghidoni<sup>26</sup> showed that the fibers exhibited characteristic periodicity. It is not yet known if this periodicity is the same in amyloid substances in other animals or in human subjects.

As noted in Table II, the hyaline deposits in islets in our cases also exhibited dichroic birefringence after staining with Congo red; this has not been reported previously. Study of the fine structure of islet amyloid is subject to the practical difficulty of obtaining suitably fixed human specimens.

Calcium deposition in islet hyalin (Fig. 3) has been reported to be rare.<sup>7</sup> However, it occurred in approximately 6 per cent of our cases (3 of 45). Calcification of primary and secondary amyloid is not rare.<sup>27</sup>

The presence of amyloid in the islets of Langerhans in this series was not accompanied by amyloid deposits in any of the other organs examined. The blood vessels of the pancreas did not contain this substance, and none was found in sections of the left atrium and kidney when examined by special stains.\* The pancreas does not often participate in systemic amyloidosis; when present, amyloid deposits are generally restricted to the walls of small blood vessels.<sup>29</sup> Islet involvement in generalized primary or secondary amyloidosis is uncommon; Ahronheim<sup>9</sup> found small amyloid deposits in islets in 2 of 11 cases with systemic amyloidosis. Dahlin<sup>30</sup> reported slight involvement of islet capillaries in 3 of 30 cases of secondary amyloidosis. Buerger and Braunstein, in a recent report of so-called senile cardiac amyloid, found deposits in the islets in 7 of their 33 cases.<sup>31</sup> However, their material was not studied from the standpoint of the incidence of diabetes mellitus.<sup>32</sup> We were unable to demonstrate amyloid in sections of the left atrium in 20 of our cases with amyloidosis of the islets of Langerhans.

Therefore, amyloid in the islets of Langerhans constitutes a form of localized amyloidosis. Localized amyloid without systemic deposition is known to occur in the stroma of certain cutaneous lesions,<sup>33,34</sup> particularly basal cell papilloma and basal cell epithelioma. Other reported

\* According to Fahr,<sup>28</sup> the lesions of diabetic glomerulosclerosis may give a weakly positive reaction with Congo red. We have obtained slight reddish-brown staining of these lesions with Congo red after prolonged staining. However, with normal staining time, adequate to produce deep staining of islet and other amyloids, the renal lesions were negative. Furthermore, renal lesions faintly stained after prolonged immersion in Congo red were not birefringent or dichroic in polarized light.

sites of localized amyloidosis include the respiratory tract, genitourinary tract, bone and other organs.<sup>35,36</sup> Some of these may represent regional deposits in unrecognized systemic disease.<sup>35</sup>

There was no statistical correlation between the degree of sclerosis of pancreatic arteries and arterioles and the occurrence of islet amyloid. We encountered instances with very marked pancreatic arteriolosclerosis without amyloid in the islets and, on the other hand, very striking islet amyloidosis in pancreases with minimal arterio- and arteriolosclerosis. These observations are in agreement with those of Bell<sup>11</sup> and differ from those reported by Moschcowitz.<sup>37</sup> Similarly, there was no statistical correlation between islet amyloidosis and diabetic glomerulosclerosis in our series; this confirms previous reports.<sup>11,38</sup>

Our data regarding the incidence of amyloidosis of the islets of Langerhans in diabetic patients as compared with those not known to be diabetic are in essential agreement with those of Bell.<sup>5</sup> It should be emphasized that in none of our cases with amyloidosis of the islets in patients apparently free of diabetes had diabetes mellitus been ruled out by glucose tolerance tests. Islet amyloid is associated principally with the diabetes of maturity.<sup>11</sup> It is rare in juvenile diabetes<sup>7,11</sup> and is apparently absent in the diabetes of hemochromatosis.<sup>39</sup>

The pathogenesis of localized amyloid is not known. Abnormalities in the protein composition of blood serum, such as are known to be associated with systemic amyloidosis, have not been demonstrated in the circumscribed form, nor can anything be stated at present concerning the possibility of local disturbance in the protein milieu of the affected area. There seems little doubt that amyloidosis of the islets of Langerhans is in some way related to the diabetic state and does not simply represent a form of age change in an endocrine organ. Rinehart, Toreson and Abul-Haj<sup>20</sup> suggested that the hyalin might constitute a barrier to the release of insulin. It is also possible that it may be a consequence of some alteration in islet function. Nevertheless, the clearly established statistical relationship of diabetes mellitus and amyloid deposits in the islets of Langerhans points to the need for additional investigation of a possible pathogenetic linkage.

#### SUMMARY

1. Hyalinization of the islets of Langerhans was found in 45 of a series of 91 consecutive necropsies in diabetic individuals over 50 years of age (49.5 per cent) and in 7 of 178 consecutive necropsies in individuals over 60 years of age not known to be diabetic (3.9 per cent).
2. Metachromasia with crystal violet and binding of Congo red were found in each instance of hyalinized islets. The Congo red-stained de-

posit exhibited dichroic birefringence in polarized light. These results, together with the general staining profile, permitted the identification of the hyaline substance as amyloid. Amyloid could not be identified in diabetic renal or vascular lesions.

3. Amyloidosis of the islets is a form of localized amyloid and occurs in approximately 50 per cent of diabetic patients over the age of 50 years.

#### REFERENCES

1. OPIE, E. L. (a) On the relation of chronic interstitial pancreatitis to the islands of Langerhans and to diabetes mellitus. *J. Exper. Med.*, 1900-1901, 5, 397-428. (b) The relation of diabetes mellitus to lesions of the pancreas; hyaline degeneration of the islets of Langerhans. *J. Exper. Med.*, 1900-1901, 5, 527-540.
2. OHLMACHER, J. C. The relation of the islands of Langerhans to diseases of the liver with special reference to carbohydrate metabolism. *Am. J. M. Sc.*, 1904, 128, 287-307.
3. CECIL, R. L. Hyaline degeneration of the islands of Langerhans in non-diabetic conditions. *Am. J. M. Sc.*, 1914, 147, 726-735.
4. WRIGHT, A. W. Hyaline degeneration of the islands of Langerhans in non-diabetics. *Am. J. Path.*, 1927, 3, 461-482.
5. BELL, E. T. Hyalinization of the islets of Langerhans in nondiabetic individuals. *Am. J. Path.*, 1959, 35, 801-805.
6. MALLORY, F. B. *The Principles of Pathologic Histology*. W. B. Saunders Co., Philadelphia, 1914, p. 521.
7. WARREN, S., and LeCOMPTE, P. M. *The Pathology of Diabetes Mellitus*. Lea & Febiger, Philadelphia, 1952, ed. 3, 336 pp.
8. GOMORI, G. Pathology of the pancreatic islets. *Arch. Path.*, 1943, 36, 217-232.
9. AHRONHEIM, J. H. The nature of the hyaline material in the pancreatic islands in diabetes mellitus. *Am. J. Path.*, 1943, 19, 873-882.
10. AREY, J. B. Nature of the hyaline changes in islands of Langerhans in diabetes mellitus. *Arch. Path.*, 1943, 36, 32-38.
11. BELL, E. T. Hyalinization of the islets of Langerhans in diabetes mellitus. *Diabetes*, 1952, 1, 341-344.
12. HARTROFT, W. S. Islet pathology in diabetes. *Diabetes*, 1956, 5, 98-104.
13. MACLEAN, N., and OGILVIE, R. F. Quantitative estimation of the pancreatic islet tissue in diabetic subjects. *Diabetes*, 1955, 4, 367-376.
14. CALKINS, E., and COHEN, A. S. Chemical composition of amyloid. (Abstract) *J. Clin. Invest.*, 1958, 37, 882-883.
15. PEARSE, A. G. E. *Histochemistry, Theoretical and Applied*. Little, Brown & Co., Boston, 1959, ed. 2, pp. 281-287.
16. WINDRUM, G. M., and KRAMER, H. Some observations on the histochemical reactions of amyloid. *A.M.A. Arch. Path.*, 1957, 63, 373-378.
17. BRAUNSTEIN, H., and BUERGER, L. A study of the histochemical and staining characteristics of amyloid. *Am. J. Path.*, 1959, 35, 791-800.
18. BLOOM, F. Diabetes mellitus in a cat. *New England J. Med.*, 1937, 217, 395-398.
19. SEIFERT, G. Die pathologische Morphologie der Langerhansschen Inseln besonders beim Diabetes mellitus des Menschen. *Verhandl. deutsch. Ges. Path.* (42nd Congress, April 22-26, Vienna, 1958), 1959, 18, 50-84.

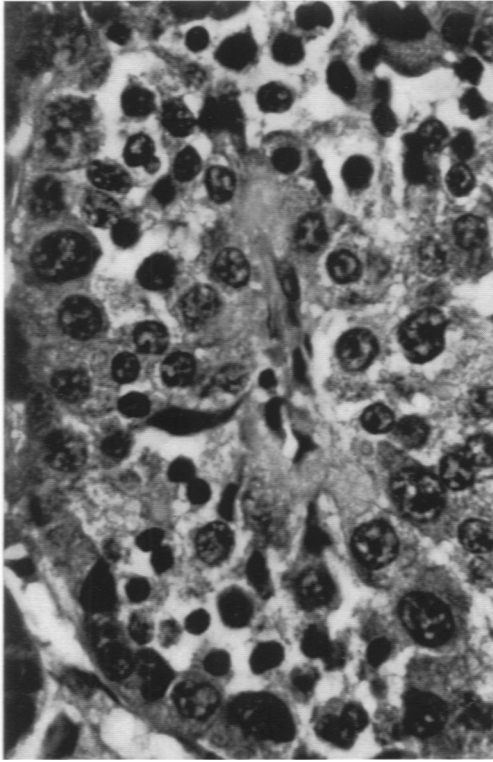
20. RINEHART, J. F.; TORESON, W. E., and ABUL-HAJ, S. K. Histochemical studies of the hyaline islets of diabetes. (Abstract) *Am. J. Med.*, 1954, 17, 124.
21. COHEN, A. S.; CALKINS, E., and LEVENE, C. I. Studies on experimental amyloidosis. I. Analysis of histology and staining reactions of casein-induced amyloidosis in the rabbit. *Am. J. Path.*, 1959, 35, 971-989.
22. PFEIFFER, H. A. Messungen der Doppelbrechung ( $\Delta n$ ) und des Dichroismus ( $\Delta k$ ) am Amyloid in Kulturen *in vitro*. *Exper. Cell Res.*, 1953, 4, 181-187.
23. LADEWIG, P. Double refraction of the amyloid-Congo red complex. *Compt. rend. et arch. soc. turq. sci. phys. et nat.*, 1945, 12, 183-184.
24. SPIRO, D. The structural basis of proteinuria in man. Electron microscopic studies of renal biopsy specimens from patients with lipid nephrosis, amyloidosis, and subacute and chronic glomerulonephritis. *Am. J. Path.*, 1959, 35, 47-73.
25. COHEN, A. S., and CALKINS, E. Electron microscopic observations on a fibrous component in amyloid of diverse origins. *Nature, London*, 1959, 183, 1202-1203.
26. GUEFT, B., and GHIDONI, J. The site of formation and ultrastructure of amyloid. (Abstract) Program of the Fifty-seventh Annual Meeting, American Association of Pathologists and Bacteriologists, Memphis, Tenn., April 28-30, 1960, pp. 18-19.
27. SYMMERS, W. St. C. Primary amyloidosis: a review. *J. Clin. Path.*, 1956, 9, 187-211.
28. FAHR, T. Über Glomerulosklerose. *Virchows Arch. path. Anat.*, 1942, 309, 16-33.
29. GRUBER, G. B. Pathologie der Bauchspeicheldrüse (mit Ausnahme der Langerhansschen Inseln und der Diabetesfrage). III. Kreislaufstörungen. In: *Handbuch der speziellen pathologischen Anatomie und Histologie*. Vol. 5, Verdauungsdrüsen, part 2, Kopfspeicheldrüsen, Bauchspeicheldrüse, Gallenblase und Gallewege. Henke, F., and Lubarsch, O. (eds.) Springer, Berlin, 1929, p. 308.
30. DAHLIN, D. C. Secondary amyloidosis. *Ann. Int. Med.*, 1949, 31, 105-119.
31. BUERGER, L., and BRAUNSTEIN, H. Senile cardiac amyloidosis. *Am. J. Med.*, 1960, 28, 357-367.
32. BRAUNSTEIN, H. Personal communication, 1960.
33. FREUDENTHAL, W. Amyloid in der Haut. *Arch. Dermat. u. Syph.*, 1930, 162, 40-94.
34. SANNICANDRO, G. La degenerazione amiloide della cute. *Gior. ital. dermat. e sif.*, 1933, 74, 1499-1534.
35. WOLF, R. L.; HITZIG, W. M., and OTANI, S. Amyloidosis unassociated with a predisposing disease. *A.M.A. Arch. Int. Med.*, 1955, 95, 141-152.
36. GOLTZ, R. W. Systematized amyloidosis; a review of skin and mucous membrane lesions and a report of 2 cases. *Medicine*, 1952, 31, 381-409.
37. MOSCHCOWITZ, E. The pathogenesis of the hyalinization of the islands of Langerhans. *A.M.A. Arch. Path.*, 1956, 61, 136-142.
38. ALLEN, A. C. So-called intercapillary glomerulosclerosis—a lesion associated with diabetes mellitus. *Arch. Path.*, 1941, 32, 33-51.
39. BELL, E. T. The relation of portal cirrhosis to hemochromatosis and to diabetes mellitus. *Diabetes*, 1955, 4, 435-446.



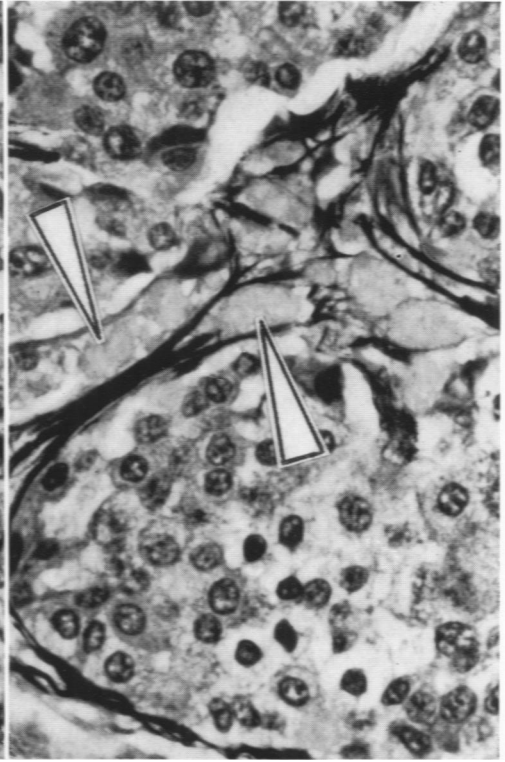
[ *Illustrations follow* ]

## LEGENDS FOR FIGURES

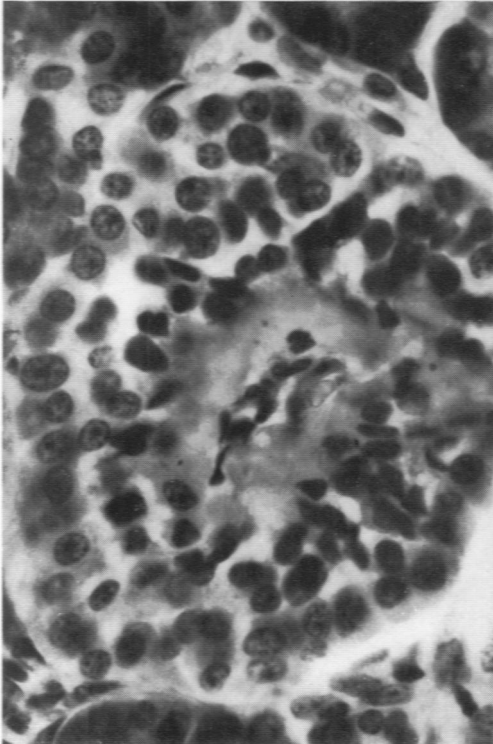
- FIG. 1. Portion of an islet of Langerhans. Typical appearance of early or slight "hyaline" change. A pericapillary deposit of homogeneous material is located between the wall of a centrally located capillary and the islet cells. Hematoxylin and eosin stain.  $\times 650$ .
- FIG. 2. Portion of an islet of Langerhans. The islet capillary is at the upper right. Homogeneous deposits appear in the interstices of an argyrophilic fiber network (arrows). Silver and hematoxylin stain.  $\times 650$ .
- FIG. 3. Islet of Langerhans. The centrally located islet capillary is surrounded by a collar of homogeneous, strongly orange-red staining material. A few calcific particles are visible in the hyalin. Frozen section stained with Congo red-hematoxylin.  $\times 650$ .
- FIG. 4. The islet shown in Figure 3, viewed with polarized light. One strong and several weak anisotropic bands appear in the homogeneous deposit. Birefringence was dichroic; the bright band, for example, was green in one plane and yellow-pink after rotation through an angle of  $90^\circ$ . Anisotropism could not be demonstrated in this deposit prior to Congo red staining.  $\times 650$ .



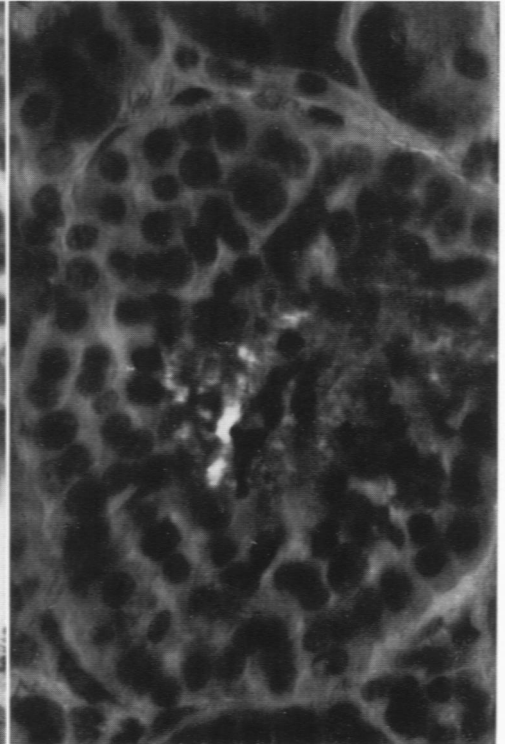
1



2



3



4