

THE AMERICAN JOURNAL OF PATHOLOGY

VOLUME XXXII

JANUARY-FEBRUARY, 1956

NUMBER 1

PNEUMOCYSTIS INFECTION AND CYTOMEGALY OF THE LUNGS IN THE NEWBORN AND ADULT *

H. HAMPERL

Director of the Institute of Pathology, Bonn University, Bonn, Germany

Knowledge of pneumocystis pneumonitis has developed far more rapidly in Europe than in the United States or elsewhere in the world. It appears timely, therefore, to present the current concepts of this condition and to include a discussion of the possible relation of this infection to pulmonary cytomegaly.

Plasmacellular Interstitial Pneumonitis (Pneumocystis Pneumonitis) of the Newborn

In recent years there has been seen in central Europe a peculiar type of infantile pneumonitis which apparently does not occur in the United States. General attention was directed toward this disease when Ammich¹ in Berlin (1938) and Benecke² in Rostock (1939) reported a considerable number of such cases.

The disease scarcely ever occurs before the 6th week of age or after the 6th month,³ and is evident most frequently between the 10th and 14th weeks. It appears primarily in premature or in mature dystrophic infants, in hospitals and nurseries. The incubation period is about 6 weeks.⁴ Today the clinical and roentgenologic diagnosis is quite simple.⁵ The mortality lies between 30 and 40 per cent. In adults a similar disease has been seen only twice: a 60-year-old female with Hodgkin's disease (Vaněk⁶), and a 48-year-old male with myeloid leukemia (Jírovec and Vaněk⁷).

At necropsy there can be seen an almost homogeneous gray-white consolidation of all lobes of the lungs. Histologically (Fig. 1), there is extensive plasmacytic infiltration of the alveolar septa (interstitial plasmacytic pneumonitis). The alveolar lumina contain either edematous fluid or a peculiar foamy material. There is almost no fibrinous exudate.

The etiology of the disease was unknown until van der Meer and

* Received for publication, June 10, 1955.

Brug,⁸ Vaněk and Jírovec,⁹ and Giese¹⁰ recognized the foamy material in the alveolar lumina as parasites. Vaněk and Jírovec, together with most of the other authors, believed the parasites to be *Pneumocystis carinii*, a protozoan. They spoke of pneumocystis pneumonitis. The term *Pneumocystis carinii* had been coined by the Delanoës¹¹ to designate a parasite previously described by Carini.¹² Giese, on the other hand, considered the parasites to be yeasts and the foamy structures ascispores and ascospores. Recently it has been said¹³ that it is possible to culture the parasite and to identify it as belonging to the Endomycetes of the genus *Saccharomyces*.¹⁴⁻¹⁶ The fact that therapy has not been successful with the drugs employed against protozoa but with those against fungi could be interpreted in favor of Giese's opinion. The question of the nature of the parasites, therefore, cannot be considered as completely settled, although pneumocystis is most likely to be the agent.¹⁷ Some authors,¹³⁻¹⁶ by inoculating the parasites into newborn mice and cats, succeeded in producing a disease similar to that seen in humans. As the parasite can be found also in every case of this disease in humans, Koch's postulates would be fulfilled. One can thus regard the parasite as the causative organism of interstitial plasmacytic pneumonitis.

The parasites can be found in smears from the lung, in bronchial secretions, and in histologic slides. They most often form large conglomerates, but occasionally lie singly in edematous alveoli¹⁸ bordering an area of pneumonic infiltration. One can assume, therefore, that they occupy an alveolar lumen first as single individuals and then multiply, using up the edematous fluid, until they completely fill the alveolus¹⁸ (Fig. 2). The plasmacytic infiltration of the alveolar septa seems to appear at the same time. Using special stains, one can even see single phagocytized parasites in alveolar septa^{18,19} (Fig. 3). They have been reported in one case in organs other than the lung.²⁰ *Pneumocystis* has been found in rodents, rabbits, dogs, and sheep.^{7,21,22}

In the honeycombed conglomerates within the alveolar lumina some isolated, light-refracting "cysts" may be seen.²³ Both conglomerates and cysts contain large amounts of acid mucoproteins and stain intensely with the periodic acid-Schiff (PAS) stain.¹⁸ They can be impregnated with Levaditi's silver method²³ and stain metachromatically with toluidin blue.²⁴ The cysts (sporogonia), furthermore, take Gridley's²⁵ and Weigert's stains. They include one, two, four, or eight Feulgen-positive clumps, which are the spores. Occasionally the disintegrating parasites form a granular, intensely eosinophilic material in the center of a conglomerate.

There is a remarkable frequency of combination of cytomegalic dis-

ease and interstitial plasmacytic pneumonitis.²⁶⁻²⁸ In a non-selected group of 200 infants, cytomegalic disease of salivary glands was diagnosed 25 times; all of these infants except 2 had an interstitial pneumonitis at the same time.²⁷ It seemed worth while, therefore, to consider the possibility that pneumocystis pneumonitis may occur also in adults with cytomegalic disease much more frequently than is suspected.

Cytomegaly in the Lungs of Adults

There is no doubt that cytomegaly of the lungs in adults does occur without pneumocystis pneumonitis. I myself have seen such a case in a 32-year-old male, who died of a sarcomatous type of Hodgkin's disease, mainly localized in the lungs and combined with severe cachexia. Bordering an area of pulmonary infiltration, there were numerous cytomegalic alveolar cells (Fig. 4) which were not present in other areas of the lung or in other organs. The lumina surrounded by the cytomegalic cells were empty (Fig. 5); accordingly, there was no "cytomegalic pneumonitis."

It is remarkable that there was a neoplastic disease of the hematopoietic system also in 2 other cases of cytomegalic pulmonary disease in adults (Wyatt *et al.*,²⁹ Reinhard *et al.*³⁰). All 3 patients were severely emaciated; thus it is probable that the presence of cytomegaly in the lungs is purely accidental and a final phenomenon, as pointed out by Ackerman in Reinhard's case.

In another similar case described by Von Glahn and Pappenheimer,³¹ the cytomegaly was combined with pneumonitis, but I am unable to say whether the authors considered the cytomegaly to be related to the cause of the pneumonitis.

Cytomegaly and Pneumocystis Infection in the Lungs of Adults

In 1952, Vaněk⁶ reported a case of pneumocystis in a 60-year-old female with cytomegaly of the lung. In the American literature there have been reported 3 cases of cytomegalic inclusion pneumonitis in adults (McMillan,³² Wyatt *et al.*³³). As some of the photomicrographs appeared to me to be suggestive of pneumocystis infection, I asked Dr. McMillan to send me several unstained slides of his case, which he was kind enough to do. The patient was a 60-year-old Japanese female who died in Montreal in 1945. I can add nothing to Dr. McMillan's excellent case history and anatomical report and should like only to stress that, as in the infantile interstitial plasmacytic pneumonitis, all lobes of the lung were consolidated and grayish white. Microscopically, McMillan (and also Wyatt and his co-workers in their 2 cases) found, apart from the cytomegalic cells, polymorphonu-

clear cells and bacteria (*Streptococcus viridans*) as well as an eosinophilic protein coagulum, but almost no fibrin in the alveoli.

These protein coagula most often lie in the center of the alveoli and are surrounded by a lighter staining border consisting of numerous round vesicles or honeycombs which can be seen under high power (Fig. 6). Both center and border stain intensely with the PAS technique (Fig. 7). With Masson's trichrome stain the vesicles are seen to contain very small granules. With Gridley's²⁵ (Fig. 8) and Weigert's (Fig. 9) stains one can easily recognize the cysts (sporogonia) of the parasites. I am convinced, therefore, that parasites were present in McMillan's case and that they are identical with those found in European infantile interstitial plasmacytic pneumonitis (viz., *Pneumocystis carinii*). I have not been able to recognize any regular connection between the appearance of cytomegalic alveolar epithelial cells and the previously described changes in the lung. The cytomegalic elements seem to be scattered more incidentally in the lung.

As far as the histologic picture is concerned, however, there are several significant differences between the condition in infants and these adult cases.

1. In the adults there are often very numerous polymorphonuclear cells in the alveoli, occasionally even occurring without parasites. In McMillan's³² case this seemed to be due to the simultaneous infection with streptococci, which could be found in great numbers in the alveoli. Sometimes one even has the impression that the clumps of parasites have been broken up and dissolved by the polymorphonuclear cells in the alveoli.

2. In McMillan's case³² the alveolar septa are only very sparsely infiltrated with polymorphonuclear cells and lymphocytes. At least one would not make the diagnosis of interstitial pneumonitis from this histologic picture.

3. Nevertheless, the septa in some areas are very much enlarged by a material resembling edematous fluid under low power. Under high power and with special stains it can be seen that this is a massive infiltration with parasites (Fig. 10). With elastic tissue stains a sparsity of the elastic framework of the alveolar septa is noticeable. Therefore, I suppose that the infiltration with parasites leads to a breaking apart of the elastic tissue and finally to its destruction.

4. In some places emphysematous alveoli can be seen, bordered by hyaline membranes, as in the newborn (Fig. 11). Underneath the thin membranes in the alveoli, clumps of parasites again can be found.

I do not doubt that in both cases of Wyatt and co-workers³³ the

parasites could be found in addition to the cytomegalic cells. These authors themselves identified their cases with that of McMillan³² and I, too, find in their description the same characteristic features: protein coagula in alveoli and bronchi, sparsity of fibrin, and hyaline membranes. In addition, there can be recognized in their figures 5 and 6 the characteristic honeycomb cysts with granules. In contradistinction to the case of McMillan, there is found in both cases of Wyatt and co-workers a localized monocytic and lymphocytic, as well as plasmacytic, infiltration in the septa. The same is true also in Vaněk's⁶ case.

We can thus confirm that in 2 known adult cases the cytomegaly in the lung was accompanied by a pneumocystis infection (Vaněk's⁶ and McMillan's³² cases), while it seems highly probable that in the cases of Wyatt and co-workers³³ also such a pneumocystis infection was present.

Pneumocystis Infection in Adults

There may exist in adults, however, as in infants, a pneumocystis infection of the lung without cytomegaly. In both known cases—a 48-year-old male, who died of myeloid leukemia and lobar pneumonia (Jirovec and Vaněk⁷), and a 21-year-old male, cause of death unknown (van der Meer and Brug⁸)—pneumocystis infection was simply a secondary finding at necropsy.

DISCUSSION

There are in adults, clear pneumocystis infections of the lungs with pneumonitis, pneumocystis pneumonitis with cytomegaly, and cytomegaly without pneumocystis infection and without pneumonitis. With these facts in mind, we must ask ourselves whether we actually are right in speaking of cytomegalic inclusion pneumonitis and, consequently, in considering the cytomegalic virus responsible for these inflammatory changes in the lungs of adults. In McMillan's³² case, for instance, two other organisms, pneumocystis and streptococcus, were present in addition to the cytomegalic virus, so that in this respect the case is inconclusive. In Vaněk's⁶ case and most probably also in the 2 cases of Wyatt and co-workers³³ there was present, in addition to cytomegaly, a pneumocystis infection; this infection rather than the cytomegalic virus was quite probably responsible for the inflammatory changes. On the other hand, in my own case and in 2 cases from the literature, cytomegaly in the adult lung was present without pneumonitis. I find, therefore, no evidence that the cytomegalic virus alone is capable of causing pneumonitis in adults. It is

possible that the relationship is different in infants, but one must first eliminate the possibility that in cases of infantile pneumonitis with cytomegaly the inflammation may be caused by a different agent (bacteria?) than in adults.

Hitherto, I have believed that the parasites causing infantile interstitial plasmacytic pneumonitis have been confined to central Europe. Recently, however, cases have been reported in Scandinavia^{34,35} and Great Britain.³⁶ McMillan's³² case demonstrates that the parasite occurs also in North America, so we must consider the possibility also of an occasional fatal infection of this type in the newborn in North America.

SUMMARY

In the case of fatal inclusion-disease pneumonitis described by McMillan³² in 1947, the same parasite (*Pneumocystis carinii*) has been found as is known to cause an interstitial plasmacytic pneumonitis in the newborn in Europe. This pneumonitis in Europe is frequently combined also with cytomegalic disease. Accordingly, as this parasite occurs in North America, one must consider the possibility of an occasional infection of this type in the newborn of that region.

It seems doubtful that there is in adults a pneumonitis due to cytomegalic infection, since a simultaneous infection with these parasites most probably was present also in the other known cases of cytomegalic pneumonitis (Wyatt *et al.*³³).

REFERENCES

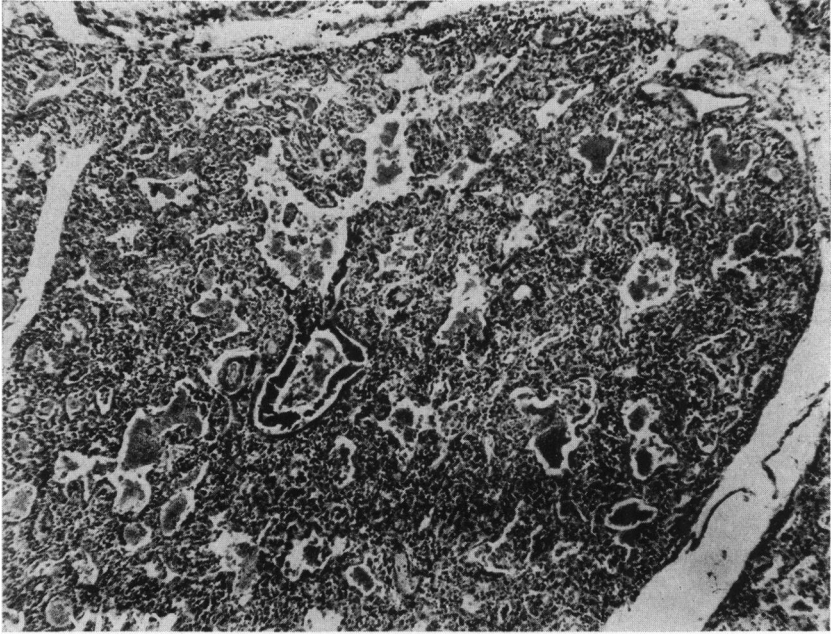
1. Ammich, O. Über die nichtsyphilitische interstitielle Pneumonie des ersten Kindesalters. *Virchows Arch. f. path. Anat.*, 1938, 302, 539-554.
2. Benecke, E. Eigenartige Bronchiolenerkrankung im ersten Lebensjahr. *Verhandl. d. deutsch. path. Gesellsch.*, 1939, 31, 402-406.
3. Bachmann, K. D. Bericht über 120 Fälle von frühkindlicher interstitieller Pneumonie. *Ztschr. f. Kinderh.*, 1954-55, 75, 119-131.
4. Bachmann, K. D. Zur Epidemiologie und Inkubation der frühkindlichen interstitiellen Pneumonie. *Ztschr. f. Kinderh.*, 1953-54, 74, 133-140.
5. Nitschke, A. Über die interstitielle (plasmazelluläre) Pneumonie der frühgeborenen und schwächlichen Kinder. *Ztschr. f. Kinderh.*, 1940-41, 62, 200-222.
6. Vaněk, J. Parazitární pneumonie z infekce *Pneumocystis Carinii* u 60leté Zeny. [Parasitic pneumonia due to *Pneumocystis carinii* infection in a woman 60 years old.] *Časop. lek. česk.*, 1952, 91, 1260-1262.
7. Jirovec, O., and Vaněk, J. Zur Morphologie der *Pneumocystis carinii* und zur Pathogenese der *Pneumocystis*-Pneumonie. *Zentralbl. f. allg. Path. u. path. Anat.*, 1954, 92, 424-437.
8. van der Meer, G., and Brug, S. L. Infection à *Pneumocystis* chez l'homme et chez les animaux. *Ann. Soc. belge de méd. trop.*, 1942, 22, 301-307.
9. Vaněk, J., and Jirovec, O. Parazitäre Pneumonie. "Interstitielle" Plasmazellen-pneumonie der Frühgeborenen, verursacht durch *Pneumocystis carinii*. *Zentralbl. f. Bakt.*, I Orig., 1952, 158, 120-127.

10. Giese, W. Pathogenese und Ätiologie der interstitiellen plasmazellulären Säuglingspneumonie. *Verhandl. d. deutsch. path. Gesellsch.*, 1953, 36, 284-289.
11. Delanoë, P., and Delanoë (Mme.). Sur le rapports des kystes de Carini du poumon des rats avec le Trypanosoma Lewisi. *Compt. rend. Acad. d. sc.*, 1912, 155, 658-660.
12. Carini, A. Formas de eschizogonia do Trypanozoma Lewisi. *Comm. a Soc. de Med. de Sao Paulo*, August 16, 1910.
13. Ladstätter, L. Kulturversuche bei interstitieller plasmacellulärer Pneumonie. *Klin. Wchnschr.*, 1954, 32, 1044-1046.
14. Brandstein, L., and Csillag, A. Experimental interstitial plasmacellular pneumonia. *Acta Morph. Acad. Scient. Hungaricae*, 1954, 4, 38-39.
15. Csillag, A., and Brandstein, L. The role of a Blastomyces species in the genesis of interstitial pneumonia of the premature infant; a preliminary report. *Acta Microbiol. Acad. Scient. Hungaricae*, 1954, 1, 525-529.
16. Csillag, A., and Brandstein, L. The role of a Blastomyces in the aetiology of interstitial plasmocytic pneumonia of the premature infant. *Acta Microbiol. Acad. Scient. Hungaricae*, 1954, 2, 179-190.
17. Jírovec, O. Über die durch Pneumocystis carinii verursachte interstitielle Pneumonie der Säuglinge. *Monatschr. f. Kinderh.*, 1954, 102, 476-485.
18. Hamperl, H. Zur Frage des Parasitennachweises bei der interstitiellen plasmocellulären Pneumonie. *Klin. Wchnschr.*, 1952, 30, 820-822.
19. Bruns, G. Zur Morphologie der Pneumocystis carinii. *Zentralbl. f. allg. Path. u. path. Anat.*, 1953-54, 91, 168-173.
20. Zandanell, E. Pneumozystisbefund ausserhalb der Lunge bei interstitieller plasmazellulärer Pneumonie der Säuglinge und Frühgeburten. *Zentralbl. f. allg. Path. u. path. Anat.*, 1954, 92, 74-80.
21. Carini, A., and Maciel, J. Ueber Pneumocystis carinii. *Centralbl. f. Bakteriol.*, 1916, 77, 46-50.
22. Sedlmeier, H., and Dahme, E. Pneumocystis carinii-Infektion beim Hund. *Zentralbl. f. allg. Path. u. path. Anat.*, 1955, 93, 150-155.
23. Pliess, G. Die Pneumocystis carinii und ihre Bedeutung bei der interstitiellen plasmacellulären Säuglingspneumonie. *Frankfurt. Ztschr. f. Path.*, 1953, 64, 185-208.
24. Bruns, G., and Böttger, D. Die Toluidinblau-Färbung der Pneumocystis carinii. *Acta histochem. (Jena)*, 1954, 1, 25-28.
25. Gridley, M. F. Laboratory Manual of Special Staining Technics. U. S. Armed Forces Institute of Pathology, Washington, D. C., 1953, pp. 188-189.
26. Dittrich, J. K., and Seifert, G. Zur Frage der Beziehungen zwischen Cytomegalie, interstitieller Pneumonie und Erythroblastose. *Ztschr. f. Kinderh.*, 1953, 73, 639-652.
27. Seifert, G. Weitere Untersuchungen zur Frage der Syntropie von interstitieller Pneumonie und Zytomegalie. *Zentralbl. f. allg. Path. u. path. Anat.*, 1953-54, 91, 445-450.
28. Seifert, G. Zur Pathologie der Cytomegalie. (Einschlusskörperchenkrankheit, Speicheldrüsenvirusenerkrankung.) *Virchows Arch. f. path. Anat.*, 1954, 325, 596-623.
29. Wyatt, J. P.; Hemsath, F. A., and Soash, M. D. Disseminated cytomegalic inclusion disease in an adult; with primary refractory anemia and transfusional siderosis; report of a case. *Am. J. Clin. Path.*, 1951, 21, 50-55.
30. Reinhard, E. H.; Good, J. T., and Martin, E. Chemotherapy of malignant neoplastic diseases. *J. A. M. A.*, 1950, 142, 383-389.

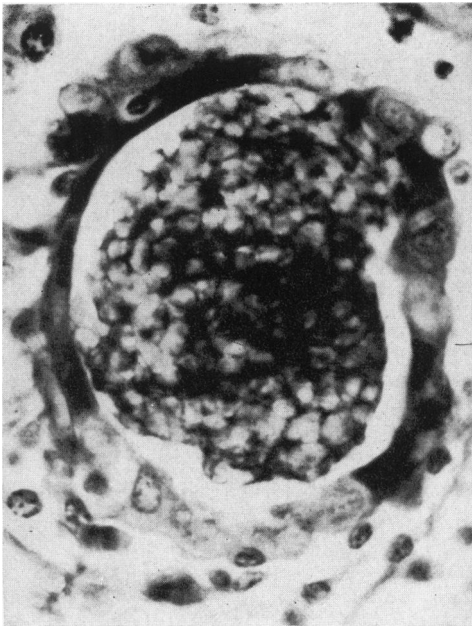
31. Von Glahn, W. C., and Pappenheimer, A. M. Intranuclear inclusions in visceral disease. *Am. J. Path.*, 1925, 1, 445-466.
 32. McMillan, G. C. Fatal inclusion-disease pneumonitis in an adult. *Am. J. Path.*, 1947, 23, 995-1003.
 33. Wyatt, J. P.; Simon, T.; Trumbull, M. L., and Evans, M. Cytomegalic inclusion pneumonitis in the adult. *Am. J. Clin. Path.*, 1953, 23, 353-362.
 34. Linell, F. Plasmacells pneumoni. *Nord. med.*, 1949, 41, 760-764.
 35. Gormsen, H. On interstitial plasma cell pneumonia in infants. *Acta paediat.*, 1950, 39, 291-314.
 36. Baar, H. S. Interstitial plasmacellular pneumonia due to *Pneumocystis carinii*. *J. Clin. Path.*, 1955, 8, 19-24.
-

LEGENDS FOR FIGURES

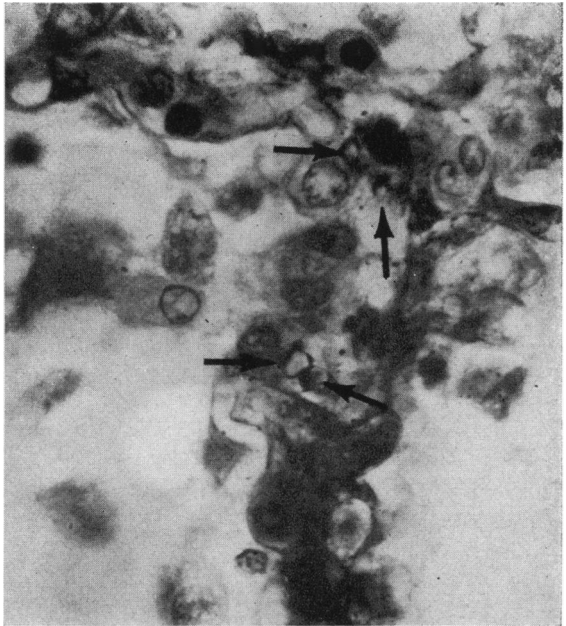
- FIG. 1. Interstitial plasmacytic pneumonitis of the newborn caused by *Pneumocystis carinii*. The alveoli are filled with apparently homogeneous material. Hematoxylin and eosin stain. $\times 50$.
- FIG. 2. *Pneumocystis* pneumonitis of the newborn. A bronchiole is filled with a conglomerate of parasites. Periodic acid-Schiff's (PAS) stain. $\times 700$.
- FIG. 3. *Pneumocystis* pneumonitis of the newborn. Parasites in the alveolar septa are indicated by arrows. PAS stain. $\times 900$.



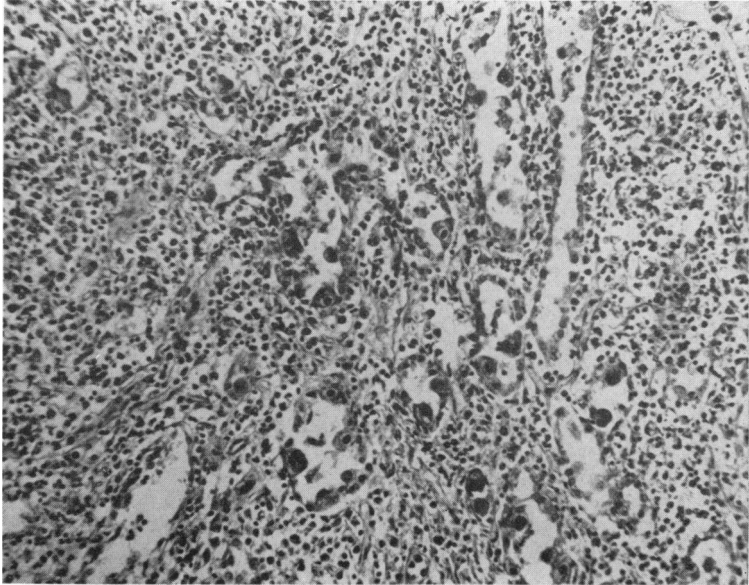
1



2



3



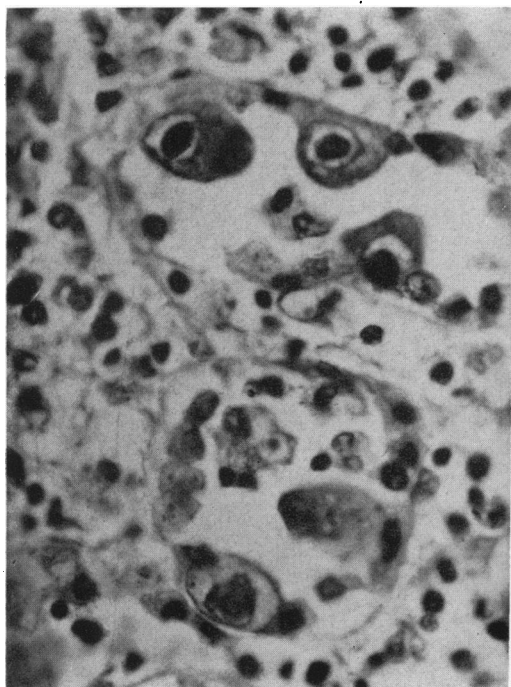
4

FIG. 4. Cytomegaly of the lung in an adult with Hodgkin's disease. Hematoxylin and eosin stain. $\times 150$.

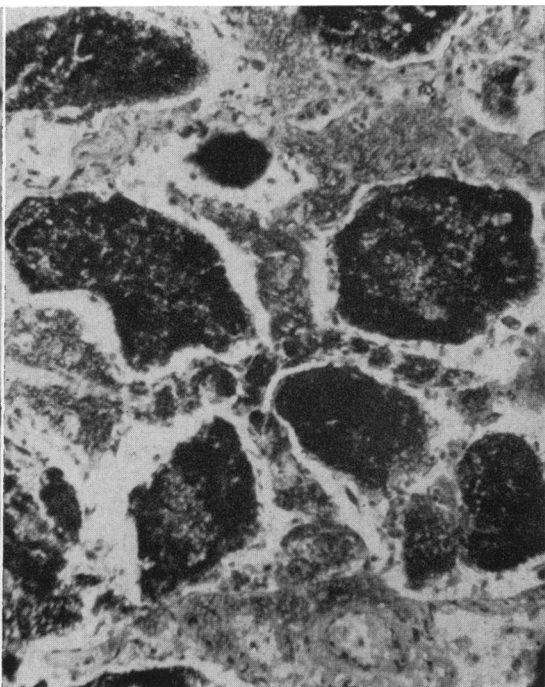
FIG. 5. From the same case as Figure 4. $\times 600$.

FIG. 6. McMillan's³² case. Two cytomegalic cells at the alveolar septum. The lumen of the alveolus is filled by a conglomerate of pneumocystis. Masson's trichrome stain. $\times 700$.

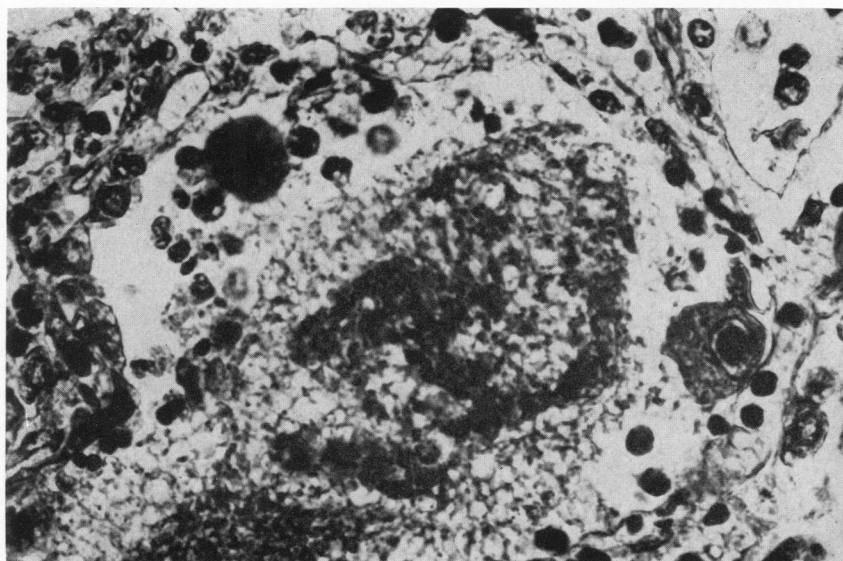
FIG. 7. McMillan's³² case. The conglomerates of pneumocystis in the alveoli are intensely stained with the PAS method. Enlargement of the alveolar septa may be noted. (See also Fig. 9.) $\times 170$.



5



7



6

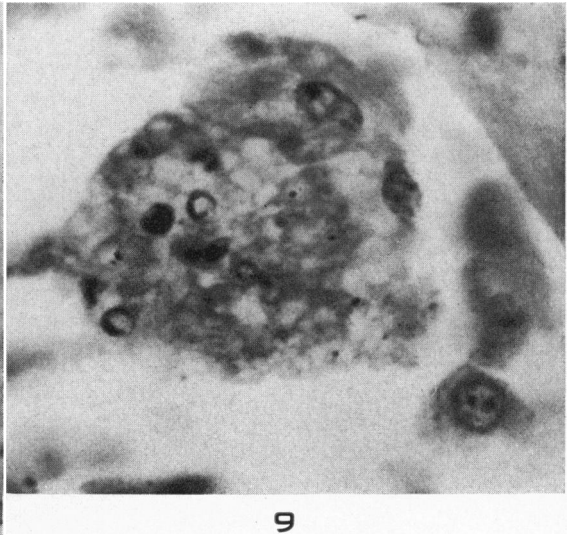
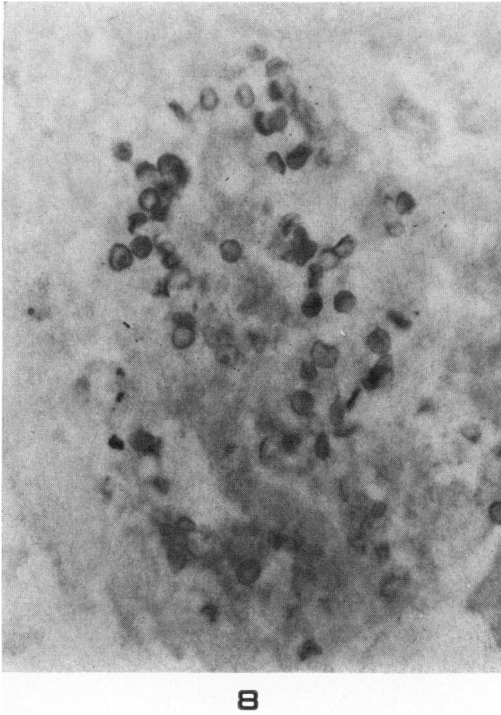
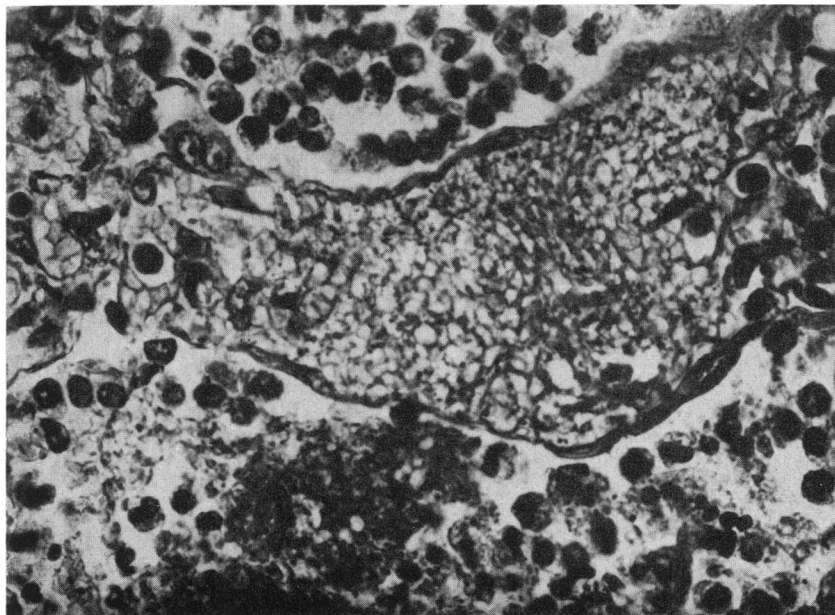


FIG. 8. McMillan's³² case. The cysts in a mass of pneumocystis are stained with Gridley's²⁵ fungus stain. $\times 800$.

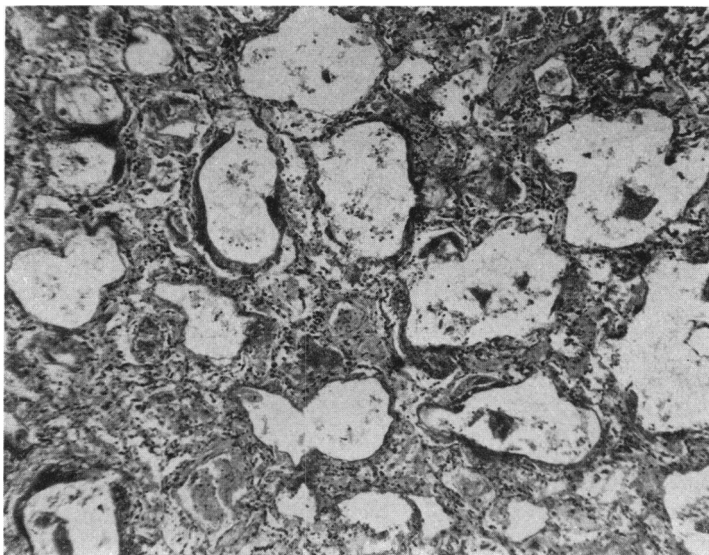
FIG. 9. McMillan's³² case. The cysts in a conglomerate of pneumocystis are stained with the Gram-Weigert stain. $\times 1040$.

FIG. 10. McMillan's³² case. An alveolar septum is greatly enlarged by infiltration with pneumocystis. (See also Fig. 7.) $\times 670$.

FIG. 11. McMillan's³² case. Hyaline membranes line the alveolar septa. Hematoxylin and eosin stain. $\times 50$.



10



11