

## Acute Liver Necrosis Following Overdose of Paracetamol

D. G. D. DAVIDSON,\* M.B., CH.B., D.OBST.R.C.O.G. ; W. N. EASTHAM,† M.B., B.S.

*Brit. med. J.*, 1966, 2, 497-499

Although paracetamol was first described more than seventy years ago, it is only in the last fifteen that it has become popular as a mild analgesic. It has been shown to be the principal breakdown product of phenacetin and to have an analgesic effect of similar magnitude. Liver damage following abuse of phenacetin is quoted by Kasanen and Forsström (1964), but in humans this complication has not been noted with paracetamol, although liver necrosis has been reported in rats (Boyd and Berczky, 1966).

### Case 1

A woman aged 30, an inmate of a mental institution, was admitted to hospital two hours after ingesting at least 50 paracetamol tablets. She had been discovered while still swallowing some of the drug, and gastric lavage was carried out almost immediately. She had been under psychiatric care since adolescence and had received various drug therapies. Currently she was taking nortriptyline, 25 mg. three times a day. She had been taking barbiturates as hypnotics for many years. In the past she had been treated with chlorpromazine and amitriptyline.

On examination she was afebrile, and was drowsy but easily roused to answer questions. There was no evidence of icterus and no hyperventilation. The pulse rate was 80 and B.P. 90/70 mm. Hg. The liver was not palpable. Apart from the diminished level of consciousness there was no evidence of a neurological lesion. Results of investigations are given in Table I.

TABLE I.—Case 1. Investigations

	Day 1	Day 2	Day 3	Day 4
Plasma <i>p</i> -aminophenol (mg./100 ml.) ..	22.4			
Plasma barbiturate (mg./100 ml.) ..	6.1	3.2	3.1	4.1
Plasma urea (mg./100 ml.) ..		12	40	74
Plasma Na+ (mEq/l.) ..		131	143	131
Plasma K+ (mEq/l.) ..			3.8	2.9
Plasma HCO <sub>3</sub> <sup>-</sup> (mEq/l.) ..		11.5	18.5	14.5
Haemoglobin (g./100 ml.) ..		15	15	12.5
W.B.C./c.mm. ..		20,000	16,000	12,500
E.S.R. ..		2	2	1
C.S.F. glucose (mg./100 ml.) ..		10		
Blood glucose (mg./100 ml.) ..		37	48	115

On the second day the patient had an epileptiform fit. It was thought this might be due to drug withdrawal, probably barbiturate, as there was no previous history of epilepsy. Twenty-two hours after her admission the brachial blood-pressure suddenly dropped from 90 systolic to zero. No heart sounds were audible and cardiac resuscitation was carried out.

Treatment over the next two days consisted of general supportive therapy for an unconscious patient. A low blood-sugar level was suspected after cell-free C.S.F. with a sugar level of less than 10 mg./100 ml. was obtained. Blood-sugar levels were maintained initially with 50 ml. of 50% glucose and later with a 5% glucose drip infusion.

The patient's condition continued to deteriorate and she died on the third day after ingestion of the tablets. She was at no time clinically jaundiced.

\* Senior House Officer, Regional Poisoning Treatment Centre, Royal Infirmary, Edinburgh. Now Registrar, Anaesthetic Department, Aberdeen Royal Infirmary.

† Lecturer in Pathology, University of Edinburgh. Now Lecturer in Pathology, Monash University, Melbourne, Australia.

### Case 2

Some months later a man aged 28 was admitted from the same mental institution. He had known the first patient and that she had died after an overdose of paracetamol. He had ingested a claimed 150 of the tablets together with a gill of vodka.

For 18 months prior to the incident he had been treated with large doses of chlorpromazine varying from 0.3 to 1 g. daily. In the week before admission pericyazine was being substituted for chlorpromazine in a dose of 20 mg. three times a day. He had been dependent on sodium amylobarbitone in the past and his current hypnotic dose was 600 mg. at night.

On admission some seven hours after ingestion of the tablets he was fully conscious and afebrile. There was no evidence of jaundice. The pulse rate was 104 and blood-pressure 130/90. The abdomen was soft and the liver was not palpable. Results of investigations are given in Table II.

TABLE II.—Case 2. Investigations

	Day 1	Day 2	Day 3	Day 4
Plasma <i>p</i> -aminophenol (mg./100 ml.) ..	26.7	14.4		
Plasma urea (mg./100 ml.) ..			46	60
Plasma Na+ (mEq/l.) ..			136	140
Plasma K+ (mEq/l.) ..			4.9	4.8
Plasma HCO <sub>3</sub> <sup>-</sup> (mEq/l.) ..			1.5	2.3
Haemoglobin (g./100 ml.) ..	17		17	13.5
W.B.C./c.mm. ..	16,400		42,500	19,500
E.S.R. ..	1		<1	1
Blood glucose (mg./100 ml.) ..	90		<40	<40
Blood fructose (mg./100 ml.) ..				10
Alk. phos. (K.A. units) ..		17	30	
Bilirubin (mg./100 ml.) ..		7.2	9.3	
Thymol turbidity ..		6	6	
pH ..			7.07	7.42
Pco <sub>2</sub> (mm. Hg.) ..			21	32
Standard bicarbonate (mEq/l.) ..			8.8	22
O <sub>2</sub> saturation (%) ..			95	89
Prothrombin ratio ..			>5	4.7

The patient's stomach was washed out on admission. He remained well but obstreperous during the first 24 hours and was sedated with amylobarbitone and chlorpromazine. On the morning of his second day in hospital he complained of nausea and right upper abdominal pain. He was by then slightly icteric but the liver was not palpable. Bile was present in the urine. On the morning of the third day he was markedly icteric and was hyperventilating. He was unconscious but was reacting to painful stimuli. In view of the low blood-sugar level (<40 mg.) he was given a 25 g. of glucose intravenously. The acidaemia was treated with 1/6 molar sodium lactate and 2.5% sodium bicarbonate. Vitamin K was given intravenously and neomycin was given via a naso-gastric tube.

There was an initial slight response to this therapy in the form of a rise in blood-pressure to 110 systolic.

Urinary output, however, was low and input had to be restricted. Because of this and because fructose is said to be more readily metabolized by an ailing liver (*Amer. J. Med.*, 1955), calorie requirement was supplied by 30% fructose intravenously instead of 5% glucose.

On the fourth day his condition worsened, and altered blood was aspirated from the naso-gastric tube. Metaraminol and low-molecular-weight dextran were used in an attempt to maintain the circulation, but both were ineffective. He died some 80 hours after admission.

### Post-mortem Findings

#### Macroscopic

*Case 1.—Kidneys:* Section of each showed slight congestion of the renal parenchyma. The pelves and calices contained small quantities of pus and the mucosa was inflamed throughout. The *liver* weighed 1,650 g. It was obviously congested and was also the seat of a very patchy necrosis. This was in the form of small pale yellowish-brown areas not exceeding 0.3 cm. in diameter. There was no evidence of any frank haemorrhage into the hepatic parenchyma.

*Case 2.—Stomach:* Numerous petechial haemorrhages, some confluent, were present in the fundus and proximal half of the body. In the absence of ulceration the altered blood present was presumed to be derived from these sites. *Kidneys:* Each organ on section showed a normal renal-cortical and medullary pattern. There was no macroscopic evidence to suggest tubular necrosis. The *liver* weighed 2,010 g. The parenchyma was a dark reddish colour, and on section was seen to contain multiple small areas of yellowish-brown tissue. These appeared to represent areas of focal necrosis.

#### Microscopical Findings in Both Cases

*Sections of Liver.—*Low-power examination revealed acute centrilobular hepatic necrosis involving all areas (Figs. 1 and 3). The

necrosis, although surrounding the centrilobular areas, extended throughout the mid-zone towards the peripheral part. High-power examination revealed eosinophilic degeneration of the cells, together with pyknosis of the nuclear material within the central parts of the lobules. Vacuolation and early degenerative features of the more peripherally placed cells surrounding the portal tracts were observed and were more pronounced in Case 2 (Figs. 2, 4, and 5). A very mild polymorphonuclear leucocytic infiltration had occurred in both cases. There did not appear to be any focal haemorrhage associated with the necrosis nor was there any evidence of a cholestatic type of lesion existing in the remaining cells and sinusoids around the portal areas nor any bile plugs in the central areas. The features described represent acute fulminating liver necrosis, the distribution being of a centrilobular type. The features are not specific and in no way diagnostic of any one particular injurious agent.

*Renal Tissue.—*Sections of kidney from Case 1 showed relatively normal cortical and medullary elements. The collecting tubules, however, throughout the sections showed the presence of cast formation, the casts being of the coarse granular type, eosinophilic, and almost completely limited in their distribution to the lower collecting tubular structures. Sections from Case 2 showed changes similar to those of Case 1, but the tubules in several areas were in an advanced state of degeneration, indicating tubular necrosis prior to death. Those affected were principally the proximal tubules, but the distal convoluted tubules also showed degenerative changes. Casts were again observed in the collecting tubules. The features

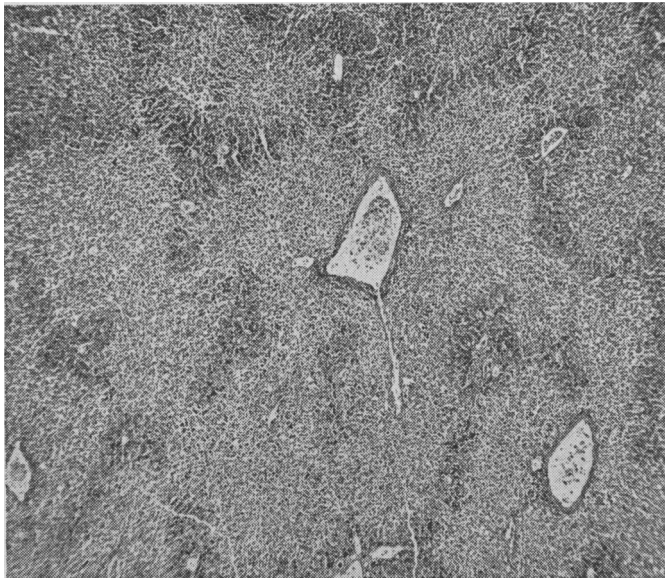


FIG. 1.—Liver, Case 1. ( $\times 20$ .)

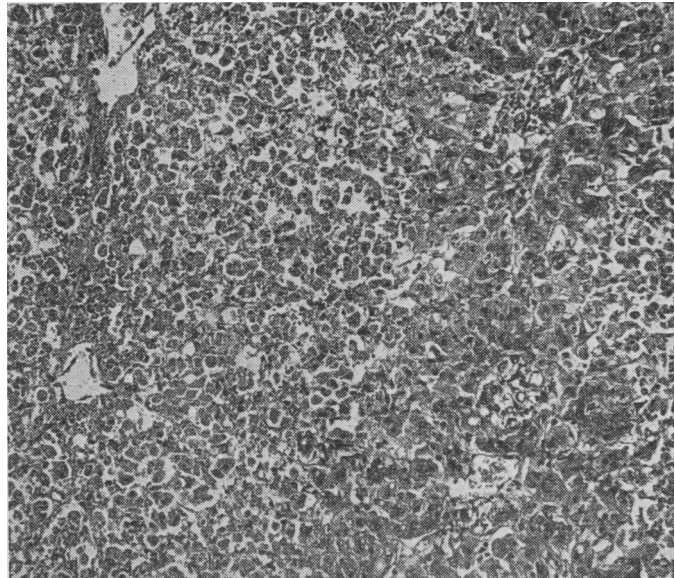


FIG. 2.—Liver, Case 1. ( $\times 100$ .)




FIG. 3.—Liver, Case 2. ( $\times 20$ .)

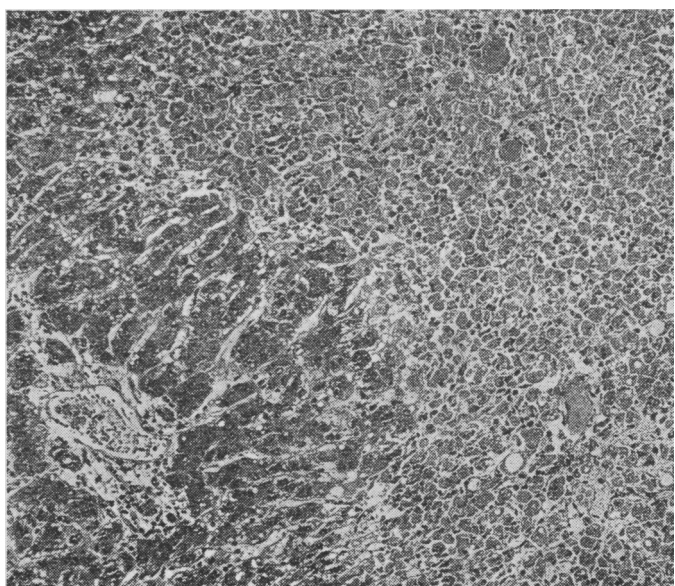


FIG. 4.—Liver, Case 2. ( $\times 100$ .)

described are consistent with the changes observed in cases where there has been a massive hepatic necrosis resulting in or associated with acute renal failure, the so-called hepato-renal syndrome.

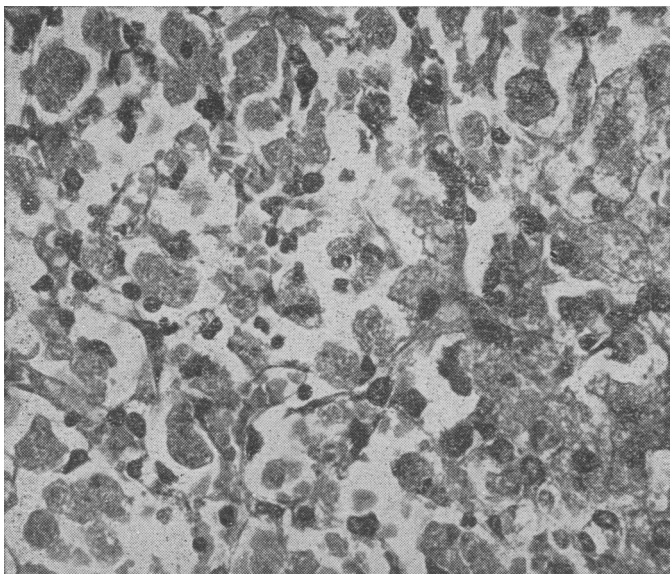


FIG. 5.—Liver, Case 2. ( $\times 400$ .)

### Discussion

The clinical course and pathological findings are remarkably similar and the problem was to elucidate the cause of the acute fulminating liver necrosis.

The main issue was whether the necrosis was due to a viral infection or to some toxic effect of one of the drugs involved. Acute infective hepatitis and homologous serum jaundice are usually associated with prodromal features of pyrexia, malaise, nausea, and vomiting. Apart from some nausea in Case 2 these features were lacking in both cases. Further, in the pre-icteric phase of the disease the E.S.R. is usually high and the white count low. In both cases the reverse was found. The course of the disease was unusually rapid for a liver necrosis of viral origin. Death normally occurs in these cases three weeks from the onset (Hunter, 1956). The absence of lymphocytic cellular infiltration of the portal tracts, together with a scanty but predominant polymorphonuclear reaction, suggests a toxic rather than a viral cause (Anderson, 1961).

The drugs here considered possibly responsible for liver necrosis are: chlorpromazine; amitriptyline and nortriptyline; pericyazine; barbitone, amylobarbitone sodium, and quinalbarbitone; paracetamol.

Chlorpromazine is of course well known as a causative agent in the production of jaundice, but characteristically the picture is of an obstructive lesion. There are usually prodromal symptoms, and the serum flocculation tests are negative (Sherlock, 1963b). Further, there is usually evidence of biliary stasis with bile plugs both in the necrotic centrilobular areas and in the canaliculi nearer the portal tracts. It is clear that if these patients' liver affections were due to chlorpromazine it was not of the type normally ascribed to that drug.

Barbiturates of many varying forms are often taken in large doses as a means of attempting suicide. Jaundice associated with them is not mentioned in recent texts (Sherlock, 1963a) nor are they held as being a causal factor of acute liver necrosis.

Werner (1962), in a review of antidepressant drugs, notes liver complications with some, but not with amitriptyline. Nortriptyline and pericyazine are both relatively recently introduced drugs, and so far there seem to be no published data on liver toxicity associated with their use in man.

Paracetamol was the only drug taken in amounts greater than usual by both patients described here. Levels were estimated as total *p*-aminophenol and were considerably in excess of those found with therapeutic dosage. The range of levels quoted by Gwilt *et al.* (1963) is from 0.45 to 2.6 mg./100 ml. 45 minutes after the ingestion of 1 g. of paracetamol.

Because of the high blood-levels of paracetamol in both patients (22.4 and 26.7 mg./100 ml.) and the close time-relationship between ingestion of the tablets and the development of what both clinically and pathologically was a very rapidly progressing acute liver necrosis, we feel that the damage was a direct toxic effect of the drug, possibly potentiated by a phenothiazine or nortriptyline.

Other interesting features are:

1. *Low Blood-sugar Levels Encountered.*—This is not usually a major feature in liver disease but is present more often than supposed, as indicated by Conn and Seltzer (1955).

2. *Early Appearance of Leucocytosis in Conjunction with a Low E.S.R.*—In cases of paracetamol overdose when there are no facilities for estimating the blood-level of the drug itself the possibility of liver damage may be suspected by noting an increased white cell count in conjunction with a low E.S.R. If these are found close observation of the patient will be required for 48 hours at least.

3. *Changes in the Kidneys of Both Patients.*—We are unable to say whether these features are a direct toxic effect of the ingested poison or secondary to the hypotension which preceded death or to the hepato-renal syndrome.

### Summary

Two cases of acute liver necrosis with fatal outcome are described. Both followed the ingestion of large numbers of paracetamol tablets. Evidence is given suggesting that paracetamol was the chief cause of the necrosis. The presence of profound hypoglycaemia was noted in both patients, overshadowing, and in one instance preceding, other evidence of liver upset.

We wish to thank Dr. Henry Matthew for his help and encouragement and for permission to publish the clinical details of these cases. Dr. W. E. Hunt kindly gave access to the pathological material of Case 2, and Dr. W. D. Boyd gave much background information on both patients.

### REFERENCES

- Amer. J. Med.*, 1955, 19, 163.  
Anderson, W. A. D. (1961). *Pathology*, 4th ed., p. 824. Kimpton, London.  
Boyd, E. M., and Bereczky, G. M. (1966). *Brit. J. Pharmacol.*, 26, 606.  
Conn, J. W., and Seltzer, H. S. (1955). *Amer. J. Med.*, 19, 460.  
Gwilt, J. R., Robertson, A., and McChesney, E. W. (1963). *J. Pharm. Pharmacol.*, 15, 440.  
Hunter, D. (1956). In *Price's Textbook of Practice Medicine*, 9th ed., p. 671. Oxford Univ. Press, London.  
Kasanen, A., and Forsström, J. (1964). *Ann. Med. intern. Fenn.*, 53, 17.  
Sherlock, S. (1963a). *Diseases of Liver and Biliary System*, 3rd ed., p. 300. Blackwell, Oxford.  
— (1963b). *Ibid.*, p. 304.  
Werner, G. (1962). *Clin. Pharmacol. Ther.*, 3, 59.