

Intracranial venous thrombosis complicating oral contraception

F. Dindar,* M.B., B.CH. (Rand.), M.R.C.P. and M. E. Platts, M.D., C.R.C.P.[C], Toronto

Summary: Four days after the onset of a severe headache a 22-year-old woman who had been taking oral contraceptives for less than three weeks had a convulsion, followed by right hemiparesis. Other focal neurologic signs and evidence of raised intracranial pressure appeared, and she became comatose on the seventh day. A left craniotomy revealed extensive cerebral venous thrombosis. She died the next day. On postmortem examination extensive thrombosis of the superior sagittal sinus and draining cerebral veins, and multiple areas of cerebral hemorrhage and hemorrhagic infarction were seen. Some of the superficial cerebral veins showed focal necrosis of their walls, and the lateral lacunae of the superior sagittal sinus contained proliferating endothelial cells. The adrenal veins were also thrombosed. The significance of these findings is discussed. The literature on cerebrovascular complications of oral contraception, particularly cerebral venous thrombosis, is reviewed.

Résumé: *Thrombose veineuse intracrânienne, complication de la contraception orale*

Une jeune femme de 22 ans qui ne prenait des contraceptifs oraux que depuis trois semaines présenta une céphalée sévère. Quatre jours plus tard, elle avait une convulsion suivie d'une hémiparésie droite. D'autres foyers neurologiques et des signes d'une augmentation de la pression intracrânienne apparurent et le septième jour, elle était dans le coma. Une craniotomie gauche révéla une thrombose veineuse cérébrale étendue. Elle mourut le jour suivant. A l'autopsie, on nota une thrombose étendue du sinus longitudinal supérieur et des veines cérébrales drainantes, ainsi que de multiples foyers d'hémorragie cérébrale et d'un infarctus hémorragique. Sur certaines veines cérébrales superficielles, on

constatait une nécrose focale de la paroi, et des lacunes latérales du sinus longitudinal supérieur contenaient des cellules endothéliales prolifératives. Les veines surrénales étaient également thrombosées. La signification de ces constatations est à l'étude. Nous passons enfin en revue la littérature sur les complications cerebrovasculaires de la contraception orale, particulièrement la thrombose veineuse cérébrale.

Attention was drawn for the first time to a possible association between the use of oral contraceptives and cerebrovascular disease by Lorentz in 1962.¹ Since then, numerous case reports and controlled retrospective studies,² most describing cerebral arterial occlusion, have supported this association; these have been reviewed by Masi and Dugdale.³

There are very few reports of cerebral venous thrombosis in women using oral contraceptive agents; some of the patients survived the episode^{4,7} whereas others did not.^{5,8-11} To the 10 pathologically confirmed cases in the English literature¹¹ we add one more, describing some specific histologic changes in the vessel walls, and discussing some of the problems of diagnosis and management.

Case report

M.D., a 22-year-old single woman, was well until June 3, 1973, when a severe generalized headache developed, necessitating a visit to her family doctor. Three weeks earlier he had given her a prescription for Norinyl®-1, a norethindrone-mestranol oral contraceptive tablet, which she had taken in the past, although not recently. Owing to the severity of the headache she was referred to a neurologist whose examination yielded normal findings. The results of a lumbar puncture were also normal. She was sent home on analgesics, but the headache did not subside and vomiting supervened.

On June 6 she was admitted to the Women's College Hospital. Physical examination, including a detailed neurologic assessment, yielded no abnormal findings apart from low grade pyrexia. The next day she had a generalized convulsion, followed by right hemiparesis which persisted. A detailed neurologic examination on June 10 revealed right hemiparesis, partial right homonymous hemianopia, a right hemisensory deficit, expressive aphasia and early papilledema. A left

carotid angiogram showed a space-occupying lesion in the left parietal region causing some shift to the right. The configuration of vessels suggested some swelling in the frontal pole as well. There were prominent enlarged cortical veins draining anteriorly into the Sylvian region. No opacification of the superior sagittal sinus was observed in the posterior two thirds of the skull.

The patient was transferred to the neurosurgical department at The Wellesley Hospital. During examination in the emergency department she suddenly complained of increasing headache, became restless, screamed, and then stopped breathing and became comatose. She was resuscitated and sent immediately to the operating room. Bifrontal burr holes were drilled and the ventricles were tapped; the ventricles were small but the cerebrospinal fluid pressure was increased. A left-sided frontoparietal craniotomy was then performed. Extensive thrombosis of the superficial cerebral veins was observed in the frontal, temporal, parietal and occipital regions. A subcortical focus of hemorrhagic necrotic tissue in the posterior parietal region was evacuated. Near the end of the operation swelling of the brain was observed, so the dura was left open and the bone flap removed. Postoperatively the patient remained dextro-corticate. Treatment with dexamethasone, diphenylhydantoin and antibiotics was ineffective. The patient died on June 11, 1973, eight days after the onset of headache.

Postmortem findings

Significant findings were confined to the brain and adrenal glands.

Brain: The brain had herniated through the left craniotomy site. There were severe herniations of the right cingulate and right parahippocampal gyri. A small amount of blood was present in the subarachnoid space over both hemispheres. The superior sagittal sinus, transverse sinuses and occipital sinus, as well as many of the draining veins, were thrombosed (Figs. 1 and 2). Coronal sections of the brain showed multiple small and large areas of hemorrhage and hemorrhagic infarction affecting both the grey and white matter bilaterally (Figs. 3 and 4). Secondary brain stem hemorrhages were present (Fig. 4). Microscopic examination showed organizing thrombus in the superficial cerebral veins and the superior sagittal sinus. The lateral recesses of the superior sagittal sinus showed masses of proliferating endothelial cells (Fig. 5). The cerebral veins were acutely necrotic in some areas with polymorphonuclear infiltration; in other regions they showed edema of the wall only.

From the department of pathology, The Wellesley and The Princess Margaret Hospitals, Toronto

*Formerly resident in neuropathology; currently resident in clinical neurology at The Toronto Western Hospital

Reprint requests to: Dr. M. E. Platts, The Princess Margaret Hospital, 500 Sherbourne St., Toronto, Ont. M4X 1K9

There was no evidence of intracerebral arterial thrombosis. The carotid arteries in the neck were not examined.

Adrenal glands: A large vein in the left adrenal gland showed thrombosis with early organization (Fig. 6). The right adrenal gland showed an organizing venous thrombus only on microscopic examination.

Discussion

Our patient died from the sequelae of extensive cerebral venous thrombosis. Except for the intake of oral contraceptives none of the numerous predisposing factors such as hypertension or polycythemia was present.¹² Therefore, we believe that in this case the oral contraceptives were the cause of the venous thrombosis.

A review of the related literature discloses that many of the patients had been taking medication containing estrogen for only a short time (Table I). From the information available to us we can conclude that our patient could not have taken it on this occasion for longer than three weeks although she had taken it previously for a period of unknown duration. The low content of estrogen in several of the widely used preparations, as in our case, does not appear to protect the patient from this complication.

The pathogenetic mechanisms of vascular thrombosis due to oral contraceptives fall into two categories. First, there are the well documented changes in coagulation factors leading to a hypercoagulable state:¹³ increased pla-

telet aggregation and adhesiveness; increased factors VII, IX and X; and increased prothrombin and fibrinogen. Also noted are molecular alterations in fibrinogen, decreased antithrombin III, and an increased incidence of cryofibrinogenemia. Neither platelet studies nor coagulation factor studies were performed in our case because the diagnosis was not suspected clinically and the patient died shortly after the craniotomy.

The second important factor, on which increasing attention has recently been focused, is changes in the vessel wall. The evidence for this has come from experiments in animals, detailed neuropathological reports,^{11,14,15} and angiographic findings. Endothelial proliferation is the most frequently re-

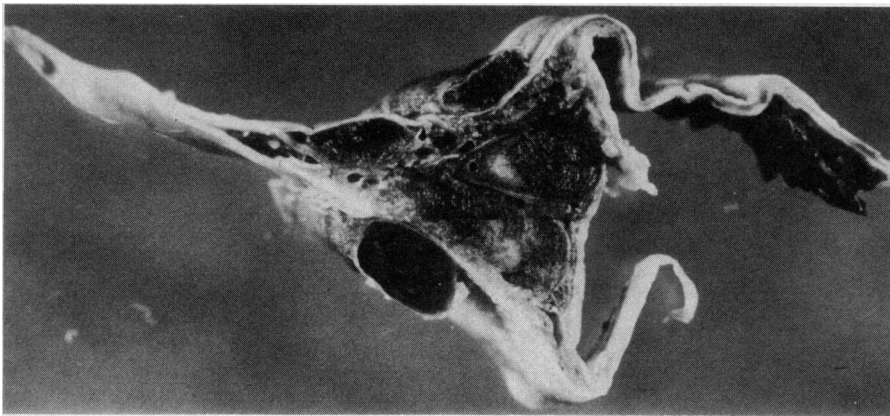


FIG. 1—Thrombosed superior sagittal sinus and cerebral veins. A small amount of blood clot is present on the extradural surface at the top.

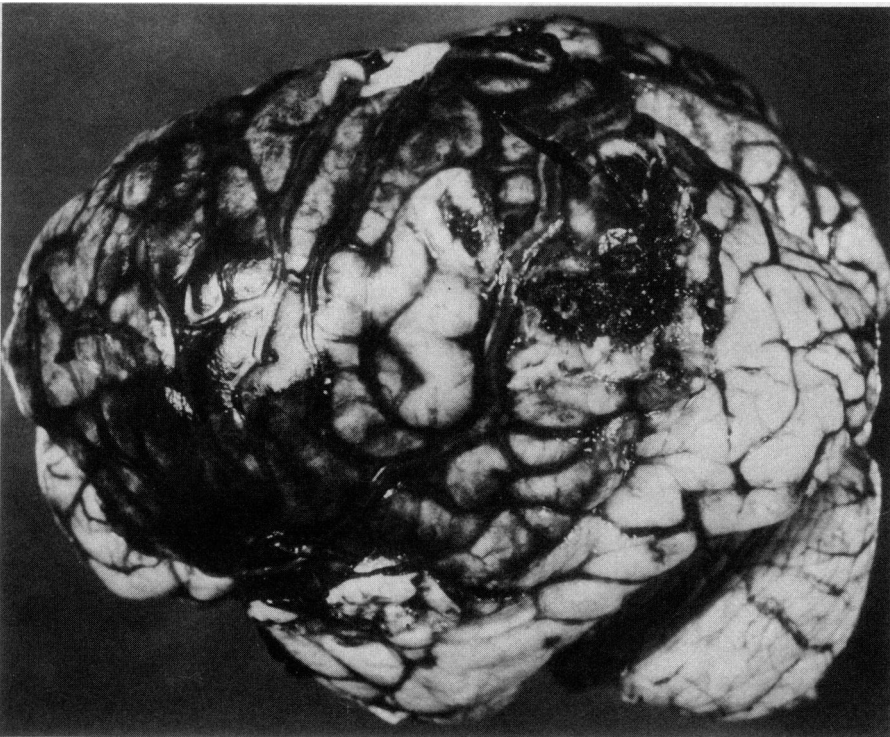

FIG. 2—Thrombosed superficial cerebral veins over left hemisphere. Herniation of brain in area of frontoparietal craniotomy is evident, with hemorrhagic necrosis at biopsy site posteriorly. Defects near the central superior surface represent areas where fresh unfixed tissue was removed for virological studies.

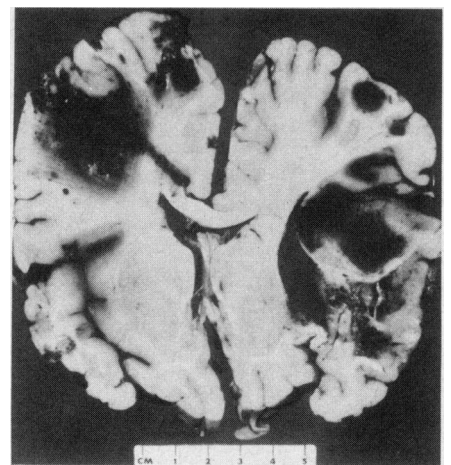


FIG. 3—Coronal section of the brain through the frontoparietal region to show areas of hemorrhage and hemorrhagic infarction in both hemispheres. A needle track extends to the left cingulate gyrus. Note the triangular defect in the centre of the superior surface representing the site of the enlarged, thrombosed superior sagittal sinus.

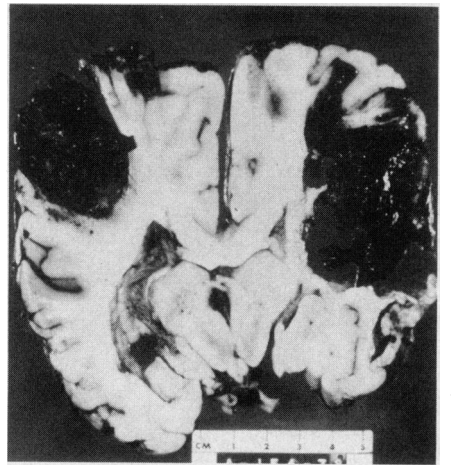


FIG. 4—Coronal section of the brain through the parietal region showing massive bilateral cerebral hemorrhages as well as secondary hemorrhages in the midbrain.

ported finding. Poltera¹¹ has described endothelial proliferation in the lateral lacunae of dural sinuses in two cases of venous sinus thrombosis. He believes that the coagulation process commenced in the lacunae. In our case proliferating endothelium was observed in lateral lacunae of the superior sagittal sinus. The significance of these findings has been questioned,¹³ and it has been suggested that these are normal arachnoid villi. We believe these changes are significant.

The other striking finding in our case was focal necrosis of walls of thrombosed cerebral veins with marked polymorphonuclear infiltration in some areas. Altshuler, McLaughlin and Neuberger¹⁴ have described fibrinoid swelling of intracerebral arterioles and necrosis of the walls of small intrarenal vessels. We believe that these findings cannot be explained entirely on the basis of vein wall ischemia and are possibly related to the contraceptive intake.

The symptomatology of all the patients falls into two groups: the effects of acutely raised intracranial pressure — headache, vomiting, convulsions, papilledema and increasing somnolence; and focal neurologic deficits. In most cases, as in our patient, there was an increase in body temperature.

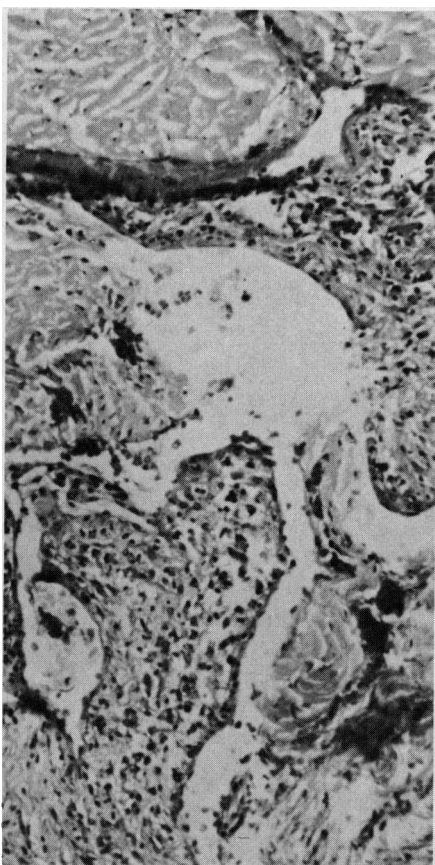


FIG. 5—Masses of proliferating endothelial cells in the lateral recesses of the superior sagittal sinus.

The gross pathologic findings in the other reported cases have been similar to those in our case. Subarachnoid hemorrhage in varying degrees was frequently present.

Cerebral venous thrombosis should be considered as a possible diagnosis in any healthy woman who suddenly develops an obscure neurologic condition with signs of raised intracranial pressure with or without focal features. Although in our case the diagnosis was made only at craniotomy, in most cases it can be made by adequate angiography. The important point is that both venous sinus thrombosis and raised intracranial pressure slow cerebral circulation and, therefore, unless the procedure is repeated at a slow speed, phlebograms are not obtained

and the diagnosis is missed.¹⁶ If venous sinus thrombosis is suspected, then repeat injection should be considered necessary.

The prognosis of this condition is variable. At one extreme there is rapid progression and death in a few days; our patient died eight days after the onset of headache. On the other hand, patients have gone on to make an almost complete recovery. Some recovered patients had been treated with heparin,^{4,7} but the extremely variable progression of the disease makes the results of anticoagulant therapy difficult to assess. In the later stages there is a definite risk of aggravating cerebral hemorrhage with anticoagulation. Kalbag and Woolf¹⁶ consider anticoagulation mandatory before convulsions en-

Table 1—Cases of cerebral venous thrombosis, confirmed at autopsy, in patients taking oral contraceptive agents

Age	Reason for medication	Oral contraceptive	Estrogen content	Duration of Treatment
35*	Contraception	Enovid	0.15 mg mestranol	2 years
29††	Contraception	Enovid	0.15 mg mestranol	1 year
29†	Contraception	Ortho-Novum	0.08 mg mestranol	1 year
24¶	Contraception	Lyndiol, 2.5	0.075 mg mestranol	7 weeks
49¶	Menopausal symptoms	Metrolen-M	0.1 mg mestranol	11 days
30¶	Contraception	Anovlar	0.05 mg ethinyl estradiol	Not known
23¶	Contraception	Gynovlar	0.05 mg ethinyl estradiol	11 days
29¶	Contraception	Nuvacon	0.1 mg ethinyl estradiol	1 year
41♂	Menstrual disturbances	Ovulen	0.1 mg mestranol	6 months
50♂	Blood-stained vaginal discharge	Norcyclin 5	0.15 mg mestranol	2 weeks
22**	Contraception	Norinyl-1	0.05 mg mestranol	3 weeks

*Buchanan and Brazinsky⁵

†Walsh, Clark and Thompson⁸

‡Shafey and Scheinberg⁹

¶Atkinson, Fairburn and Heathfield¹⁰

♂Poltera¹¹

**Present report

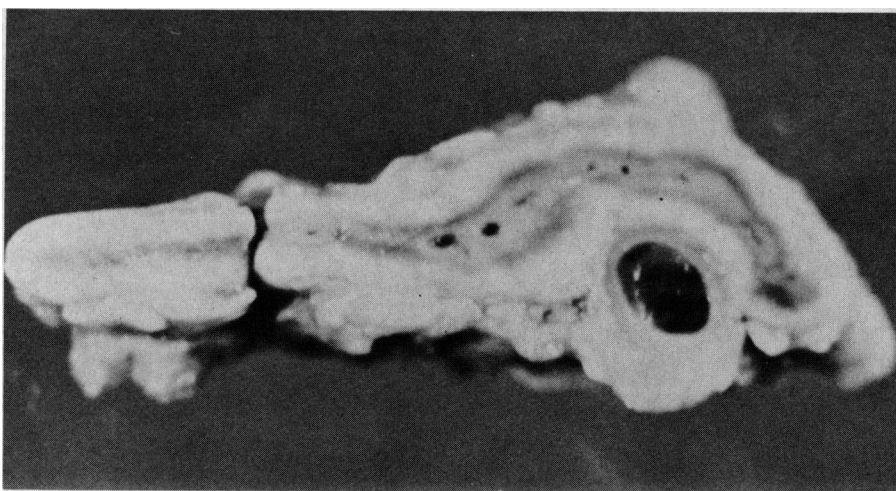


FIG. 6—Thrombosis of a large vein draining the left adrenal gland.

restores
equilibrium in 9 out of 10
patients
with
vertigo



ANTIVERT

Antivert* stops vertigo in 9 out of 10 cases.¹
Antivert restores equilibrium and increases
the flow of blood through vasodilation.²

Indications: Vertigo, whether due to cerebral arteriosclerosis, Ménière's syndrome, labyrinthitis, radiation sickness, vestibular dysfunction or other related conditions. Antivert has also been found valuable in the treatment of vascular headache.

Contraindications: Severe hypotension and hemorrhage.

Side Effects: Cutaneous flushing, sensations of warmth, tingling and itching, burning of the skin, increased gastrointestinal motility, and sebaceous gland activity. These frequent, short-lived reactions are coincidental to vasodilation produced by niacin.

Precautions: Since meclizine may occasionally induce drowsiness, patients should be cautioned when engaged in activities requiring alertness.

Composition: Meclizine HCl 12.5 mg. and niacin 50 mg. per tablet.

Dosage: One tablet 3 times a day before meals. If excessive flushing occurs, tablets should be taken immediately after meals.

Supply: Scored tablets (blue), in bottles of 100 and 500.

(1) Menger, H.C., Clin. Med., 4, 313, 1957.

(2) Griesman, L., Scient. Exh. Am. Acad. Ophth. Otolaryng., 1964.

FULL INFORMATION AVAILABLE ON REQUEST.

*Trade Mark — Authorized User.

sue; the two cases reported by Fairburn⁷ support the use of anticoagulants. A focal neurologic deficit may be due to edema alone and is therefore not a contraindication in the early stages.¹⁶ Dehydrating agents to relieve intracranial pressure should be avoided because they may aggravate the thrombosis. The use of dexamethasone is recommended.

The risk of cerebral venous thrombosis developing in a young woman on oral contraceptives is extremely small. However, it should be considered in the differential diagnosis of such a patient presenting with severe headache or focal neurologic deficit.

We would like to thank Drs. K. E. Livingston and Otto Veidlinger for providing the clinical information, Miss Marlene Bliss for photographic assistance, and Mrs. Marie Wilson for her secretarial expertise.

References

- LORENTZ IT: Parietal lesion and "enavid" (corresp). *Br Med J* II: 1191, 1962
- INMAN WHW, VESSEY MP: Investigation of deaths from pulmonary, coronary and cerebral thrombosis and embolism in women of child-bearing age. *Br Med J* II: 193, 1968
- MASI AT, DUGDALE M: Cerebrovascular disease associated with the use of oral contraceptives. A review of the English language literature. *Ann Intern Med* 72: 111, 1970
- FILIPA G, REGLI F, NOSEDA G: Kausalzusammenhänge Zwischen Einnahme Oraler Kontrazeptiva Hirvenenthrombose. *Munch Med Wochenschr* 13: 691, 1967
- BUCHANAN DS, BRAZINSKY JH: Dural sinus and cerebral venous thrombosis. Incidence in young women receiving oral contraceptives. *Arch Neurol* 22: 440, 1970
- MCFARLAND HR: Regression of cerebral lesions after cessation of oral contraceptives. *South Med J* 63: 145, 1970
- FAIRBURN B: Intracranial venous sinus thrombosis complicating oral contraception: treatment by anticoagulant drugs. *Br Med J* II: 647, 1973
- WALSH FB, CLARK DB, THOMPSON RS, et al: Oral contraceptives and neuro-ophthalmologic interest. *Arch Ophthalmol* 74: 628, 1965
- SHAFEE S, SCHEINBERG P: Neurological syndromes occurring in patients receiving synthetic steroids (oral contraceptives). *Neurology (Minneapolis)* 16: 205, 1966
- ATKINSON EA, FAIRBURN B, HEATHFIELD KWG: Intracranial venous thrombosis as complication of oral contraception. *Lancet* I: 914, 1970
- POLTERA AA: The pathology of intracranial venous thrombosis in oral contraception. *J Pathol* 106: 209, 1972
- STEBBENS WE: *Pathology of Cerebral Blood Vessels*, first ed. St. Louis, Mosby, 1972, p 189
- HOUGIE MD: Thromboembolism and oral contraceptives. *Am Heart J* 85: 538, 1973
- ALTSHULER JH, McLAUGHLIN RA, NEUBERGER KT: Neurological catastrophe related to oral contraceptives. *Arch Neurol* 19: 264, 1968
- IREY SN, TAYLOR HB, MAMON WC: Vascular lesions in women taking oral contraceptives. *Arch Pathol* 89: 1, 1970
- KALBAG RM, WOLF AL: Vascular diseases of nervous system, part II, in *Handbook of Clinical Neurology*, vol 12, first ed, edited by VINKEN PJ, BRUYN GW, Amsterdam, N Holl Publ Co, 1972, p 422

Pfizer PHARMACEUTICAL DIVISION
50 PLACE CREMAZIE, MONTREAL 351, QUEBEC