

# ELECTRON MICROSCOPIC OBSERVATIONS OF BONE MARROW FROM PATIENTS WITH SIDEROBLASTIC ANEMIA

GEORGE D. SORENSON, M.D.

*From the Department of Pathology, Washington University School of Medicine, St. Louis, Mo.*

Sideroblastic anemia, also called sidero-achrestic<sup>1</sup> or hypochromic-hypersideremic anemia,<sup>2</sup> is a moderate to severe, chronic anemia which is refractory to known therapy.<sup>3-5</sup> Patients with this disease usually have high serum iron values and saturated iron-binding proteins. Characteristically the tissue iron stores are greatly increased and there are large quantities of iron in the liver as well as in the bone marrow.<sup>5,6</sup> Within the bone marrow much of the iron is in macrophages, but iron stains also show many blue granules within erythroblasts and erythrocytes. Electron microscopic studies have demonstrated that much of the iron in the latter cell types is within mitochondria.<sup>7</sup> The present investigation was undertaken to learn more about the ultrastructure of bone marrow in patients with sideroblastic anemia, including, in particular, intercellular relationships and the intra- and extracellular form and localization of iron.

## MATERIAL AND METHODS

Bone marrow was examined from 7 patients with sideroblastic anemia (Table I).<sup>5</sup> Samples were obtained from each patient by conventional needle aspiration of the sternum. Aspirate was rapidly placed in either Dalton's osmium dichromate fixative at pH 7.6<sup>8</sup> or in 0.6 per cent potassium permanganate in Krebs-Henseleit solution

TABLE I  
CLINICAL FEATURES IN 7 PATIENTS WITH SIDEROBLASTIC ANEMIA

Patient	Sex	Age	Duration of anemia (yr.)	Lowest recorded hemoglobin (gm.)	Lowest recorded hematocrit (%)	Serum iron ( $\mu$ gm. %)
A.S.	M	66	2.0	4.3	18	250
W.C.	M	37	10.0	6.0	27	294
L.H.	M	83	3.0	7.9	25	106
H.M.	M	88	0.5	8.0	28	212
O.B.	M	66	0.5	7.9	28	211
G.M.	M	53	2.0	5.5	23	340
H.S.	M	60	2.5	8.5	25	254

This investigation was supported in part by United States Public Health Service Grant A-3355.

Accepted for publication, September 8, 1961.

which is a modification of Luft's fixative.<sup>9</sup> Fixation in osmium fixative was for approximately 1 hour at room temperature and in potassium permanganate fixative for about 2 hours at 4° C. Specimens were then dehydrated in graded solutions of ethanol, infiltrated and embedded in partially prepolymerized methacrylate or araldite. Polymerization occurred at 60° C. Sections were cut on glass knives in a Porter-Blum microtome.<sup>10</sup> Sections approximately 1  $\mu$  in thickness were mounted on slides for identification by phase microscopy of the area to be sectioned for electron microscopy. Thin sections were mounted on collodion-coated copper grids and examined in either an RCA EMU-2E or EMU-3F electron microscope at an initial magnification of 1,500 to 30,000 diameters. Some thin sections were stained with lead hydroxide.<sup>11</sup> Films of bone marrow from the same patients were stained with Wright's stain and by the Perls (Prussian blue) method and examined by light microscopy.

## OBSERVATIONS

### *Light Microscopy*

Bone marrow films from these patients exhibited erythroid hyperplasia. A close association between some macrophages and immature erythroid cells was observed, but this relationship was not as readily apparent as by electron microscopy. This might have been due to distortion and destruction of reticuloendothelial cells which frequently occurs in bone marrow films.<sup>12</sup> However, an occasional macrophage with surrounding erythroblasts was found (Fig. 1). This formed a macrophage-erythroblast island, as described by Bessis and Breton-Gorius.<sup>13,14</sup> Bone marrow films stained by the Perls (Prussian blue) method contained blue granules of variable size within macrophages and small blue granules within erythroblasts and erythrocytes. There were as many as 50 iron-positive granules within a single erythroid cell. The latter type of granule usually had a perinuclear arrangement (Fig. 2). The number of erythroid cells which contained numerous stainable iron granules varied from patient to patient, but not infrequently the majority of nucleated erythroid elements were involved.

### *Electron Microscopy*

The aspirated material contained large clumps of marrow cells with intact intercellular relationships and blood vessels which were well preserved. Cells of erythroid and myeloid series, as well as megakaryocytes, plasma cells and macrophages, were readily identified. Iron was observed only within macrophages, sinus lining cells and cells of the erythroid series.

*Macrophages.* Macrophages of bone marrow were large cells with abundant cytoplasm containing a variety of inclusions, among which large amounts of molecular ferritin were prominent (Figs. 3 and 4).<sup>15</sup> Some ferritin was scattered diffusely throughout the cytoplasm and frequently appeared in clumps. The latter were observed by light micros-

copy and were usually identified as hemosiderin. Iron was never visualized within mitochondria. Another type of inclusion which was variably associated with clumps of ferritin was irregular in size and shape and quite osmiophilic except for round clear areas or vacuoles (Fig. 3). It appeared likely that this substance was lipofuscin or ceroid since macrophages in the marrow of these patients contained acid-fast material which could be stained in paraffin sections with oil red O.<sup>16</sup> Some of the other foreign material in the cytoplasm of the phagocytes consisted of erythrocytes in varying stages of disintegration. Frequently the outline of the engulfed cell could still be barely detected, and at the periphery of such degenerating cells two alterations were observed. About some there was an irregular accumulation of ferritin while in other places membrane formations were observed (Figs. 5 and 6). The latter were composed of a regular array of tightly packed osmiophilic membranes within or extending circumferentially about a portion of the periphery of the red blood cell. Within shadow outlines of engulfed erythrocytes there were also closely packed clumps of electron-dense material in a distinctly grouped arrangement (Fig. 5). This arrangement consisted of several closely situated but separate masses of material which represented the iron between the cristas of the mitochondria; this has been described in erythroid cells from these patients.<sup>6</sup>

*Macrophage-Erythroblast Relationship.* The close association of erythroblasts with macrophages as observed by light microscopy (Fig. 1) was even more readily apparent by electron microscopy. The macrophages had prominent cytoplasmic processes which extended out between or beside adjacent erythroblasts. Thus many erythroblasts bordered on or were partially surrounded by macrophage cytoplasm, and often rather large portions of the plasma membranes of the two cell types were in apposition. At times a macrophage was surrounded by several erythroblasts, forming a macrophage-erythroblast island (Fig. 7). This was observed prominently in bone marrow from patients with sideroblastic anemia, but an identically close association between erythroblasts and macrophages has been encountered in other cases of anemia.<sup>17</sup> Invaginations of erythroblast plasma membranes adjacent to the macrophages were frequent; and particulate ferritin was aligned along the outer surface of these indentations (Figs. 8 and 9). Within the erythroblasts there were membrane-enclosed spaces containing ferritin; this was also arranged just within the surrounding membranes. Ferritin enclosed in similar membranes was not observed within macrophages. It appeared that the ferritin had been transferred from the macrophage to the adjacent erythroblast. This means of ferritin intake by erythroblasts has been termed rhopheocytosis (rhopheo: Greek  $\rho\phi\epsilon\omega$ —to sup greedily,

gulp, or bolt down) by Policard and Bessis.<sup>18</sup> At other times ferritin seemed to pass into erythroblasts by a similar process except that the erythroid cells were not immediately adjacent to a macrophage (Figs. 9 and 10). This suggested that some ferritin was free to pass into erythroblasts from the extracellular space of the bone marrow away from the immediate zone of contact between macrophage and erythroblast.

*Erythroblasts.* Erythroblasts contained iron in several locations. Iron in the form of ferritin within small vesicles was mentioned above. Ferritin was also situated diffusely throughout the erythroblast cytoplasm, but to a lesser extent than in macrophages. In addition, there were cytoplasmic clumps of ferritin (Figs. 11 and 12). Such clumps sometimes appeared to be enclosed by a membrane and usually only one, but occasionally two clumps were seen in the section of a single cell. Iron was also found within mitochondria of erythroblasts as well as erythrocytes within the marrow space (Fig. 12). The number of erythroid cells affected varied from case to case, but frequently mitochondrial iron was found in most nucleated erythroid elements (Fig. 13). Within an individual abnormal erythroblast with mitochondrial iron, the mitochondria were usually uniformly involved. A small portion of the mitochondrial iron could be ferritin, but most of it differed in appearance from the cytoplasmic aggregates of ferritin. The latter had a uniform, rather coarsely granular form whereas the mitochondrial iron was more finely dispersed (Fig. 14). This difference was observed in bone marrow fixed in osmium as well as in that fixed in potassium permanganate. A difference between the appearance of ferritin and mitochondrial iron has also been noted by Bessis and Breton-Gorius.<sup>19</sup> The amount of iron within individual mitochondria was quite uniform within a single cell but varied from erythroblast to erythroblast. The mitochondrial iron lay between cristas which apparently kept it separated. Iron was not observed within the double membranes of mitochondria. Some mitochondria in erythrocytes within the marrow sinuses contained extremely large amounts of iron which caused the mitochondrial membranes to be distended. Occasionally, a greatly enlarged or giant mitochondrion was observed.

#### DISCUSSION

Normal human bone marrow contains small amounts of iron which can be stained with the Perls (Prussian blue) reaction.<sup>12,20-22</sup> This stainable iron lies largely within macrophages and is usually considered to be hemosiderin. The relationship between hemosiderin and ferritin has long been a matter of disagreement. However, electron microscopic observations have clearly demonstrated that much of what is identified as

hemosiderin by light microscopy is actually closely arranged molecular ferritin.<sup>23,24</sup> However, not all the iron in hemosiderin is in this form.<sup>25</sup> The observations we have made in these anemic patients are not only in accord with this concept but also indicate that there is much ferritin (and perhaps iron in other forms also) throughout the cytoplasm of macrophages; this cannot be seen with the light microscope. The hemosiderin clumps are sometimes associated with other cytoplasmic inclusions which are probably lipofuscin or ceroid.

Final destruction of erythrocytes occurs in macrophages.<sup>26</sup> This process takes place not only in bone marrow macrophages but also elsewhere in other reticuloendothelial tissues. However, the details of the process of red cell disintegration are not well understood. Electron microscope observations of macrophages in bone marrow by Bessis and Breton-Gorius have shown the development of lamellar membranes and the accumulations of ferritin at the periphery of engulfed cells.<sup>24</sup> An identical development of osmiophilic membranes about disintegrating red cells occurs in sinus lining cells of liver.<sup>27</sup> The present investigation is in complete agreement with these observations. The membrane formations are apparently related to the lipoprotein content of engulfed red cells,<sup>28</sup> and similar structures (myelin figures) can be seen in purified preparations of lipoprotein.<sup>29</sup> The close association of ferritin with disintegrating erythrocytes suggests that it is obtained from these cells. While some of this ferritin is probably released from the erythrocytes, portions may be derived from hemoglobin iron during the process of disintegration within the macrophage.

It is well known that iron derived through the catabolism of erythrocytes is re-utilized in the formation of hemoglobin by erythroblasts.<sup>30</sup> When the iron is released in reticuloendothelial cells outside the bone marrow, it is apparently carried to sites of erythropoiesis by a serum globulin, transferrin. Such a mechanism may also be important in transfer within the bone marrow. However, in the marrow it appears that there is also direct transfer of iron in the form of ferritin between macrophages and erythroblasts. This process of intercellular transfer was initially described by Policard and Bessis.<sup>18</sup> Although particularly marked and therefore easy to visualize in marrow from patients with sideroblastic anemia, it also occurs in other conditions.<sup>2,17</sup> Similar macrophage-erythroblast islands occur in fetal yolk sac,<sup>31</sup> and a somewhat similar intercellular transfer occurs in the fetal liver.<sup>27</sup> Although a close association of some erythroblasts with macrophages can be seen by light microscopy, the extensive contact between these two types of cells is more adequately appreciated with electron microscopy.

The attachment of ferritin to the erythroblastic plasma membrane

and the subsequent incorporation of this into the cell has been called rhopheocytosis by Policard and Bessis.<sup>18</sup> Although the entrance of the ferritin into the erythroblast can be considered a form of phagocytosis or pinocytosis, the details of the passage of ferritin out of the macrophage and across the intercellular space are difficult to define exactly. It appears that sometimes the ferritin passes from the macrophage directly into an adjacent erythroblast. In the latter, it is observed just beneath the plasma membrane enclosed by a single membrane which is presumably derived from the erythroblast. Apparently ferritin escapes from the macrophage into the intercellular space unsurrounded by a membrane, or else this membrane has rapidly broken down or fused with that of the erythroblast. Otherwise, the ferritin within the erythroblast would be contained within a double membrane. Ferritin in the extracellular space adjacent to erythroblasts may also be observed, apparently at some distance from any macrophage. This may mean that not all the ferritin passing into an erythroblast is transferred directly from a macrophage or that the ferritin is attached to an erythroblast when it is in proximity, and at least a portion of the cell moves to another location.

Some erythroblasts and immature erythrocytes may show a positive reaction for iron normally when stained by the Perls method. Erythroid cells containing stainable iron were initially noted by Grüneberg in newborn flexed-tailed mice with congenital normocytic-hypochromic anemia.<sup>32</sup> Later, identical granules were found in the blood of normal newborn rats, mice, and human fetuses, and newborn infants.<sup>33</sup> In mice there are approximately 1 to 12 granules per cell, but in the human fetal blood only 1 or 2 are observed. Douglas and Dacie also noted that immature erythroid cells usually contained fewer than 10 to 12 blue granules per cell.<sup>21</sup> These counts are in marked contrast to those we have made in abnormal erythroblasts in our patients; some erythroblasts among these may contain as many as 50 blue granules. Erythroid cells containing granules stained by Perls's stain are designated sideroblasts or siderocytes, depending on whether or not a nucleus is observed. Although sideroblasts and siderocytes are present in human bone marrow, normally they are not found in the peripheral blood.<sup>21</sup> The number of bone marrow sideroblasts and siderocytes increases in many hematologic disorders, and frequently under these circumstances siderocytes may appear in the peripheral circulation.<sup>21</sup>

Recent electron microscopic studies indicate that foci of stainable iron in normal erythroid cells are actually aggregates of closely arranged molecular ferritin. More of these clumps are observed than might be expected by light microscopy. It appears likely that all erythroblasts contain some iron in this form. Identical clumps have been observed in

erythroblasts in human beings,<sup>2,17</sup> guinea pigs (adult and fetal),<sup>17,31</sup> rats,<sup>17</sup> and rabbits (adult and fetal).<sup>17,27</sup>

Recently, attention has been focused on iron stains of bone marrow as it has become known that in some patients with refractory anemia the number of iron-containing erythroid cells is increased, as is the number of iron granules in single erythroblasts.<sup>1-5</sup> Electron microscopy has shown that most of the iron granules observed by light microscopy in the marrow of these patients is actually within erythroblast mitochondria.<sup>2</sup> Clumps of ferritin are encountered as in normal erythroblasts, but these are relatively uncommon. Our own observations are in complete agreement with these findings.

Sideroblastic anemia occurs despite the existence of enormous iron stores, and the iron evidently passes readily into erythrocyte precursors. However, much of it is apparently not utilized for hemoglobin formation. The reason for this is unknown. It may be due to a defect in heme synthesis; certain of these patients do show abnormalities in porphyrin metabolism.<sup>5</sup> It is particularly noteworthy that the iron accumulates in mitochondria, since it has been demonstrated that these are important in certain phases of porphyrin synthesis, possibly in the formation of heme by incorporation of iron into the porphyrin ring.<sup>34,35</sup> On the other hand, it is also possible that there may be abnormality of globin formation or in the combination of products in the final formation of hemoglobin. It does seem likely, however, that iron accumulates in erythroid cell mitochondria because of a failure in normal incorporation into hemoglobin. This may be due to certain enzyme system defects associated with the mitochondria.

#### SUMMARY

Electron microscopic studies were made of bone marrow in 7 patients with sideroblastic anemia. Increased iron was observed within both macrophages and immature erythroid cells. The former appeared as ferritin which was either clumped or dispersed throughout the cytoplasm. Erythroblasts frequently lay adjacent to macrophages forming macrophage-erythroblast islands.

Some ferritin entered near-by erythroblasts directly from macrophages ("rhopheocytosis"). Erythroblast cytoplasm contained ferritin, and there were large amounts of iron within mitochondria. The latter was the characteristic abnormality in the bone marrow from these patients. The cause of mitochondrial iron accumulation is unknown; it may be related to defects in mitochondrial enzymes.

#### REFERENCES

1. HEILMEYER, L. Les anémies sidéroachrestiques. *Sang*, 1958, 29, 465-475.

2. BESSIS, M. C., and BRETON-GORIUS, J. Ferritin and ferruginous micelles in normal erythroblasts and hypochromic-hypersideremic anemias. *Blood*, 1959, **14**, 423-432.
3. BJÖRKMAN, S. E. Chronic refractory anemia with sideroblastic bone marrow. A study of 4 cases. *Blood*, 1956, **11**, 250-259.
4. DACIE, J. V.; SMITH, M. D.; WHITE, J. C., and MOLLIN, D. L. Refractory normoblastic anaemia; a clinical and haematological study of seven cases. *Brit. J. Haemat.*, 1959, **5**, 56-82.
5. FLIPSE, T. E.; SORENSON, G. D., and VARVA, J. D. Refractory sideroblastic anemia. Report of 5 cases with studies of porphyrin metabolism and electron microscopy. (Submitted for publication)
6. CAROLI, J.; BERNARD, J.; BESSIS, M.; COMBRISSE, A.; MALASSET, R., and BRETON, J. Hémochromatose avec anémie hypochrome et absence d'hémoglobine anormale; étude au microscope électronique. *Presse méd.*, 1957, **65**, 1991-1996.
7. BESSIS, M., and BRETON-GORIUS, J. Accumulation de granules ferrugineux dans les mitochondries des érythroblastes. *Compt. rend. Acad. sc.*, 1957, **244**, 2846-2847.
8. DALTON, A. J. A chrome-osmium fixative for electron microscopy. *Anat. Rec.*, 1955, **121**, 281.
9. LUFT, J. H. Permanganate—a new fixative for electron microscopy. (Brief note) *J. Biophys. & Biochem. Cytol.*, 1956, **2**, 799-801.
10. PORTER, K. R., and BLUM, J. A study in microtomy for electron microscopy. *Anat. Rec.*, 1953, **117**, 685-710.
11. DALTON, A. J. and ZEIGEL, R. F. A simplified method of staining thin sections of biological material with lead hydroxide for electron microscopy. *J. Biophys. & Biochem. Cytol.* 1960, **7**, 409-410.
12. HUTCHISON, H. E. The significance of stainable iron in sternal marrow sections; its application in control of iron therapy. *Blood*, 1953, **8**, 236-248.
13. BESSIS, M., and BRETON-GORIUS, J. Granules ferrugineux observés au microscope électronique dans les cellules de la moelle osseuse et dans les sidérocytes. *Compt. rend. Acad. sc.*, 1956, **243**, 1235-1237.
14. BESSIS, M., and BRETON-GORIUS, J. Incorporation de granules ferrugineux par les érythroblastes, observée au microscope électronique. *Compt. rend. Soc. biol.*, 1956, **150**, 1903-1905.
15. FARRANT, J. L. An electron microscopic study of ferritin. *Biochim. et biophys. acta*, 1954, **13**, 569-576.
16. LILLIE, R. D.; ASHBURN, L. L.; SEBRELL, W. H.; DAFT, F. S., and LOWRY, J. V. Histogenesis and repair of the hepatic cirrhosis in rats produced on low protein diets and preventable with choline. *Public Health Rep.*, 1942, **57**, 502-508.
17. SORENSON, G. D. Unpublished observations.
18. POLICARD, A., and BESSIS, M. Sur un mode d'incorporation des macromolécules par la cellule, visible au microscope électronique: la rophéocytose. *Compt. rend. Acad. sc.*, 1958, **246**, 3194-3197.
19. BESSIS, M., and BRETON-GORIUS, J. Le cycle du fer dans l'organisme révélé par le microscope électronique. *Sem. hôp., Paris, path. et biol.*, 1957, **33**, 2173-2194.
20. RATH, C. E., and FINCH, C. A. Sternal marrow hemosiderin; method for determination of available iron stores in man. *J. Lab. & Clin. Med.*, 1948, **33**, 81-86.
21. DOUGLAS, A. S., and DACIE, J. V. The incidence and significance of iron-con-

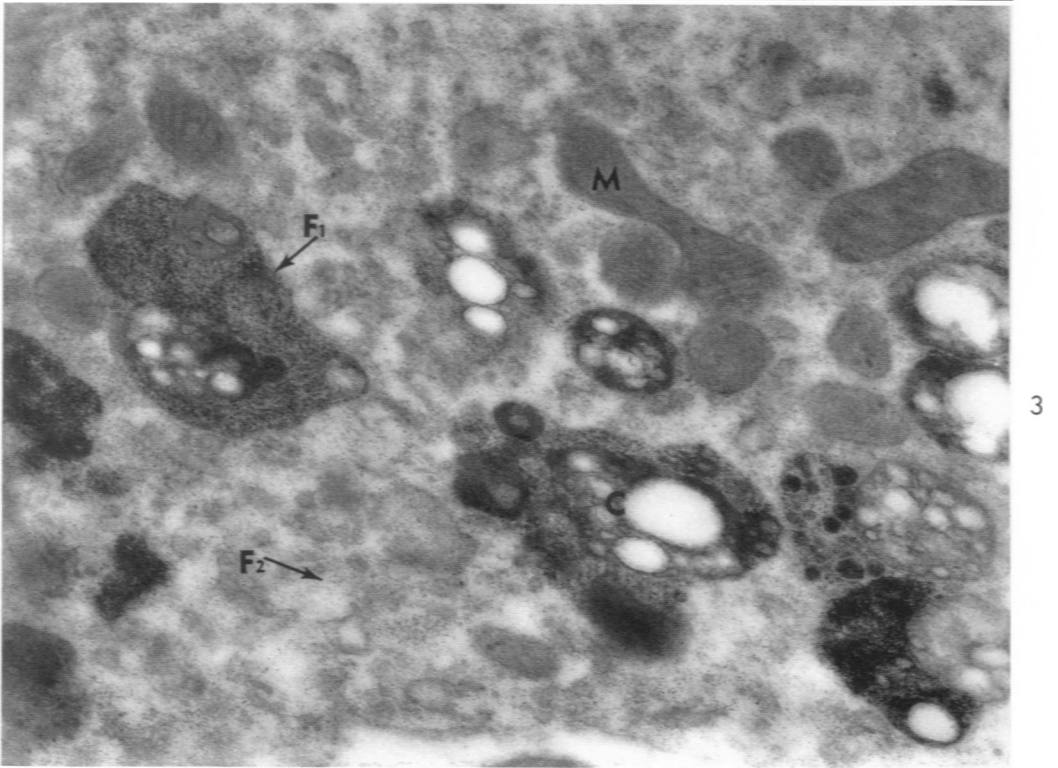
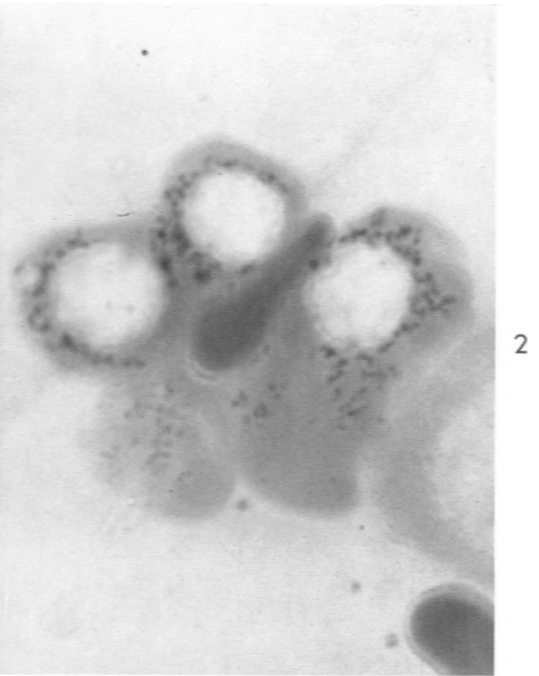
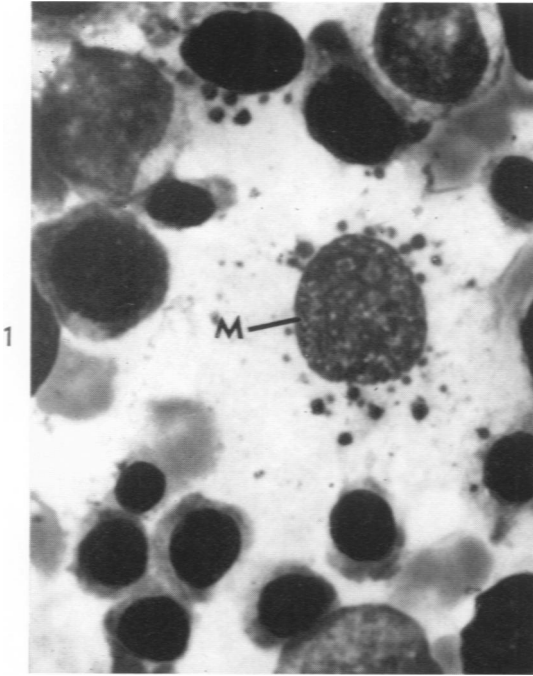


- taining granules in human erythrocytes and their precursors. *J. Clin. Path.*, 1953, 6, 307-313.
22. KAPLAN, E.; ZUELZER, W. W., and MOURIQUAND, C. Sideroblasts; a study of stainable nonhemoglobin iron in marrow normoblasts. *Blood*, 1954, 9, 202-213.
  23. RICHTER, G. W. Electron microscopy of hemosiderin: présence of ferritin and occurrence of crystalline lattices in hemosiderin deposits. *J. Biophys. & Biochem. Cytol.*, 1958, 4, 55-58.
  24. BESSIS, M., and BRETON-GORIUS, J. Différents aspects du fer dans l'organisme. II. Différentes formes de l'hémosidérine. *J. Biophys. & Biochem. Cytol.*, 1959, 6, 237-240.
  25. RICHTER, G. W. The nature of storage iron in idiopathic hemochromatosis and in hemosiderosis. Electron optical, chemical, and serologic studies on isolated hemosiderin granules. *J. Exper. Med.*, 1960, 112, 551-570.
  26. WINTROBE, M. M. *Clinical Hematology*. Lea & Febiger, Philadelphia, 1956, ed. 4, p. 156.
  27. SORENSON, G. D. An electron microscopic study of hematopoiesis in the liver of the fetal rabbit. *Am. J. Anat.*, 1960, 106, 27-40.
  28. POLICARD, A.; BESSIS, M., and BRETON-GORIUS, J. Structures myéliniques observées au microscope électronique sur des coupes de globules rouges en voie de lyse. *Exper. Cell Res.*, 1957, 13, 184-186.
  29. STOECKENIUS, W. An electron microscope study of myelin figures. *J. Biophys. & Biochem. Cytol.*, 1959, 5, 491-500.
  30. NOYES, W. D.; BOTHWELL, T. H., and FINCH, C. A. The role of the reticulo-endothelial cell in iron metabolism. *Brit. J. Haemat.*, 1960, 6, 43-55.
  31. SORENSON, G. D. An electron microscopic study of hematopoiesis in the yolk sac. *Lab. Invest.*, 1961, 10, 178-193.
  32. GRÜNEBERG, H. Siderocytes: a new kind of erythrocytes. *Nature, London*, 1941, 148, 114-115.
  33. GRÜNEBERG, H. Siderocytes in man. *Nature, London*, 1941, 148, 469-470.
  34. RIMINGTON, C. Connaissances récentes sur la biosynthèse des porphyrines et de l'hème. *Rev. hémat.*, 1957, 12, 591-597.
  35. SANO, S.; INOUE, S.; TANABE, Y.; SUMIYA, C., and KOIKE, S. Significance of mitochondria for porphyrin and heme biosynthesis. *Science*, 1959, 129, 275-276.
- 

[ Illustrations follow ]

## LEGENDS FOR FIGURES

- FIG. 1. Bone marrow film. A central macrophage (M) with many cytoplasmic inclusions (many of these represent hemosiderin) is surrounded by immature erythroid cells. Wright stain.  $\times 2,000$ .
- FIG. 2. Bone marrow film stained with the Perls (Prussian blue) reaction. The numerous fine, dark cytoplasmic foci in erythroblasts represent iron granules.  $\times 4,000$ .
- FIG. 3. A portion of macrophage cytoplasm containing mitochondria (M), ferritin in clumps ( $F_1$ ) and diffusely distributed ( $F_2$ ), and dense inclusions with numerous holes or vacuoles which may be ceroid (C).  $\times 30,000$ .



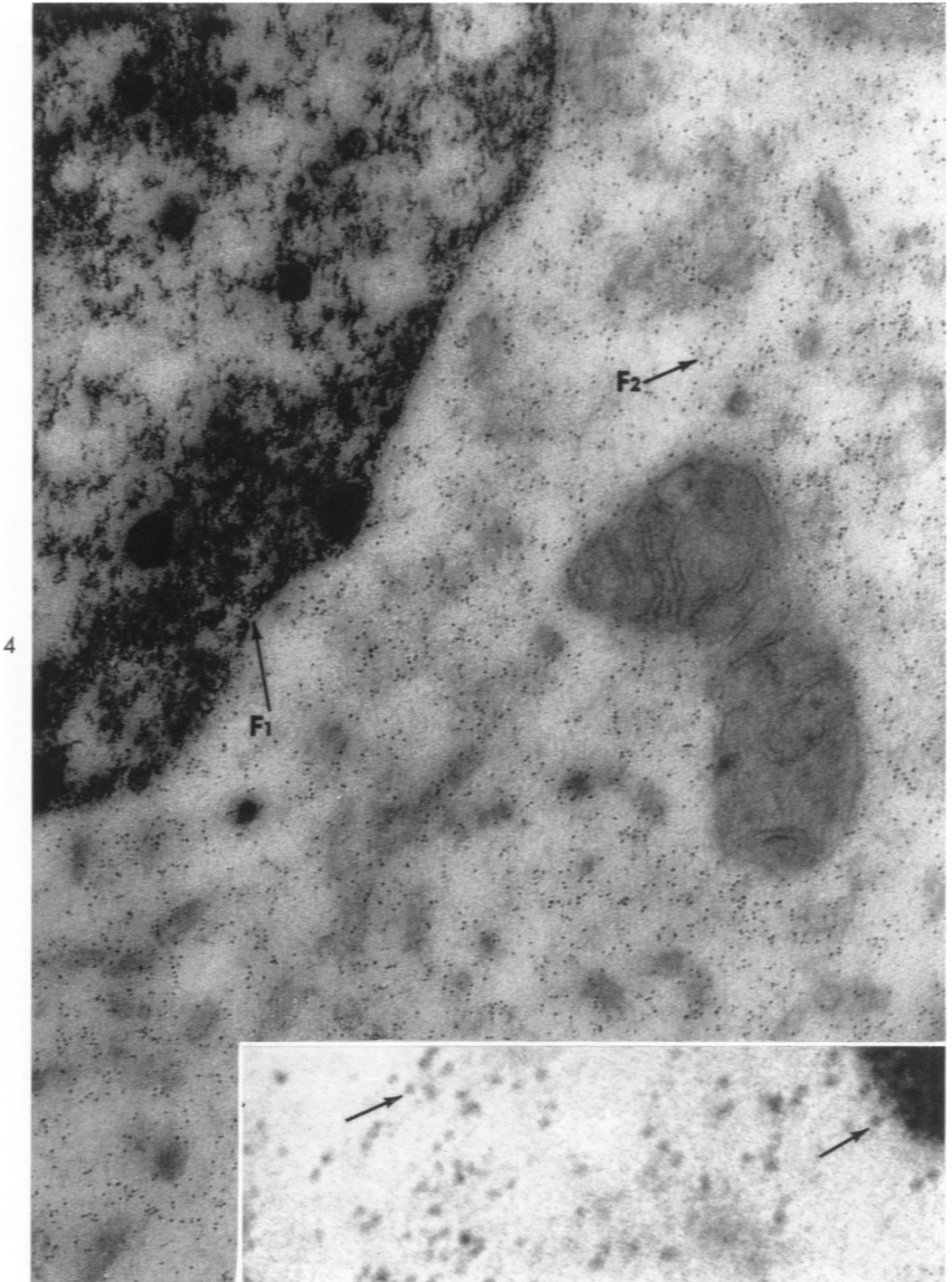
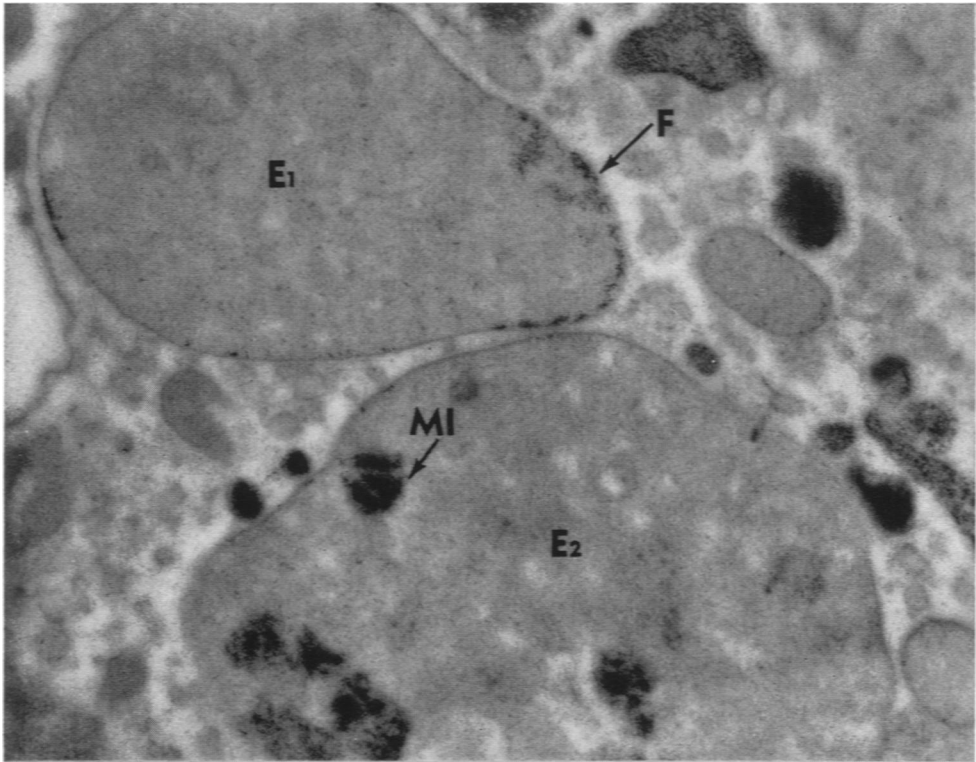
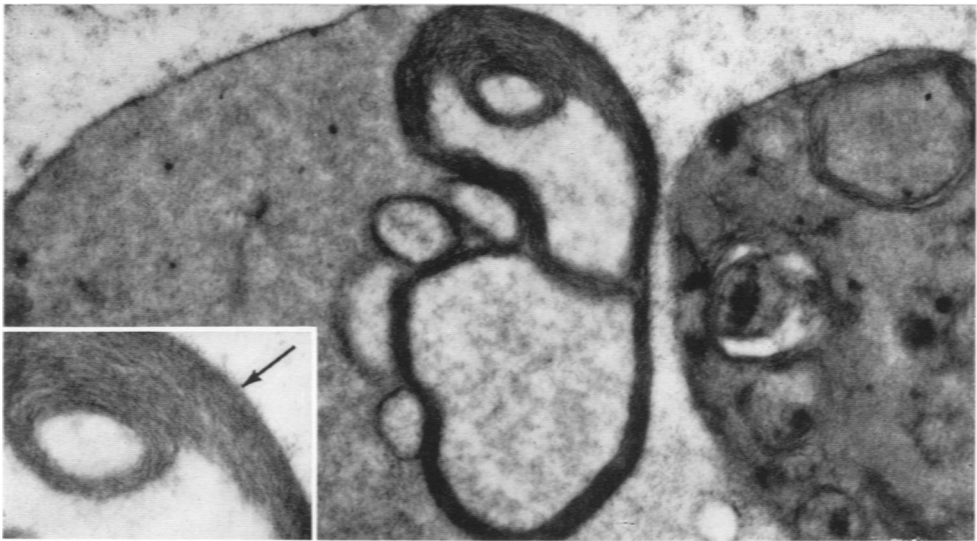


FIG. 4. Another macrophage containing clumped ( $F_1$ ) and free ferritin ( $F_2$ ). Each electron-dense spot indicates a molecule of ferritin.  $\times 72,000$ . Insert at greater magnification demonstrates the characteristic multiple dense foci which represent accumulations of iron within each molecule of ferritin.  $\times 300,000$ .



5



6

FIG. 5. Cytoplasm of a macrophage contains two disintegrating erythrocytes ( $E_1$ ,  $E_2$ ). Ferritin (F) is concentrated about the periphery of  $E_1$ ; dense foci within  $E_2$  constitute mitochondrial iron (MI). In the latter, separate clumps represent compartmentalization of the iron produced by the mitochondrial cristas.  $\times 25,000$ .

FIG. 6. A macrophage contains disintegrating erythrocytes: within and about these are lamellar membrane formations. These are probably produced from the lipoprotein in the red cell.  $\times 23,000$ . *Insert:* The numerous lamellas within the membrane formations or myelin figures are clearly demonstrated.  $\times 36,000$ .

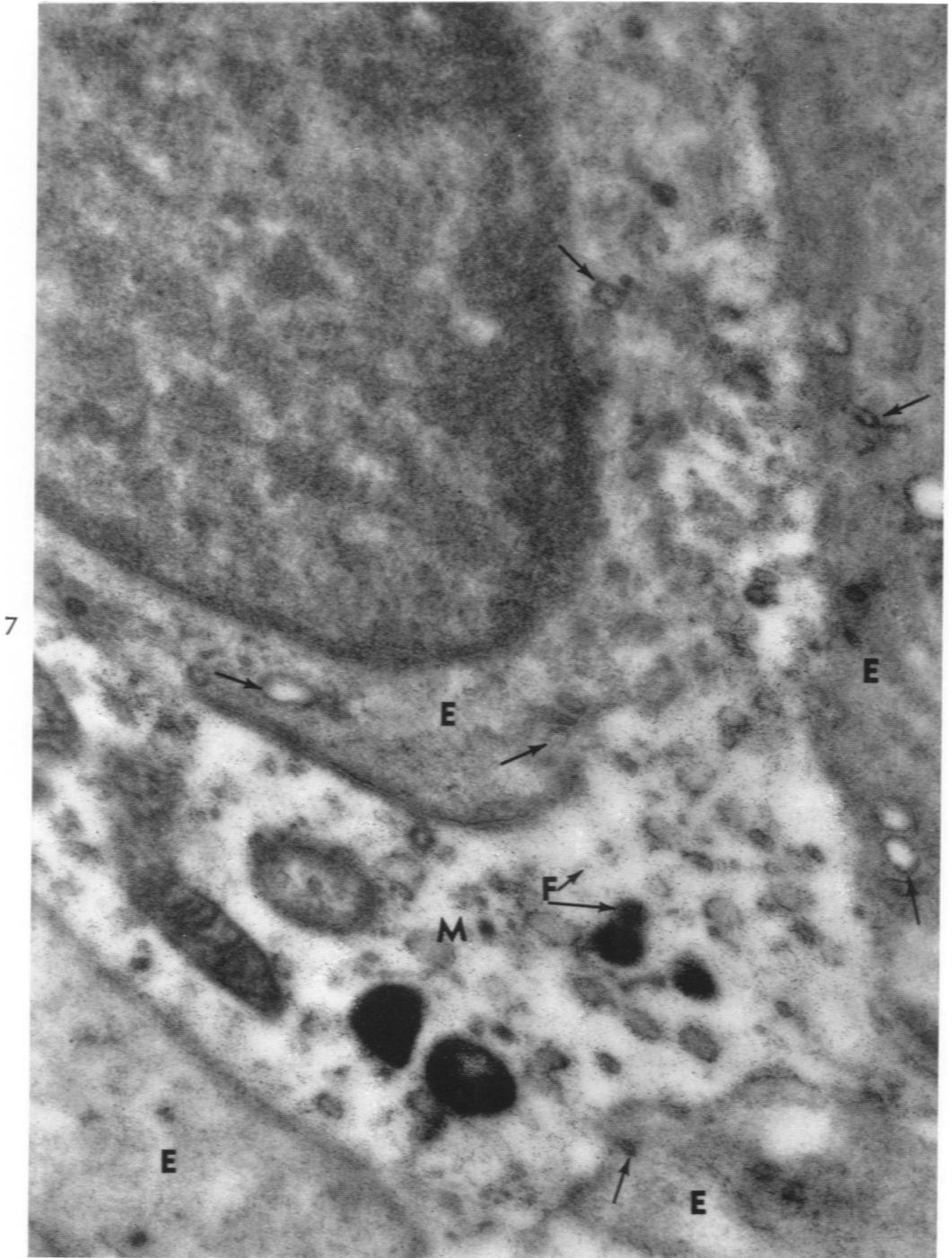
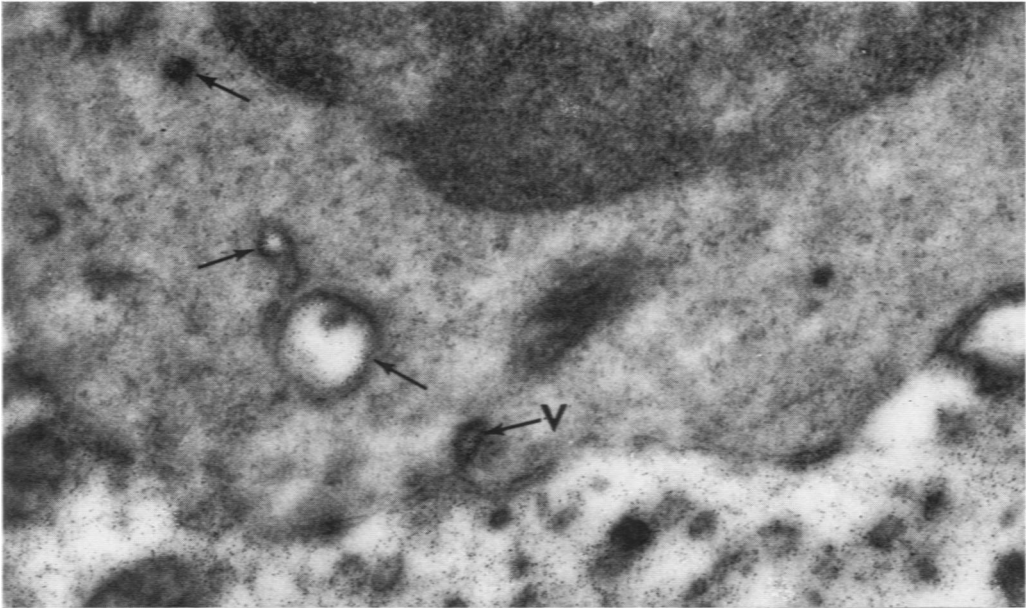
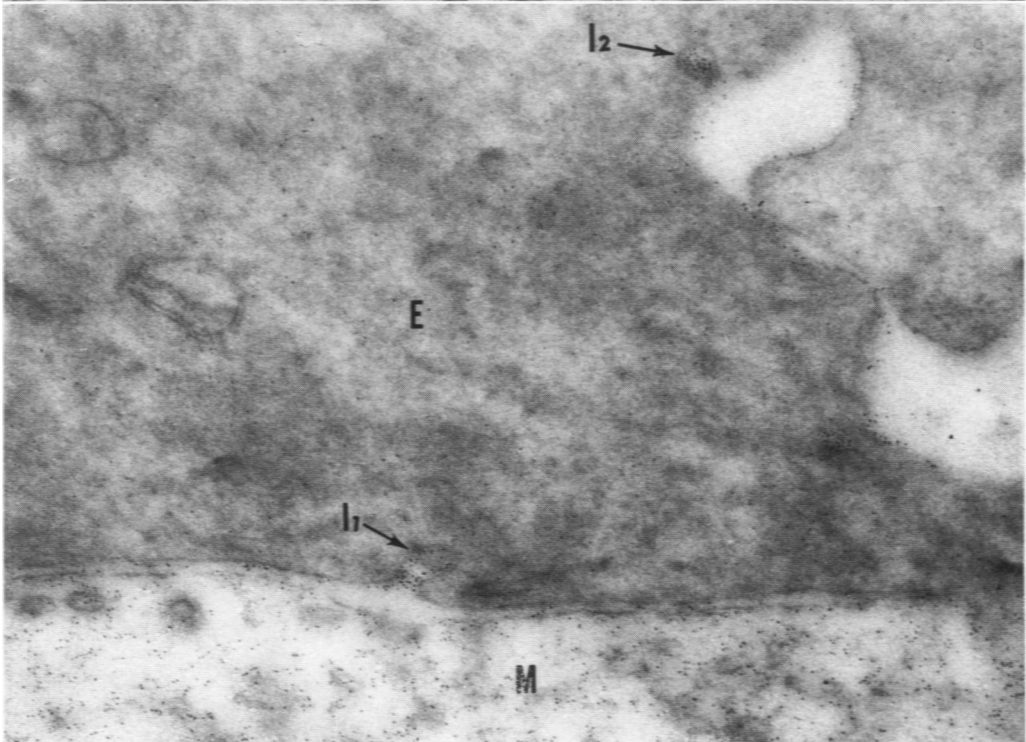


FIG. 7. A portion of macrophage (M) is surrounded by erythroblasts (E). The former contains much ferritin (F). In the erythroblast cytoplasm adjacent to the macrophage there are numerous vesicles containing ferritin (arrows). The ferritin has passed into the erythroblasts from the adjacent macrophage.  $\times 31,000$ .



8



9

FIG. 8. Adjacent portions of a macrophage and an erythroblast. Several vesicles in the erythroblast contain ferritin (arrows), and one (V) is just within the plasma membrane.  $\times 41,000$ .

FIG. 9. Parts of macrophage (M) and erythroblast (E) cytoplasm. Ferritin is contained within invaginations ( $I_1$ ,  $I_2$ ) of the erythroblast plasma membrane. One invagination ( $I_2$ ) is apparently at a distance from the margin of any macrophage.  $\times 65,000$ .

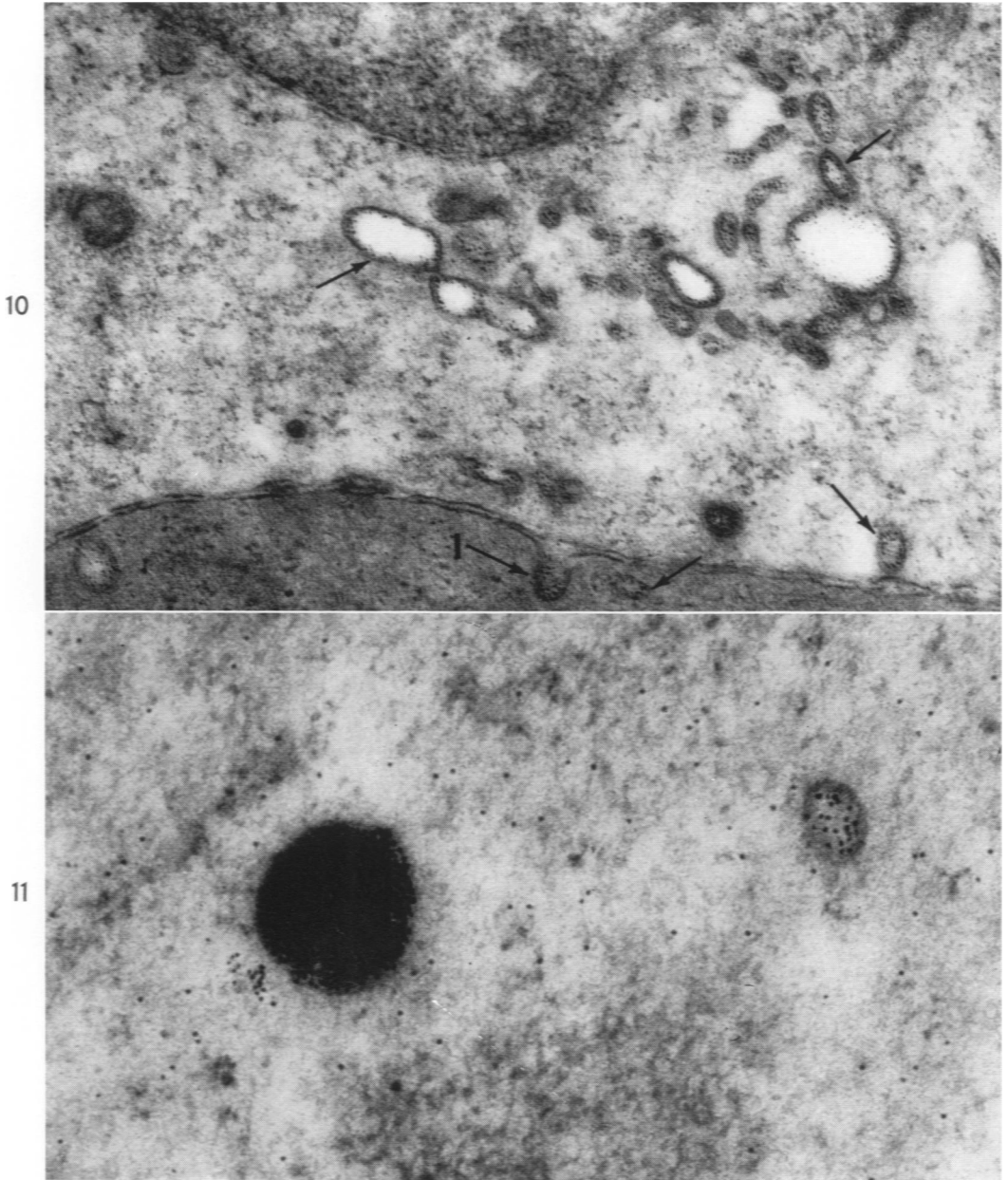
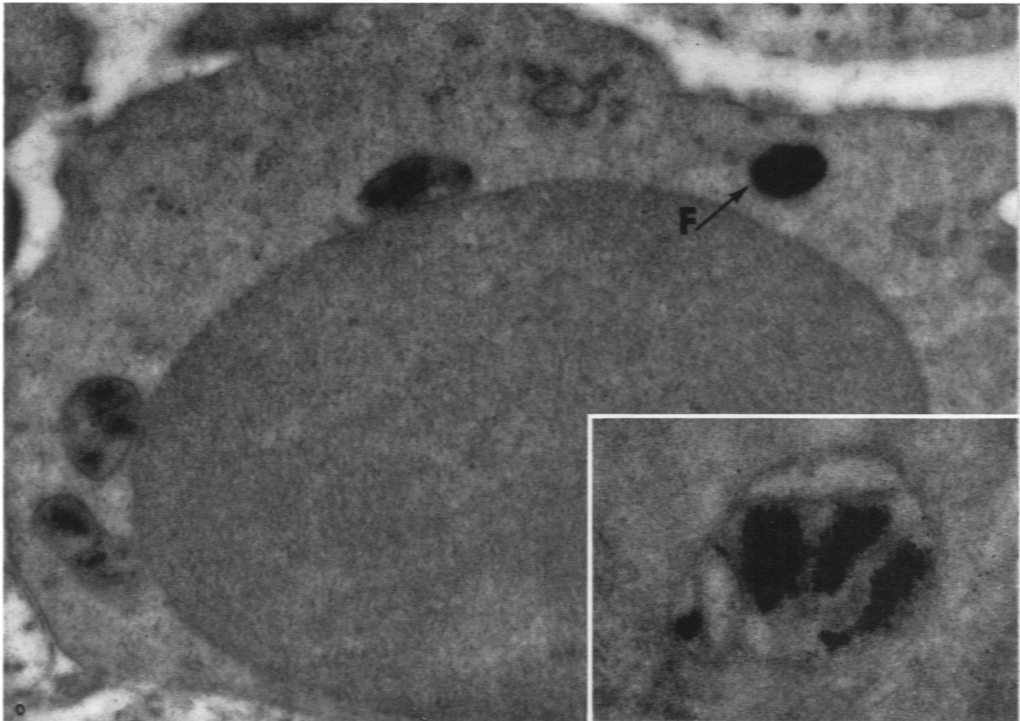


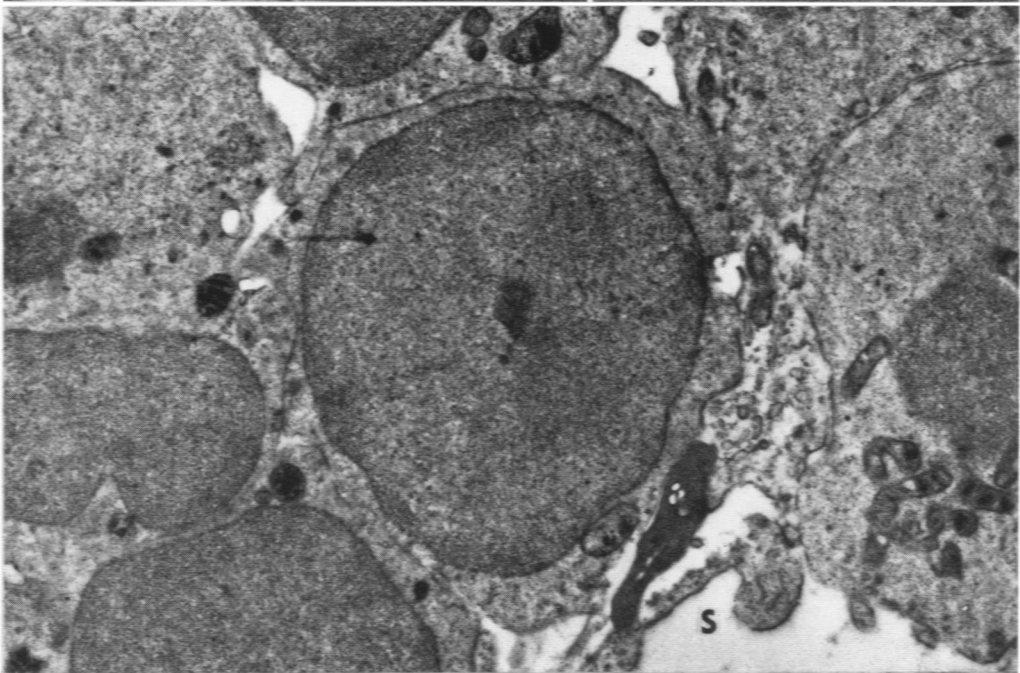
FIG. 10. Erythroblasts with ferritin within an invagination (I) of one of the plasma membranes and contained within vesicles (arrows) in the cytoplasm of both cells.  $\times 56,000$ .

FIG. 11. Ferritin in an erythroblast. Some of the ferritin is clumped, some is within a vesicle, and some is free in the cytoplasm.  $\times 80,000$ .





12



13

FIG. 12. Erythroblast with a clump of ferritin (F) surrounded by a single membrane and several mitochondria containing iron.  $\times 21,500$ . *Insert*: An erythroblast mitochondrion which contains iron separated into clumps by mitochondrial cristas.  $\times 65,000$ .

FIG. 13. A survey electron micrograph illustrates numerous erythroid cells with iron in their mitochondria. S = sinus.  $\times 16,000$ .

14

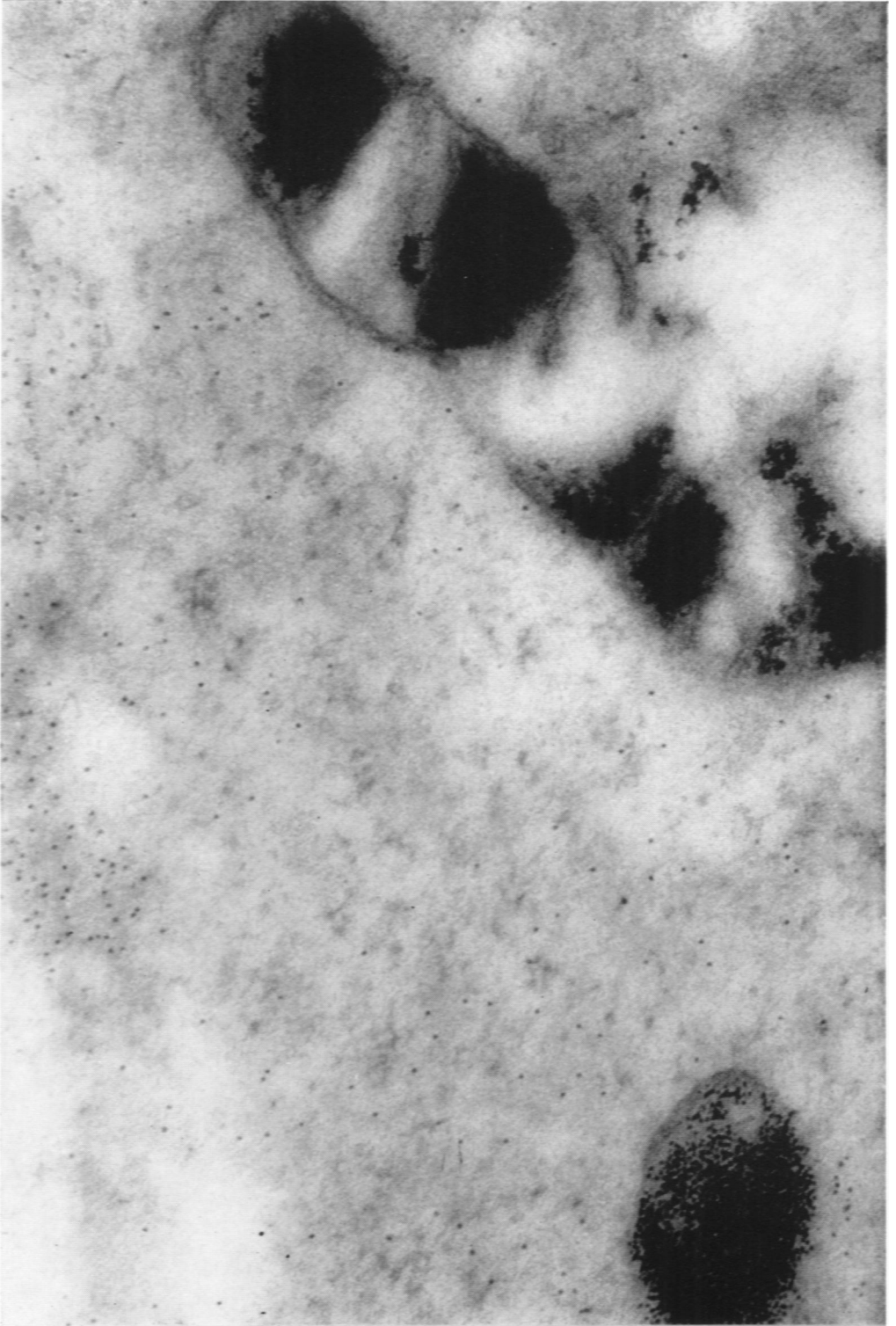

FIG. 14. An erythroblast contains mitochondrial iron which appears more finely dispersed than the rather coarsely granular clumped ferritin.  $\times 100,000$ .