

the amount of equipment in the vicinity of the operating-table.

I am grateful to Professor D. W. Smithers, director of the department of radiotherapy, for encouraging me to develop this monitoring technique. My thanks are also due to Drs. K. W. Taylor and J. B. N. Stedford, of the physics department, for their help in assembling the electronic equipment.

REFERENCES

- Austen, W. G., and Raker, J. W. (1960). *Cancer Chemother. Rep.*, **10**, 61.
 Garai, O. F., Cooling, C. I., and Staunton, M. D. (1962). *Brit. med. J.*, **1**, 1231.
 Stehlin, J. S., Clark, R. L., White, E. C., Healey, J. E., Dewey, W. C., and Beerstecher, S. (1960). *Arch. Surg.*, **80**, 934.
 ——— and Dewey, W. C. (1961). *Ibid.*, **83**, 943.

RECURRENT CANCER OF HEAD AND NECK

TREATMENT WITH CONTINUOUS INTRA-ARTERIAL METHOTREXATE AND INTERMITTENT INTRAMUSCULAR CITROVORUM FACTOR

BY

G. WESTBURY, F.R.C.S., M.R.C.P.

Consultant Surgeon

J. G. HUMBLE, C.V.O., M.R.C.P.

Consultant Haematologist

D. E. PEGG,* M.B., B.S.

Lecturer in Haematology

AND

K. A. NEWTON, M.R.C.P., F.F.R.

Consultant Radiotherapist

H. T. FORD, M.B., B.S., F.F.R.

Senior Registrar, Radiotherapy Department

W. F. WHITE, M.B., B.S.

Senior House Officer, Radiotherapy Department

Westminster Hospital, London

[WITH SPECIAL PLATE]

Administration of cytotoxic agents directly into the artery of a tumour-bearing area was first described by Klopp and his colleagues (1950), who used fractionated doses of nitrogen mustard (HN₂). They showed that changes could be produced in normal and neoplastic tissues that were not achieved by intravenous injection even of lethal amounts of the drug. Spill-over into the general circulation did, however, produce moderate depression of haemopoiesis, and the authors suggested, among other methods, that systemic toxicity might be reduced by an antagonist given intravenously at the time of each intra-arterial injection. Sullivan *et al.* (1959), applying this principle, reported the use of continuous intra-arterial infusion of lethal doses of an antimetabolite together with the intermittent intramuscular administration of the specific metabolite as an antidote. They described remarkable regression of advanced tumours of the head and neck with intra-carotid infusion of methotrexate (4-amino-N¹⁰-methyl-pteroyl glutamic acid; amethopterin), a folic-acid analogue which interferes with the participation of folic acid in nucleic-acid synthesis; citrovorum factor (folic acid; leucovorin) was given in amounts sufficient to minimize systemic toxicity, but not to compete entirely with the high concentrations of antimetabolite in the carotid territory.

The present paper relates our experience with this method of therapy in a group of patients with inoperable malignant tumours of the head and neck, all of whom had been heavily treated with one or more courses of supervoltage radiotherapy. It was anticipated that delayed irradiation effects, in particular endarteritis, might reduce the efficacy of intra-arterial therapy, but it was not thought justifiable at this stage to use a new technique of treatment before giving patients the benefit of radiotherapy and/or surgery, methods known to be capable of achieving control of disease for many years. This problem is further considered in the discussion.

*In receipt of a full-time grant from the British Empire Cancer Campaign during the period of this study.

Material

Since July, 1960, 26 cases have been treated. Two of these received a second infusion after 9 and 11 months respectively. The lesions treated included 3 carcinomas of tongue, 1 carcinoma of lip, 11 carcinomas of buccal mucosa and alveolus, 4 carcinomas of palate, antrum, or ethmoid, 2 carcinomas of tonsillar fossa, 2 primary skin carcinomas, 2 rhabdomyosarcomas of mouth and orbit respectively, and 1 fibrosarcoma of parotid region. The youngest patient was aged 7 and the oldest 87 years. All patients, as stated, had received supervoltage radiotherapy in radical dosage. Seven cases had been treated twice, one three times, and one at least five times over some years. In 12 cases local or radical excision of the primary lesion had been performed; two patients had undergone multiple surgical procedures. Four patients had had block dissection of cervical lymph nodes. Case 13 is a typical example. This 66-year-old man with carcinoma of the buccal mucosa was treated by implantation of radium needles in September, 1959, to a dose of 8,000 r in seven days. A local recurrence was treated in March, 1960, with the 15-curie telecobalt unit to 5,592 r in 41 days, and in June, 1960, hemimandibulectomy and block dissection of the neck in continuity was performed. Further local recurrence failed to respond to an implant of gold grains in November, 1960, and the patient was presented for infusion therapy in March, 1961.

Details of the 26 cases are given in the Table.

Method

In most cases the tumour lay within the territory of supply of the external carotid artery, which was usually cannulated via its superior thyroid branch (Klopp *et al.*) exposed through a short incision at the level of the hyoid bone. Polyvinyl chloride ("portex") tubing was employed, being easier to secure than polyethylene, as it is soft enough to take the bite of the encircling ligatures; a modified No. 6 F.G. umbilical

G. WESTBURY *ET AL.*: TREATMENT OF RECURRENT CANCER OF HEAD AND NECK

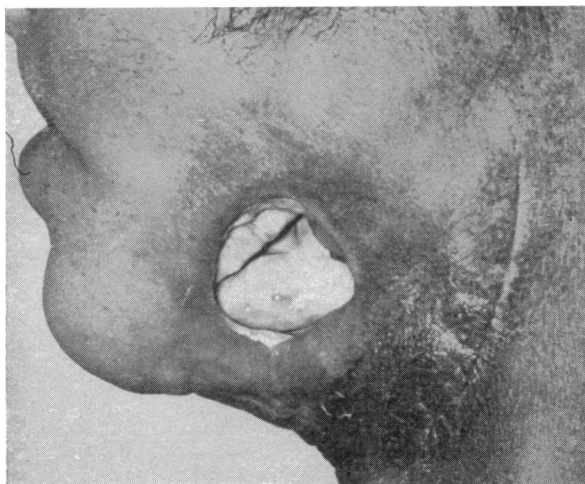


FIG. 1.—Before treatment.

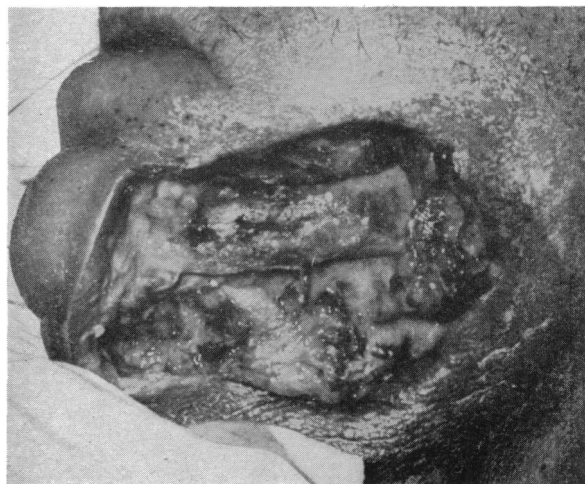


FIG. 2.—After treatment.

FIGS. 1 and 2.—Case 4. Extensive necrosis following intra-arterial infusion of methotrexate.

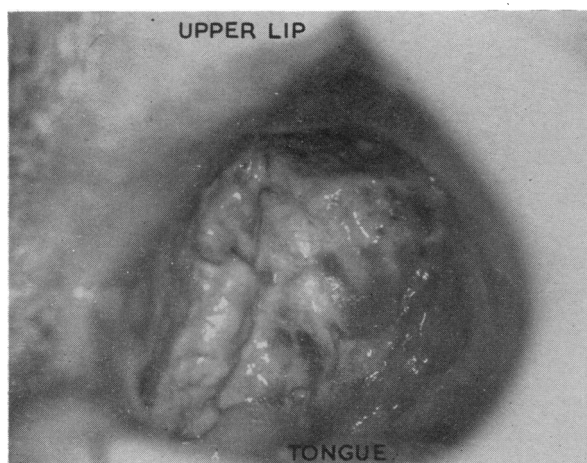


FIG. 3.—Before treatment.

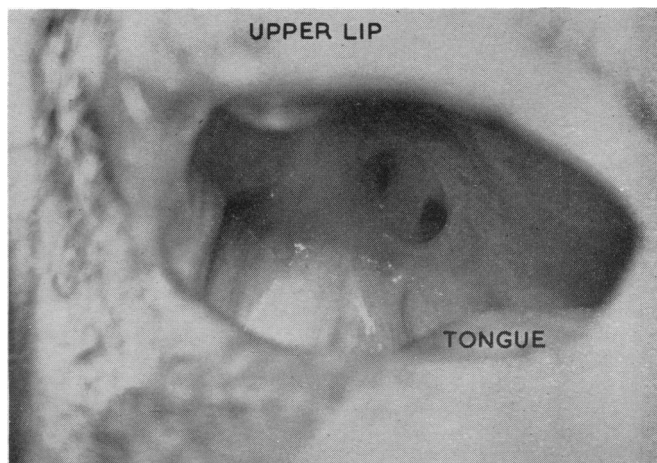


FIG. 4.—After treatment.

FIGS. 3 and 4.—Case 23. Recurrent carcinoma of palate treated with methotrexate.

A. R. GHANI AND D. J. TIBBS: BLOOD-BORNE CELLS AND MURAL THROMBI

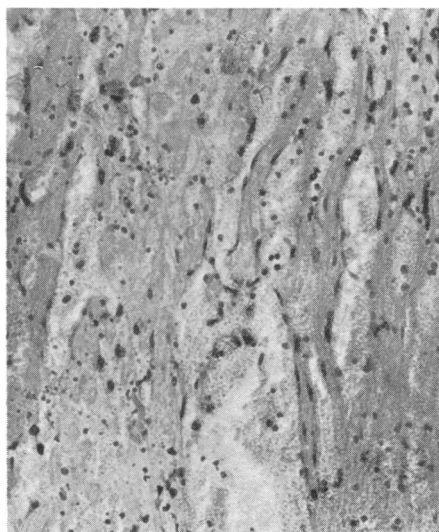


FIG. 1.—Sinuses lined by endothelial-like cells at 28 days. (x66.)

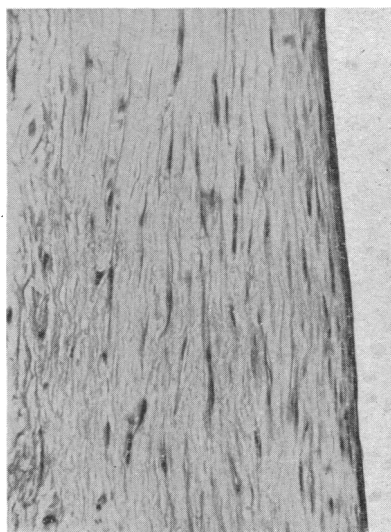

FIG. 2.—Appearance of fully organized mural thrombus at 21 weeks. (H. and E. x66.)

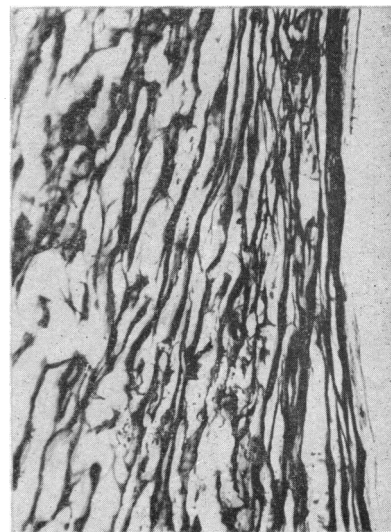

FIG. 3.—Reticulin network shown by silver stain in 21-week preparation. (x66.)

Summary of 26 Cases of Recurrent Cancer of Head and Neck Treated with Methotrexate

Case No.	Age and Sex	Diagnosis	Previous Therapy	Artery Catheterized	Methotrexate Dosage (mg. : days of Infusion)	Complications and Toxicity	Tumour Response	Pain Relief
1	23 M	Rhabdomyosarcoma R. cheek	Surg.; irradi.	(i) R. ext. carotid (ii) R. common carotid; L. ext. carotid	125 : 5 510 : 8	Nil Secondary haemorrhage. Transient L. hemiplegia x2	Partial "	Tumour painless " "
2	77 F	L. cervical nodes from carcinoma tongue	Irrad.	L. ext. carotid	311 : 9	Pulmonary embolus	Nil	Partial
3	7 F	Fibrosarcoma R. parotid region	Surg.; irradi.	R. " "	156 : 8	Extravasation into neck. W.B.C. 1,750 per c.mm.	"	Tumour painless
4	65 M	L. cervical nodes from carcinoma of lip	Irrad.	L. " "	194 : 7	Tissue necrosis. Extension of fistula	Partial	Partial
5	76 M	Carcinoma R. buccal mucosa and alveolus	"	R. " "	200 : 9	Transient hemiplegia	"	Complete
6	53 M	Carcinoma R. buccal mucosa	Surg.; irradi.	" " "	320 : 9	Nil	Nil	"
7	64 M	Carcinoma L. posterior third of tongue	Irrad.	L. " "	157 : 7	"	"	Partial
8	54 F	Carcinoma L. antrum	Surg.; irradi.	" " "	210 : 6	W.B.C. 1,700, platelets 73,000 per c.mm.	Partial	Complete
9	87 M	Carcinoma R. lower alveolus	Irrad.	R. " "	236 : 9	Pneumonia	Complete	"
10	10 M	Rhabdomyosarcoma R. orbit	Surg.; irradi.	R. int. "	162 : 14	Transient hemiplegia due to manip. of drip. W.B.C. 1,800. Platelets 100,000 per c.mm.	Nil	Tumour painless
11	70 F	Multicentric carcinoma of mouth with nodes and deposit in R. chin	Irrad.	Bilateral ext. carotid	345 : 12	W.B.C. 1,600, platelets 72,000 per c.mm.	Partial	Partial
12	54 M	Carcinoma R. upper buccal sulcus	Surg.; irradi.	R. ext. carotid	500 : 14	Fistula formation	"	Complete
13	66 M	Carcinoma L. buccal mucosa	"	L. " "	217 : 8	Nil	Nil	"
14	33 M	Carcinoma L. tonsillar fossa	Irrad.	" " "	255 : 9	Secondary haemorrhage from tumour	"	Nil
15	52 F	Carcinoma nose involving lip	Surg.; irradi.	(i) R. ext. carotid (ii) " " "	252 : 9 487.5 : 14	Nil	Complete Nil	Complete "
16	60 F	Carcinoma R. lower alveolus with cervical nodes	Irrad.	R. ext. carotid	170 : 7	"	"	Partial
17	58 M	Carcinoma L. tonsillar fossa	"	L. " "	412 : 20	"	Partial	Complete
18	70 F	Carcinoma L. floor of mouth with cervical nodes	Surg.; irradi.	" " "	812 : 21	W.B.C. 1 200 per c.mm.	"	"
19	67 M	Carcinoma L. ethmoid involving orbit and antrum	"	L. common carotid	280 : 7	Bronchopneumonia. W.B.C. 1,230 per c.mm.	"	"
20	67 F	Carcinoma of palate. Bilat. antrum with cervical nodes	"	Bilateral ext. carotid	330 : 6	Hemiplegia same side as infusion. Bronchopneumonia	Nil	"
21	53 M	Carcinoma R. buccal mucosa	"	R. ext. carotid	437 : 9	Vagus cut. Pyrexia	Partial	"
22	54 M	Basal-cell carcinoma L. face	"	L. " "	600 : 15	Wound infection	"	"
23	78 M	Carcinoma of palate and R. buccal mucosa	"	R. " "	606 : 11	Secondary haemorrhage. Hemiplegia. W.B.C. 2,000, platelets 50,000 per c.mm.	Complete	"
24	63 M	Carcinoma of floor of mouth and R. bucco-alveolar sulcus	"	" " "	400 : 8	Fever and rigors Bronchopneumonia	Partial	Partial
25	48 M	Carcinoma L. tonsil with cervical nodes	Irrad.	L. " "	400 : 8	Nil	"	"
26	51 M	Carcinoma L. tongue and floor of mouth	Surg.; irradi.	" " "	787 : 11	Necrosis of half tongue. Fever and rigors	Complete in area infused	Complete

Dosage of citrovorum factor, 6 mg. six-hourly (see text).

catheter has proved satisfactory (Espiner, 1961). It is essential to check the position of the catheter tip, which cannot easily be palpated within the vessel and may even inadvertently enter the internal carotid. Arteriography, used in the early cases, has been replaced by the gentle instillation of a few millilitres of 5% fluorescein, viewing the area supplied in ultra-violet light (Duff *et al.*, 1961). This method has the advantages of speed and simplicity, and, moreover, avoids possible artifacts produced by the necessarily forcible injection of contrast medium. Occasionally—for example, in a second perfusion—the catheter must be implanted directly into the external carotid artery. The method of fixation is that described by Duff and his colleagues, whose paper should be referred to for details.

Retrograde catheterization of the external carotid via the superficial temporal artery, exposed in front of the pinna, was attempted in seven patients. In three of these the tubing could not be passed beyond the level of the zygomatic arch. In a third patient transient hemiplegia followed flushing of the blocked catheter, presumably due to ejection of the clot down into the common carotid artery and thus into the internal carotid. This route may, however, be the only one possible where the cervical lymph nodes are massively involved, and is perhaps particularly indicated where the primary lesion

lies in the area of distribution of the maxillary artery. The tip of the catheter may be positioned by infusing fluorescein as it is slowly advanced until the area of the tumour is outlined. In one patient with a rhabdomyosarcoma of the orbit the internal carotid was infused by introducing the catheter into the proximal stump of the divided external carotid artery. The common carotid artery was cannulated directly in one patient with carcinoma of the ethmoid involving the antrum and orbit, in whom an attempt at retrograde introduction through the superficial temporal artery had failed. The common carotid was also cannulated in a second patient with rhabdomyosarcoma of the mouth whose external carotid had thrombosed after a previous infusion; this was supplemented by infusion through the contralateral external carotid after proving with fluorescein that both vessels contributed to the supply of the tumour.

The daily dose of methotrexate is given usually in 2 l. of dextrose-saline solution by means of a long transfusion-giving set, raising the bottle sufficiently to exceed the patient's arterial pressure. A second bottle is placed in tandem to prevent reflux of blood should the first bottle run out unnoticed. Fluid overloading must be avoided, especially when performing bilateral infusions (three patients), in children, or in the old and

frail patient. A drip chamber embodying a 0.7-mm. needle transmitting small drops of fluid has facilitated regulation of the drip rate and reduced the daily volume to 500 ml. We have not employed pumps, though this method may have its place where the patient has hypertension of such a degree as to make a gravity feed impracticable. On completion of the infusion the catheter is removed by firm traction and the site of exit compressed for five to ten minutes.

Dosage

Almost all the patients were given *citrovorum* factor at a standard dose of 6 mg. six-hourly intramuscularly, starting on the morning of methotrexate infusion and carrying on for 48 hours after the infusion had been stopped. In four patients whose white blood count fell sharply the dose was increased to 9 mg. six-hourly. The dose rate of methotrexate and duration of treatment varied considerably. Great caution was exercised in the early cases for fear of producing necrosis in tissues already damaged by previous therapy; Special Plate, Figs. 1 and 2 illustrate this complication in a man who received 194 mg. of methotrexate in seven days (Case 4). Marked buccal mucositis and tumour response were seen at this dose level, but incomplete regression and early relapse of disease led us to increase the dose of methotrexate in the later cases, usually to 50 mg. daily. A course of treatment was continued until severe leucopenia (or technical complications) supervened. As confidence in management of this type of case was gained, methotrexate infusion was resumed, after several days' pause for bone-marrow recovery, along the lines advised by Sullivan *et al.* (1960), the cannula being kept open meanwhile with dextrose-saline. When neither buccal nor bone-marrow toxicity was produced at this dose rate, the daily dose of methotrexate was raised to 75 or even 100 mg. for a few days. The longest over-all period of treatment was 21 days, and the highest total dose of methotrexate in the same patient 812.5 mg. Where simultaneous bilateral infusion was required (three patients) the combined daily dose of methotrexate did not exceed 60 mg.

Results

In assessing results our principal criterion of anti-tumour effect has been decrease in the size of the lesion. On this basis 18 patients showed some objective regression; this varied from partial shrinkage to complete clinical disappearance of tumour (Special Plate, Figs. 3 and 4). Lessening of fetor and improvement in trismus were early accompaniments of tumour response, which was seen as early as the third day. In three cases only was complete clinical regression achieved at any stage; one patient remains clinically free from disease five months after infusion (Case 23); an 87-year-old man showed no sign of recurrence up to the time of death from intercurrent bronchopneumonia two and a half months after infusion (Case 9); tumour recurred in the third patient (Case 15) three months after therapy and failed to respond to a second infusion. Case 26 showed complete tumour regression in the area infused, but part of the lesion extending across the midline was unaffected. Relief of pain, sometimes rapid and dramatic, was seen in all but one patient. Pain sometimes returned after discontinuing the infusion, but in other instances relief was maintained surprisingly even

in the presence of advancing local disease. Of the three mesodermal lesions in the group, the rhabdomyosarcoma of the mouth (Case 1) responded partially and transiently; the rhabdomyosarcoma of the orbit (Case 10) and the fibrosarcoma of the parotid area (Case 3) showed no response.

Side-effects of Methotrexate

Local

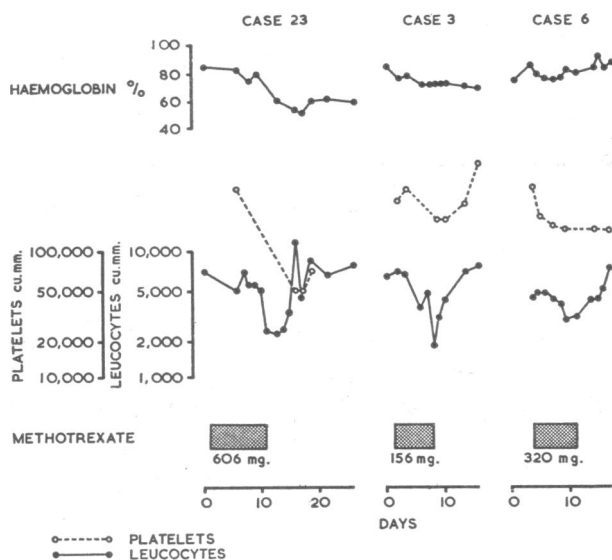
A mucosal reaction on the palate, buccal epithelium, alveolus, and tongue on the treated side was seen in six cases. This mucositis, starting as a patchy erythema, proceeded to the formation of discrete yellow plaques surrounded by an intense red margin, finally coalescing to produce, in its fully developed form, a confluent yellow film closely resembling that produced by irradiation. These patients complained of sore mouth and dysphagia. We regard mucositis as a desirable indication of an adequate biological effect of methotrexate on the target area; it was produced in those three patients mentioned in whom complete tumour regression occurred. Three patients showed a skin reaction in the infused area. This consisted of erythema leading to brawny desquamation. It is possible that photosensitivity played a part in the production of this rash, since the affected areas were exposed to sunlight during the infusion. In one patient the infused half of the tongue underwent complete necrosis; the slough subsequently separated without incident. In Case 4, already referred to, with an established fistula through the floor of the mouth, infusion was followed by extensive spreading necrosis of the tissues around the fistula. Generalized buccal ulceration and intestinal lesions due to methotrexate were not seen.

Haematological

Leucopenia of 2,000 cells per c.mm. or less occurred on seven occasions; leucocyte counts below 1,000 per c.mm. were not encountered. The production of leucopenia was not related to variation in the dose of methotrexate or to the rate of its administration. Depression of the leucocyte count to 2,000 per c.mm. never occurred earlier than five days from the beginning of treatment, and recovery was always rapid when the treatment was discontinued.

Depression of the platelet count tended to occur at about the same time as the leucopenia or a little later, and depression to 100,000 per c.mm. or less was encountered in four patients, who also experienced leucocyte depression to below 2,000 per c.mm. Again, recovery was rapid as soon as the infusion was discontinued, and overt haemorrhagic complications were not seen. As with the leucopenia, there was no relation to total drug dosage or rate of administration.

The level of haemoglobin was unaltered by the treatment in all patients except Case 23 (see Chart). This patient had the lowest platelet count in the series (50,000 per c.mm.), and the fall in haemoglobin level may have been a manifestation of platelet deficiency. A more typical example of haemopoietic depression is seen in Case 3, and for comparison the peripheral blood findings in Case 6 are shown; this patient had twice as much methotrexate in approximately the same period and showed only moderate depression of the leucocyte and platelet counts.



Showing effect of methotrexate therapy on blood picture.

Surgical Complications and Mortality

The presence of an indwelling intra-arterial catheter, often in the neighbourhood of an infected primary lesion, is attended by a number of hazards. Of these complications directly associated with cannulation, the commonest in this series was infection, in all cases due to *Staphylococcus pyogenes*. Five patients developed swinging fever, sometimes with rigors, and resolving only on removal of the catheter. In two of these patients secondary haemorrhage followed within a few days of withdrawal of the catheter. In one patient this was fatal; bleeding was controlled in the other by ligation of the common, external, and internal carotid arteries. One further patient developed a staphylococcal wound infection without systemic effects, and infusion was continued for the desired time uneventfully.

Neurological complications resulting directly from surgical interference with the carotid arteries were seen in three patients. Reference has already been made to transient hemiplegia following clearing of a blocked superficial temporal catheter with saline; this patient was subsequently reinfused via the common carotid artery and suffered a further temporary episode of hemiplegia before his death from secondary haemorrhage. Transient hemiplegia occurred in Case 10 after manipulation of a catheter whose tip lay in the internal carotid artery. In Case 23 hemiplegia followed ligation of the carotid arteries to control secondary haemorrhage; paralysis has partially recovered, but there is residual weakness of the upper limb.

External leakage of fluid occurred in one patient; extravasation into the neck led to premature discontinuation of the infusion in another. There was no instance of catheter blockage which could not be cleared. Complications not directly related to cannulation were seen in seven patients, all elderly. Four developed bronchopneumonia, leading to death in one patient and premature discontinuation of the infusion in three others. Lesser respiratory infection occurred in two further cases. The patient who died from bronchopneumonia had become hemiplegic (on the same side as the cannulation) on the first post-operative day. Transient hemiplegia occurred in one further case in which the contralateral external carotid was cannulated;

though this also may have been due to cerebral thrombosis, it is impossible to exclude operative manipulation of the carotid bulb with mural thrombosis and subsequent embolism as the cause of the neurological lesion. Fatal pulmonary embolus occurred in one patient. The three deaths in the series were due respectively to haemorrhage from the common carotid artery, massive pulmonary embolus on the fourteenth post-operative day, and bronchopneumonia following post-operative thrombosis.

Discussion

Study of this small group of patients confirms that methotrexate infused intra-arterially can produce regression of epithelial tumours of the head and neck. Moreover, regression has been achieved in lesions recurring after or primarily resistant to intensive irradiation. It is disappointing that regression in most cases has been incomplete, and, in fact, in one patient only out of 26 does freedom from disease persist more than three months after treatment. It has already been suggested that the effectiveness of intra-arterial therapy might be impaired by irradiation changes in the vascular bed of the tumour, and it would be reasonable to anticipate better results in unirradiated patients. We do not, however, feel that the results so far obtained by ourselves and others warrant the widespread use of intra-arterial chemotherapy in previously untreated patients where facilities for adequate conventional treatment exist. A further major disadvantage of the method of intra-arterial infusion is the strict limitation of its effect by the vascular anatomy, seen clearly in the failure of involved cervical lymph nodes to respond. Finally, the morbidity and mortality associated with prolonged intra-arterial infusion greatly exceed those of radiotherapy, especially in the older age group among whom many of these patients are found.

The above considerations lead us to believe that methotrexate infusion for head and neck cancer should at present be restricted mainly to the failures of surgery and radiotherapy. In these otherwise hopeless patients a considerable measure of palliation may be expected, and in a few cases prolonged control of disease.

It is, however, important to investigate the effect of combinations of methotrexate infusion with surgery and/or radiotherapy, and such attempts seem justifiable in certain lesions with a poor prognosis. Carcinoma of the maxillary antrum suggests itself for trial, since, in addition, lymph-node spread in this condition is relatively infrequent and late.

Summary

Experience with intra-arterial infusion of methotrexate in 26 patients with recurrent head and neck cancer is described. Though most lesions showed some response, complete and prolonged regression of disease was achieved in one patient only. The method was associated with considerable morbidity, especially in the aged and where the internal carotid artery was infused. Three patients died as a result of treatment.

At present methotrexate infusion should be restricted mainly to the palliation of otherwise untreatable cases.

We are grateful to Lederle Laboratories for the supply of methotrexate and citrovorum factor, and especially to Ruth Porter, M.R.C.P., for her invaluable help. The management of these exacting cases would not have been possible without the care of the sisters, nurses, and house-

surgeons concerned. We are indebted to the British Empire Cancer Campaign for making funds available for this work. The cost of some of the apparatus was met from a generous donation by Mr. Geoffrey Harmsworth. We thank Sir Stanford Cade, Mr. E. Stanley Lee, Mr. T. M. Prossor, and Mr. D. Walker-Ashcroft for referring cases. The Department of Clinical Photography, Westminster Hospital, was responsible for the illustrations, and Miss B. Hedley-Prole rendered valuable secretarial assistance.

REFERENCES

- Duff, J. K., Sullivan, R. D., Miller, E., Ulm, A. H., Clarkson, B. D., and Clifford, P. (1961). *Cancer (Philad.)*, **14**, 744.
 Espiner, H. J. (1961). Personal communication.
 Klopp, C. T., Alford, T. C., Bateman, J., Berry, G. N., and Winship, T. (1950). *Ann. Surg.*, **132**, 811.
 Sullivan, R. D., Miller, E., and Sykes, M. P. (1959). *Cancer (Philad.)*, **12**, 1248.
 ——— Wood, A. M., Clifford, P., Duff, J. K., Trussell, R., and Burchenal, J. (1960). *Cancer Chemother. Rep.*, **10**, 39.

SERUM MUCOPROTEINS AND PLASMA FIBRINOLYTIC ACTIVITY IN CORONARY-ARTERY DISEASE

BY

D. OGSTON, M.A., M.B.

Garden Research Fellow, Department of Medicine, University of Aberdeen

It has been observed that atherosclerotic subjects have a greater serum mucoprotein level than normal subjects (Antonini and Salvini, 1957; Schwartz and Gilmore, 1958). Schwartz and Gilmore suggested that this increased mucoprotein level might reflect increased depolymerization of connective-tissue ground-substance mucopolysaccharide, and that this process plays a part in the pathogenesis of atherosclerosis. Dorfman (1959), however, has stated that it is unlikely, on chemical grounds, that the blood mucoproteins arise from such a source.

Most workers have been unable to show any alteration in plasma fibrinolytic activity in subjects with coronary-artery disease. Nestel (1960) found that subjects who had sustained a cardiac infarction over one month before had a mean lysis-time which did not differ significantly from controls, although the same worker noted significantly less plasma fibrinolytic activity in subjects with intermittent claudication due to atherosclerosis than in a control group (Nestel, 1959). Neither Merskey *et al.* (1960) nor Goldrick (1961) could demonstrate any decrease in plasma fibrinolytic activity in patients with coronary-artery disease.

The present investigation was undertaken to determine what relationship, if any, exists between serum mucoprotein levels and fibrinolytic activity in post-cardiac-infarction subjects.

Methods and Material

Plasma Fibrinolytic Activity.—This was determined by a modification of the method of Bidwell (1953). The modifications introduced have been described (Ogston and Fullerton, 1961).

Serum Mucoproteins.—The perchloric acid-soluble, phosphotungstic acid-insoluble tyrosine content of serum was estimated by means of the Folin-Ciocalteu reagent (Winzler *et al.*, 1948). The factor 23.8 was used to convert milligrams tyrosine to milligrams mucoprotein. Reproducibility studies were carried out on this method using sera of mucoprotein content 80–245 mg./100 ml. The difference between duplicates, as a percentage of the mean serum mucoprotein content, had a mean value of 3.5% (standard deviation 2.5%; N=40).

Two groups of subjects were studied in respect of serum mucoprotein levels.

Group 1. Men aged 40 to 70 Years.—This group consisted of 22 healthy subjects and patients in the convalescent ward. Care was taken to ensure that

members of this group gave no history of angina pectoris or intermittent claudication, had no evidence of atherosclerosis on clinical examination, and had a normal erythrocyte sedimentation rate and a normal electrocardiogram.

Group 2. Post-cardiac-infarction Male Subjects aged 42 to 71 Years.—All 33 members of this group had the electrocardiographic changes of recent cardiac infarction at the time of admission to hospital 3 to 52 months previously. The majority were receiving long-term anticoagulant therapy (phenindione), the Quick one-stage prothrombin time being maintained at 2 to 2½ times the control. The remainder were receiving either no therapy or 1 mg. of phenindione a day (low-dosage group of the M.R.C. (1959) trial of long-term anticoagulant therapy).

All blood samples were obtained in the morning between 8 and 9 o'clock after fasting for 10 hours. When plasma fibrinolytic activity was determined the subjects rested for 15 minutes before venepuncture; none had undertaken strenuous exercise before attending for venepuncture. All members of the post-cardiac-infarction group were accustomed to venepuncture and hospital environment, and it was not thought that anxiety influenced significantly the results of the plasma fibrinolytic activity estimations.

Results

Table I shows that subjects who had sustained a cardiac infarction had a significantly greater mean serum mucoprotein level than the control male subjects. The

TABLE I.—Mean Serum Mucoprotein Levels in Subjects who Have Sustained a Cardiac Infarction and in Age-matched Controls

Group	No.	Mean Age (Years)	Serum Mucoprotein Level (mg./100 ml.)	
			Mean	S.D.
1. Normal men	22	52	107	12
2. Post-cardiac-infarction males	33	58	126	22
Significance of difference (P)			.. <0.001	

Chart shows the scatter and distribution of the results in the two groups. It is seen that the serum mucoprotein levels in the controls varied between 81 and 130 mg./100 ml. In the post-cardiac-infarction subjects the range is much wider (from 70 to 160 mg./100 ml.) and 14 of these 33 subjects had values greater than 130 mg./100 ml.—that is, higher than the level found in any of the