

THE AMERICAN JOURNAL OF PATHOLOGY

VOLUME XIV

MAY, 1938

NUMBER 3

DEGENERATIVE ARTHRITIS *

A COMPARISON OF THE PATHOLOGICAL CHANGES IN MAN AND EQUINES

G. R. CALLENDER, M.D., AND R. A. KELSER, D.V.M., PH.D.

(From the Army Medical Research Board, Ancon, Canal Zone)

It is now known that many animal species suffer from joint diseases of both known and unknown etiology and that some of these are similar in character in all species studied. In a previous paper ¹ we reported the results of an investigation which showed that a very prevalent condition among Army horses and mules in Panama, which had been considered a form of osteomalacia, and which caused a large amount of lameness, was in reality degenerative arthritis of undetermined etiology. It was also indicated that the condition in the horses and mules was very similar to the degenerative type of arthritis in man. We present in this paper results of a comparative study of the affection in man and the equine species.

Arthritis may be divided into two general types, inflammatory and degenerative. Both include diseases of known etiology. In the inflammatory group there are the specific infections, of which tuberculosis, gonorrheal and streptococcal arthritis are examples in man. In lower animals the arthritis of pyosepticemia or "joint-evil" due to *Shigella viscosa*, *Salmonella abortivo-equinus*, *Escherichia coli*, or streptococci, is the outstanding example of this type. In the degenerative group Charcot's arthropathy seen in syphilis ²

* Received for publication February 21, 1938.

and also following traumatic nerve destruction ³ is the outstanding lesion of known etiology. In addition to these there are inflammatory arthritides sometimes resulting in ankylosis, of which the etiology is obscure though they are generally designated as "rheumatoid" or atrophic, and degenerative lesions of unknown etiology which, as they usually present clinical symptoms only in the later stages when compensatory bone production occurs, are then called hypertrophic arthritis.

This paper is based on 60 specimens from man and one or more joints from each of 54 horses and mules destroyed because of disabling lameness. Most of the specimens from man were from the knee and, with the exception of one or two from the surgical clinic, they were obtained at autopsy.

The various types of pathology of diseased joints in man have been described by Nichols and Richardson,⁴ Allison and Ghormley,⁵ Parker *et al.*,^{6,7} and others. The pathology is also presented in the papers of Keefer *et al.*,⁸ and in the review prepared at the request of the American Committee for the Control of Rheumatism, by Hench *et al.*⁹ Degenerative changes in the joints of horses and mules are described in the papers of Williams, Fisher and Udall,¹⁰ Hare,¹¹ Bennet and Bauer,¹² Kintner and Holt¹³ and others. Parker's papers describing the changes in the knee joint with advancing age ⁶ and in rheumatoid arthritis ⁷ serve to clarify the essential difference in the pathology of these conditions. The first paper described degenerative arthritis, the second the essentially inflammatory nature of rheumatoid arthritis. Although publications prior to Parker's described many of the changes of degenerative arthritis, none are as definite as his, and the others at times are confusing because of the inclusion of pathological features of other conditions.

Certain changes have been observed in the material on which this paper is based that were not described by Parker and concerning some of these we have found no references. These studies appear to indicate rather clearly the sequence of events in the joint changes so the lesions will be described in the order in which they apparently occur, or rather in the order of their severity, for some of them may not be progressive.

In order to define the pathological changes the normal histological structure of the joints in man and in horses and mules will

be briefly described. Starting at the joint surface there is, in young animals and children, a layer of cells whose nuclei are roughly parallel with the surface and which appears to be continuous with the surface layer of the synovial membrane at the margin of the joint. In adults this layer of cells cannot be made out on the bearing surface of the cartilage but in the same position there is a membrane-like condensation of protoplasm which limits the more or less homogeneous ground substance between it and the underlying cartilage matrix (Fig. 1). It appears, as has been stated by others, that there is no synovial membrane over the central bearing surface of the joint cartilage, yet when loss of substance occurs on apposed surfaces in degeneration of the cartilage, so that such surfaces are no longer in contact, a membrane may form over them which appears to be synovial in character. There is no traceable connection between these membranes and the peripheral synovia except where ulcers are near or at the joint margin (Fig. 2). Beneath the peripheral membrane of the normal joint surface the homogeneous cartilage begins and extends to the calcified matrix overlying the cortical bone. Near the periphery the cartilage cells have their long axes more or less parallel to the surface. As the distance from the periphery increases the axes assume more and more a vertical position with relation to the bone cortex, and especially in horses and mules, tend to be arranged in rows at right angles to the subchondral bone (Fig. 3). In man, even at ages prior to complete ossification of the epiphyses, the cells are arranged much less regularly and are more often found in groups of nuclei not all of which have independent capsules (Fig. 1). The cells, and especially the nuclei, are larger and apparently fewer in number near the calcified matrix in both man and equines.

In so far as we can determine from a few specimens, prior to the completion of epiphyseal ossification no calcium deposit is found about the cartilage cells in man or equines, as indicated by staining reactions in frozen sections of joint cartilage which has not been decalcified. However, as early as the 24th year in man, in this series, frozen sections stained by hematoxylin show zones of deep blue staining granules about the cell capsules. These are largest near the calcified matrix, decreasing to practical absence near the joint surface. These calcific zones have been found in

apparently normal cartilage at all older ages examined. Similar deposits were found in the normal cartilages of full-grown horses but not in those of a 10 months fetus. This finding suggests a change in the chemical composition of the cartilage about the time when ossification is complete.

The cartilage terminates abruptly at the calcified matrix. This is a layer of material having nuclei of the cartilage type and containing calcium which often appears in wavy striae parallel to the bone cortex, the stria joining the cartilage usually being the most densely stained with the blue of hematoxylin. Normally this layer is distinct at its junction with the cartilage, but projects into the bone cortex in irregularly shaped papillary-like masses which blend with the underlying cortical bone. Calcium appears to be retained in this matrix after decalcification processes have completely removed it from the normal bone beneath, in so far as staining reactions reveal its presence (Fig. 3).

Beneath the calcified matrix is the cortical bone, the character of which varies with the species, size and activity of the animal and differs in each bone and in different parts of the same bone. In general, large surfaces which bear the stress more or less evenly show little thickening or condensation of the trabeculae of the cortical bone. The central portions of the femoral condyles are examples. Localized areas where the subchondral trabeculae form compact bone with few marrow spaces occur at points of maximum stress, as in the grooves and on the apices of the ridges of the tibial tarsal bone and the tibia of horses and mules.

In judging as to the condition of the bone, therefore, these variations must be remembered, as must also the natural difference in bony structure of larger or smaller animals and also variations secondary to physical activity.

In fetal cartilage no definite line of demarcation can be made out between that portion which will remain cartilage and that which will be transformed into bone. Most of the blood vessels loop back at about normal cartilage depth from the periphery but occasional vessels approach nearer the joint surface. After the bone cortex is defined and the calcified matrix is laid no vessels are found in the cartilage, but in all types of cortex, from the least to the most dense, vascular tissue is found projecting from the marrow spaces into or even through the calcified matrix. These

projections are more numerous in cortical bone in which there is little peripheral condensation of the trabeculae (Fig. 3).

It appears to us that variations in density of the bone cortex have been misconstrued as changes due or secondary to degenerative arthritis, the lesions of which are prone to occur at just those points of stress where normally the bone is more dense. With these normal conditions and variations in mind the pathological lesions of degenerative arthritis, as observed by us in man and in horses and mules, will be described.

The mildest lesion seen consists of parallel grooves running in the direction of motion of the joint surfaces. These are relatively infrequent in horses and mules and rare in man. In the former they are found in the hinge joints like the tibiotarsal; in man on the patella, especially on the middle facets. In the equine species this may be the only type of lesion of a joint and it involves both joint surfaces, while in man other changes have always been present and the patellar cartilage alone may be affected.

Grossly the lesion consists of grooves of varying depth, the lateral margins appearing slightly raised. There is little change in color except in the deeper ones in equines in which the depth of the depression in some areas is dark red in color, the base being so thinned that the vascular underlying bone shows through. Hare,¹¹ in his study of this type of lesion, found that it consisted of ridges and grooves, the ridges of one of the apposed surfaces fitting into the grooves of the other. This we have been unable to demonstrate in our specimens. In fact, the depth of the groove often is made up of less dense tissue than the surrounding cartilage, indicating lack of pressure in this area. In man only shallow grooves have been seen (Figs. 4 and 5).

Microscopically a section across the long axis of a groove shows a depression of the surface of the cartilage with relatively slight bulging or elevation of the lateral margins. The membranous surface layer may be swollen in the depth of the groove. The cartilage cells are somewhat disturbed in arrangement and more separated in the matrix beneath the marginal bulging. The cartilage beneath shows more or less fibrillation, the long axes of the fibers being at right angles to the joint surface, the fibrillated material extending a varying distance toward the cortical bone (Figs. 6 and 7). Deeper grooves show correspondingly greater changes

both in the character and in the degree of the cell arrangement. Groups of nuclei in a single capsular space are frequent and fibrillation is more pronounced. Occasionally splits or clefts are formed along the fibrils, extending varying distances into the cartilage (Fig. 8). These may reach the cortical bone and sometimes penetrate into it along the vascular tissue projections which extend from the bone into or through the calcified matrix. When this occurs there is a necrosis of the subchondral plate and a production of fibrous tissue in the spaces between the bone trabeculae. This may go on to the formation of cartilage and osteoid tissue, while lateral to such clefts bone production, beginning as an increase in thickness of the calcified matrix, may take place and extend into the cartilage. In this manner a bony thickening of the cortex may occur.

These clefts and accompanying or subsequent changes are much more frequent following other types of degenerative change described below. In our material lesions were found in the subchondral bone only when cartilage changes had reached the bony cortex. We are therefore unable to confirm Hare's hypothesis that focal necrosis in the bone is the primary change. In our specimens the bone changes have been obviously secondary to those of the cartilage.

"Blister" formation is somewhat more common than grooving and may be seen in any joint. Equine joints have furnished the best examples. The first changes noted grossly are small smooth elevations of the surface of the cartilage without color change. These become somewhat flattened at the top, the margins more sharply defined, and the color paler than the surrounding tissue. Rupture usually occurs and the peripheral layers become shreds or fringes projecting above the surface. It appears that coalescence of these blisters forms fringe areas of varying size (Figs. 15 and 16).

Microscopically the early stages in formation are best studied in frozen sections of the joint cartilage. Serial sections of an early elevation show in the center an irregular space bounded by fibrillated cartilage surrounded by a zone, more or less fibrillar, with cells more widely separated than normal (Fig. 12). This change gradually decreases to blend finally with the normal cartilage beyond the swollen areas. Study of a number of these early lesions,

which are located in the peripheral third or half of the cartilage, suggests that the primary change is a focal edema, followed by fibrillation and "blister" formation (Fig. 11). Rupture of such blisters gives rise to fringes. These consist of strands of fibrillated cartilage projecting above the surface, the longer ones being attached at the periphery of the blister, the shorter extending from the base of what now may be termed a small "ulcer" or erosion.

Occasionally on the same joint surface on which the discrete blister formations are seen, shallow pits occur which have slightly raised edges and a smooth surface only slightly paler than the unchanged cartilage. Microscopically these are covered by partly hyalinized fibrocartilage continuous with the upper layers of the normal cartilage (Fig. 13). Beneath the surface layers, and extending a varying distance toward the cortical bone, the cartilage is more or less fibrillated and the nuclear arrangement is disturbed. Such pits appear to result from blister formation followed by loss of the fluid but without fringes being formed, as is the case in those that have ruptured.

Considerable areas of this "fringed" cartilage are found which, as stated above, may have resulted from the coalescence or extension of the blister areas, but may also have originated otherwise, though other mechanisms or sequences of events have not been evident in our material. Traumatism of the apposed surface by the frayed tissue may well account for the fringed area on that side without the preliminary blister formation. Figure 14 shows changes in the cartilage of the proximal end of the humerus of a mule apposed to an eroded, fringed glenoid fossa. The small pale areas are fibrillated, almost myxomatous tissue. In some areas there were some membranous fringes and the entire cartilage showed fibrillation and abnormal arrangement of the cartilage cells.

Clefts extending toward or into the cortical bone occur, as in the case of the grooves. These are often close together along the surface and extend but a short distance into the cartilage, while others, more widely separated, extend deeper, forming irregular masses of cartilage attached at the base to the calcified matrix. Beneath, and in the fringes, the alignment of the cells is markedly disturbed and cell nests are often abundant. Practically always both apposed surfaces show changes though these are usually dif-

ferent in extent, sometimes in type, or both. Grossly the uniformly fringed areas are described as erosions. Relatively low magnification ($\times 10$), however, shows the essentially villous character of the bases which is confirmed by microscopic sections.

The further progress of the erosive degenerative process is characterized by a necrosis and loss of substance of the surface of the ulcer so that the remaining tissue is thinner than the surrounding cartilage. As this loss of substance continues the lesions appear as irregular, discrete and confluent areas eroded to varying depths below the surface of the normal cartilage (Fig. 19). The bases lose the villous character and become dingy gray in color. Such erosions or shallow ulcers were by far the most frequent type of lesion found by us in equines (Fig. 18). They were present in some joint of practically every animal autopsied for this investigation, all of which were destroyed because of disabling lameness. In man the fringed type was the most frequent (Fig. 15). In some of these the fringes projected above the surface but in many there was loss of substance so the fringed bases were definitely below the normal cartilage level. Most of the human bones, however, came from individuals who had given no history of joint disease.

The bases of the deeper ulcers, as observed in horses and mules, have been covered by a layer of dense fibrous tissue though masses of fibrillated hyaline cartilage may remain projecting from the underlying bone. The bone itself has never been bared. In man several advanced cases have shown areas of bare bone though in each instance portions of the surface were covered by fibrous tissue and fibrous and fibrillated hyaline cartilage (Fig. 17). When bone is bared it may be eburnated, but also may show thinning of the cortical layer and actual absence of bony cortex and calcified matrix. The bases of such areas consist of ends and small bridges of trabeculae between masses of fibrous and hyaline cartilage. In such cases vascular fibrous and osteoid tissue extends varying distances into the cortex, replacing the fat marrow between trabeculae (Fig. 20).

Frozen sections of undecalcified cartilage of affected joints show considerable variation in the amount of visible calcium as indicated by staining reactions. The cells near the calcified matrix showed the most but the distribution was not uniform. In some

areas in and near erosions and fringed areas none of the granular deposit may be seen. Further, in apparently normal cartilage, especially in the later age groups, the distribution was often uneven.

The ulceration and loss of substance usually involves both apposed surfaces which then cease to be in contact. Such areas no longer carry their proportion of the stress of the joint, therefore the remaining cartilage must carry the entire load. There is malocclusion of the joint. In such joints hypertrophic changes occur which appear to be compensatory in character.

The first change appears to be hypertrophy, or swelling of moderate degree, of the remaining cartilage at the margins of the bearing surface and extension of the cartilage over the edge of the joint surface, especially in such joints as the patella-femoral. The new or extended cartilage is fibrillated and the cell arrangement is distorted. Then bone formation starts from the calcified matrix and extends into the cartilage in the same manner as occurs beneath ulcerated areas on the original joint surfaces (Fig. 8). As the bone production continues vessels from the marrow enter the process and eventually the new bone becomes continuous with the old and appears of similar or like structure (Figs. 21-24). It has been suggested (Parker⁶) that the pressure in the maloccluded joint forces the bone outward to form these lips or shelves. Except that the pressure must have an influence in the direction the new bone formation will take in relation to the old bone, it does not appear from our material that this is so. That it is compensatory is indicated by the occurrence of the same process directed against the pressure of the joint as seen in Figures 23 and 24, where it seems that the bone is produced in an effort to compensate for the loss of cartilage substance.

Masses of these shelves composed of cartilage, with or without some bone formation, may fail to be firmly united to the bone. In such instances they become pedunculated and later may be separated and free in the joint as "joint mice" (Fig. 21). Nutrition of these free masses appears to be fairly well maintained though in the larger ones the central ossified portions may become necrotic. This maintenance of structure indicates that the nutrition of joint cartilage, to a great extent at least, is from the synovial fluid.

Hypertrophic lesions were neither numerous nor severe in the

horses and mules of our series. These animals are destroyed before the occurrence of such advanced changes as are found in man. Masses of cartilage in the capsule and at the joint margin, however, were occasionally found.

The semilunar cartilages of the knee show degenerative changes more or less in proportion to the degree of change in the cartilage of the apposed femur. These menisci are formed of bundles of fibers embedded in a hyaline matrix, the long axis of the fibers being roughly parallel to the contour of the meniscus. The cross section is triangular, the apex toward the center of the joint area, the base at the periphery. The base is attached by fibrous tissue to the margin of the tibial condyles and the fibrillated ends are attached to the central portion of the bone between the condyles. The medial meniscus is longer and smaller in cross section than the lateral one. The changes in degenerative arthritis are: first, fringes extending onto the central portions from the apices of the menisci; then fibrillation or rather loss of the hyaline matrix so that the cartilages appear as masses of fibers, which may rupture so that the cartilage appears fractured; and finally considerable portions may disappear (Figs. 25 and 26). These changes are usually more advanced in the larger medial meniscus and occasionally in man may be advanced with only relatively minor degeneration of the cartilages of the femur. As observed in our material, they were seldom of advanced degree in equines. In joints in which the menisci show advanced degeneration with loss of substance, new cartilage and bone formation may occur from the intercondylar eminence at or near the attachment of the lateral meniscus. Such formation would appear to be compensatory in that it would tend to limit the lateral motion of the femur on the tibia which the degenerated menisci no longer serve to prevent.

Changes in the synovial membrane lining the joint cavities have not been marked except in a few of the advanced hypertrophic cases in man. Vascular papillary projections from the synovial membrane are practically constant. These are of small size in most mildly affected joints, longer and more abundant in those showing hypertrophic changes. Occasionally in both man and equines there are relatively large (1-2 cm. diameter) pedunculated cystic masses covered by synovial membrane. Occasionally,

attached to and apparently arising from the capsule at its attachment to the bone, pedunculated and sessile masses of cartilage are found evidently arising from this membrane. Rarely such a cartilaginous mass is embedded beneath the synovial membrane in the inner tissues of the capsule.

In advanced hypertrophic cases the synovial fluid may be dark in color and gelatinous in consistence. When this condition has been found in equines there has usually been some evidence of recent injury complicating the disease process.

DISCUSSION

Grooves and blisters, especially the latter, appear from our experience to be the primary and earliest lesions in degenerative arthritis. Grooves are best seen in equines. This type of lesion is easily overlooked in human joints. Practically all writers have described the fissures, clefts and fringe formation, and the extension of the clefts into the subchondral bone. The relation of these to blood vessels has been noted. We have not seen evidence of fracture of the bony plate as noted by Parker but fractures might well be caused by "joint mice" caught between the joint surfaces. As a result of the study of serial sections, these openings from cartilage to marrow appear to be the result primarily of a cartilage fissure extending through the calcified matrix along vessels which appear normally to extend to the cartilage from the marrow beneath. The clefts are localized; that is, the extension into the bone rarely exceeds 1 mm. in the plane at right angles to that of the section. Eight or ten sections at 25 μ often show both termini of these lesions.

Pressure may have something to do with the process in the early stage but the condition may continue after pressure has been removed by loss of substance from both apposed surfaces. Moreover, when new bone is formed above the previous normal level of the bony plate evidence may remain beneath the new bone cortex in the form of fibrous, cartilaginous or osteoid tissue which has not been replaced by fatty marrow. It appears that when the process is complete, as shown in Figures 23 and 24, a normal marrow eventuates as in primary bone formation. We are simply viewing various stages in the breakdown and repair of the joint structure. Therefore, it appears reasonable that abnormal tissues, remnants

of the repair, should be found beneath the joint surface after the process in the immediate area reaches a stage which, though imperfect as compared to the normal, is practically complete or stationary. It is necessary to view more than one plane in studying a three dimensional process if erroneous conclusions are to be avoided.

Several writers have mentioned the increased density of the bone beneath the degenerated areas, usually referring to it as compression of the trabeculae. Some also speak of rarefaction or osteoporosis as a feature of the process in the subchondral bone. As mentioned above, there is marked variation in the character of the subchondral bone. We have been unable to demonstrate in the subchondral bone either increases in density or porosity which could be considered a part of the disease. Certainly these are not early changes. Neither has vascular change nor the necrosis in the bone as described by Hare been evident in our material prior to advanced degeneration of the overlying cartilage.

Increase in density of subchondral bone occurs in areas where the physical nature of the joint indicates that the greater stresses occur. It is possible that due to this density the nutrition of the lower portion of the articular cartilage, which is believed to receive its nutrition from the underlying bone, receives less as a result of such density and relative avascularity and thus is rendered more susceptible to degenerative changes. However, the peripheral portions of the cartilage receive nutrition from the synovial fluid, as is indicated by the condition of the cartilage in "joint mice." From our material it appears that the primary degenerative change starts in the peripheral half or third of the cartilage and this is supported by the studies of others. It thus seems more logical to assume a change in the character of the synovial fluid, rather than in the subchondral bone, as responsible for the primary degenerative process.

Eburnation of the bared bony cortex occurs in advanced lesions in man but such eburnation appears to be the result of new compensatory bone formation which commences in the calcified matrix and extends into the cartilage. Such bone, kept bare by the frictional trauma of an apposed bare bone, may show a dense cortex, often interrupted by areas of imperfect bony closure of the bony plate as seen in Figure 20.

The productive (hypertrophic) changes are similar in man and equines but have been seen in advanced stages only in man. Their compensatory character has been indicated. There has been some argument as to the origin of the new formation of bone and cartilage but in the specimens available to us there seems to be but one source and that is the calcified matrix and subchondral bone. Even in advanced lesions we have not seen evidences of periosteal bone formation or evidence that the connective tissues at the margin of the joint enter into the productive process. Even at the margins where the lips or shelves are formed there is little evidence of new cartilage formation. Instead, there is evidence of proliferation of the cartilage cells near the calcified matrix while the peripheral hyaline cartilage appears edematous or swollen rather than proliferating. In some instances fibrous tissue from the region of the joint margin and capsular attachment extends over a lip or shelf of bone. This fibrous tissue seems to be proliferating and there is sometimes a suggestion of the formation of fibrocartilage but such pictures are unusual in degenerative arthritis and lead to a suspicion that some other factor is present. This construction is the common one in inflammatory arthritis, including the so-called rheumatoid variety in which the fibrous tissue mass extends as a pannus onto the surface of the joint cartilage; the cartilage degenerates, eventually may disappear and fibrous and finally bony ankylosis eventuate.

We have not examined phalangeal joints in which Nichols and Richardson described periosteal bone formation. In these joints the periarticular cartilage masses known as Heberden's nodes are large, as compared to the joint, and it would be difficult to decide their origin because their peripheries blend with the periosteal structures along the shafts of the bones. Certainly in the weight-bearing joints of our series, of all grades of severity, especially in the human specimens, we have not been able to determine periosteal bone formation. In equines this occurs in spavin, for instance, which is primarily not a disease of the joint cartilages, but there is bone production by the periosteum in the region of the capsular attachment which may extend over the joint area and interfere with motion. Spavin may be concurrent with but does not appear to be a part of degenerative arthritis.

The number of individuals, human and equine, that have been

examined routinely at autopsy for joint disease is still too small to determine the incidence of degenerative changes in the joints. Fifty-four Army horses and mules over 10 years old, destroyed because of lameness, had many lesions each in various joints but the extent and severity of the lesions did not always correspond with the clinical findings. That is, there were instances in which the most advanced or extensive lesions were in joints that had not been considered affected, and minor lesions in many joints other than those responsible for the symptoms. No lesions were found in a 6 year old pony that died of encephalitis.

These findings in equines are in accord with those in man. Only 5 of our 7 advanced cases with lipping and other hypertrophic changes had complained of their joints. Two of 18 cases with rather extensive erosions but no definite hypertrophic change had vague symptoms. Forty of the 48 persons whose knee joints were found affected did not complain of joint trouble. Twenty-two of the 40 had mild lesions, 16 had moderately extensive erosions and 2 had advanced lesions with hypertrophic changes on both patella and femur.

The human series of Keefer, Parker, *et al.*,⁸ consisted of knee joints from 100 persons, dead of various diseases. In the combined groups (Keefer's and ours), no lesions were found in 7 in the first two decades of life. Lesions were present in 1 of 2 in the third decade, 5 of 7 in the fourth, 15 of 16 in the fifth, 36 of 37 in the sixth, all of 42 in the seventh, 26 of 27 in the eighth and 15 of 16 in the ninth decade. The findings in even this small number indicate that lesions of degenerative arthritis may occur at any time after the bone and joint structures are completely formed and that after the fifth decade is reached few persons are free from these changes. It will require the examination of a number of different joints of several thousand persons in general autopsy services to determine the incidence of this disease, especially because so few of those affected have clinical symptoms. Roentgen examinations are of great value in determining the presence of relatively early lesions in such joints as those of the vertebrae and fingers. They show ulcers on the condyles of the femur when they are deep enough and can be X-rayed in profile but do not show lesions of the patella and patellar fossae until the hypertrophic changes of the advanced process are present.

Clinical symptoms are of some value. In the inflammatory conditions, including the so-called rheumatoid arthritis, pain, tenderness and some fever are present early and often usher in the process, while in pure degenerative arthritis the process is usually advanced and secondary hypertrophic changes have occurred before symptoms are sufficiently severe to send the patient to a physician.

The seven advanced lesions in our series were well distributed in the age groups. The youngest was 48, the oldest 87. Both of these and two in the eighth decade, age 73 and 76, had syphilis. All seven had arterial disease and three had gangrene of toes. In our subclinical group as a whole, although the numbers are small, the extent of the area involved appeared to increase with advancing age, but exceptions were present. Work done so far suggests that starting at about age 20, the incidence rises with increasing rapidity for the next 20 years. Thereafter the changes are found in practically all. Increase in the extent of the areas involved appears to increase with age but increase in severity — or perhaps better stated as rapidity of progression of the lesions — seems to be due to other factors than age. One is reminded of the great variations in the extent and rapidity of progress of the arterial degeneration in atheromatous arteriosclerosis.

There is little evidence as to the cause or causes of the primary degenerative change. The age incidence suggests that metabolic or rather chemical or physico-chemical changes in the cartilage render it more susceptible to damage by normal wear and tear. The early stages of blister formation bear out this hypothesis. The subchondral bone cortex and the calcified matrix are formed at the limit of the vessel loops from the bone. The formation of this limiting line is gradual. In early childhood the end of the bone is largely cartilaginous and no obvious dividing line can be made out between that portion of the cartilage which will remain as such and that which will eventually become bone. The completion of the bone cortex and the superimposed calcified matrix may well mark a quantitative change in the nutrition brought to the joint cartilage. There are some data on this point, though how such chemical and chemico-physical changes as have been found are related to degeneration of the cartilage is unknown.

Hoffmann, Lehmann and Wertheimer are quoted by Bywaters ¹⁴

as finding that the glycogen content of cartilage varies with the kind of cartilage and the age of the animal, also in different individuals, variations being between 0.02 and 0.6 per cent. It was also indicated that there is a diminution with age and with increasing calcification of the cartilages.

The calcium content of cartilage can scarcely be determined with sufficient accuracy for comparative studies because of the impossibility of obtaining uniform specimens for analysis. Unless samples include the base as well as the periphery of the cartilage without the inclusion of underlying calcified matrix and bone, and this is practically impossible, comparative analyses would be of little value. Our studies of frozen sections indicate that there is a considerable variation in the amount of visible calcium between the deep and superficial portions of the cartilage and between the cartilage of children and adults. Further, there is much variation in the evenness of its distribution in the cartilages of the later age groups. Whether this variation is quantitative chemically or whether it is one of the physical-chemical state of the calcium, we do not know. The degenerative changes, especially the splitting, suggest a loss of elasticity. Perhaps analogous conditions are the increase in calcium found accompanying loss of elasticity in the aorta and lens of the eye. Disturbance of chemical equilibrium might cause a change of the calcium from a colloid to an insoluble state, while simple dehydration, causing a relative increase in the calcium content, might be responsible for lack of cartilage elasticity. Certainly degenerated cartilages appear dry as compared with the normal, but comparative analyses for water content would be as difficult as those for calcium. Further, the cause of dehydration, if existent, might well be related to changes in osmotic pressure caused by decrease in salt content or change in the chemical-physical state.

Believing that a dietary deficiency with mineral imbalance was the cause of the lameness in the group from which our equine cases were taken, their diet was modified by adding alfalfa hay, which corrected the calcium deficiency, balanced the $\text{CaO-P}_2\text{O}_5$ ratio and added vitamins, especially vitamins A and D. A number of our cases had been on this improved diet for 2 years but we were unable to make out any evidence of a repair process other than the compensatory hypertrophic changes described. The period was

not sufficiently long to determine the effect of the new diet on the incidence of clinical lameness.

CONCLUSIONS

1. Degenerative arthritis is a definite disease entity of unknown etiology which commences as a degeneration of joint cartilage and involves bone only secondarily.

2. It exists in many animal species and is an important cause of disability in man and equines.

3. The lesions in man and horses and mules are practically identical in character, though the most advanced lesions are not ordinarily found in equines because the resulting disability causes them to be destroyed before the changes reach such a stage.

4. Though a relatively few examinations have been made, the lesions of degenerative arthritis have not been seen in man prior to the third decade, but after this their incidence increases rapidly so that they are almost universal when the fifth decade is reached.

5. A relatively small proportion of the lesions give rise to symptoms but this proportion increases with advancing age as does the extent of the areas involved.

6. Involvement of the cartilage alone often appears to be symptomless. When pain occurs it probably usually results from pressure on subchondral bone which has either been denuded of cartilage or more or less damaged by extension of the degenerative change. In those cases in which loose pieces of cartilage or bone (joint mice) are present in the joint, pain may be produced as a result of their getting between the joint surfaces.

7. Loss of cartilage substance, causing malocclusion of the joint, is followed by bone production from the calcified matrix and subchondral bone. This appears to be a compensatory effort to replace the degenerated cartilage with bone and, though secondary, has given the name hypertrophic arthritis to the disease. This new bone formation is rare in man except in the clinical disease in which it is usually present.

8. Symptomatic degenerative arthritis occurs in equines from less advanced lesions than in man. It appears that the greater the physical activity of the individual, man or animal, the more serious does this condition become.

9. While the area of cartilage, the number of joints involved,

and the incidence of clinical arthritis increase with advancing age, rapid progress of the disease to severe disability appears to be due to other factors as it may occur in the fifth decade or earlier, as well as in later life.

10. Ankylosis, fibrous or bony, does not occur in this condition though compensatory bone formation may be responsible for limitation of joint motion.

NOTE: The authors are indebted to Lieut. Col. H. W. Mahon, Capts. Karl R. Lundeberg and Dwight W. Kuhns, Medical Corps, for specimens from man, and to Lieut. Cols. C. W. Greenlee, C. C. Whitney and D. H. Mallan, V.C., for specimens from equines, and to Sgt. C. M. Margeson and Privates 1st Class John Austin and Elmer West for technical assistance.

REFERENCES

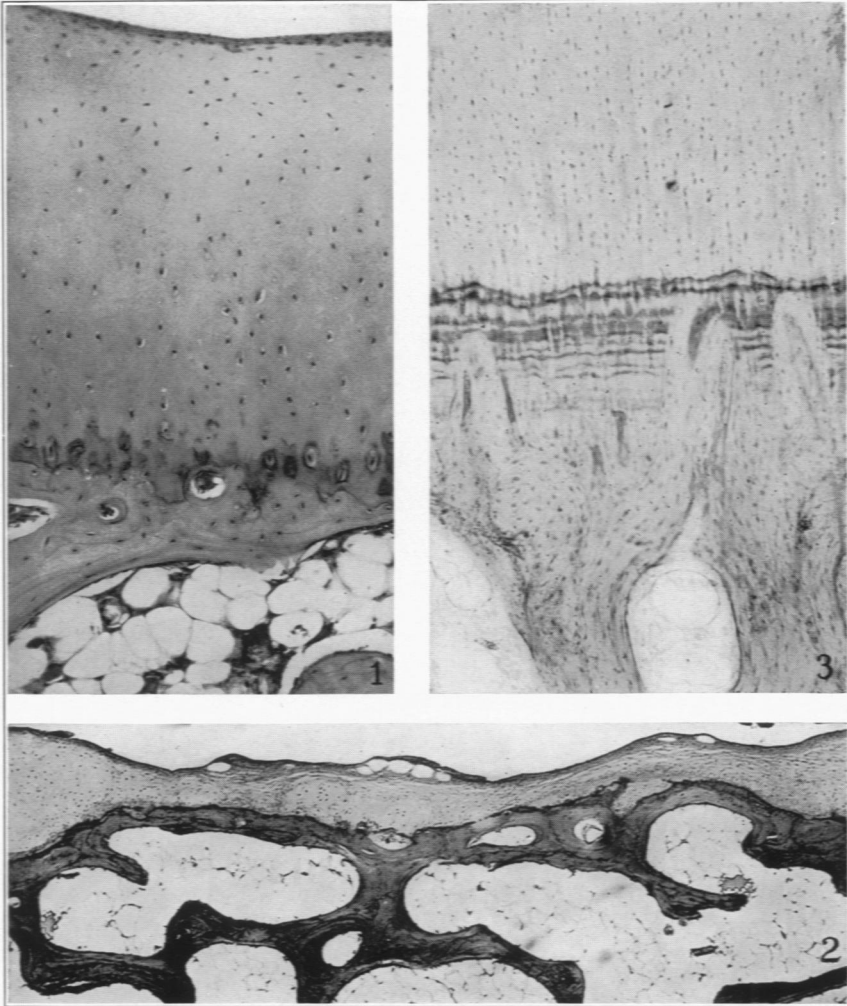
1. Kelsner, R. A., and Callender, G. R. Equine degenerative arthritis. *Vet. Med.* (in press).
2. Moritz, Alan Richards. Tabische Arthropathie. Histologische Studie. *Virchows Arch. f. path. Anat.*, 1928, 267, 746-855.
3. Shands, A. R., Jr. Neuropathies of the bones and joints; report of a case of an arthropathy of the ankle due to a peripheral nerve lesion. *Arch. surg.*, 1930, 20, 614-636.
4. Nichols, Edward H., and Richardson, Frank L. Arthritis deformans. *J. M. Research*, 1909, 21, 149-221.
5. Allison, Nathaniel, and Ghormley, R. K. Diagnosis in Joint Disease. A Clinical and Pathological Study of Arthritis. William Wood and Company, New York, 1931.
6. Parker, Frederic, Jr., Keefer, Chester S., Myers, Walter K., and Irwin, Ralph L. Histologic changes in the knee joint with advancing age; relation to degenerative arthritis. *Arch. Path.*, 1934, 17, 516-532.
7. Parker, Frederic, Jr., and Keefer, Chester S. Gross and histologic changes in the knee joint in rheumatoid arthritis. *Arch. Path.*, 1935, 20, 507-522.
8. Keefer, Chester S., Parker, Frederic, Jr., Myers, Walter K., and Irwin, Ralph L. Relationship between anatomic changes in knee joint with advancing age and degenerative arthritis. *Arch. Int. Med.*, 1934, 53, 325-344.
9. Hench, Philip S., Bauer, Walter, Fletcher, Almon A., Ghrist, David, Hall, Francis, and White, Preston. The present status of the problem of "rheumatism"; a review of recent American and English literature on "rheumatism" and arthritis. *Ann. Int. Med.*, 1935, 8, 1315-1374, 1495-1555, and 1673-1697.

10. Williams, W. L., Fisher, Carl W., and Udall, D. H. The spavin group of lameness. *Proc. A. V. M. A.*, 1905, **42**, 283-348.
11. Hare, Tom. Investigation of etiology and pathogeny of equine chronic arthritis (rheumatoid arthritis). *Vet. Rec.*, 1927, **7**, 411 and 432.
12. Bennet, Granville A., and Bauer, Walter. A systematic study of the degeneration of articular cartilage in bovine joints. *Am. J. Path.*, 1931, **7**, 399-414.
13. Kintner, J. H., and Holt, R. L. Equine osteomalacia. *Philippine J. Sc.*, 1932, **49**, 1-89.
14. Bywaters, E. G. L. The metabolism of joint tissues. *J. Path. & Bact.*, 1937, **44**, 247-268.

DESCRIPTION OF PLATES

PLATE 48

- FIG. 1. Normal human joint cartilage from condyle of femur. Note irregular distribution of cartilage cells.
- FIG. 2. Ulcer on femoral condyle. Base covered by synovial membrane which shows cyst formation. Calcified matrix thin with bony spur extending into cartilage to right of center.
- FIG. 3. Normal equine lower cartilage, calcified matrix and cortex of subchondral bone. Note vessels penetrating nearly through calcified matrix which shows striae of calcification (*c.f.* Fig. 1 in which calcified matrix is not striated). Both types are found in man and equines. Note regular arrangement of the cartilage cells.

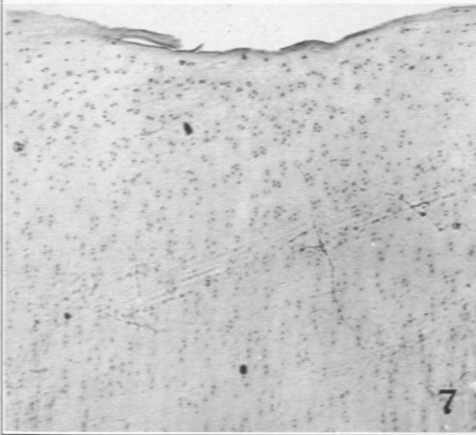
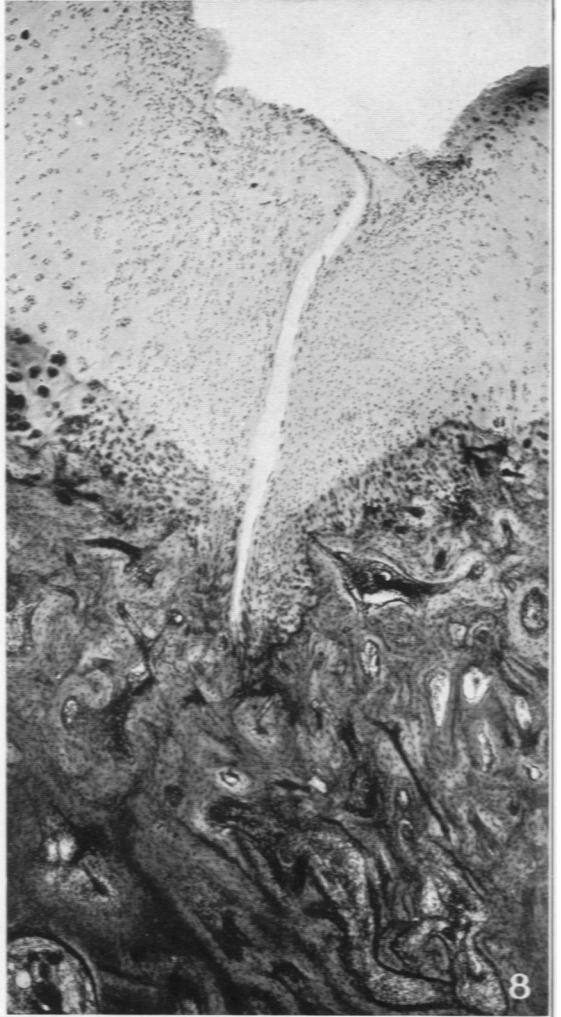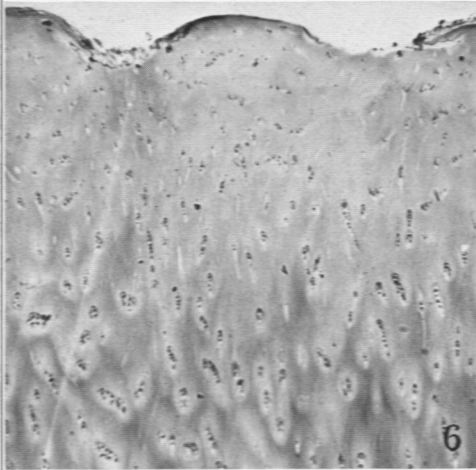
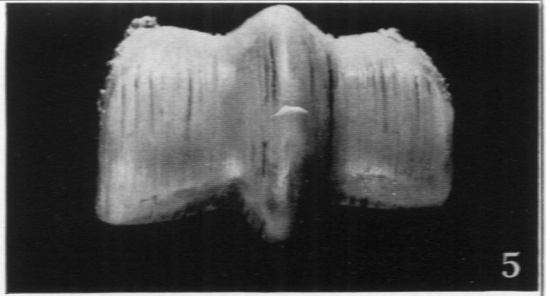
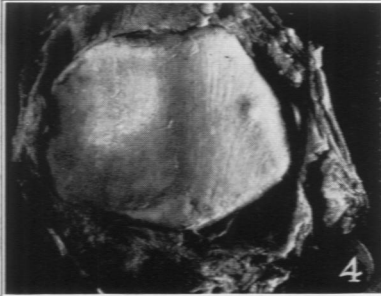


Callender and Kelsor

Degenerative Arthritis

PLATE 49

- FIG. 4. Shallow grooves and "blister" in human patella.
- FIG. 5. Shallow and deep grooves in the cartilage of the distal end of the large metacarpal bone of a horse. The darkest streaks showed deep red at the base.
- FIG. 6. Shallow grooves in human joint cartilage cut across their long axis. Note soft tissue in base of the one at the left.
- FIG. 7. Shallow groove in equine joint cartilage.
- FIG. 8. Deep groove in equine joint cartilage. A cleft extends from base of groove into cortex of bone. Vascular fibrous tissue replaces bone about the cleft and extends into marrow spaces at lower right. Beginning bone formation replaces calcified matrix and extends into cartilage. Nuclear arrangement of cartilage is disturbed and there is necrosis of the fringed surface on the right margin of the groove.



Callender and Kelser

Degenerative Arthritis

PLATE 50

- FIG. 9. Large "blister" on a human patella.
- FIG. 10. "Blisters" and "pits" in cartilage of an equine patella.
- FIG. 11. Mound of edematous cartilage on left and ruptured "blister" on right. Frozen section from equine patella cartilage which grossly was similar to specimen shown in Fig. 10.
- FIG. 12. Early "blister" formation. Frozen section of equine patella cartilage.
- FIG. 13. "Pit" in equine patella cartilage from specimen similar to that seen in Fig. 10.
- FIG. 14. Membranous fringes on the surface and multiple areas of pale, almost myxomatous tissue in cartilage of equine humerus which was apposed to a fringed glenoid fossa.
- FIG. 15. Fringed eroded patella fossa, upper left, and deep ulcer on condyle, lower left, of human femur. Patient had not complained of joint symptoms.
- FIG. 16. Fringe areas and a few small "blisters" on femoral condyles of a mule. Animal had been affected with shifting lameness and many joints showed degenerative arthritis.

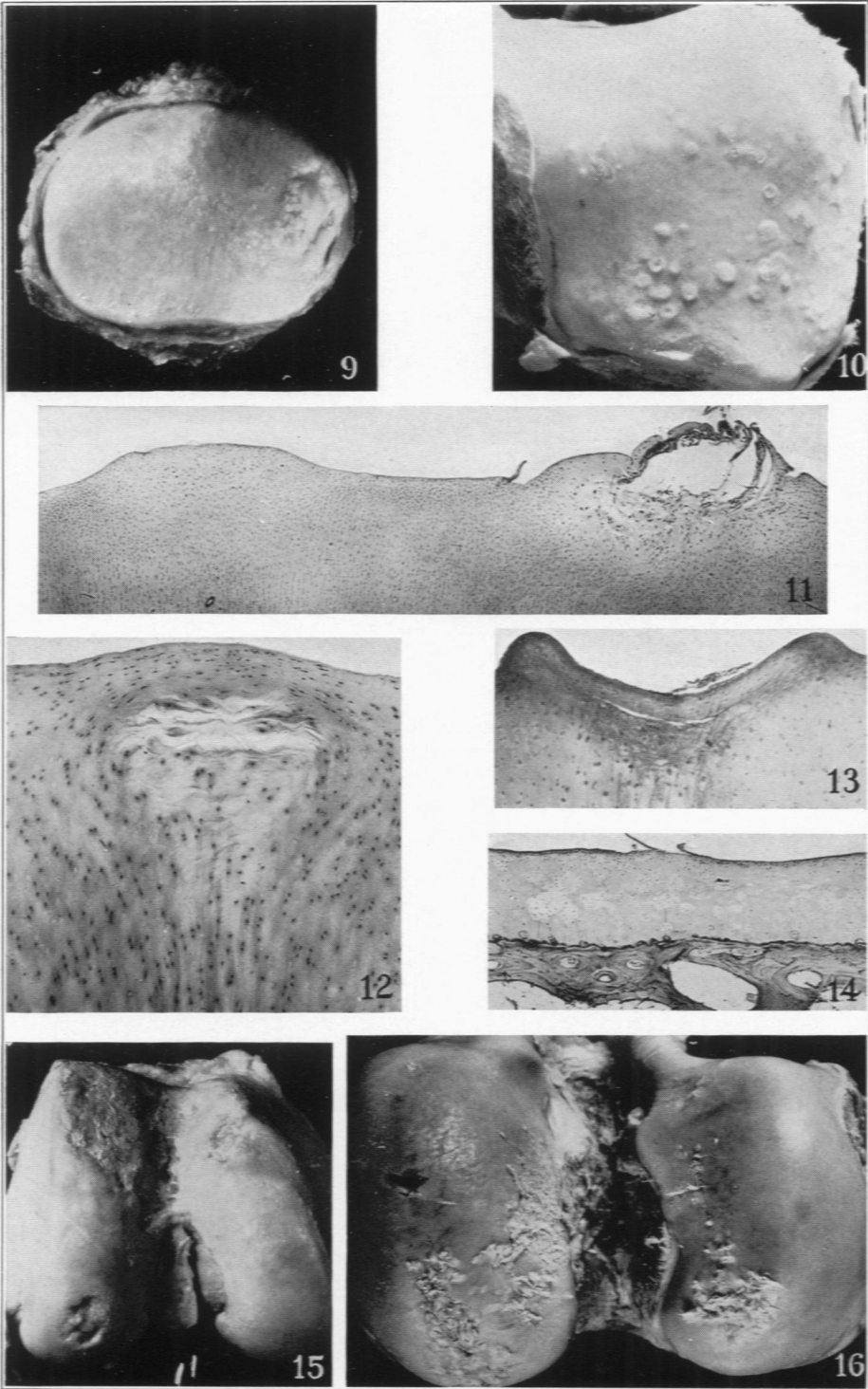
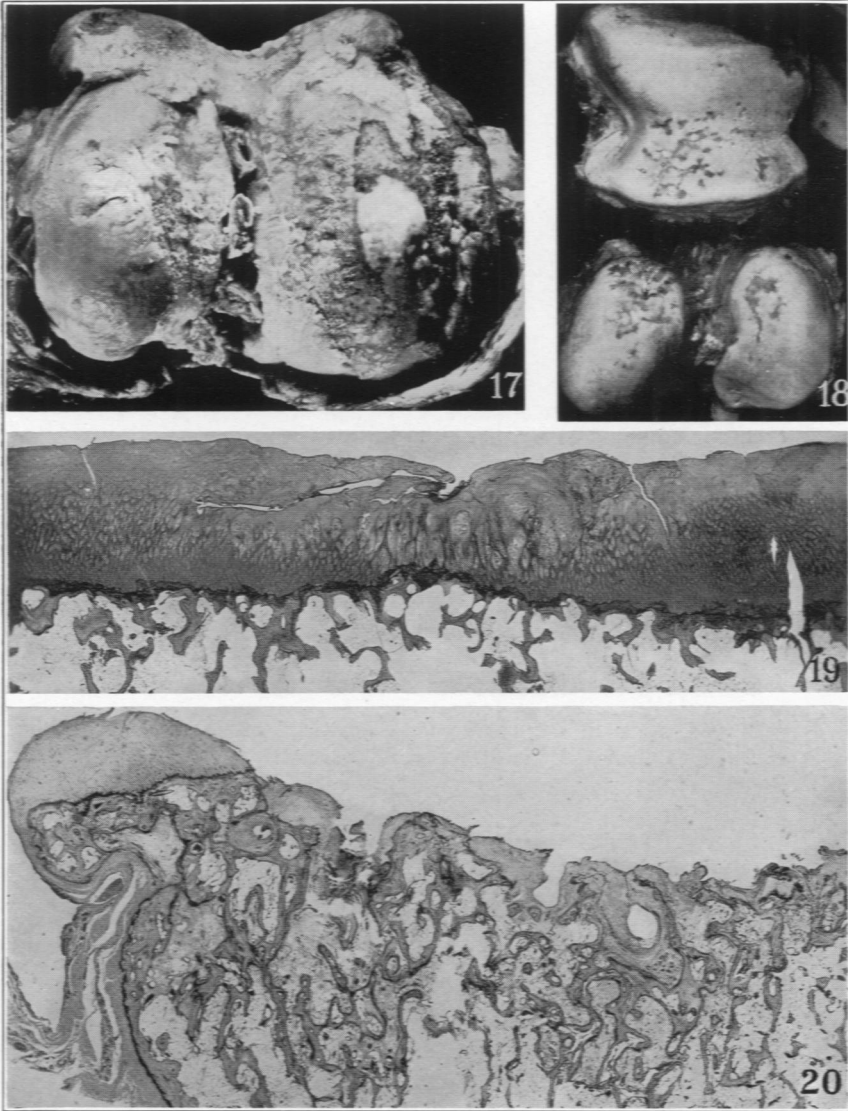


PLATE 51

- FIG. 17. Advanced degenerative arthritis with hypertrophic changes (see Fig. 21 for lateral view). Lower end of human femur. Condyles are partly denuded but there is little eburnation. Note island of swollen cartilage in the ulcerated area on the right.
- FIG. 18. Erosions in the cartilage of the patella fossa and femoral condyles of a mule destroyed for lameness.
- FIG. 19. Ulcer in human cartilage showing marked fibrillation fissures or clefts and bone formation from region of the calcified matrix. Note that there is no change in the density of the subchondral bone.
- FIG. 20. Section from human joint which showed ulceration similar to that seen in Fig. 17. Ulcer surface composed of ends of trabeculae and masses of fibrillated cartilage. Marrow spaces near surface are filled with fibrous and osteoid tissue. There is lipping at the margin from new bone growth which is covered with swollen fibrillated cartilage.

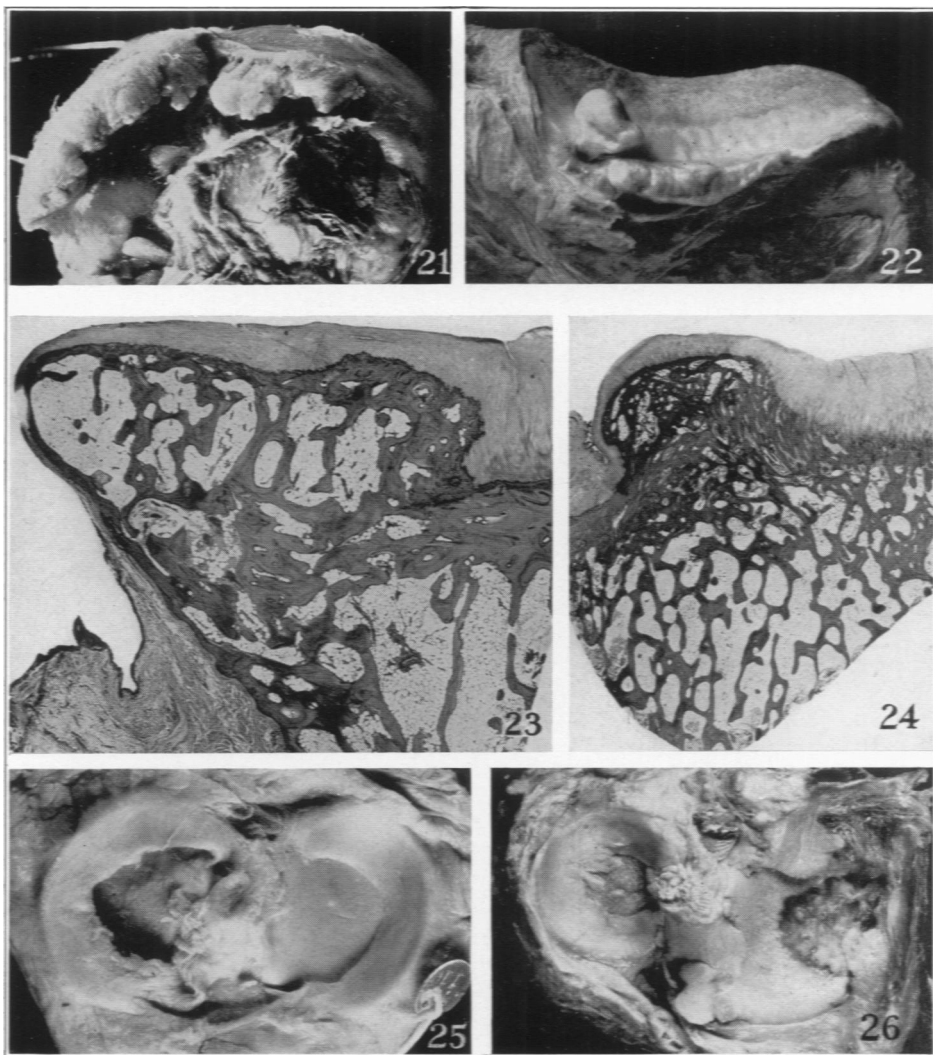


Callender and Kelsor

Degenerative Arthritis

PLATE 52

- FIG. 21. Advanced lipping of patella fossa and condyle of human femur (see Fig. 17).
- FIG. 22. Shelf formation on equine patella. Note pedunculated mass arising from bone margin. Fringed erosion occupies upper half of joint surface.
- FIG. 23. Section of lipped margin of human patella fossa which grossly was less advanced than that shown in Fig. 21. New bone, which appears normal, rises above the old cortex and is covered by thin fibrillated cartilage. There was extensive deep ulceration of patella and patella fossa. Note extension on to old cortex.
- FIG. 24. Section from the opposite side of bone of Fig. 22, showing cross section of the lip or shelf. Note similarity of Figs. 23 and 24.
- FIG. 25. Human tibia. Mesial semilunar cartilage (left) shows fibrillation for a short distance from its attachment and a small fringe. Lateral meniscus essentially normal, early "blister" formation in cartilage on right.
- FIG. 26. Human tibia. Lateral meniscus shows rather large pedunculated masses extended onto the eroded joint cartilage. Medial meniscus largely destroyed. Mass of bone covered with cartilage at lower center which extended to cervical ligament.



Callender and Kelser

Degenerative Arthritis