

# THE EARLY EFFECT OF HYPERTENSION ON THE AORTIC INTIMA OF THE RAT

## AN ELECTRON MICROSCOPIC STUDY

W. J. S. STILL, M.D.

*From the Department of Pathology, Medical College of Virginia, Richmond, Va.*

While the effect of acute and chronic hypertension on small vessels has been extensively studied,<sup>1-6</sup> less attention has been paid to the effect on the elastic arteries.<sup>7</sup> Yet it is widely held that the commonest disease of large arteries—namely, atherosclerosis, both human and experimental—is accelerated by hypertension.<sup>8-13</sup> The mechanisms by which this acceleration is accomplished are not known, but it seems important to establish the effect of hypertension on normal vessels of the caliber usually affected by atherosclerosis.

The following study illustrates the effects of relatively short periods of hypertension on the aortic intima of the rat. It shows that an apparently selective infiltration of mononuclear cells occurs and that the sites of infiltration may be dependent on the condition of the underlying internal elastic lamina.

### MATERIAL AND METHODS

Aortic hypertension was created by constricting the aorta by ligature at the site between the origins of the renal arteries. No elaborate measures were taken to ensure the same degree of constriction in each case, and a constriction was deemed successful if the distal kidney blanched immediately after constriction but thereafter showed reactive hyperemia.

Direct blood pressure readings from the carotid arteries were taken before, and at intervals after, constriction in the test animals and in a number of control animals before and after sham operations, without actual constriction of the aorta, had been performed. Significant rises in blood pressure were always obtained in the test animals beginning 4 hr. after constriction. The smallest mean rise was 15 mm. Hg and the greatest 50 mm. Hg above initial levels. No significant rises in blood pressure were obtained in the sham-operated animals.

For the experiment, 12 male rats of the Wistar strain, weighing an average of 350 gm., were used. The aorta was constricted by a silk ligature and animals killed at intervals of 4 hr. to 7 days afterwards. The thoracic and upper abdominal aorta—that is, above the constriction—was taken for examination in each case, and for control purposes, the same segments were taken from a sham-operated animal. The lower abdominal aorta (below the constriction) was taken from the test animals and examined as an additional control for the segments above the constriction. The aortas

---

Supported by Grant HEO 9622 from the National Heart Institute, U. S. Public Health Service.

Accepted for publication June 13, 1967.

were removed before fixation, cut into thin cross sections, and fixed as such in 1% buffered osmium tetroxide for 1 hr. in the cold. The tissue was subsequently embedded in Maraglas D.E.R.<sup>14</sup> Phase sections were cut from all blocks and thin sections from appropriate areas. An RCA EMU 3G microscope was used.

## RESULTS

In all test animals the aorta above the constriction was visibly dilated, as compared with the normal rat aorta at the same level, and its wall was rigid and open when removed. This contrasted with the collapsed state of the vessel below the constriction. The morphologic changes to be described were present in the upper segments of the test aortas only; no comparable changes were seen in the segments of vessel below the constriction in the same animals or in the aortas of the control animals. The aortic intima of the control rats consisted of a single layer of endothelial cells, separated from the internal elastic lamina by a nominal subendothelial space which contained a few connective tissue fibrils. Occasionally a single mononuclear cell, not of smooth muscle origin, was present.<sup>15</sup> The same structure was true for the aortic intima below the constriction in the test animals.

Study of phase sections from the upper segments showed that intimal changes described below were present in the great majority, were focal in distribution, and appeared to be related to gaps or other irregularities in the internal elastic lamina. The impression was also gained that although there was some increase in the severity of the changes between 4 hr. and 7 days, the increase was of a mild degree.

Mononuclear cells, monocytes, and lymphocytes, in approximately equal numbers, were found in all stages of entry into the intima (Fig. 1, 2, and 4). This reaction was focal. In all sections studied, no cell of blood origin other than monocytes and lymphocytes could be identified in the intima. On one occasion a red cell was seen apparently entering the intima in company with a monocyte. It was rare to see polymorphonuclear leukocytes or platelets in apposition with the endothelium, and this was in contrast to the large numbers of mononuclear cells found adhering to the surface (Fig. 1-3 and 5). Frequently, pseudopodia from the mononuclear cells were linked with hooklets<sup>15</sup> projecting from the luminal surface of endothelial cells (Fig. 4). A number of the mononuclear cells, both on the surface of the intima and in the intima, contained osmiophilic inclusions of varying density and composition. These were considered to be lipid in nature (Fig. 5 and 6).

In all animals the subendothelial space was widened even in the areas not containing cells. In these areas and around cellular infiltrations, widening was due to an accumulation of granular material (Fig. 7).

which in places was more fibrillar in nature (Fig. 5 and 8) and occasionally contained fragments of fibrin (Fig. 8). Many endothelial cells showed vesicles of varying size containing apparently identical granular material to that seen free in the intima (Fig. 3).

Survey of a large number of thin sections confirmed the impression gained from the phase sections—namely, that mononuclear accumulations were most frequently found where the underlying internal elastic lamina showed a gap (Fig. 1, 3, 4, and 6). With some frequency also, cells were found near small pads of smooth muscle that are normally found in the intima of the rat,<sup>15</sup> mouse,<sup>16</sup> and rabbit<sup>17,18</sup> (Fig. 3 and 5). These smooth-muscle pads were contained within fenestrae of the elastic lamina and the elastic tissue on the luminal side was seldom complete. Since these pads were also frequently adjacent to gaps in the internal elastic lamina proper, the over-all impression was that infiltrating cells gathered in areas of intima where the internal elastic lamina was, for some reason, not smooth or continuous.

Many endothelial cells appeared plump and swollen. They showed a marked increase in small vesicular structures, the membranes of the Golgi complex were conspicuous, and there appeared to be a general increase in smooth-walled membranes (Fig. 2, 4–6, and 8). Endothelial cells at times showed dense osmiophilic inclusions and, more frequently, vesicles of varying size containing granular material (*vide supra*). Evidence of degeneration of endothelial cells was not conspicuous and was considered no more frequent than in the normal aorta.

#### DISCUSSION

Increased intraluminal pressure in the aorta of the rat produces localized infiltrations of mononuclear cells into the intima. There is little doubt that such cells are derived from the luminal blood flow and are entering the intima from the lumen. Further, although this is much less certain, infiltration of mononuclear cells appears to occur with greatest frequency where gaps exist in the internal elastic lamina or where intimal smooth-muscle-cell pads exist. Coincidental with the cellular invasion there is, in the intima, a more generalized accumulation of granular material believed to be derived from blood plasma.

The infiltrating cells seen in the intima were entirely mononuclear in type. Esterly and Glagov<sup>7</sup> have shown that under chronic hypertensive conditions the main renal artery becomes unduly permeable to cells from the blood. They found mononuclear cells, polymorphonuclear cells and red cell fragments in the intima and presumed these had been forced into the vessel wall by increased luminal pressure. The infiltration of cells under these circumstances is not so selective as it appears to be

in the present investigation, although it may be that after lengthier terms of hypertension, other cells would appear in the intima. Nevertheless, the absence of blood-borne cells other than mononuclears at this stage is intriguing. It would appear that monocytes and lymphocytes play some active role in penetrating the endothelium rather than being merely passively forced through it. The endothelium did not appear to be damaged by this immigration, and it is assumed that penetration took place between endothelial cells. The changes observed in the endothelium could be accounted for by the increased filtration of plasma elements consequent to raised intraluminal pressure.<sup>19</sup>

In studies of experimental and human atherosclerosis by the present author and others,<sup>15,17,18,20-24</sup> the importance of the monocyte in this process and its propensity to invade the intima has been emphasized. The present study again illustrates the role this cell may have in arterial disease. Further, the presence of lipid within such cells, both those attached to the endothelium and those in the intima within hours of arterial constriction, shows their ability to become lipophages in circumstances other than those of hyperlipidemia.

The impression gained in the present study was that infiltrating cells gather preferentially in areas of the intima immediately adjacent to gaps in the internal elastic lamina and where pads of smooth-muscle cells were present. These gaps in the lamina and pads of cells in the intima have been described in the aorta of the rat,<sup>15</sup> mouse,<sup>16</sup> and rabbit,<sup>17,18</sup> and their reactions to the effects of hyperlipidemia have been described.<sup>17,18,22</sup> However, a much more extensive study would be required to test the plausibility of the suggestion that they play some part in the site selection of more extensive arterial changes. At present it appears, for example, that they are too numerous to be of importance in influencing the eventual site of atherosclerotic plaques. Nevertheless, they appear, under hypertensive conditions, to be areas of potential weakness.

This study and that of Esterly and Glagov<sup>7</sup> indicate that under hypertensive conditions whether of short (hours) or long (weeks) duration the intima of large arteries becomes abnormally permeable to cells and other material from the circulating blood. This process may therefore be of importance in the initiation of some arterial lesions and the enhancement of others.

#### SUMMARY

Increased luminal pressure was produced in the rat aorta by constriction of the abdominal segment. These conditions produced, within 4 hr., infiltration of mononuclear cells from the blood into the intima, together with an accumulation of plasma elements in the subendothelial

space. The cells appeared to gather in areas of intima which were contiguous to gaps in the internal elastic lamina.

## REFERENCES

1. BIAVA, C. G., DYRDA, I., GENEST, J., and BENCOSME, S. A. Renal hyaline arteriolosclerosis. An electron microscope study. *Amer J Path* 44:349-363, 1964.
2. BYROM, F. B., and DODSON, L. F. The causation of acute arterial necrosis in hypertensive disease. *J Path Bact* 60:357-368, 1948.
3. MCGEE, W. G., and ASHWORTH, C. T. Fine structure of chronic hypertensive arteriopathy in the human kidney. *Amer J Path* 43:273-299, 1963.
4. SPIRO, D., LATTES, R. G., and WIENER, J. The cellular pathology of experimental hypertension. I. Hyperplastic arteriolar sclerosis. *Amer J Path* 47:19-49, 1965.
5. WIENER, J., SPIRO, D., and LATTES, R. G. The cellular pathology of experimental hypertension. II. Arteriolar hyalinosis and fibrinoid change. *Amer J Path* 47:457-485, 1965.
6. WOLFGARTEN, M., and MAGAREY, F. R. Vascular fibrinoid necrosis in hypertension. *J Path Bact* 77:597-603, 1959.
7. ESTERLY, J. A., and GLAGOV, S. Altered permeability of the renal artery of the hypertensive rat. An electron microscopic study. *Amer J Path* 43:619-638, 1963.
8. BELL, E. T., and CLAWSON, B. J. Primary (essential) hypertension: A study of four hundred and twenty cases. *Arch Path (Chicago)* 5:939-1002, 1928.
9. BRONTE-STEWART, B., and HEPTINSTALL, R. H. The relationship between experimental hypertension and cholesterol-induced atheroma in rabbits. *J Path Bact* 68:407-417, 1954.
10. BURCH, G. E., and PHILLIPS, J. H. Hypertension and arteriosclerosis. *Amer Heart J* 60:163-167, 1960.
11. MCGILL, H. C., JR., FRANK, M. H., and GEER, J. C. Aortic lesions in hypertensive monkeys. *Arch Path (Chicago)* 71:96-102, 1961.
12. MOSES, C. Development of atherosclerosis in dogs with hypercholesterolemia and chronic hypertension. *Circulation Res* 2:243-247, 1954.
13. PATERSON, J. C., MILLS, J., and LOCKWOOD, C. H. The role of hypertension in the progression of atherosclerosis. *Canad Med Ass J* 82:65-70, 1960.
14. ERLANDSON, R. A. A new Maraglas, D.E.R.® 732, embedment for electron microscopy. *J Cell Biol* 22:704-709, 1964.
15. STILL, W. J. S., and O'NEAL, R. M. Electron microscopic study of experimental atherosclerosis in the rat. *Amer J Path* 40:21-35, 1962.
16. KARRER, H. E. An electron microscope study of the aorta in young and in aging mice. *J Ultrastruc Res* 5:1-27, 1961.
17. STILL, W. J. S. An electron microscope study of cholesterol atherosclerosis in the rabbit. *Exp Molec Path* 2:491-502, 1963.
18. STILL, W. J. S. Pathogenesis of experimental atherosclerosis. *Arch Path (Chicago)* 78:601-612, 1964.
19. DUNCAN, L. E., JR., CORNFIELD, J., and BUCK, K. The effect of blood pressure on the passage of labeled plasma albumin into canine aorta wall. *J Clin Invest* 41:1537-1545, 1962.
20. O'NEAL, R. M., and STILL, W. J. S. Pathogenesis of atherosclerosis. *Fed Proc* 21 (Suppl.):12-14, 1962.

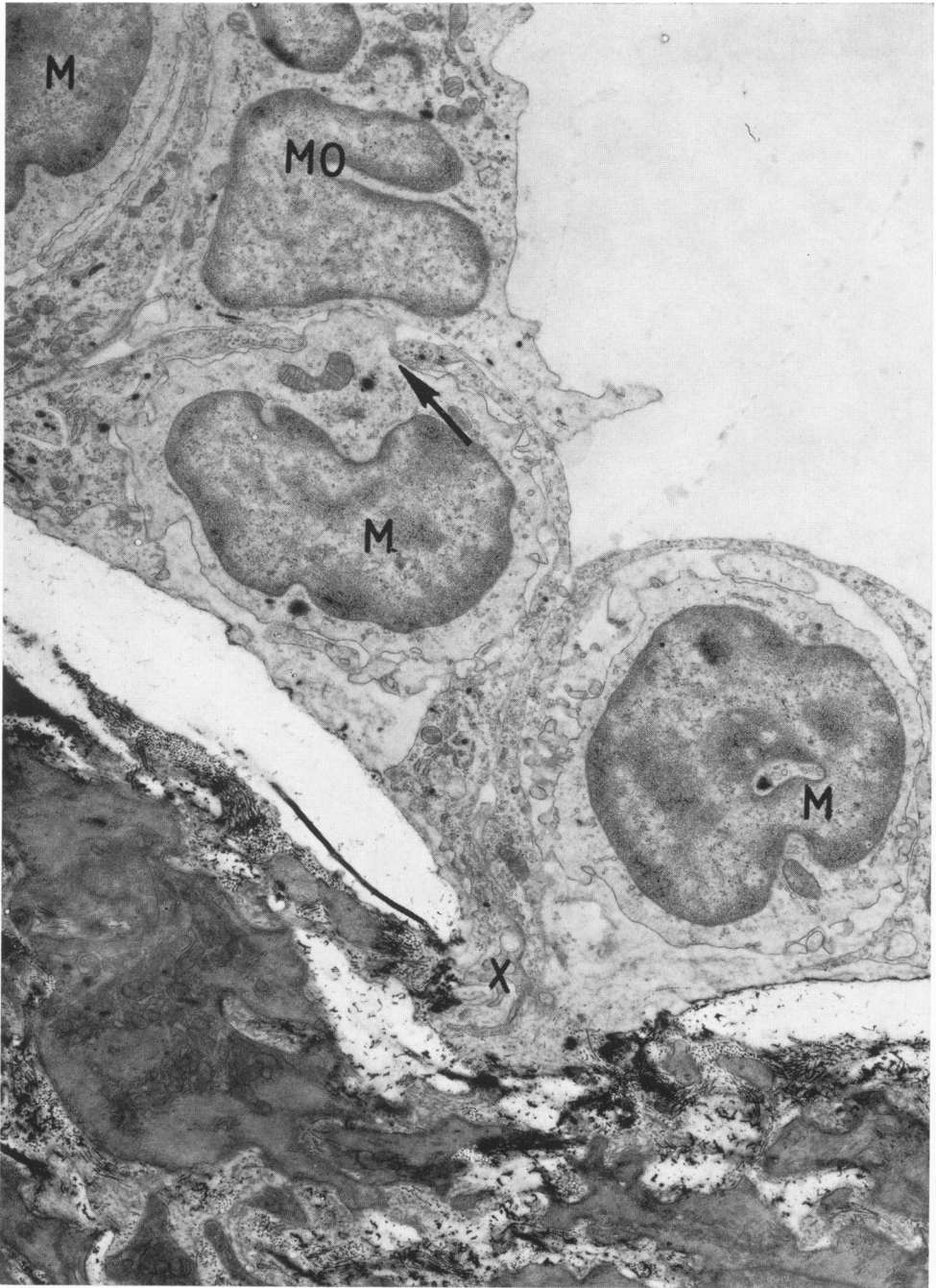21. POOLE, J. C. F., and FLOREY, H. W. Changes in the endothelium of the aorta and the behaviour of macrophages in experimental atheroma of rabbits. *J Path Bact.* 75:245-251, 1958.
22. STILL, W. J. S. Electron microscope studies in experimental atherosclerosis. *Symp Zool Soc London* 11:181-188, 1964.
23. STILL, W. J. S., and MARRIOTT, P. R. Comparative morphology of the early atherosclerotic lesion in man and cholesterol-atherosclerosis in the rabbit. An electronmicroscopic study. *J Atheroscler Res* 4:373-386, 1964.
24. STILL, W. J. S., and DENNISON, S. M. Reaction of the arterial intima of the rabbit to trauma and hyperlipemia. *Exp Molec Path* 6:245-253, 1967.

The author is grateful to Miss Susan Dennison for expert technical assistance.

---

#### LEGENDS FOR FIGURES

- FIG. 1. Intima 48 hr. after constriction. Three mononuclear cells (M) are in sub-endothelial space, one showing protrusion through endothelium (arrow). Another (MO) is attached to endothelium. Gap is present in elastic lamina (X).  $\times 7000$ .



1

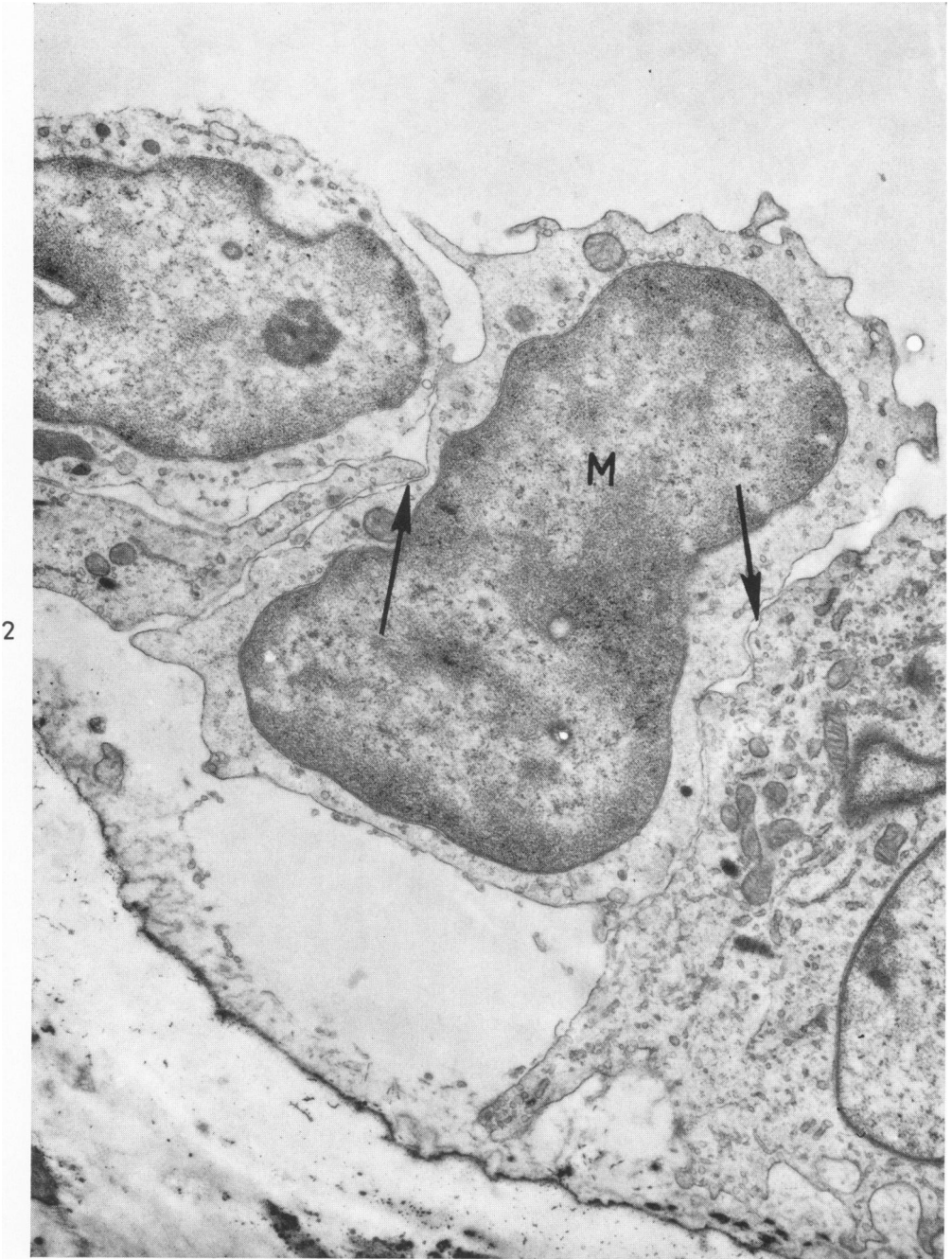
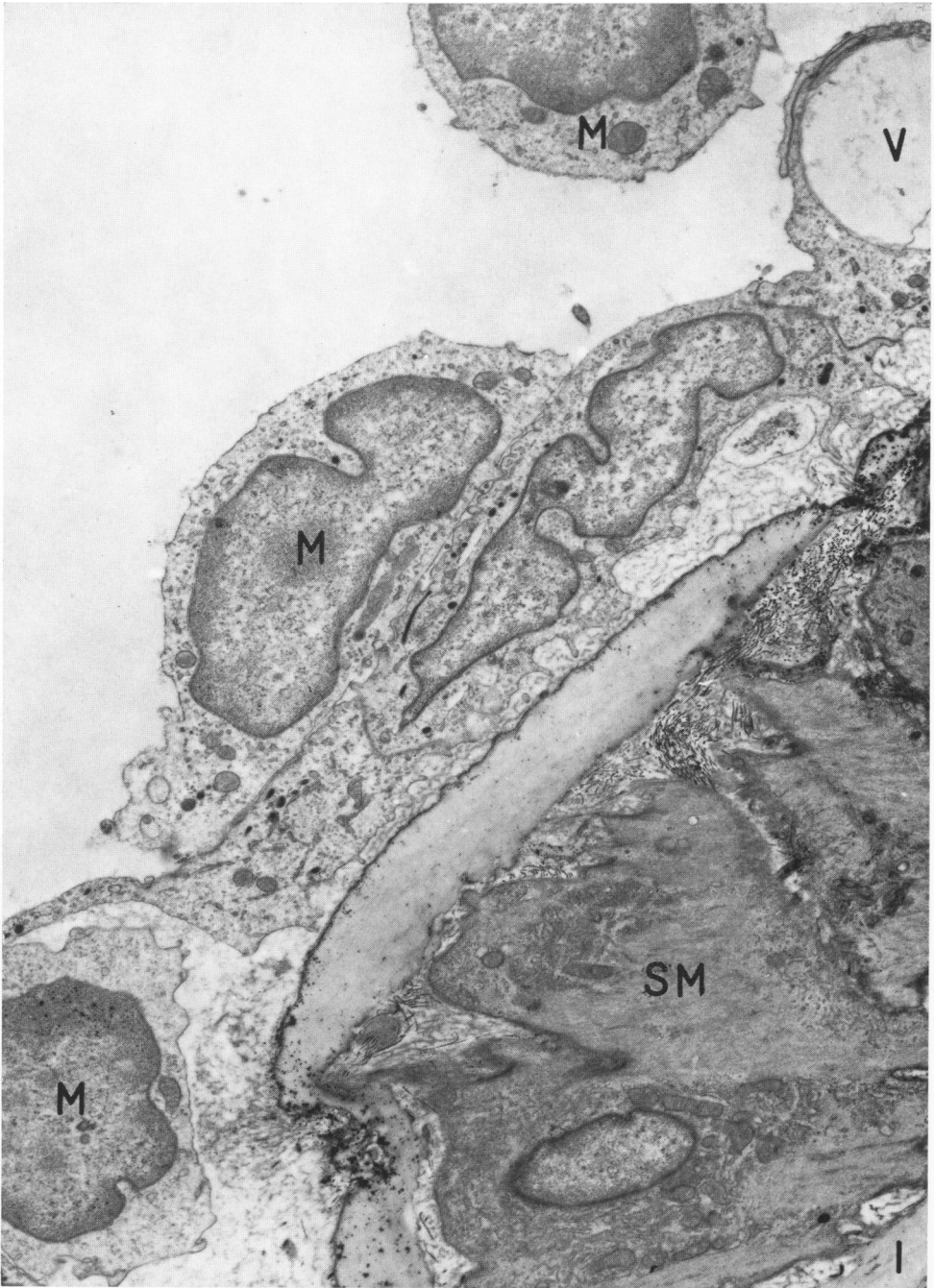


FIG. 2. At 18 hr. after constriction, mononuclear cell (M) is seen penetrating endothelium (arrows). Another is in contact with surface at top left.  $\times 15,000$ .



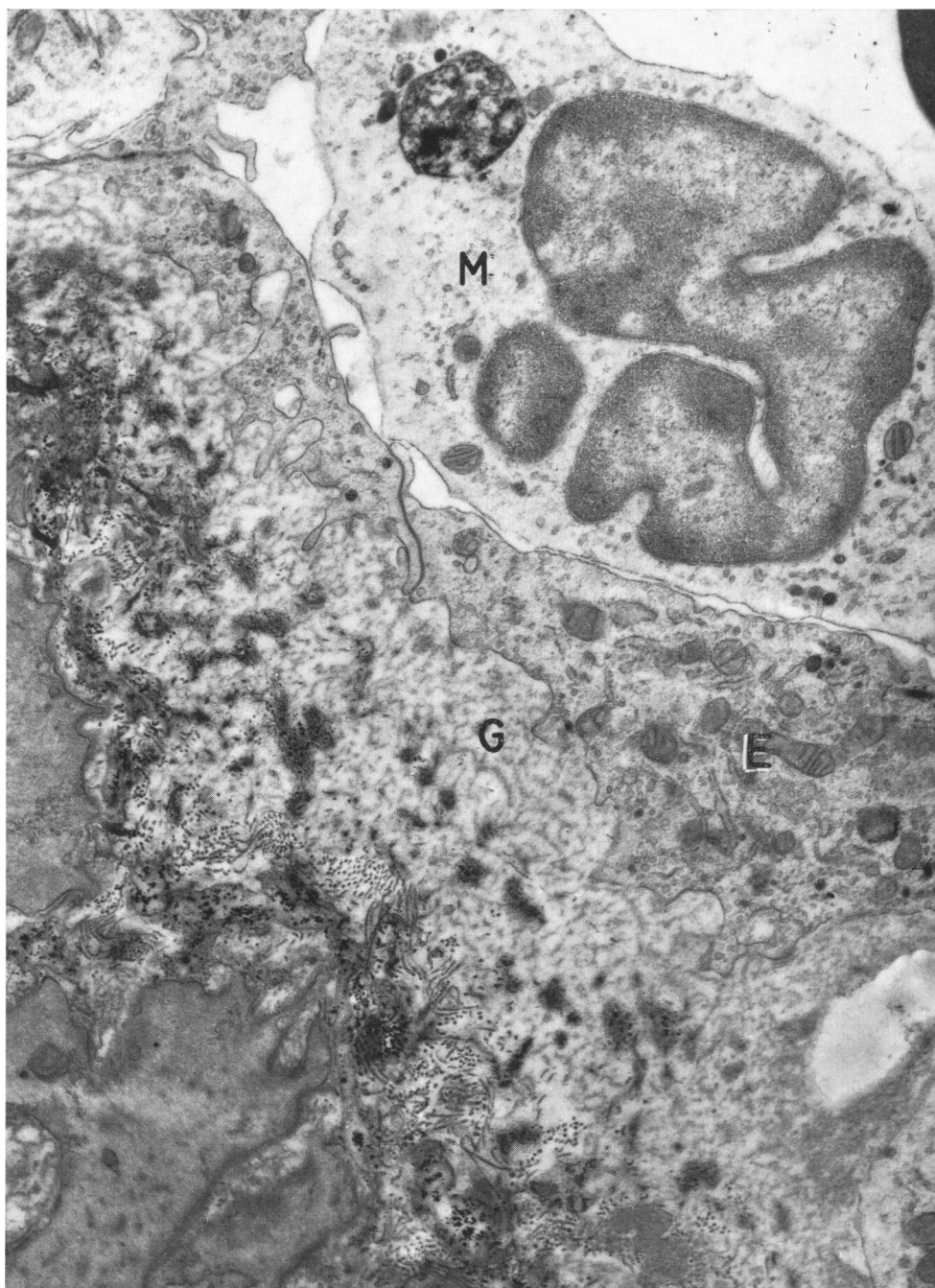


3

FIG. 3. At 18 hr. after constriction, monuclear cells (M) are in various positions relative to endothelium. Granular material is present in subendothelial space and in vesicle top right (V). Pad of smooth muscle is present (SM). Internal elastic lamina proper is at bottom right (I).  $\times 5000$ .

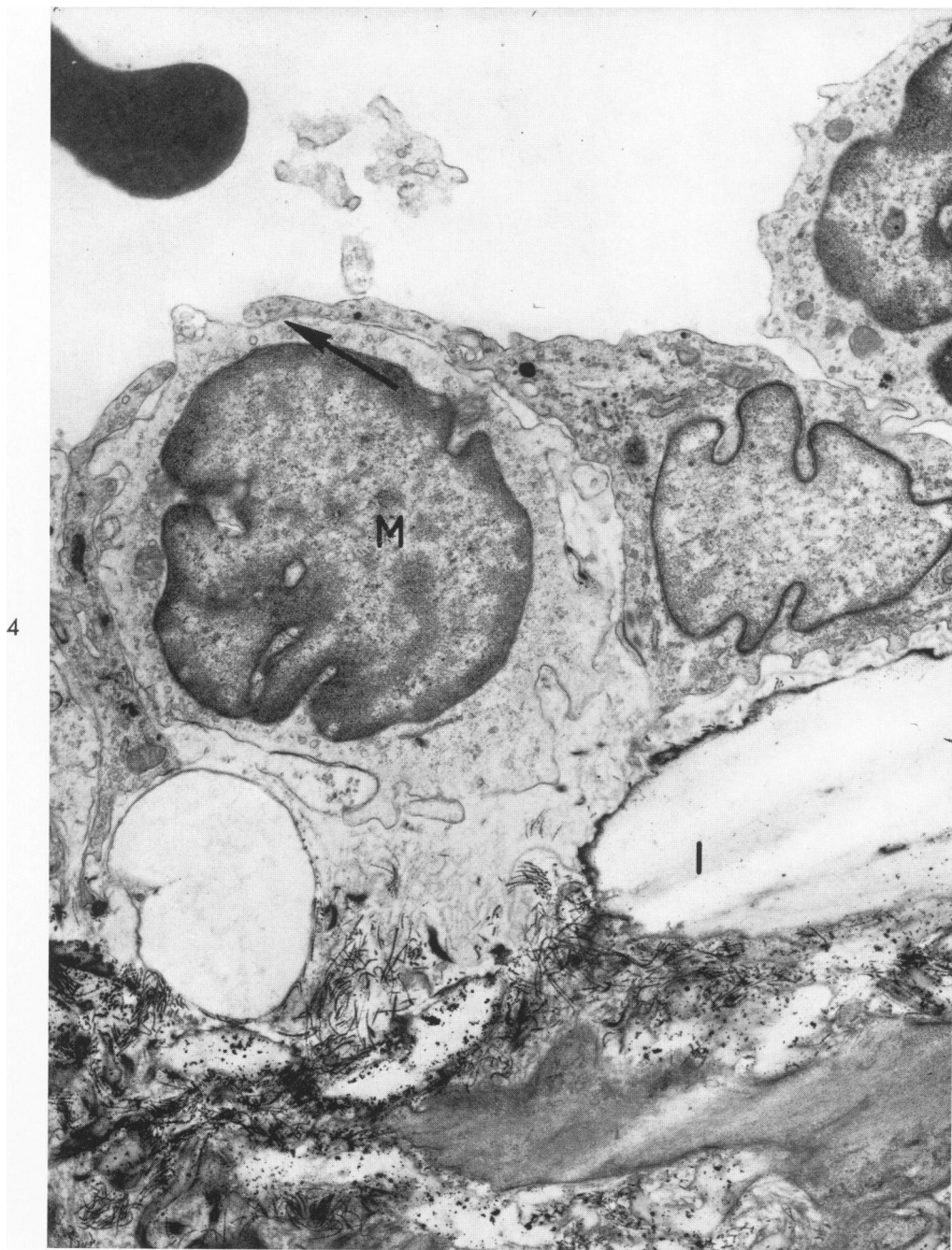

FIG. 4. At 48 hr. after constriction, mononuclear cell (M) has just penetrated endothelium (arrow). Another at right is attached to endothelium by interlocking process. Gap in internal elastic lamina (I) is present.  $\times 8000$ .



5

FIG. 5. Mononuclear cell (M) with large osmiophilic inclusion is in contact with endothelium (E). Note hooklets in endothelium. Granular material has gathered in subendothelial space (G) and is mixed with collagen fibrils. Smooth-muscle cells at bottom left are part of intimal pad of this tissue. Four days after constriction.  $\times 8800$ .

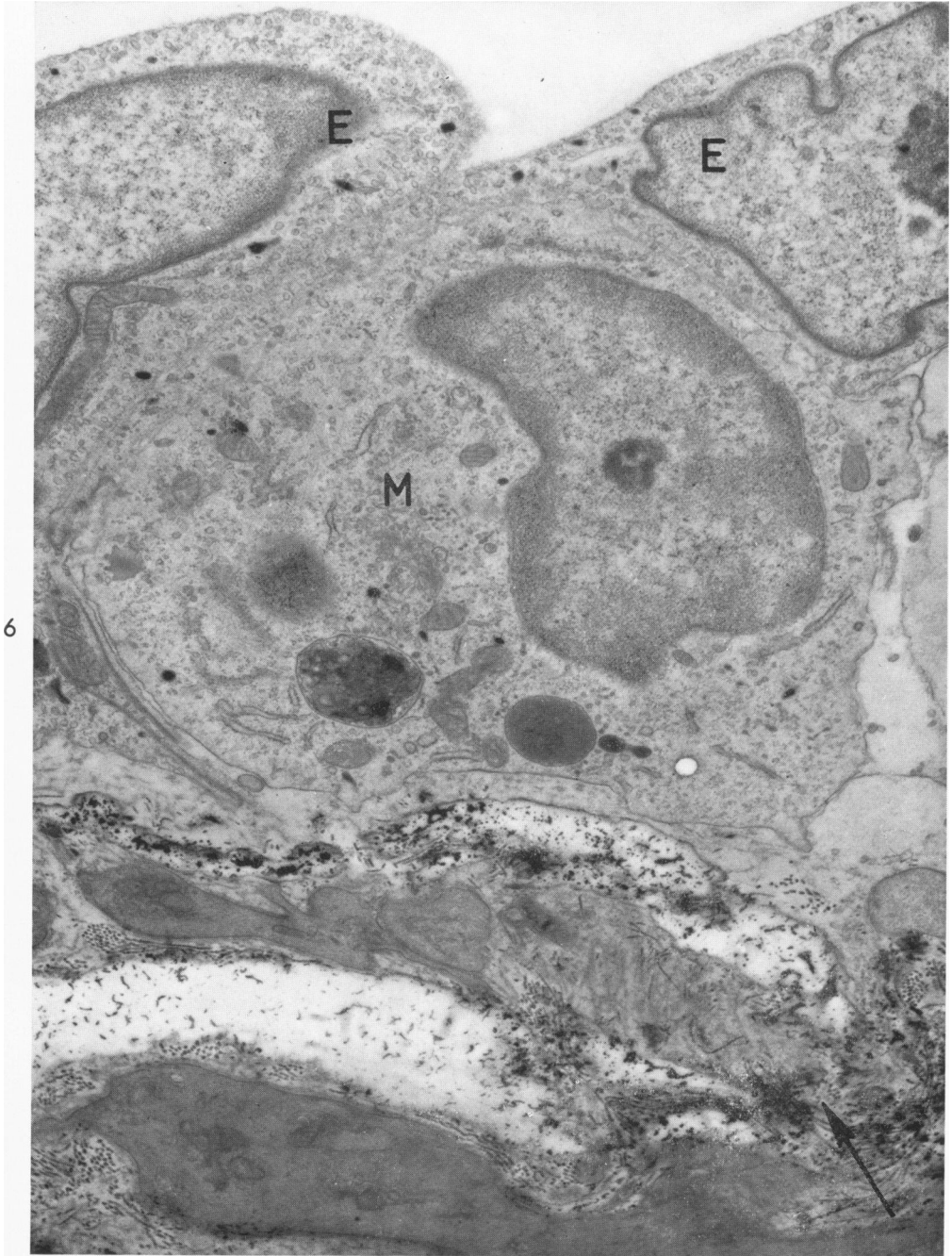
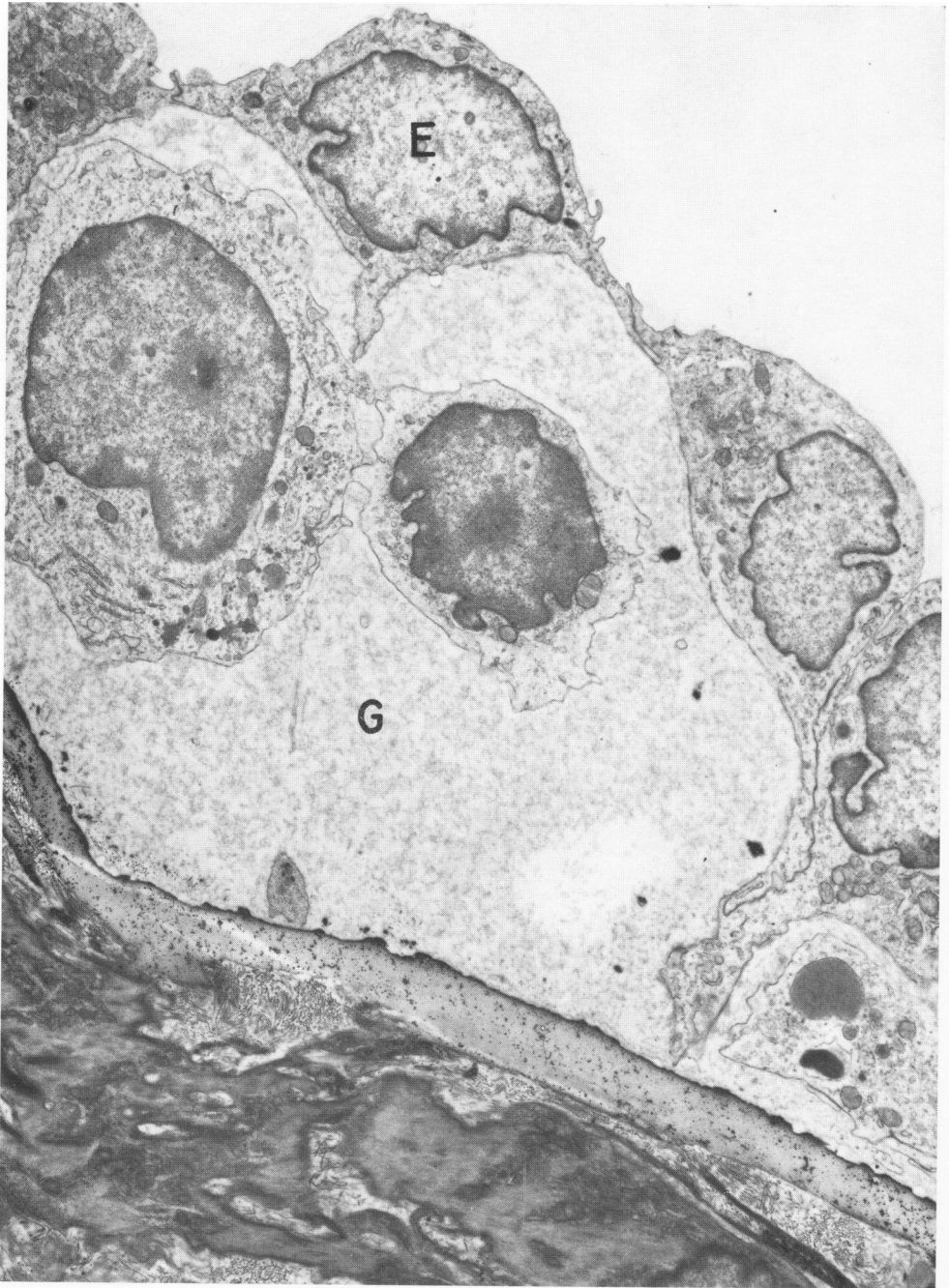

FIG. 6. Mononuclear cell (M) with osmiophilic inclusions of different densities, 48 hr. after constriction. Two endothelial cells (E) show large number of small vesicles. Gap is present in internal elastic lamina (arrow).  $\times 8800$ .



7

FIG. 7. Four days after constriction, subendothelial space is much widened by granular material (G). Mononuclear cells of different types are present in intima, and fragment of cell containing lipid is at bottom right. Endothelium (E) shows a number of hooklets. Internal elastic lamina is continuous.  $\times 4600$ .

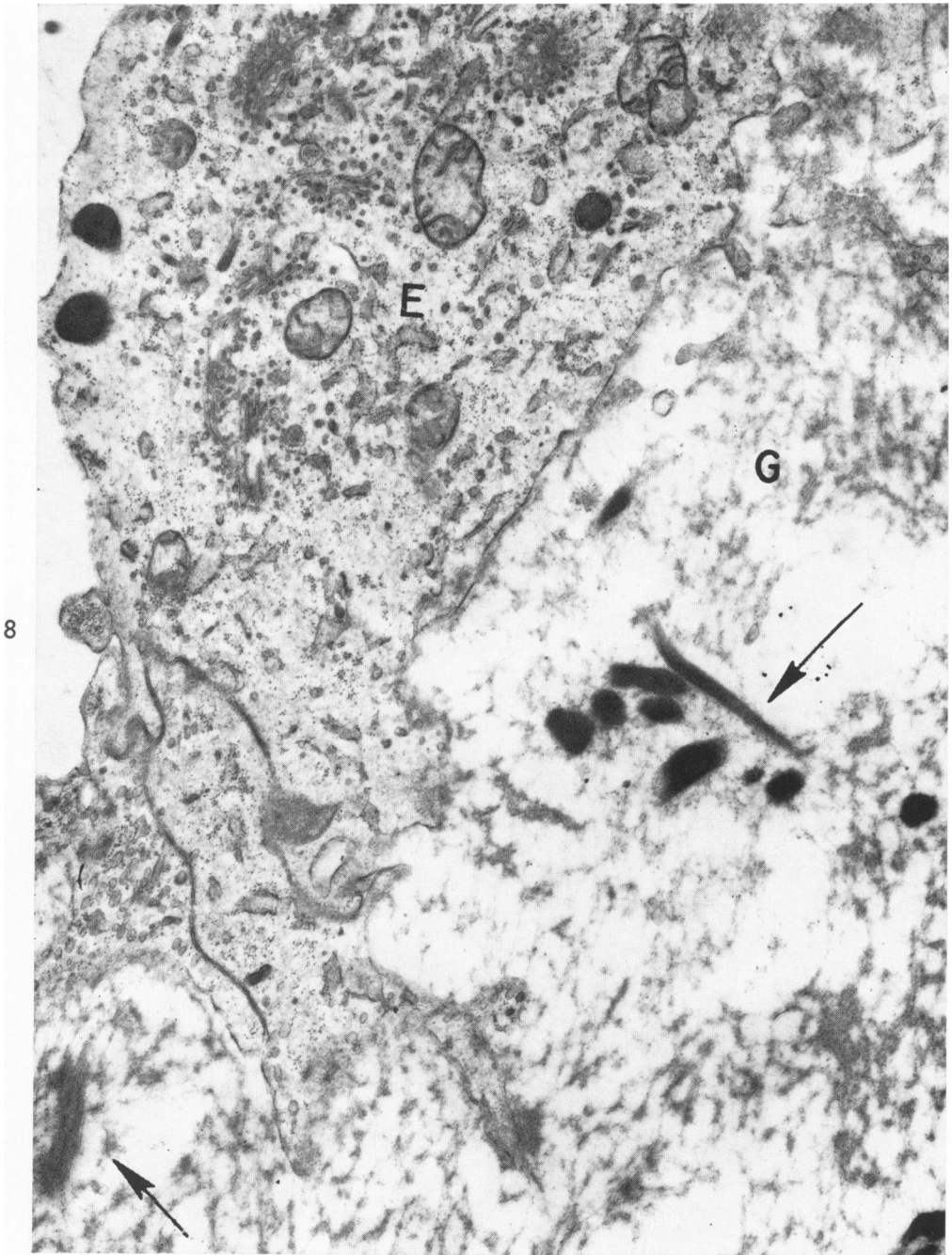


FIG. 8. Endothelium (E) shows prominent increase in smooth-walled lamellae and small vesicles. Granular material (G) in subendothelial space is now more fibrillar in appearance, and strands of fibrin are present (arrows), some with cross striations visible. Seven days after constriction.  $\times 17,400$ .