

GENERALIZED ANGIOMATOSIS PRESENTING THE CLINICAL CHARACTERISTICS OF STORAGE RETICULOSIS

**WITH SOME OBSERVATIONS ON THE RETICULO-
ENDOTHELIOSES**

BY

LEONARD G. PARSONS, M.D., F.R.C.P., and J. H. EBBS, M.D., D.C.H.

(From the Children's Hospital and the Department of Children's Diseases
in the University of Birmingham)

During recent years a considerable and increasing interest has been displayed in those disease conditions which show proliferative changes in the reticulo-endothelial system, and to which, in German literature, the name of reticulo-endotheliosis has been given. Such changes can be evoked by many different stimuli and whereas some forms of activity are hyperplastic and reactive, others are neoplastic in nature; thus they may occur in the presence of abnormal lipoids or as the result of infection and blood destruction, or as proliferative changes of a neoplastic nature, e.g. Hodgkin's disease and certain leukaemias. In a paper published a few years ago, Abt and Denenholz (1936) maintained that the grouping together of such heterogeneous conditions under one heading 'reticulo-endotheliosis' did not present any advantage either for clinical diagnosis or for pathological classification, and at first sight the case here recorded supports their view, since the condition found at autopsy was entirely different from the clinical diagnosis of a storage reticulosis. The different incidents in this case will be described in chronological order, a method which illustrated the way in which the diagnosis varied from time to time and the steps by which the final clinical diagnosis was reached.

Case report

On March 6, 1934, V. D., a girl aged fourteen years, was referred by her doctor to a surgical colleague, Mr. F. A. R. Stammers, for an opinion as to the nature of a swelling of the upper part of the sternum which had appeared suddenly about a month previously. The swelling had not increased much in size during this time, but six months before a similar swelling had appeared and subsided. The lump, which was about the size of a filbert nut, appeared to arise from the lower part of the left sterno-clavicular joint and gave a feeling of fluctuation with doubtful egg-shell crackling at one point. The condition was regarded as due to either tuberculosis or syphilis, or as being a myeloma. A

radiological examination of the sternum was made by Dr. C. G. Teall, who reported as follows: 'Bone destruction and rarefaction in manubrium, ? tuberculous.' Shortly afterwards the child was admitted to a nursing home for the removal of the tumour and it was then discovered that she also had a greatly enlarged spleen. At operation the tumour did not show any resemblance to tuberculous osteitis or a myeloma, but consisted of an air-containing cyst in which were present spicules of bone and some blood. A histological examination of a portion of the tumour was made by Prof. Haswell Wilson, who stated that 'sections show dense fibrous tissue with areas of transition to cartilage and some islands of calcification and imperfectly formed bone. There are some foci of chronic inflammation, round cell infiltration and old haemorrhage; nothing suggestive of myeloma or tuberculosis.'

On March 23 she was admitted to the General Hospital, Birmingham, for further investigation. At this time the spleen almost reached the middle line and the crest of the ilium and an indefinite lump was palpable below the liver. The child was pale and a blood count showed a definite degree of orthochromic anaemia (table 1). A few days later, one of us (L. G. P.) was asked to see her and made the suggestion that her condition was due to a 'reticulo-endotheliosis.' On the assumption that the lump below the liver was a mass of glands, Hodgkin's disease was regarded as the probable form of reticulo-endotheliosis; nevertheless, to exclude the possibility of aleukaemic leukaemia another differential leucocyte count was done, and the long bones were x-rayed. The differential count showed a few immature lymphocytes and myelocytes (table 1), and the report on the x-ray photographs was as follows: 'Similar changes (we presume to those in the sternum) in the humeri, femora, tibiae and right fibula—Hodgkin's disease' (C. G. Teall).

On April 13 the patient was transferred to the Children's Hospital under the care of one of us (L. G. P.) and at this time, apart from the pallor, she did not appear to be ill. Both the girl and her mother, but not her father, had somewhat Jewish features, although a Jewish ancestry could not be traced. The child was fairly well developed although secondary sexual characters were not present. On examination of the abdomen, in addition to the large tumour having all the characteristics of an enlarged spleen, there was an indefinite soft mass in the right subcostal area which was apparently continuous with the liver. The liver itself was enlarged, felt soft, and its lower border could not be accurately determined. Free fluid was not demonstrated in the abdomen and there were no abnormal signs in the chest. There were no tumours palpable in the long bones and indeed, apart from a cloud of albumin in the urine, nothing else was found on physical examination. The Wassermann reaction was negative. Skiagraphs of the long bones showed various areas of decalcification having the appearance of cysts in the upper ends of both humeri (fig. 1 and 2) and of the right fibula (fig. 3), the upper ends (particularly the necks) and also the lower ends of both femora (fig. 4). These skiagraphs were described as being consistent with a diagnosis of Hodgkin's disease. A skiagraph (antero-posterior) of the chest showed 'much shadowing in the lower two-thirds of the right lung field and an appearance of consolidated areas and cavities' (fig. 5), and a lateral view showed consolidation of the right upper and middle lobes. The appearance of the lung skiagraphs was so strikingly similar to that seen in a case of the Christian-Schüller syndrome which had recently been under our care that the question as to whether this case was an example of Gaucher's splenomegaly with bony deposits was immediately raised. A blood count at this time showed a hypochromic anaemia, and the red blood cells showed some anisocytosis. In spite of the fact that up to this date the results obtained from biochemical examination of the blood (table 2) had been essentially normal, it was thought the child might be suffering from Gaucher's disease and therefore

TABLE I
BLOOD COUNTS

DATE	HGB. PER CENT.	RED BLOOD CELLS PER C. MM.	COLOUR INDEX	WHITE BLOOD CELLS PER C. MM.	POLYMORPHS PER CENT.			LYMPHS. PER CENT.	MONOS. PER CENT.	REMARKS
					NEUT.	EOS.	BASO.			
23.3.34	50	2,570,000	0.98	5,200	69.0	1.6	0.6	22.6	6.2	
29.3.34				6,040	67.0	1.6	1.2	21.2	3.6	Myelocytes—2.0. Immature Lymphs. 3.4.
16.4.34	69	4,190,000	0.82	12,250	62.7	0.7	1.3	29.4	6.0	Anisocytosis. Vol. per cent., 72. Vol. Index, 0.87. ? Microcytosis. Sat. Index, 0.96.
29.5.34				6,500	79	1	0	13	7	R.B.C. Normal
4.4.35	70	3,680,000	0.95	7,500	69	2	1	22	6	Crenation of R.B.C. noted in counting chamber and films, which were all carefully prepared.

PRICE-JONES CURVES—

21.4.34. M.D.—7.11 μ . The curve showed slight spread to the right, the largest cell measured being 10.5 μ
 4.4.35. M.D.—7.04 μ . The curve was within normal limits in every respect.

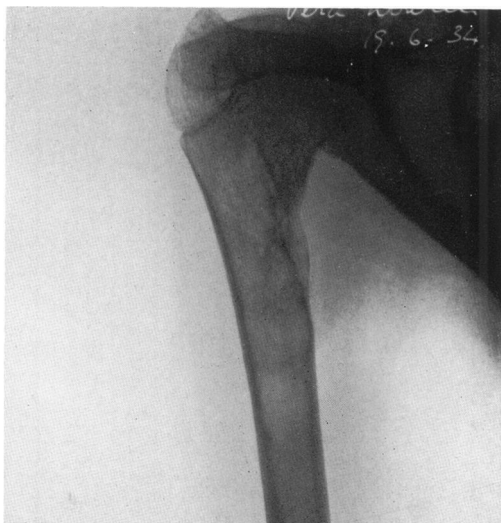


FIG. 1.—X-ray picture of upper end of right humerus showing cystic changes.

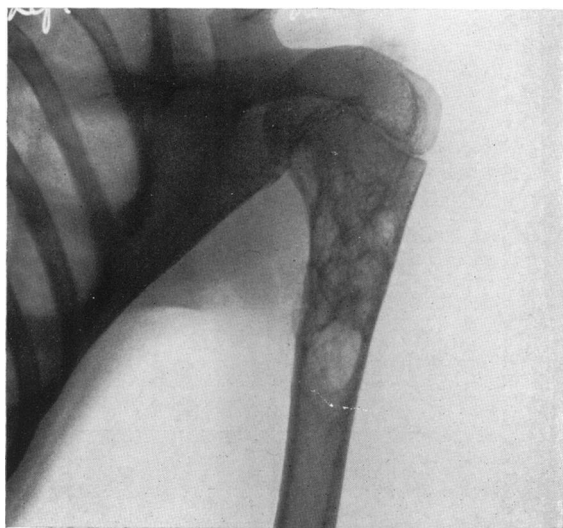

FIG. 2.—X-ray picture of upper end of left humerus showing cystic changes.

TABLE 2
BLOOD CHEMISTRY

DATE	1.4.34		10.4.34		17.4.34		3.5.34		28.5.34		27.6.34		4.10.34		4.4.35		10.4.35		FLUID IN BLOOD SPACES 14.5.35		
	MGM. PER CENT.	MGM. PER CENT.	MGM. PER CENT.	MGM. PER CENT.	MGM. PER CENT.	MGM. PER CENT.	MGM. PER CENT.	MGM. PER CENT.	MGM. PER CENT.	MGM. PER CENT.	MGM. PER CENT.	MGM. PER CENT.	MGM. PER CENT.	MGM. PER CENT.	MGM. PER CENT.	MGM. PER CENT.	MGM. PER CENT.	MGM. PER CENT.	MGM. PER CENT.	MGM. PER CENT.	
Total fatty acids ..	329	559		591	518																246
Total cholesterol ..	188	211	148	400	171				171												126
Phospholipoids ..	180	167		350	214				214												196
Urea ..			29		33				33												87
Non-protein nitrogen ..			31		34				34												61
Amino acid nitrogen ..			13.1		10.2				10.2												8.2
Uric acid ..			2.1		2.4				2.4												7.4
Creatinine ..					1.28				1.28												1.9
Calcium ..					10.6				10.6												8.7
Phosphorus ..					2.6				2.6												20.0
Phosphatase ..					11.1				11.1												
Van den Bergh ..					0.7				0.7												
Chlorides ..																					485
Albumin ..																					319
Globulin ..																					2.3
Fibrin ..																					0

The normal values for blood lipoids (mgm. per cent.) in children according to Erickson, Williams, Hummel and Macy (1937) are: Total lipoids, 336.606 (average 454); total cholesterol, 126.281 (average 182); phospholipoids, 51.175 (average 126).

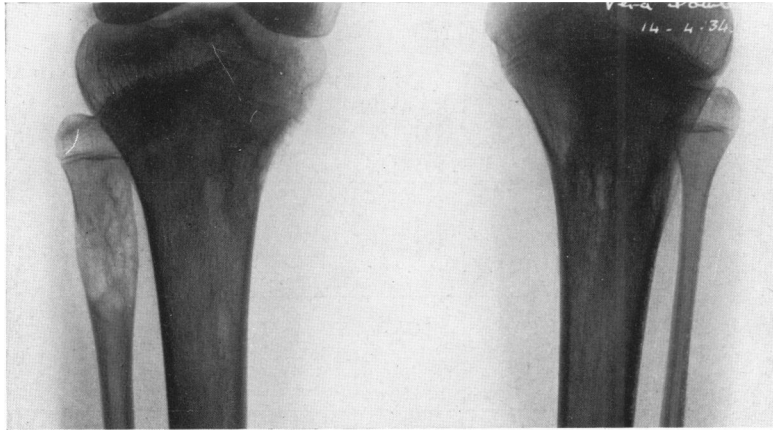


FIG. 3.—X-ray picture of upper ends of tibiae and fibulae showing cystic changes, particularly at upper end of right fibula.

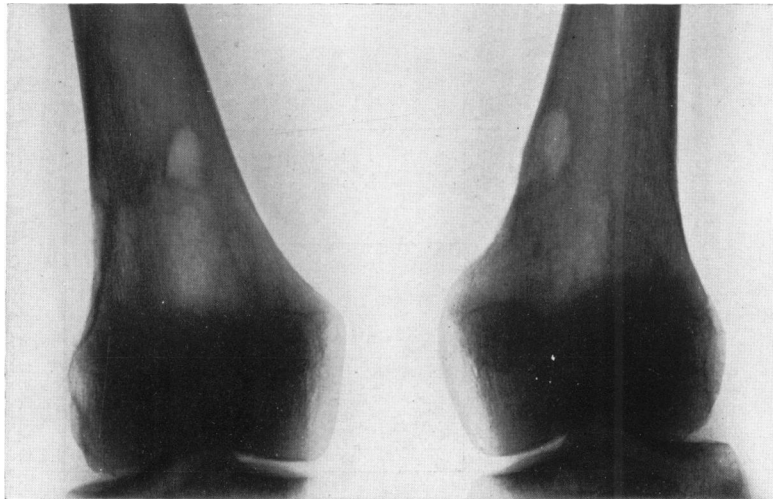


FIG. 4.—X-ray picture of lower ends of femora showing cystic spaces.

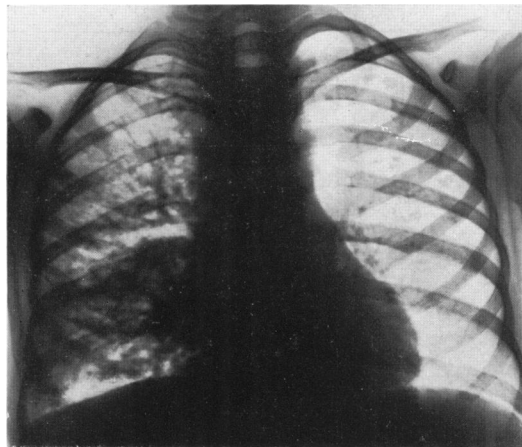


FIG. 5.—X-ray picture of chest showing marked changes in the right lung.

further sections from the tumour removed at operation were examined by the late Dr. R. J. Gittins, who reported as follows: 'Sections of marrow show no abnormal marrow cells. There is much fibrous infiltration around the vessels which show some fibrosis of their coats. The picture suggest a chronic inflammatory reaction but there are no distinctive or characteristic features. Syphilitic infection appears possible.' Gaucher cells were not seen in the sections. Pigmentation of the skin and the wedge-shaped pigmentation of the cornea (pingueculae), which are features of Gaucher's disease, were absent and slit lamp examination of the eyes did not reveal any abnormality.

The presence of a normal percentage of cholesterol in the blood did not necessarily exclude a lipoid disease, because the blood cholesterol is frequently low in Gaucher's disease and may be normal in patients suffering from the Christian-Schüller syndrome despite the fact that the abnormally stored lipoid in that disease is a cholesterol ester; moreover the total lipoids and phospholipoids in the blood have been found to be normal in proved cases of Gaucher's disease (Pachman, 1938). Nevertheless, further investigations were carried out and on May 3, 1934, high values for blood cholesterol and phospholipoids were obtained (table 2). These findings were regarded as strong evidence in favour of a lipoidosis and the diagnosis of Gaucher's disease was accepted. At this time, also, the blood calcium and phosphorus were estimated and were found to be 10.6 and 2.6 mgm. per cent. respectively, the latter being a somewhat low value, the normal at her age being about 3 mgm. per cent. The immediate direct Van den Bergh reaction on the blood serum was negative, the delayed reaction was slightly positive and the indirect showed 0.7 units of bilirubin (0.2 to 0.5 normal).

Because of the diagnosis of Gaucher's disease, x-ray treatment to the spleen was started and the child was discharged on June 22, 1934, but continued to attend the out-patient department for x-ray treatment until April 1935. During this time further biochemical examinations of her blood were undertaken and radiographic changes appeared in the vertex of the skull, the pelvis, the upper ends of the tibiae and the left fibula (see fig. 6 to 10), but her general condition

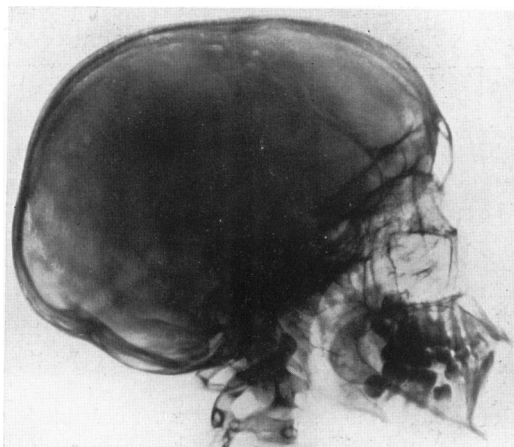


FIG. 6.—X-ray picture of the skull showing small areas of rarefaction in the vertex.

did not show any deterioration, although the abdomen enlarged slightly as a result of further enlargement of the liver and spleen.

* Fig. 6 to 10 were taken six weeks before death and one year after fig. 1 to 5.

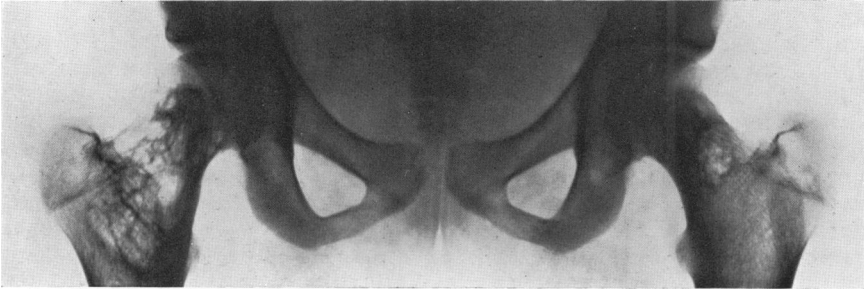


FIG. 7.—X-ray picture of upper end of femora showing extensive changes in neck of the right femur.

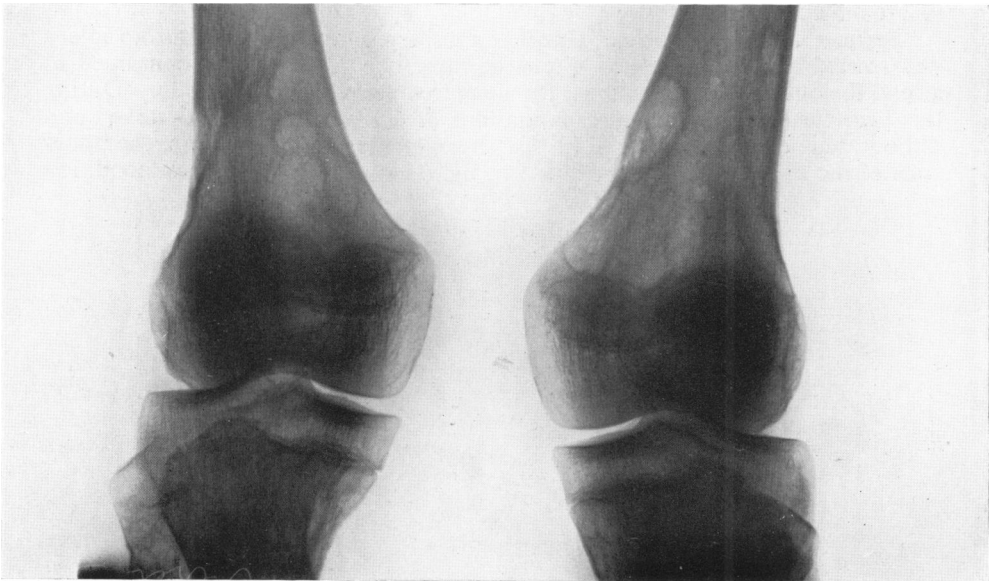


FIG. 8.—X-ray picture of lower end of femora for comparison with fig. 4.

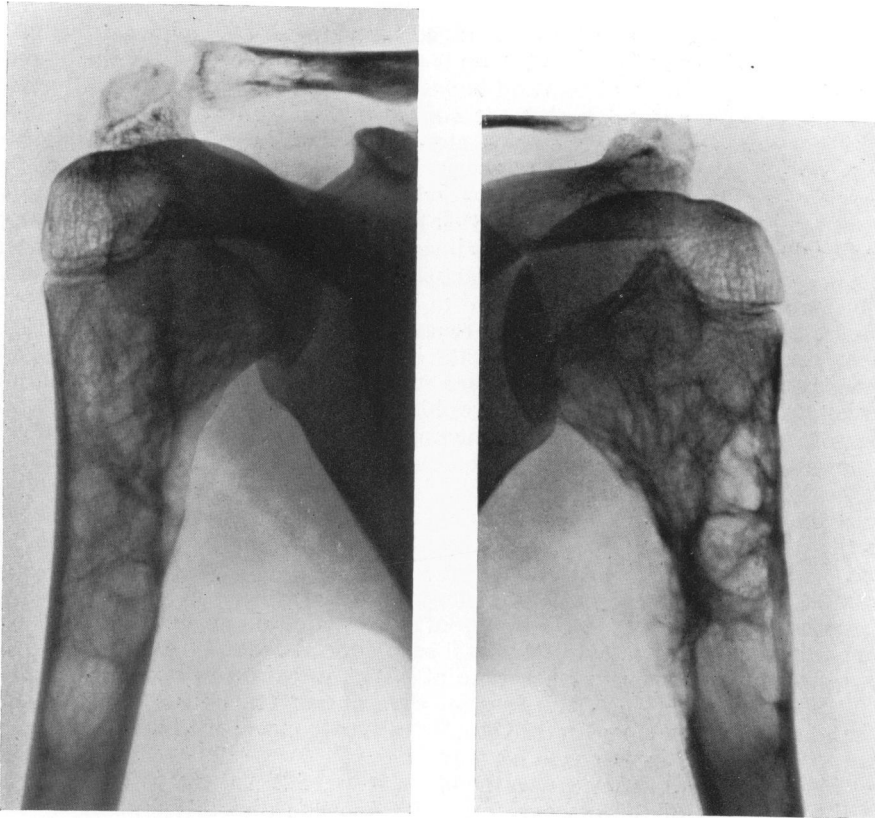


FIG. 9 and 10.—X-ray picture of right (fig. 9) and left humerus (fig. 10) showing an extension of the changes seen in fig. 1 and 2.

Differential diagnosis. The points which during this child's life seemed to justify the diagnosis of the 'osseous form of Gaucher's disease' can be summarized as follows: an enormous degree of splenomegaly, hepatomegaly, infiltration of the lung, cystic areas and tumours in the long bones, an abnormal condition of the blood lipoids, hypochromic anaemia, a Jewish facial appearance, good nutrition, normal blood calcium, the absence of a palpable parathyroid tumour and also of Bence-Jones protein in the urine. It is true that the following characteristics of the disease were absent: family history, Jewish parentage, pigmentation of the skin, brownish pingueculae, persistent leucopenia, the club-shaped appearance of the lower ends of the femora in the skiagraphs, foci in the mandible, and Gaucher's cells at biopsy of the tumour. The absence of these signs is, however, not as important as at first sight might appear to be the case. For instance, the disease does not always show a familial incidence, nor are the patients invariably Jewish; skin pigmentation is absent in 25 to 55 per cent. of the cases and pingueculae are among the rarer manifestations of the disease. The skiagraphic appearances in the bones in the present patient are like those figured by Abt and Bloom (1928) in a case of Gaucher's disease and are also similar to those sometimes found in the Christian-Schüller syndrome. They are strikingly similar to the bone changes described by van Creveld and Poorten (1935) in a child which during life was thought to be an example of

the Christian-Schüller syndrome, but which did not show any evidence of that disease at autopsy, and which they classified as an infective reticulo-endotheliosis. An interesting point in this connexion is that during the lifetime of the present patient skiagraphs of her lungs and bones were shown to Professor van Creveld who expressed the opinion that the condition was a form of the Christian-Schüller syndrome. Leucopenia is always stressed as an important sign in Gaucher's disease, and both it and the anaemia have been regarded as due to the presence of Gaucher cells in the marrow (myelophthitic anaemia). This view is not accepted by Castle and Minot (1936), and if indeed this be the true explanation of the blood changes it is extraordinary that leucopenia is not characteristic of all forms of storage reticulosis; actually the opposite sometimes happens. Thus, leucocytosis has been described in Niemann Pick's disease, in Gaucher's disease itself and in other forms of reticulo-endotheliosis. Gittins (1933) has given good reasons for believing that the changes in the reticulum in haemolytic anaemia and in storage reticulosis are reactive in nature and that sometimes reticulum cell proliferation and argyrophil reticulin fibril formation may replace marrow tissue and result in the production of an aplastic blood picture. Such a view furnishes a more reasonable explanation of variations in the blood picture in the various forms of reticulo-endotheliosis than the one which regards them solely as a mechanical result of the presence of masses of storage reticulum cells. In the present case the majority of the white cell counts ranged between 5,200 and 7,500, although they have reached 12,250 per c.mm. (table 1). The most formidable argument against the diagnosis of Gaucher's disease was the absence of Gaucher cells in the biopsy of the sternal tumour, but it was thought that this was because these cells had been squeezed out of existence by the excess of fibrous tissue; such a state of affairs is known to occur, since Brill and Mandelbaum (1913) have shown that during the course of Gaucher's disease there is a tendency for the Gaucher cells to elongate and later to disappear and to be replaced by intercellular fibrosis.

Weighing up all the evidence, therefore, it was felt that the points in favour of the diagnosis of the osseous form of Gaucher's disease considerably outweighed those against it, and this diagnosis was therefore accepted. It will be noted that a diagnostic splenic puncture was not made, the reason for this being that we have never been completely satisfied about the safety of this procedure. Although the findings at autopsy rudely shattered any feeling of pride in our diagnostic acumen they did at least furnish the consolation that this caution in the matter of splenic puncture was completely justified. The child did not attend the hospital after the middle of April 1935, and on May 12 of that year she died suddenly during the night. During the day before she had developed fever, cough, and difficulty in breathing. A post-mortem examination was performed by one of us (J. H. E.) at her home on May 13.

Autopsy summary

Female, aged fourteen years, height 5 feet. The extremities were slightly wasted and there was a small healed operation scar over the upper part of the sternum. The abdomen was very prominent, the circumference at the umbilicus being 31.5 inches. The skin showed a purpuric rash consisting of numerous small, bluish-black nodules, varying in size from one millimetre to one centimetre in diameter, some of the larger ones being slightly raised. Some of these nodules had the appearance of extravasated blood, whereas others were naevoid in appearance showing slight dilatation of small capillaries. They all appeared to be of recent origin.

In the abdomen the liver was found to occupy the whole area exposed

extending from the costal margin to the symphysis pubis, and measured fourteen inches long by fourteen inches wide. The two lobes were well defined by a prominent fissure. The most striking feature, however, was the presence of a large number of dark cysts on the surface which varied in size from minute swellings to the size of a hen's egg; these cysts were purplish-black in colour and contained thin, blood-stained fluid (fig. 11 and 12). Dense fibrous adhesions

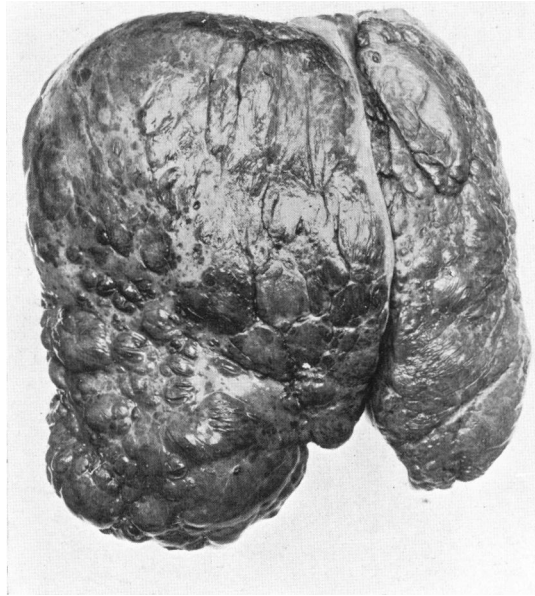


FIG. 11.—Anterior surface of liver showing multiple cysts.

bound the upper surface of the liver to the diaphragm and several cysts were ruptured during its removal from the body. The cut surface of the liver (fig. 13) presented the appearance of a large irregular sponge, the cystic spaces being of an angiomatic nature and forming a complete network throughout fully four-fifths of the liver substance, the only recognizable liver tissue remaining being a small, pale, yellowish red area in the central zone. Except for dense adhesions the gall-bladder appeared normal.

The spleen (figs. 14, 15 and 16), which was pushed to the extreme left side of the abdominal cavity by the liver, was unusually large, reached the brim of the pelvis and measured 10 by $6\frac{1}{4}$ by 5 inches. It was firm with a dark greyish-green mottled surface, and there were dense adhesions between its antero-superior surface and the parietal peritoneum. The cut surface was fibrous and showed an irregular network of cystic spaces with thick walls, some of which were filled with thin serous fluid, others with dark blood, and still others with a milky, gelatinous material. Here and there recent small haemorrhages were seen.

A large retroperitoneal mass measuring $6\frac{3}{4}$ by 7 inches, was found beneath the left lobe of the liver; this had its origin in the region of the root of the mesentery and consisted of several large, thin-walled cystic spaces which ruptured during removal and discharged a thin sanguineous fluid. The peritoneal cavity contained several ounces of blood-tinged fluid.

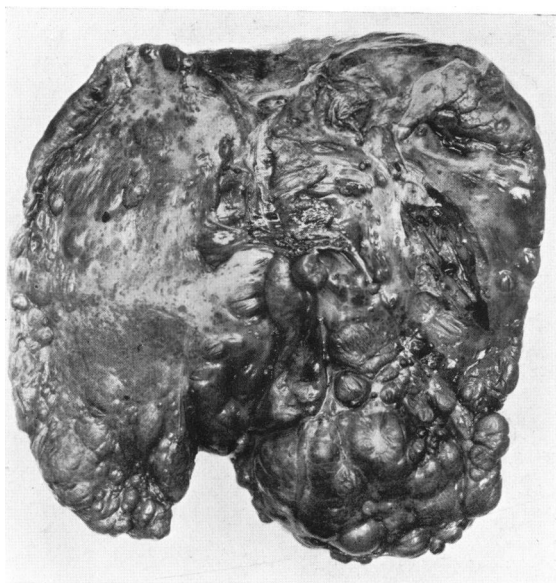

FIG. 12.—Posterior surface of liver.

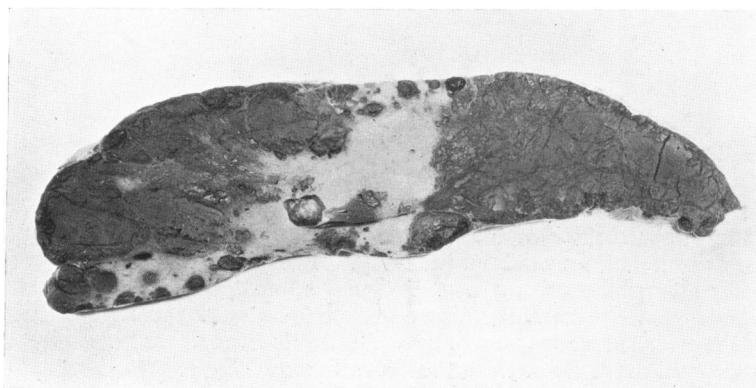


FIG. 13.—Cut surface of liver showing large area involved by the formation of cysts, only a small central portion being free of them.

Both kidneys were normal in size, soft in consistency and presented a mottled surface due to the presence of numerous brownish-black haemorrhagic areas in the cortex, all of which appeared to be of recent origin.

On opening the thorax about three ounces of thin pinkish fluid were found in each pleural cavity. The left lung was dark reddish-grey in colour and showed marked congestion and early broncho-pneumonia but there were no cystic changes to be seen. The right parietal pleura showed several small blood cysts hanging from its surface. The right lung presented many firm, fibrous adhesions over the posterior surface of the base and apex, was reddish-black in colour and showed numerous angiomatous cysts on its surface. There was little normal lung tissue recognizable, all the lobes showing evidence of marked congestion,




FIG. 14.—Anterior surface of spleen.

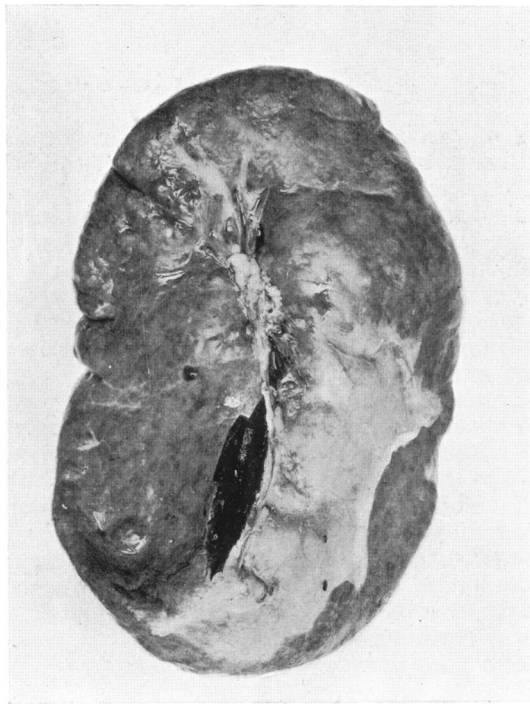


FIG. 15.—Posterior surface of spleen.

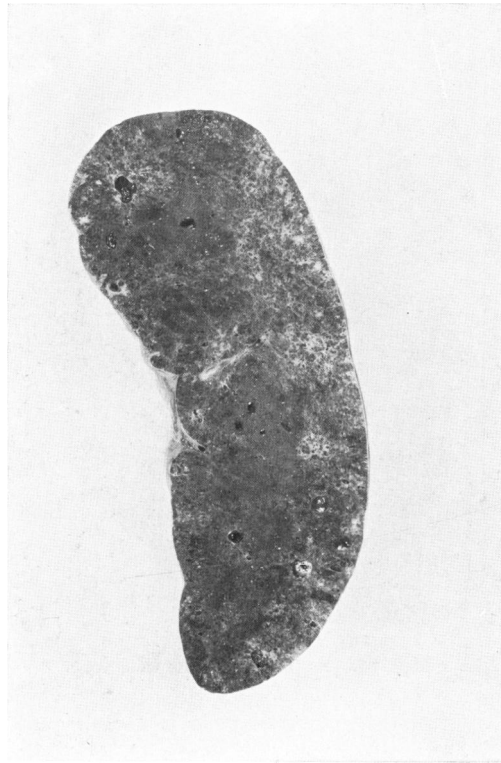


FIG. 16.—Cut surface of spleen.

a dense network of cystic spaces, and considerable fibrosis. The bronchi contained thick mucus, but there was no evidence of their dilatation nor of involvement by the cystic changes.

The thymus gland was prominent and consisted of two lobes. The left lobe showed no change, but the right consisted of multiple cavernous angiomata filled with dark fluid blood.

The pericardium presented several cysts over its surface; clusters of these were seen in the region of the origin of the great vessels and presumably arose from mediastinal lymph glands. The heart showed no evidence of involvement by the process and presented no gross abnormalities.

BONES. The posterior portion of the eighth rib on the right side showed an area of tumour formation two inches in length, dark greenish-black in colour, and involving the whole thickness of the rib. This area was soft, allowed free bending of the rib at this point and consisted of numerous thin-walled cystic spaces, filled with blood-stained fluid. Similar lesions were noted in the seventh rib on the right side and smaller lesions in the fifth and seventh ribs on the left side. The manubrium sterni was thickened and the cut surface showed empty cystic spaces having thin walls and confined to an area in the region of the left sterno-clavicular joint (fig. 17). Similar lesions were found in the neck of the right femur. The other bones were not examined.

No gross abnormalities were detected in the other organs.

Microscopical examination. **SPLEEN.** Numerous pieces of tissue taken from different parts of the organ were examined and all the sections revealed a similar picture (fig. 18). The general structure was sponge-like in nature, with cavernous angiomatic spaces occupying about two-thirds of the spleen. These cavernous spaces varied in size from quite small to large spaces, some of which were filled with blood and others with clear serum. A few had lost their contents or had not

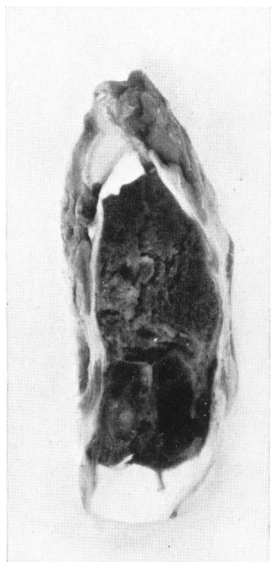


FIG. 17.—Upper surface of manubrium sterni showing cystic spaces beneath original operation site near left sterno-clavicular joint. (Natural size.)

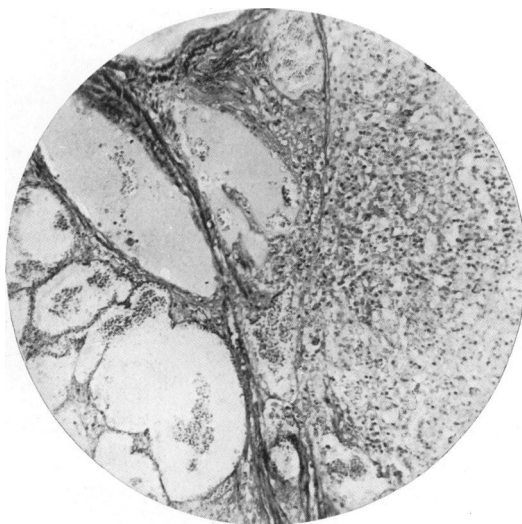


FIG. 18.—Spleen, showing arrangement of angiomatic spaces ($\times 95$).

been filled. Some of the spaces were separated by thick fibrous septa, whereas others were separated by a thin layer of cells and all were lined by endothelial cells. The nuclei of the endothelial cells varied in size and shape, some being round and lightly stained with granules, while others were long and darkly stained; the latter were more frequent in the thick wall where fibrous tissue had formed. In the remaining areas of spleen the splenic pulp showed fairly marked congestion.

LIVER. There were extreme variations in the size of the cavernous spaces which contained red blood cells, fibrin and a few leucocytes with a relative increase of the polymorphonuclear cells (fig. 19). In a few spaces there was evidence of post-mortem thrombus formation. The septa varied greatly in thickness from those consisting of a single layer of large spindle-shaped endothelial cells to those (fig. 20) which were thick, having a lining of long endothelial cells. There was much collagen and fibrous tissue present in the septa. The lining cells besides being long, had long pale nuclei. A few cells showed two nuclei but there were no mitotic figures and they did not appear malignant in the usual histological sense. The large septa showed papillary projections and contained small capillaries.

LUNGS. Both lungs showed considerable congestion, the alveoli contained a few blood cells, numerous large pigment-containing 'heart-failure cells' and

a few leucocytes (fig. 21). Scattered areas, especially at the surface, contained small cavernous angiomas with thin walls formed by a single layer of endothelial cells (fig. 22). Sections taken from the root of the right lung revealed a

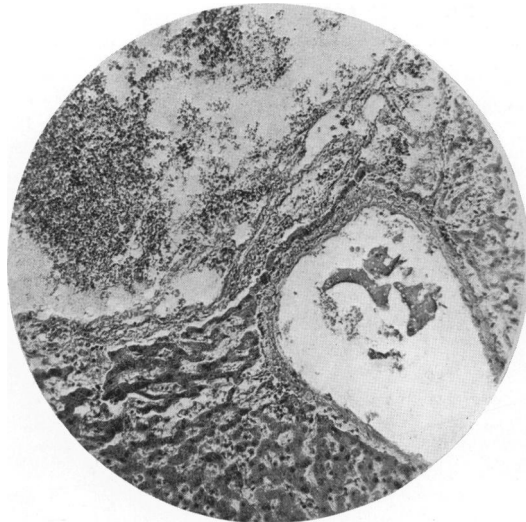


FIG. 19.—Liver: large cavernous space at edge of comparatively normal liver tissue ($\times 95$).

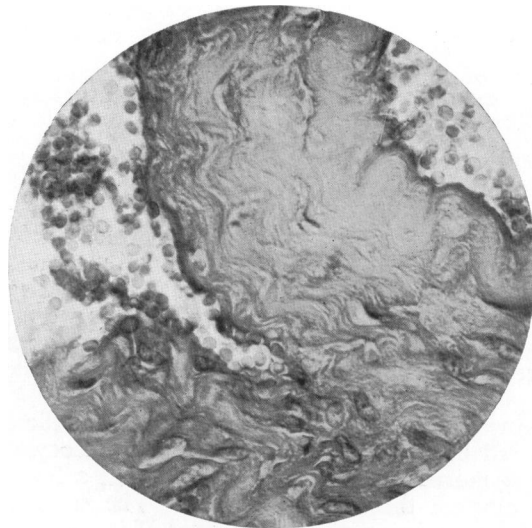

FIG. 20.—Liver: thick septum dividing a large angiomatous cyst ($\times 420$).

more chronic invasion of the lung tissue by angiomas. Here the cavernous spaces were large with thick fibrous walls, communicating with each other but no communications were found with normal blood vessels or with bronchi.

KIDNEY. Sections taken in the areas which appeared haemorrhagic in the gross specimens showed normal kidney tissue being invaded by small cavernous spaces. The glomeruli and tubules were compressed and in some places

flattened out between two septa of these spaces. The septa were lined by the same long endothelial cells seen in the sections of other organs. The process of formation and spread of the cavernous spaces appeared to be of recent origin since none was large and many glomeruli and tubules appeared normal.

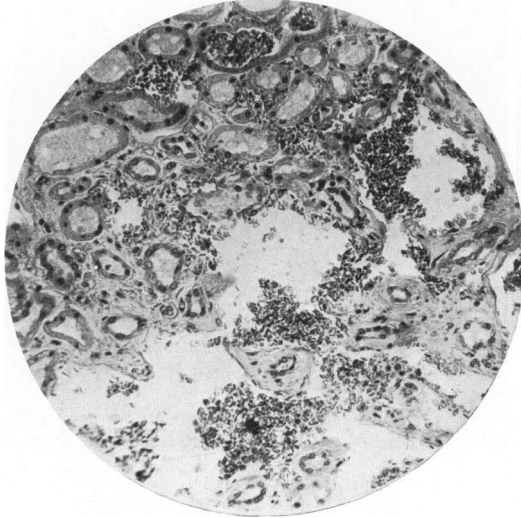


FIG. 21.—Lung: angiomas spaces showing fibrosis of septa. Alveoli filled with red blood cells and fibrin ($\times 100$).

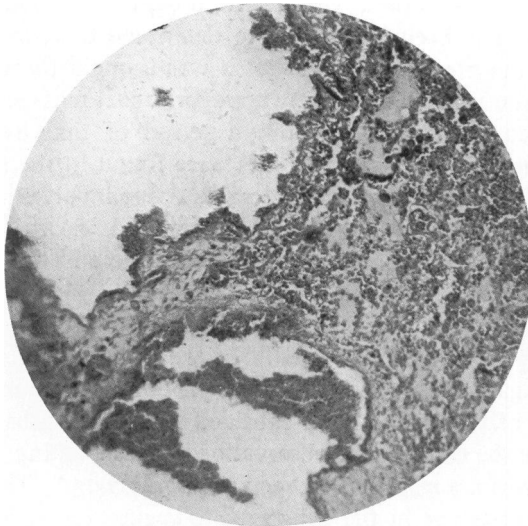


FIG. 22.—Lung: wall of angioma space shown in fig. 22, showing long lining endothelial cells.

Recent extravasations of blood were seen between the tubules which had not been reached by the process (fig. 23).

Sections of thymus and bone showed cavernous angiomas similar to those described in other organs.

L

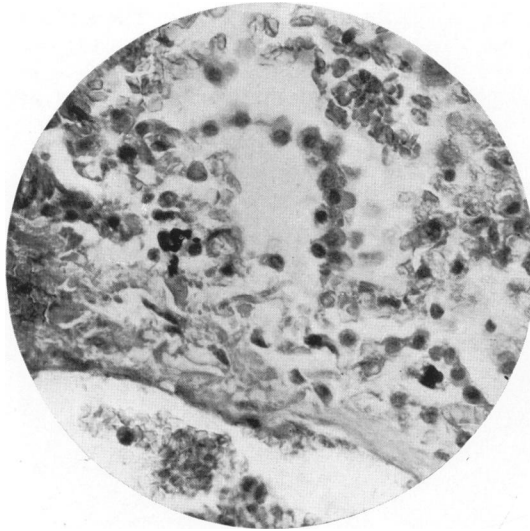


FIG. 23.—Kidney: haemorrhage and early spread of tumour between tubules. A few tubules remain isolated and surrounded by spaces which are lined by a layer of young endothelial cells ($\times 100$).

Site of origin of angiomata

In the literature angiomata are described as usually arising in the liver or the spleen, and more rarely in the thymus, skin, lung, bone marrow and retroperitoneal glands. It has been impossible to determine the site from which the tumour arose in the present case; at first it was thought to be the spleen, but further study of the liver and the large retroperitoneal mass showed that these had probably been involved for as long a period of time as the spleen, and although it is true that the largest masses were found in the spleen, liver and retroperitoneal glands, there was considerable tissue involved in the lungs, the thymus, many of the bones, the pericardium and pleura. The degree of involvement of any one organ, therefore, does not help in solving the riddle of the site of the tumour.

The onset and character of the chief signs and symptoms are usually determined by the organ primarily affected. In the present case, the first clinical sign was a swelling appearing over the upper part of the sternum twenty months before the death of the child, which subsided for five months and reappeared one month before she came under observation. This swelling fluctuated at one point and there was a suggestion of 'egg-shell crackling.' There was nothing in the clinical findings nor in the skiagraph to suggest an angioma, nor did the microscopical appearance at operation suggest anything other than a bone cyst, whilst the microscopical appearances of the fragments of bone removed at operation were inconclusive. Nevertheless, reviewing these sections with the advantage of a knowledge of the post-mortem data it is possible to find protruding from the bone marrow remnants of the lining endothelium of what were undoubtedly cavernous angiomatous spaces (fig. 24 and 25).

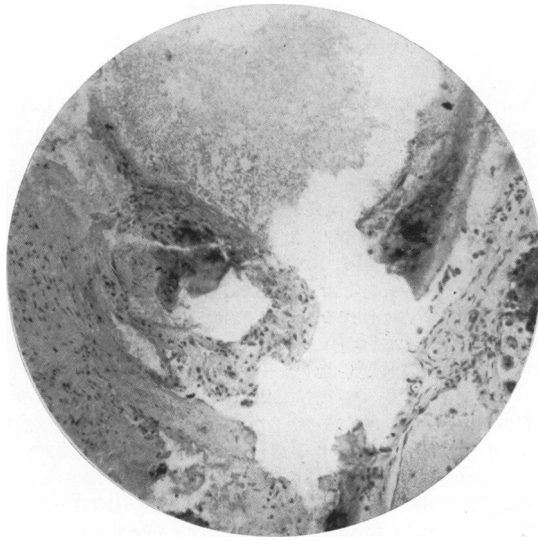

FIG. 24.—Sternum: cystic space below operation site.

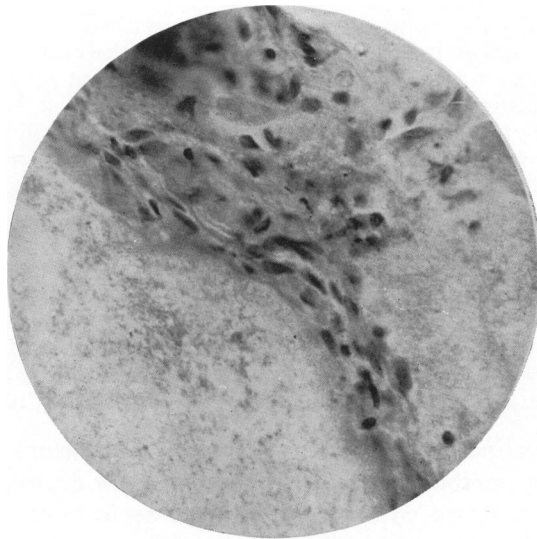


FIG. 25.—Sternum: endothelial lining of the cystic spaces shown in fig. 24.

In a study of the sections the kidney appears to be the most recently affected organ and here the spread of the angiomatic process into normal kidney tissue can be seen. This invasive tendency of the tumour is the only evidence of malignancy because individually the cells do not appear malignant; indeed, the striking characteristic of the tumour in every situation is the uniform and typical appearance of its cells which are long, spindle-shaped and fairly uniform in size with an oblong rather lightly staining single nucleus. There is no evidence of multinucleated giant cells nor of the spread of the tumour through or along the

walls of normal blood vessels. Examination of numerous portions of the organs which were available for histological examination does not suggest a secondary or metastatic growth arising from a primary focus; nowhere, in fact, does the structure vary from that of cavernous spaces lined by long endothelial cells, nor is there any suggestion of solid masses or bands of endothelial cells arranged in clumps or whorls to resemble an endothelioma.

In 1914, Shennan reported a remarkable case which in most respects is the counterpart of our own. This was a young woman, aged twenty-three years, who, when seventeen years old, developed a cough followed by anaemia, amenorrhoea and haemoptysis, the latter symptoms being due, it was thought, to a 'spongy' throat. When she came under observation she was anaemic and the spleen was enlarged to three inches below the costal margin; there were no abnormal physical signs in the chest although blood was brought up by a slight cough. During the subsequent course of her illness the first acute symptom was pain in the left side and signs of an internal haemorrhage. Haemoptysis recurred and seemed to be related to her irregular menstruation. The anaemia was sometimes secondary in type but occasionally 'pernicious' with a high colour index, variable poikilocytosis and a few erythroblasts. Purpuric spots appeared over the face, chest and arms, some of these being naevoid in appearance. One of the latter was removed from the buttock, but recurred and the histological sections showed dilated blood cavities, lined by endothelium. One year before death the upper part of the sternum and the inner end of the left clavicle became swollen and tender. During this time her general health improved but the spleen increased in size until it reached the crest of the ilium. Under treatment by x-rays the spleen became smaller and nodular; abdominal distension also occurred and repeated tapplings were required, large quantities of bloody fluid being removed (e.g. 160 oz., 72 oz., 190 oz.) on different occasions. The patient died suddenly and at post-mortem multiple cavernous haemangiomas were found which involved the entire spleen, the thymus, the mediastinal lymph nodes, portions of the lungs, the liver, the bone marrow, kidneys, sternum, left clavicle and bodies of the lumbar vertebrae. Histologically these tumours were non-malignant, but locally they exhibited a certain invasive tendency. The nature of the tumour formation was thus described by Shennan: 'In its mode of extension and in its effects upon the tissue, it is undoubtedly malignant'; on the other hand, Hall (1935), in view of the fact that the foci were largely confined to the haemopoietic system and were all histologically benign, regarded the case as an example of 'multiple foci' or 'system disease' tumour.

From this description it is obvious how closely Shennan's and the present case resemble one another; moreover, the water-colour drawings, photographs and photomicrographs which illustrate his paper depict appearances so similar to those seen in the present case, that they can be regarded as examples of the same clinical syndrome. The similarities between the two cases may be thus classified. First, the clinical histories have the following points in common: sex, duration, splenomegaly, anaemia, swelling of the upper part of the sternum and inner end of the clavicle, ascites and involvement of the lungs. Secondly, at autopsy the localization of the tumour masses were almost identical in each case, namely in the liver, spleen, mediastinum, thymus, kidneys, sacrum, clavicle and other bones. Thirdly, on histological examination of the tumours, the type of cell, the general structure, and the relation to normal tissues are extraordinarily alike in both cases. The only difference between the two patients is

that the liver in Shennan's case was not so extensively involved as in the present case.

Shennan's case is the only one discovered in the literature which is truly comparable with the one here reported, although it is not improbable that a case recorded by Grabowski (1927), under the title 'Angioma sarcomatodes systemisatum,' is a third example of this syndrome. Grabowski's paper was a thesis for the M.D. Degree of the University of Warsaw, and shortly before war broke out negotiations were in progress with the University of Warsaw for the loan of this thesis; now, alas, it is unavailable and it is even doubtful if the University Library exists. An abstract of the thesis in a German periodical, however, gives some details of the case.

The patient was a man aged thirty-two years who died seven months after the removal of an enlarged spleen. Microscopy of the organs showed a proliferation of the vascular endothelium, with a tendency to cavernous formation in the spleen, liver, bone marrow, lymph nodes, suprarenals and kidneys, and in the liver and spleen there was also sarcomatous proliferation of the endothelium. Since the endothelium of the blood-forming organs was affected and since all possible intermediate stages between the normal and pathological structures were found, the condition was considered to be 'a diffuse systematic affection of the endothelial part of the histiocytic apparatus.'

Etiological factors

It is now universally accepted that angiomas are due to a congenital developmental defect whereby vascular tissue is laid down which retains its embryonal characters and from which the angiomas grow independently. Virchow maintains that angiomas are caused by irritation of this embryonal tissue and Ewing (1928) states that 'cavernous angioma arise at any period of life—from congenital naevi—or in deep tissues, and they slowly enlarge by distension of the original vessels, and by formation of new vessels.' Foote (1919), however, believes that the disease arises in infancy from embryonic endothelium and that in adults it may arise from congenital naevi or from foetal inclusions which have remained dormant.

There are, however, certain other possible etiological factors. In a few instances the suggestion has been made that the tumours arise from a congenital naevus of the skin. In Shennan's patient cutaneous naevi were not present at the onset, but did appear later and were present for some time, one actually recurring after surgical removal. In the present case naevoid areas in the skin appeared shortly before death, although it is possible that they may have been present for a longer period in the deeper tissues of the skin; moreover, it is true that the swelling of the upper part of the sternum was an angioma which presented beneath the skin, but there is no evidence that this was the primary tumour. Borrmann (1907) reported the case of a woman aged twenty-six years who developed a simple angioma in the skin of the right breast which was removed surgically, and subsequently recurred several times; histologically all the recurrences were non-malignant and at autopsy many foci of similar structure were found in the lungs. Several other authors have reported cases of angiomas

in multiple organs associated with involvement of the skin, and those reported by Wollstein (1931), Bruchanow (1899), Orzechowski (1928), Schonberg (1923), Ewing (1928), Stamm (1891), Romdohr (1878), Ernst (1912) and von Falkowski (1914), show evidence that the skin may have had some significance in the origin of the tumour.

The possible relationship between portal cirrhosis and the origin of angiomata in the liver has been discussed by Ogilvie and Mackenzie (1936), who found five such instances in the literature and in addition five others in which the angiomata arose from the K upffer cells in otherwise histologically normal livers, and three in which the tumours originated in the endothelium of the branches of the portal vein.

The question of the relation of specific congenital defects to the development of angiomata has also been raised by several writers; for instance, Hall (1935) in recording a case mentions a congenital anomaly in the right coronary artery which might have etiological significance, and Parker (1880), Orzechowski (1928), and Spiegel (1929) also considered the same point but without arriving at any definite conclusion.

From a study of the literature it appears that multiple haemangiomas are slightly more common in the female sex, this applying particularly to the 'system tumours.' The growth of the tumour and the relation of symptoms in Shennan's case seem to be related in some way to menstruation; Schlopsnies (1929) reported a case which followed childbirth, and the breast was the primary site in the cases described by Borrmann (1907), Ewing (1928), Robinson and Castleman (1936) and possibly Ross (1932).

Several authors produce considerable support for the theory that multiple haemangiomas have their origin in multiple foci; this view is held by Wollstein (1931), on the ground that the foci in her patient, although differing in size, were of the same age, and both Shennan's case and ours would certainly bear such an interpretation.

Grabowski, as already pointed out, believed that the tumours in his patient started in the endothelium of the reticulo-endothelial system, and both Pentman (1916) and von Falkowski (1914) describe instances of tumours arising in the endothelium of the blood vessels in a diffuse manner. Schlopsnies has, however, expressed the view that it is probably 'precarious to classify the angiosarcoma in Epstein's histiocytomatoses' because angiosarcoma is a growth solely of the endothelium, and as will be seen in the following section, the endothelium of blood vessels cannot in the strictest sense be classified in the reticulo-endothelial system. In Schlopsnies' patient, already mentioned, the tumours were confined to the haematopoietic system. Paine (1931) has described a case of haemendothelioma of the spleen in which tumours were also present in the bone marrow and metastases in the liver; histologically this was a reticulum cell neoplasm, and was thought to be due to proliferation of neoplastic endothelial tissue in the haematopoietic system with certain resemblances to Hodgkin's disease. Gray (1929) maintains that although haemangiomas showing metastases are not necessarily confined to sites where reticulo-endothelial tissue is prominent, some are easily explained as an infection of the reticulo-endothelial system; he also cites a case recorded by Foot (1927) in which endothelial proliferation was present in the liver and other sites in the reticulo-endothelial system. Finally, Pentmann (1916) and Borissowa (1903) have

described tumours with multiple foci in the haematopoietic system which are not haemangiomas.

The reticulo-endothelioses

As a result of studies of patients presenting neoplasms involving several organs or parts of the body a controversy has arisen as to whether such conditions are due to generalized metastatic growths or to a generalized metaplasia and are examples of a system disease; also, if the latter, whether any of them can be regarded as diseases of the reticulo-endothelial system. There is no doubt that both Shennan's case and the present one—probably also Grabowski's—simulate closely many of the disease processes which have been classified as 'reticulo-endothelioses.' In this connexion two questions at once arise. First, can Aschoff's conception of a reticulo-endothelial system be accepted? Secondly, if the answer to the first question is in the affirmative, can a tumour arising from the endothelium of blood vessels be regarded as arising in part of that system? The term 'reticulo-endothelial system' is in constant use in medical literature and certainly trips quite glibly off the tongue, but its definition is a much more difficult matter. Nevertheless, before the possible diseases of such a system can be discussed it is essential to have an idea of its constituent parts, although this is not rendered easier by the adoption of different names for the same cell, and by the fact that the very existence of the system is denied by some authorities.

ASCHOFF'S THEORY OF A RETICULO-ENDOTHELIAL SYSTEM. Certain cells of the connective tissue series have, in the living state, the property of becoming stained by weak solutions of certain colloidal dyes such as lithium carmine, pyrrole blue and trypan blue. This property is really one of phagocytosis and the degree of phagocytosis of a given cell is indicated by the intensity of the staining. Judging by this standard Aschoff (1924) classified these mesenchymal cells into six groups, of which those in the first four are in the ascending order of intensity of staining and the cells of the last two groups are derived from those of the third and fourth:

1. The endothelial cells of the blood and the lymph vessels which take the dye only when staining is carried to an advanced degree and then only in the form of fine granules.
2. Fibrocytic or ordinary fixed connective tissue cells. These take the dye after sufficiently prolonged staining and show fine granules.
3. The reticulum cells of the spleen and lymph glands.
4. The endothelial cells (called by Aschoff reticulo-endothelial cells) of the sinuses of the lymph glands, the blood sinuses of the spleen, Kupffer cells, the capillaries of the bone marrow, adrenal cortex and pituitary. The cells of this group, which were called littoral cells by Maximow to distinguish them from vascular endothelium, take the dye more intensely than any of the others.
5. The histiocytes (tissue histiocytes) or wandering cells of the connective tissue which are also found in the loose tissues of serous membranes, omentum and pleura. Other names suggested for these cells are macrophages (Metchnikoff), clasmatocytes (Ranvier), adventitial cells (Marchand), resting wandering cells and polyblasts (Maximow).
6. The pulp cells of the spleen (splenocytes), and the vitally staining monocytes of the blood (blood histiocytes). The latter arise from

the tissue histiocytes (group 5), splenocytes, and from the cells of groups 3 and 4 'which have been shed into the circulation or wandered into it.'

Aschoff combined groups 3 and 4 together and called them the reticulo-endothelial system because of their 'common function of producing reticulum and lining sinusoidal blood and lymph spaces . . . and because of the facility which these cells have of functioning simultaneously as lining endothelial cells and producers of reticulum.' In so far as the cells of groups 5 and 6 are derived from those of groups 3 and 4, they also form part of the reticulo-endothelial system; indeed Aschoff speaks of the cell groups 3 and 4 as forming the reticulo-endothelial system in the 'narrower sense,' and those of groups 3, 4, 5 and 6 as forming that system in the 'wider sense.' The cells of groups 3 and 4 have also been called stationary or fixed histiocytes and those of 5 and 6 wandering histiocytes. The term histiocyte simply means a tissue cell, but because of their active powers these (fixed and free) cells were called macrophages by Metchnikoff to distinguish them from the polymorphonuclear cells or microphages which do not stain intravitaly. It has been suggested that certain other cells should be included in the reticulo-endothelial system of which, for the purpose of this paper, the most important are the reticulum cells of the thymus and glial cells of the brain. Aschoff does not accept this view and says 'they should not be included in the reticulo-endothelial system, the glial cells above all, because they do not participate at all in vital staining under ordinary conditions.' Nevertheless, del Rio-Hortega (1939) maintains that the microglia is derived from the mesoderm which grows into the brain with the blood vessels, and these cells, known also as 'mesoglia' or 'Hortega glial cells,' are now generally accepted as cells of the reticulo-endothelial system.

In addition to phagocytosis the cells of the reticulo-endothelial system have also other important functions in the metabolism of the body, as, for instance, the breakdown of the red blood cells, the formation of bile, the metabolism of fat and the production of antibodies.

The term 'reticulo-endotheliosis' is used by some writers to include proliferative changes in any of the components of the system, but by others it is restricted to conditions in which the change is supposed to arise in, and be more or less confined to, the cells of the fourth group, whereas the terms 'reticulosis' and 'histiocytosis' are applied to proliferation arising in and confined to the third and fifth groups respectively. Aschoff maintains that in all probability true neoplasms of the reticulo-endothelial system also occur, but that it is impossible to differentiate them from tumours of the ordinary vascular and lymphatic endothelium.

The question as to whether Aschoff is right in connecting up all the fixed and free cells which possess the power of phagocytosis and other important metabolic functions into a 'system' is one which has been the subject of considerable argument. For instance, Robb Smith (1937) criticizes the idea of a 'system,' but thinks it is possible to speak of reticulo-endothelial 'tissue.' Josephs (1937) also appears to prefer to speak of 'tissue' rather than a 'system,' for he defines 'reticulo-endotheliosis' as a group of diseases which at autopsy show widespread proliferation 'of a type of cell which is interpreted as arising from reticulo-endothelial tissue.' Jaffé (1938 a), in a masterly review of this subject, holds that the term reticulo-endothelial system has justified its existence, although he does not regard it as ideal since 'endothelial' obscures the distinction from vascular endothelium and 'reticular system' does not take into consideration the free and fixed wandering cells or the loose connective tissue and the histioid cells of the blood; nevertheless, 'a type of cell which is under continuous physiological stimulus deserves to be separated from the other mesenchymatous cells which lead a relatively quiet life.' In another article (1938 b) he says, 'the

differences between the reticulo-endothelial cells and the other cells are rather quantitative than qualitative,' yet in spite of this 'the reticulo-endothelial cells deserve to be regarded as a well defined cell system different from the other mesenchymatous cells, since, already under physiologic conditions, they are constantly in a stage of great functional activity, indicating that they play a very important rôle in the normal metabolism' . . . and although 'the other mesenchymatous cells may eventually acquire similar properties, their response is sluggish as compared to that of the reticulo-endothelial cells, and hence of inferior biologic quality.' Dealing with the pathological changes in the reticulo-endothelial system, he states that, apart from malignant tumours which arise occasionally in the reticulo-endothelial cells of the blood-forming organs, such changes are, as a rule, reactive in nature and usually due either to infections or disturbances of metabolism; moreover, sometimes this reaction may be so marked as to give the impression of a primary disease. He points out that this impression of a primary disease is produced by a group of diseases, occurring particularly in children, which show a diffuse systematic hyperplasia of the reticulo-endothelial cells or of the reticulum cells only, and which in modern literature are called reticulo-endotheliosis or reticulosis respectively. Some French and Italian writers speak of the reticulo-histiocytic system in preference to the reticulo-endothelial system.

MAXIMOW'S THEORY OF THE PLURI-POTENTIALITY OF THE UNDIFFERENTIATED MESENCHYMAL CELL. Opposed to this conception, put forward by Aschoff, of a collection of cells related primarily by their physiological function, irrespective of their embryonic origin or histiogenic potentialities—in other words a physiological and not an anatomical system—there is the view enunciated by Maximow (1934) that these cells are unrelated functionally but related genetically to a common ancestral cell (the undifferentiated mesenchymal cell) which maintains its embryonic multipotency in postnatal life. According to Maximow the undifferentiated primitive mesenchymal cells, present in large numbers in the embryo, give rise in embryonic life to the connective tissue cells, the lymphocytes of lymphadenoid tissue, the blood-forming cells of the marrow, the blood cells and indeed all those cells which Aschoff includes in the reticulo-endothelial system. These undifferentiated mesenchymal cells have also been found by Maximow in the adult in the spleen, lymph nodes, liver, marrow and subcutaneous tissue, and form a syncytium in which it is difficult to define any cell boundary. In the unstimulated organ they are inconspicuous, and lie on the basement membrane of the lymph or blood sinuses; they do not store dyes nor produce reticular fibres and are non-mobile. On stimulation, however, they swell, develop a definite cell outline, their cytoplasm becomes denser, the nucleus smaller and richer in chromatin. They are then known as reticulum cells and form the sponge-like reticulum of the spleen, lymph nodes and bone marrow, in the interstices of which lie the blood or lymph sinusoids. Reticulum cells are of two varieties, the littoral or sinus lining cell and the reticulum cell proper, to both of which reference has already been made (Hadfield and Garrod, 1938). Furthermore, according to Maximow, this undifferentiated mesenchymal cell syncytium can, under suitable circumstances, resume its embryonic character and give rise to the extraordinary variety of differentiated cells mentioned above.

RETICULO-ENDOTHELIOSIS OR RETICULOSIS? Accepting Maximow's thesis, Pullinger (1932) states that there exists a group of diseases of the reticulum 'in which proliferation is possible into one or several of the possible cell progeny' and suggests that 'reticulosis' (a term introduced by Letterer in 1924) is a more suitable name for these conditions than 'reticulo-endotheliosis,' and possesses the advantage that it allows the sub-division of the group in accordance with the predominant cell type. On the other hand, Abt and Denenholz (1936), who also accept Maximow's view, feel, as reported earlier in

the paper, that there is nothing to be obtained by calling a heterogeneous collection of cases 'reticulo-endotheliosis.' Hadfield and Garrod (1938) take up the standpoint that the views both of Aschoff and Maximow are correct; an attitude which they say receives strong support from a study of the reticulososes, under which title they class all those conditions 'in which there is generalized enlargement of the spleen, lymph nodes and liver due to hyperplasia of differentiated or undifferentiated mesenchymal cells.' Although Robb-Smith (1937, 1938) bases his classification on Maximow's doctrine, he also apparently accepts both views and his definition of reticulosis is a variant of those just quoted, being a 'progressive hyperplasia of reticular tissue with differentiations into one or more cell types,' and which is commonly systematized in that it affects throughout the body homologous tissue to that affected in the lymph nodes. He also points out that owing to proliferation arising at so many points 'infiltration' may appear to be present, but stromal destruction does not occur and embolic dissemination is rare; moreover, free cellular elements may be present in the circulating blood (leukaemia). This definition accurately describes the present case with the sole exception that there were no abnormal cells in the blood.

Robb-Smith's classification of the reticulososes is an elaborate one, and its main sub-divisions are drawn from the three histological factors in the lymph glands: follicles, sinuses, and the reticular tissue of the rest of the gland (medulla). In follicular reticulosis there is hyperplasia of undifferentiated cells in the lymph follicles and malpighian bodies in the spleen and possibly the development of follicles in the periportal hepatic tissue and bone marrow. In sinus reticulosis (endotheliosis) there is hyperplasia of undifferentiated mesenchymal cells and littoral cells in the lymph sinuses, sinusoids of the liver and venous sinuses of the spleen and bone marrow, and in some cases a proliferation of tissue histiocytes. In medullary reticulosis there is hyperplasia of undifferentiated mesenchymal cells in the medullary tissue of the lymph nodes and the spleen, in the periportal tissue of the liver, the bone marrow, and possibly in the interstitial tissue throughout the body; the undifferentiated mesenchymal cells of the follicles and sinuses may also become involved. These three main subdivisions are further divided according to the predominant cell. The present discussion is, however, concerned only with the medullary reticulososes, which are divided into the following varieties: lymphoid (lymphoid leucosis), myeloid (myeloid leucosis and myeloid transformation), monocytic (monocytic leucosis), reticulum celled, storage reticulum-celled (lipoidosis, Gaucher's disease, Niemann-Pick's disease, xanthomatosis), histiocytic, pre-histiocytic fibrillary and fibro-myeloid (Hodgkin's disease).

In 1933 Siwe wrote an article having the title 'Die Reticulo-endotheliose—ein neues Krankheitsbild unter den Hepatosplenomegalien' in which he reported one case and collected three others from the literature. In the paper by Abt and Denenholz, already referred to, these cases are further discussed, a new case described and four others collected from the literature. Included amongst the latter is a child who was a patient in the Birmingham Children's Hospital. This child was investigated there on several occasions and the details of his illness were recorded by the late R. J. Gittins (1933) in a paper on 'Anaemia and reticulo-endotheliosis.' In view of the fact that Letterer described the first case of this type, Abt and Denenholz suggest that the condition should be called 'Letterer-Siwe's disease.' The symptomatology of this disease differs from that of the patient who is the subject of this paper in that all the children were under three years of age and that a haemorrhagic tendency chiefly manifested as petechiae or purpura was consistently noted, although it is perhaps noteworthy that as a terminal event small bluish tumours occurred in the skin of the present patient. Pathologically there was in every instance 'a widespread hyperplasia of non-lipoid storing macrophages in the liver, spleen, lymph

glands, bone marrow and lungs.' This condition has also been described under other titles, e.g., aleukaemic reticulosis (Letterer), acute reticulosis of infants (Oberling and Guérin, 1934), systemic endothelial hyperplasia of haemopoietic organs, and in Robb-Smith's classification it falls into the group of reticulum celled medullary reticulosis. The disease occurs in children between the ages of two and twenty-one months, runs an acute pyrexial course with generalized enlargement of the lymph nodes and splenomegaly, and terminates fatally in about six weeks. In the majority of cases there is a hypochromic anaemia and also a slight polymorphonuclear leucocytosis, although in others there is a lymphocytosis and neutropenia; frequently there is infection in the ears, nose and throat, and several cases have shown skeletal defects. Most writers regard this disorder as a systematized response to an infection. Indeed, Jaffé says 'reticulo-endotheliosis and reticulosis are septicaemias with an abnormal excessive response of the cells under discussion' (1938 *b*). Although he also states in another contribution that the hyperplasia may be the 'morphological expression of an allergic tissue response to a septic infection' (1938 *a*). Sacks (1938) thinks the term 'reticulo-endotheliosis' should be limited to this class of case, which he describes as 'a systemic proliferation of the system of histiocytes unassociated with any demonstrable metabolic disturbance, and apparently occupying an intermediate position between inflammatory hyperplasia and malignant neoplasia.' Sacks divides systemic proliferation of the reticulo-endothelial system into three groups: (*a*) monocytic leukaemia, with or without local invasive neoplastic growth (Gittins and Hawksley, 1933); (*b*) retothelial (reticulum cell) sarcoma; (*c*) reticulo-endotheliosis.

The patient described by Gittins to whom Abt and Denenholz refer was one of a series of four children showing varying degrees of chronicity (acute to sub-chronic) of what we regarded and still do regard as erythronoclastic (haemolytic) anaemia. All these children at autopsy revealed marked histiocytic and reticulum cell reaction which we considered to be a reactive reticulosis or reactive reticulo-endotheliosis (Gittins, Josephs). Two of this series are regarded as examples of acute reticulosis by Robb-Smith, but he does not admit into that category the child claimed by Abt and Denenholz as suffering from Letterer-Siwe's disease. This child's illness showed the most chronic course of the series and at the autopsy there was found widespread reticular reaction with fibril formation replacing areas of haemopoietic tissue and thereby producing an aplastic anaemia. The diagnosis of a storage reticulosis such as Gaucher's disease was actually considered in this particular child because of the chronicity of the illness and the presence of anaemia and marked splenomegaly, but was ruled out of court by the degree of anaemia. As a matter of fact, neither this child nor the present case were ever considered to be in any sense suffering from the same or even allied diseases, although marked splenomegaly was present in both, because the outstanding condition in Gittins's case was the severe aplastic anaemia, the child only being kept alive by repeated transfusions; whereas in the present patient the outstanding feature was the enormous splenomegaly, the anaemia being but slight in degree.

It seems clear, then, that similar clinical symptoms may be produced by :

1. Generalized angiomatosis.
2. Retothelial sarcomatosis (reticulum cell sarcomatosis).
3. Storage reticulosis (storage reticulum cell medullary reticulosis).

4. Infection.
5. Reticulum celled medullary reticulosis ('hyperplasia of non-lipoid storing macrophages,' 'Letterer-Siwe's disease,' acute reticulosis of infants, aleukaemic reticulosis, reticulo-endotheliosis).
6. Hodgkin's disease.
7. Certain blood diseases, e.g., leukaemia and a form of erythronoclastic (haemolytic) anaemia.

As a matter of fact, in the present case after the suggestion of Hodgkin's disease was abandoned no other alternative diagnosis but that of a storage reticulosis was seriously considered.

Classification of angiomata

Whilst in the foregoing discussion the clinical and pathological evidence which supports the inclusion of the present case in the reticuloses (reticulo-endothelioses) has been given, yet both it and Shennan's and Grabowski's cases also find a place in the various suggested pathological classifications of the angiomata. For instance, Ewing (1928) distinguishes between 'multiple benign cavernous angiomas' and 'metastasizing cavernous angiomas which exhibit certain peculiar features of malignancy,' and Dowd (1915) in reviewing thirteen cases of cavernous angiomata of the spleen divided them into multiple benign tumours in various organs and malignant angiomas with metastases. Ogilvie and Mackenzie (1936) describe two cases which they call malignant haemangio-endothelioma and suggest the groups 'malignant haemangio-endothelioma (with or without metastases; histologically malignant)' Schlopsnies (1929) on the other hand divides cavernous angiomata into 'system tumours' and 'malignant metastasizing tumours.'

Multiple cavernous angiomata therefore appear to fall into three groups:

- (a) Those occurring in the skin.
- (b) Those occurring subcutaneously as benign growths in the various parts of the body where reticulo-endothelial tissue exists—system tumours.
- (c) Those occurring in various parts of the body as a malignant metastasizing tumour.

The duration of multiple haemangiomata varies from a few weeks up to several years. The malignant metastasizing group appears to have the shortest course, while the 'system tumours' usually survive much longer. Shennan's case was under observation for four years and our patient was first seen twenty months before her death.

Summary

A clinical and pathological report is given of a fourteen-year-old girl who showed clinical evidence of the 'osseous form of Gaucher's disease' but who at post-mortem examination was found to have suffered from cavernous angiomata varying in size in the liver, spleen, retroperitoneal glands, thymus, mediastinum,

lungs, pleura, kidneys and most of the bones of the body. The case is a difficult one to classify because of the widespread involvement of reticulo-endothelial tissue, although histologically it is apparently an example of multiple haemangiomas, the cells of which have benign histological characters. A discussion of the relation of this condition to 'reticulosis' and 'reticulo-endotheliosis' is included.

Thanks are due to Dr. C. G. Teall and the staff of the X-ray Department for many radiographic examinations, to Prof. Haswell Wilson for his help with the histological sections, to Dr. E. M. Hickmans for the biochemical estimations, to Mr. E. B. Brain for photographs, and to the Medical Research Council for defraying the expenses of the investigations.

REFERENCES

- Abt, A. F., and Bloom, W. (1928). *J. Amer. med. Ass.*, **90**, 2.
 ——— and Denenholz, E. J. (1936). *Amer. J. Dis. Child.*, **51**, 499.
 Aschoff, L. (1924). *Lectures on Pathology*, New York.
 Borissowa, A. (1903). *Virchows Arch.*, **172**, 108.
 Borrmann, R. (1907). *Beitr. path. Anat.*, **40**, 372.
 Brill, N. E., and Mandelbaum, F. S. (1913). *Amer. J. med. Sci.*, **146**, 863.
 Bruchanow, N. (1899). *Z. Kinderheilk.*, **20**, 131.
 Castle, W. B., and Minot, G. R. (1936). *Pathology, Physiology and Clinical Description of the Anæmias*, New York.
 van Creveld, S., and Ter Poorten, F. H. (1935). *Arch. Dis. Childh.*, **10**, 125.
 Dowd, C. M. (1915). *Ann. Surg.*, **66**, 177.
 Erickson, B. N., Williams, H. H., Hummell, F. C., and Macy, I. G. (1937). *J. biol. Chem.*, **118**, 15.
 Ernst, P. (1912). Quoted by Schlopsnies.
 Ewing, J. (1928). *Neoplastic diseases*, third edition, Philadelphia.
 Foot, N. C. (1927). *Amer. J. Path.*, **3**, 653.
 Foote, J. (1919). *J. Amer. med. Ass.*, **73**, 1042.
 Gittins, R. J. (1933). *Arch. Dis. Childh.*, **8**, 375.
 ———, and Hawksley, J. C. (1933). *Loc. cit.*, 241.
 Grabowski, W. (1927). *Abstract in Zbl. allg. Path. path. Anat.* (1928–1929), **44**, 65.
 Gray, J. (1929). *J. Path. Bact.*, **32**, 337.
 Hadfield, G., and Garrod, L. P. (1938). *Recent advances in Pathology*, third edition, London.
 Hall, E. M. (1935). *Amer. J. Path.*, **11**, 343.
 Jaffé, R. H. (1938a). *Handbook of Haematology*, ed. by H. Downey, Minneapolis.
 ——— (1938b). *Practice of Pediatrics*. Edited by J. Brenneman, Hagerstown, Md. 1938.
 Josephs, H. W. (1937). *J. Pediat.*, **11**, 607.
 Letterer, E. (1924). *Frankfurt Z. Path.*, **30**, 377.
 Maximow, A., and Bloom, W. (1934). *A Textbook of Histology*, second edition, Philadelphia.
 Oberling, C., and Guérin, M. (1934). *Sang*, **8**, 892.
 Ogilvie, R. F., and Mackenzie, J. (1936). *J. Path. Bact.*, **43**, 143.
 Orzechowski, G. (1928). *Virchows Arch.*, **267**, 63.
 Pachman, D. J. (1938). *Amer. J. Dis. Child.*, **56**, 248.
 Paine, C. G. (1931). *J. Path. Bact.*, **34**, 139.
 Parker, R. W. (1880). *Trans. path. Soc. Lond.*, **31**, 290.
 Pentmann, I. (1916). *Frankfurt Z. Path.*, **18**, 122.
 Pick, L. (1933). *Amer. J. med. Sci.*, **185**, 453 and 601.
 Pullinger, B. D. (1932). *Rose research on lymphadenoma*, Bristol.
 del Rio-Hortega, P. (1939). *Lancet*, **1**, 1023.
 Robb-Smith, A. H. T. (1937). *M. D. Thesis, London University*.

- Robb-Smith, A. H. T. (1938). *J. Path. Bact.*, **47**, 457.
- Robinson, J. M., and Castleman, B. (1936). *Ann. Surg.*, **104**, 453.
- Romdohr, M. (1878). *Virchows Arch.*, **73**, 459.
- Ross, J. M. (1932). *J. Path. Bact.*, **35**, 899.
- Sacks, M. S. (1938). *Arch. Pathol.*, **26**, 676.
- Schlopsnies, W. (1929). *Virchows Arch.*, **85**, 274.
- Schonberg, S. (1923). *Frankfurt Z. Path.*, **29**, 77.
- Shennan, T. (1914). *J. Path. Bact.*, **19**, 139.
- Siwe, A. (1933). *Z. Kinderheilk.*, **55**, 212.
- Spiegel, H. A. (1929). *Arch. Pediat.*, **46**, 188.
- Stamm, C. (1891). Quoted by Wollstein.
- Virchow. Quoted by Ewing.
- von Falkowski, A. (1914). *Beitr. path. Anat.*, **57**, 385.
- Wollstein, M. (1931). *Arch. Pathol.*, **12**, 562.