

TETANUS NEONATORUM

BY

D. B. JELLIFFE, M.D.(Lond.), M.R.C.P., D.C.H., D.T.M. & H.
From University College, Ibadan, Nigeria

(RECEIVED FOR PUBLICATION, SEPTEMBER 19, 1949)

Tetanus neonatorum has become a rare disease in civilized communities. That this is dependent on a general acceptance of basic elementary hygiene is emphasized by the record of the following 25 cases, all of whom were seen in the paediatric wards of University College, Ibadan, in the first six months of last year.

Ecological Background

Ibadan is a huge, sprawling town in western Nigeria. There is a fluid indigenous population of some 500,000 people. Most are of the Yoruba tribe, with a minority of Hausa and Ibo. Housing is primitive and overcrowding the rule. The vast majority have little or no education, and certainly no conception of even the simplest hygiene. During the dry season the town is covered with ironstone dust, and goats, which are commonly kept, wander all over the town, both inside and outside the houses.

Treatment of the Umbilicus

All cases in this series were Yorubas, with the exception of one patient, E.B., who was of the Benin tribe.

In this series the cord was cut at birth, a sharp splinter of palm wood or a piece of broken bottle being used. The cord is usually tied with a piece of thread or string. Various dressings seem to be used, most usually ghee butter, but occasionally palm oil, or a mixture of salt and the crushed-up central pith of the tagiri fruit, or gin and palm oil. A piece of rag heated by being placed on hot stones by the fire usually completes the dressing, which may be renewed at irregular intervals. As a result of this regime all grades of umbilical infection are common, umbilical abscesses and septicaemia being not infrequent. It is, therefore, not surprising that spores of *Cl. tetani* are often introduced into the wound from the goat-soiled dust.

Mode of Onset

The incubation period varied from five to ten days. It was six days in 64% (16 cases).

There was no history of an abnormal or difficult labour. All cases were confined in their own homes.

In every case the earliest feature noticed by the mother was the child's inability to suck the breast. This was followed after about 24 hours by definite and increasingly frequent extensor spasms. Constipation and continuous crying were part of the initial picture noticed by many of the mothers.

Clinical Picture

When once developed the clinical picture was characteristic. The children were usually well-nourished. The umbilicus was clinically infected in most cases (88%), a blackish eschar being not infrequent. The child's resting posture usually showed a moderate 'risus sardonius,' with the eyes held closed, slight hypertension of the spine, the arms semiflexed at the elbows, the hands clenched, the legs semi-flexed at the knees (Fig. 1). Tetanic spasms were superimposed upon this background. These were produced by a considerable increase in the hypertonus seen in the resting posture (i.e. marked risus, the arms held rigidly in semiflexion, hands tightly clenched, often with the thumb inside the hand, and the back hyperextended, but always to a less degree than in an adult case). There was at the same time spasm and rigidity of the muscles of the anterior abdominal wall, adductor spasm of the thighs, dorsi-flexion of the feet, and severe plantar flexion of the toes. This last was a very marked feature. Spasms occurred in most cases about every five minutes (varying from every second to every quarter of an hour), becoming more frequent as the illness developed.

Treatment

Treatment had to be based on the limited range of drugs available. Anti-tetanus serum (20,000 units i.m.) was given in all cases. Expressed breast milk was given by spoon or pipette. Subcutaneous saline was used in almost all cases. An attempt was made to nurse the children in a quiet corner of the ward, but the mothers were usually unable to understand the importance of this and carried

the babies about on their backs in the usual Yoruba fashion.

The most usual hypnotic was paraldehyde which was given intramuscularly in doses of 2-4 ml. four-hourly. Immediate results were quite good, the children having less frequent fits and being much quieter during the period of paraldehyde sedation. In two cases the intramuscular paraldehyde produced chemical abscesses of the buttocks. Alternatively chloral hydrate was used, either by mouth (gr. 3-5 four-hourly) or rectally.

Results

The results with this treatment were very bad. Seventeen cases died in the first 36 hours of treatment (68%), six lived for three to five days, one lived for 42 days, and one case recovered. The most usual course in an average case was for the spasms to become rapidly increasingly frequent. Fever (100-105° F.) and tachycardia were the rule. An analysis of the causes of death is tabulated below.

ANALYSIS OF CAUSES OF DEATH IN PRESENT SERIES

Cause of Death	No. of Cases	Percentage of Cases
No obvious cause	18	72
Hyperpyrexia	2	8
Cardiac failure:	2	8
1, acute ventricular		
1, generalized congestive		
Bronchopneumonia	1	
Anaemia and inanition ..	1	

Case Report

E.B., a female infant of the Benin tribe, aged nine days, was admitted to Jericho General Hospital, Ibadan, on April 4, 1949. There was a history of a normal uncomplicated delivery at home. The umbilicus had been cut and tied in the usual way. It had been dressed with hot rags and a gin and palm oil mixture. The mother had noticed that the child had been costive for two days and had not been able to suck the breast since the day before admission. On examination the infant showed risus sardonius, the neck slightly extended, the arms held stiffly in semiflexion with hands clenched, and the toes plantar flexed (Fig. 1). Spasms recurred every minute or so. The umbilicus was moderately infected, with slight herniation. Temperature was 101° F.

The infant was given anti-tetanus serum, 20,000 units i.m. and paraldehyde 2 ml. four-hourly, and expressed breast milk 3 oz. four-hourly.

8.4.49. Spasms almost kept under control by paraldehyde.

9.4.49. Blackish areas appearing on both buttocks. Paraldehyde discontinued. Started on oral chloral hydrate gr. 3 four-hourly.

11.4.49. Obvious sloughing, necrotic areas on both buttocks.

12.4.49. Spasms almost controlled by chloral. Abscess cavity has appeared in each buttock. Rather dehydrated, put on subcutaneous saline (5 oz. four-hourly).

20.4.49. Condition still much as before, but vomiting milk. Losing weight rapidly. Clean, but indolent, abscess cavities in both buttocks.

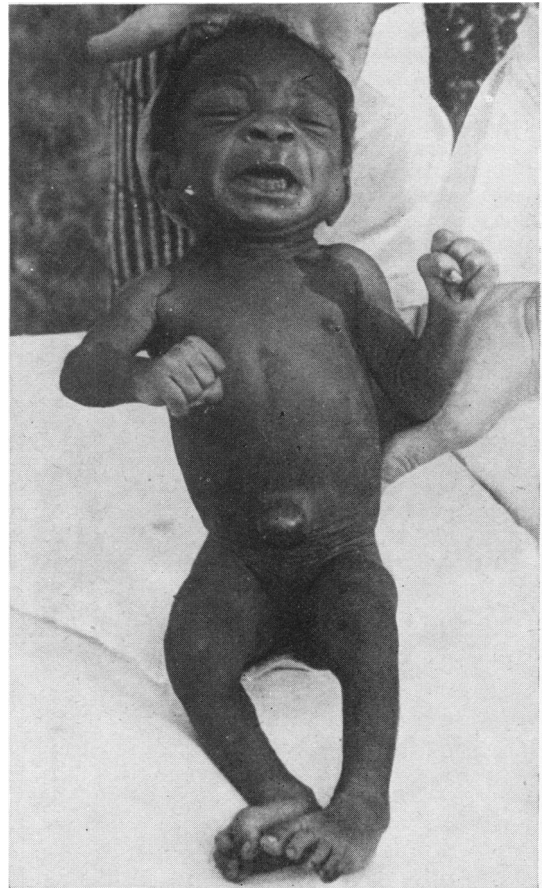


FIG. 1.—The infant described in the case report.

30.4.49. Occasional spasm only. Becoming anaemic (Hb 50%).

3.5.49. Considerable deterioration in condition. Bluish. Feeble. Dehydrated. Slight abdominal distension.

5.5.49. Vomiting occasionally.

12.5.49. No spasms. Taking milk quite well with a spoon. Occasional vomiting only. Cries well. Very dehydrated and emaciated. Buccal pad very prominent. No risus. Slight stiffness of the arms, held in slight flexion. Hands still firmly clenched. Umbilical hernia more prominent. Ulcers on buttocks clean but not

healing. Has had persistent fever of about 99-100° F. since admission.

13.5.49. Has developed oedema of scalp, with definite pitting on pressure. Urine shows no albumin.

15.5.49. Oedema has extended from scalp to face, head and neck. Unable to see eyes because of facial oedema. Rounded tumour 5 cm. in diameter has appeared above the inner end of the right clavicle. It is expansile on crying or during a spasm, can be reduced from above downwards into the thorax behind the right clavicle, and appears to contain air.

16.5.49. Oedema worse. Dyspnoeic. Tachycardia (150/min. irregular). Died in afternoon.

During the last two weeks of the illness, the child was treated with intramuscular liver injections, oral ferrous sulphate, cod liver oil, and ascorbic acid.

This patient seemed to be recovering from the tetanic spasms, but died of inanition and anaemia. The interesting feature of the case was the development of an air-filled tumour in the right side of the neck. This was almost certainly an aerocoele, arising from either the lung or a large bronchus. Presumably the constant strain of the tetanic spasms repeated over weeks, combined with anaemia, vitamin deficiency, and inanition, had produced

a stress hernia, which had caused pressure on the superior mediastinum, and resultant oedema of the head and neck.

Tetanus neonatorum is a comparatively common disease in Ibadan during the dry, dusty season. It should be completely avoidable if simple hygiene is practised. The majority of cases are fulminating so that it is unlikely that any treatment would be of use, although the possibility of using 'Flaxedil' (Tri-(diethaminoethoxy) benzene—triethiodide) intravenously via the anterior fontanelle must be considered.

Summary

The aetiology and clinical picture of tetanus neonatorum in Ibadan, Nigeria, is illustrated by a brief review of 25 cases. An unusual case of chronic tetanus neonatorum, complicated by anaemia, inanition, and an aerocoele, is described.

I should like to thank Professor A. Brown, of the Department of Medicine, University College, Ibadan, for permission to publish this paper.