

THE PATHOLOGY AND BIOCHEMISTRY OF GARGOYLISM

A REPORT OF THREE CASES WITH A REVIEW OF THE LITERATURE

BY

J. L. HENDERSON, AGNES R. MACGREGOR, S. J. THANNHAUSER
and R. HOLDEN

From the Department of Child Life and Health, University of Edinburgh, and the Joseph H. Pratt Diagnostic Hospital, Boston, Mass.

(RECEIVED FOR PUBLICATION AUGUST 17, 1951)

The detailed study by Lindsay, Reilly, Gotham and Skahen (1948) of the pathology in 12 cases of gargoylism was a welcome addition to the literature on the pathology of this curious disease. The study of the pathological features in such a relatively large series of cases enabled these workers greatly to amplify the pathological picture, which had previously been based on a small number of isolated reports. A few additional pathological reports have recently been published making a total of 12 detailed and 10 incomplete reports, with, in addition, several biopsy reports.

Lindsay and his colleagues gave a detailed description of the pathology in seven of their cases, incomplete data from another fatal case, and biopsy studies from four cases; the first of the seven detailed reports had been published by Reilly (1935), but some of the histological features now known to be characteristic were not recognized at that time. The antecedent literature contains 12 earlier post-mortem reports, only six of which are reasonably complete; also several biopsy studies. The six reasonably comprehensive reports published before the appearance of the notable contribution by Lindsay and his colleagues were written by Reilly (1935), Kressler and Aegerter (1938), who published the first detailed account of the pathology in a typical case of the disease, De Lange (1942), Kny (1942), De Lange, Gerlings, De Kleyn and Lettinga (1944) and Strauss (1948). A detailed report on the brain of the last of these cases was reported by Green (1948). The incomplete reports by Tuthill (1934) on one of Hurler's cases, and Ashby, Stewart and Watkin (1937) on two cases, were chiefly concerned with the nervous system. The other incomplete pathological reports were by Stoeckel (1941), Wolff (1942) and Njå (1945). Recently, reports on four more cases have been published: Lindsay (1950) gave a detailed account of the features in an infant aged 4½ months, Magee (1950) an incomplete report on one case and Jarvis (1950) incomplete reports on two cases.

Reports on the pathology of the cornea were contributed by Berliner (1939), Rochat (1942) and Zeeman (1942), each one case, and by Cordes and Hogan (1942), three cases. The full pathological reports of two of these cases were included in the series of Lindsay *et al.* (1948). Biopsy examinations were reported by Ellis (1937) on the liver and spleen; by Reilly (1935) and Debré, Marie and Thieffry (1946) on the liver; and by Höra (1939), and Schmidt (1942) on bone. A few other pathological reports may have been overlooked.

Strauss, Merliss and Reiser (1947) in a paper on gargoylism recorded a detailed pathological and biochemical examination in a man aged 29 years who was regarded by the authors as a case of this disease. There were so many atypical clinical and pathological features that the case cannot be accepted with certainty as one of gargoylism, though it may well have been a *forme fruste*. The patient appeared normal until after the age of 9 years, a most exceptional circumstance; he then developed progressive coarsening of the features, limitation of movement of the joints, deformity of the limbs and stunting. This case has been excluded from the following review of the pathology of gargoylism because of its doubtful classification.

We have had the opportunity of studying the pathological features of gargoylism in three young children who were observed at the Royal Hospital for Sick Children, Edinburgh, during recent years. One died in the hospital and complete post-mortem and histological examinations were made (A.R.M.); also a differential lipid analysis of the liver and spleen (S.J.T. and R.H.). The other two children had a biopsy examination made of certain organs. Some of the pathological features in the first of these three cases, notably the vascular infiltration and the heavy meningeal deposit, were of particular interest to us when we observed them in 1944, as neither had been described in the literature at that time.

CASE RECORDS

Case 1. A. McA., a boy, died on April 28, 1944, aged 6 years.

The father, aged 41 years, and the mother, aged 30 years, appeared healthy, also an elder brother aged 12 years and a younger brother aged 4 years. There had been no miscarriages. There was no history of physical or mental peculiarities on either side of the family, or of consanguinity.

Antenatal development was apparently normal. Delivery was by breech and the infant's condition was apparently satisfactory at birth. The mother thought that development was normal until the age of 9 months, when she noticed numerous abnormalities. 'His head seemed big in comparison with his body, and his body in comparison with his legs. His legs were thin. His tongue protruded.' An umbilical hernia was becoming perceptible at that time and a left inguinal hernia, present since birth, had become much larger. At 15 months he was admitted to the Royal Hospital for Sick Children, Glasgow, for operative treatment of the left inguinal hernia. The mother was told that he was mentally backward. He began to feed himself at 1½ years and to walk with assistance at 2 years.

At 3 years and 4 months he was recommended to the Ear, Nose and Throat Department, Royal Hospital for Sick Children, Edinburgh, for removal of his adenoids but was transferred to a medical ward for investigation of his general condition. At that time he was 34½ in. in height and 32 lb. in weight; dentition was still incomplete and he could walk alone, though very unsteadily. The umbilical hernia had become

larger. A diagnosis of gargoylism was made. At 6 years he was again admitted to the Royal Hospital for Sick Children, Edinburgh. He was still doubly incontinent; he had not begun to talk nor did he appear to understand speech. He could make himself understood by his mother and seemed to understand the significance of preparations such as for a meal or for going out. He was said to be happy and contented, not destructive, to look at books and to play with toys.

A dwarfed boy (Figs. 1 and 2), he was now 37½ in. in height, with a big head, an ugly face, a short neck, a deformed thorax, a protuberant abdomen with a large umbilical hernia, a lumbo-dorsal kyphosis, limbs incapable of complete extension and genu valgum.

The head was large (occipito-frontal circumference 23 in., anterior fontanelle closed). The frontal region was broad and prominent and there was slight bulging of the temporal bones above the ears. Fairly deep vascular channels could be felt, especially in the frontoparietal regions and in the vicinity of the occipital protuberance. A large varicose vein extended from the latter situation to the right ear. The ears were large, as big as an adult's. The ugly face showed rather shallow orbits with a very flat nose bridge and a button-like nose, with broad alae nasi and round nostrils constantly discharging mucopus. A red polyp the size of a pea projected slightly from and occluded the right nostril. The mouth looked a little large and the tongue was usually protruding. The lips were not unduly thick. The mandible looked broad and heavy for a boy of his age. The teeth were widely spaced in both mandible and maxilla and most of them were poorly calcified. The tongue was enlarged, usually protruded, and showed abnormal dorsal fissuring; it was not sucked.

The neck was very short so that the head appeared to be planted on the shoulders.

The trunk also showed numerous abnormalities. The antero-posterior diameter of the thorax was greatly increased and equal to the lateral diameter. The upper part of the sternal body was unduly prominent and the lower part was turned backwards. There were Harrison's sulci. The visible ribs looked broad. The abdomen was protuberant and rounded and rested on his thighs as the child sat in bed. There was a large umbilical hernia about 2½ in. in diameter. The hernial ring admitted two fingers. The penis and testes appeared normal but a varicocele was observed on the right side. There was a pronounced angular kyphosis in the dorso-lumbar spine. The scapulae were small and unusually highly and laterally placed; the inferior angle reached the sixth rib. The arms were abnormally short and the hands looked broad.

The limbs could not be fully extended. Abduction of the shoulders caused rotation of the scapulae towards the axillae; an angle exceeding 90° between humeri and scapulae could not be attained. Elbow extension was reduced by about 30° and supination of the forearm was moderately limited, also dorsiflexion of the wrists. Complete extension of the fingers was impossible and all were radially deviated and rotated a little towards the thumb; there was slight claw-hand. The hands

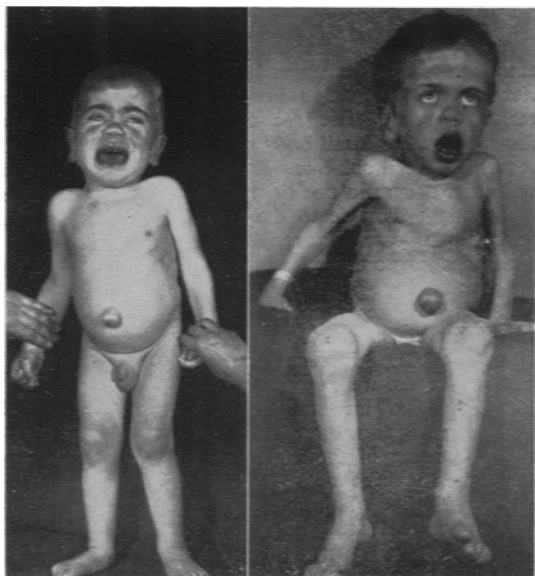


FIG. 1.

FIG. 2.

FIG. 1.—A. McA., aged 3½ years. A typical example of gargoylism. FIG. 2.—A. McA., aged 6 years. This picture taken five weeks before death shows increased malformation of the chest and greater flexion deformity of the elbows, also a severe degree of emaciation.

looked wide because of the short fingers. The finger nails also were short and wide looking. The legs showed a slight degree of limitation of extension at the knees and hips but other movements at the hips did not show any appreciable restriction. There was genu valgum, pronounced on the left and slight on the right. The toes were broad and rather stumpy like the fingers. On standing, the knees touched and were slightly flexed.

The skin was rather dry and its elasticity rather poor. The cheeks were ruddy. The dark brown hair was unusually coarse, also the eyebrows, the hairs of which projected unduly. The eyebrows met in the midline. The eye lashes were normal. The lips and conjunctivae had a normal colour. There was a purulent discharge from the left ear from which *Staph. aureus* and diphtheroids were obtained by film and culture; the left tympanic membrane was perforated. There was a bilateral diffuse corneal opacity which imparted a ground glass appearance to the eyes.

Nutrition was poor (weight, 38½ lb.). There was a subnormal amount of subcutaneous fat. The limbs were all thin, especially the legs. The calves were very thin.

MUSCULAR CONDITION. The general muscle volume was poor, particularly noticeable in the calves. The general tone was poor. He did not like to stand indefinitely and walked with difficulty when holding a finger. When he clapped his hands the movements were slow and clumsy.

MENTAL CONDITION. He was severely mentally defective. He shouted and periodically made loud noises which sometimes resembled singing. He attracted people's attention, for example to point out a light. He could drink from a cup and eat with his hands but could not feed himself with a spoon. He resented examination in a fairly normal manner and became annoyed when made to do certain things such as lying down. He laughed when tickled. He was doubly incontinent.

ALIMENTARY SYSTEM. The liver was considerably enlarged extending to four fingerbreadths below the costal margin in the mid-clavicular line. The spleen was slightly enlarged and could be palpated one fingerbreadth below the costal margin.

CARDIOVASCULAR SYSTEM. The heart was moderately enlarged. The apex beat was in the sixth intercostal space 1 in. lateral to the mid-clavicular line. There was a soft mitral systolic murmur and reduplication and accentuation of the pulmonary second sound. A radiograph of the heart showed considerable enlargement, particularly of the left ventricle.

RESPIRATORY SYSTEM. There was a considerable amount of thickish, muco-purulent discharge from both nostrils and a similar post-nasal discharge. The nasal polypus projecting from the right nostril has been noted. There was mouth breathing with snoring.

X-RAY EXAMINATION OF SKELETON. The skull bones were not thickened; the vascular channels were unduly prominent and the sella turcica was large. The ribs had narrow necks and wide bodies. The bodies of the

last two thoracic and second lumbar vertebrae were dysplastic. The eleventh thoracic vertebra showed considerable hypoplasia of the body. The twelfth thoracic vertebra also showed a small body with an

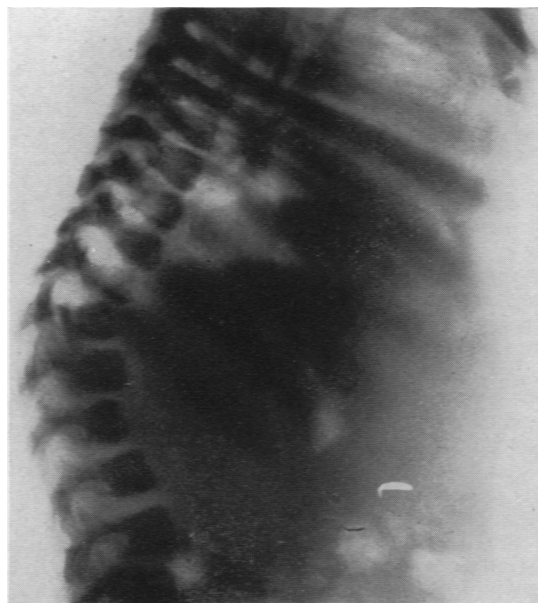

FIG. 3.—Lateral radiograph of dorso-lumbar spine in Case 1, showing typical hook-like malformation of the body of the twelfth dorsal vertebra, also to a lesser degree of the bodies of the eleventh dorsal and second lumbar vertebrae. The broad ribs are also typical.

anterior defect in its upper half, showing in the lateral view. This imparted a hook-like appearance to the vertebral body. The second lumbar vertebra also showed a rather small body and a less pronounced but characteristic hook-like deformity (Fig. 3). This deformity occurs in one or more of the vertebrae from the eleventh thoracic to the second lumbar in a high proportion of cases of gargoylism and is a pathognomonic feature of the disease.

The limb bones were characteristically thickened and roughly formed. The humeral and femoral heads were somewhat flattened. The humeral necks were narrow and there was a medial bending of the shafts of the humeri at the neck. The irregular outline of the bases of the metacarpals and the claw-hand were clearly seen (Fig. 4). The normal number of carpal

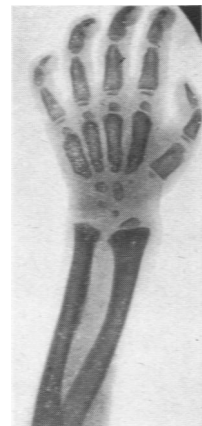

FIG. 4.—Radiograph of forearm and hand of Case 1, showing typical thickening and irregularity of the long bones.

bones was present, but several of them were unusually small and were probably late in appearing.

Arrangements were made to repair the umbilical hernia by operation. On April 28, 1944, phenobarbitone, grains 2, and atropine sulphate, grains 1/100, were given before an attempt was made to induce anaesthesia with nitrous oxide and oxygen. After a small amount of anaesthetic had been administered he became very cyanosed and breathing ceased. Respiration began again with the aid of artificial respiration; no further anaesthetic was given, and the operation was abandoned. The cyanosis disappeared and on becoming conscious the child became restless and cried. After about two hours he suddenly collapsed and became pale, cyanosed and pulseless. Artificial respiration, adrenalin 5 m μ and coramine 1 ml. intracardially, were of no avail and he soon died.

Post-mortem Report

The general appearance was as has already been described.

Head. The bones of the vault of the skull were of average thickness and density. The mandible was thick and heavy; thickening was especially noticeable at the symphysis menti, where the antero-posterior diameter of the bone was much increased. The increased thickness of the rami decreased the space between their inner surfaces, so that the size of the oral cavity was reduced.

Meninges. Adhesions were present between the dura mater and the pia-arachnoid over the vertex of the brain. Over this area there was a deposit of yellowish material, which adhered to the inner surface of the dura and to the arachnoid.

The leptomeninges showed a peculiar greyish opacity, which intensified to whiteness over the temporal poles. The subarachnoid space was slightly enlarged and contained a quantity of gelatinous material.

Brain. The brain was large (1,758 g.). Externally, there was no evidence of swelling or atrophy. The arteries at the base showed white flecks in their walls resembling atheromatous deposits.

On section, a moderate degree of atrophy of the white matter was found, with dilatation of the lateral and third ventricles. The perivascular spaces in the subcortical regions of the cerebral hemispheres were enlarged and contained gelatinous material similar to that in the subarachnoid space. This condition was most pronounced in the upper lateral occipital regions.

Serous Sacs. The pleural, pericardial and peritoneal sacs were healthy.

Respiratory System. No abnormality was found in the respiratory passages. The lungs were congested and slightly oedematous. No pneumonia was present.

Cardiovascular System. The heart was slightly enlarged, owing to hypertrophy of the left ventricle. None of the chambers was dilated. The colour and consistency of the myocardium were not abnormal.

The coronary arteries were straight, prominent and hard. To the touch they felt like nodular cords, and they were studded with numerous small, pale yellow flecks. Not only the main branches, but even the smallest visible twigs on the surface of the heart were affected in this way.

Both cusps of the mitral valve were thick and opaque. At the points of attachment of the chordae tendineae there were prominent fibrous nodules. The cusps and the chordae were not contracted or distorted, and the orifice was not stenosed. The cusps of the aortic valve also were thick and opaque, but this change was less pronounced than in the mitral valve. The tricuspid and pulmonary valves were not affected.

Alimentary System. The tongue was very large, being of average adult size, heavily furred and fissured.

No abnormality was noted in the pharynx or oesophagus.

The umbilical hernia contained neither bowel nor omentum. The alimentary tract presented no abnormality. The liver was much enlarged (1,150 g.), uniformly pale brown, and fairly firm. The pancreas showed no abnormality.

The Spleen. The spleen was slightly enlarged (83 g.). Its consistency was not altered. The cut surface was greyish red. The Malpighian bodies were visible but small.

Urogenital System. The left kidney and ureter were normal. The right kidney was much enlarged (8 in. long; 723 g.). This was due to severe hydronephrosis. The immensely dilated pelvis contained clear fluid. The renal substance was atrophied so much that only a thin membrane remained. The right ureter was sharply kinked immediately below the pelvi-ureteric junction, where it described a hair-pin bend, the limbs of which were bound together by connective tissue. Below this kink the ureter was of normal calibre. The bladder was healthy.

Both testicles were in the scrotum and appeared healthy.

Endocrine Glands. The pituitary gland was enlarged (0.85 g.), and lay in a somewhat enlarged pituitary fossa.

The right suprarenal gland weighed 3 g. It had been compressed between the liver and the enlarged right kidney and was flattened. The left suprarenal gland weighed 3.52 g. and appeared healthy. The thyroid, parathyroid and thymus glands showed no obvious abnormality.

The Bones. Portions of the limb bones that were examined were not visibly abnormal and contained marrow of normal appearance. The ribs showed slight 'beading' of the costochondral junctions on the inner aspect, and some a slight flat bulge extending about 1 cm. along the inner surface of the rib from the junction.

The bodies of the lower dorsal and upper lumbar vertebrae, at the site of the kyphosis, were reduced in size from above downward, but on section the bone did not appear to be abnormal.

Histological Report

Liver (Figs. 5 and 6). In paraffin sections all the parenchymal cells had a foamy appearance, owing to the presence of vacuoles in the cytoplasm, from which some material had been dissolved out in the process of preparation. The vacuoles varied in size, but were mostly small. They were less sharply defined than the vacuoles that are found in ordinary fatty degeneration. The nuclei had not been compressed and many retained their central position in the cells. The swelling of the liver cells had compressed the sinusoids, so that many had become almost indistinguishable. The Kupffer cells were inconspicuous, but some had foamy cytoplasm, as if they too contained the abnormal substance. The fibrous stroma and the blood vessels were normal.

Spleen. Endothelial (Fig. 7) cells attached to the walls of the sinusoids of the pulp were swollen and had vacuolated cytoplasm, so that the sinusoids appeared to be lined by a continuous layer of large, pale, foamy cells. A few similar cells lay free in the lumina of the sinusoids. The swelling of the littoral cells decreased the lumina, so that the pulp had a solid appearance. No foamy cells were seen between the sinusoids. In the Malpighian bodies, which were of average size, a few foamy cells were observed in the lymphoid reticulum. Some of the Malpighian arterioles showed hyaline degeneration of their walls.

Heart. In a few places small, round cells were found in the fibrous septa of the myocardium, which was otherwise unaltered. The pericardium was healthy. The mural endocardium was not altered. The anterior cusp of the mitral valve was increased in thickness throughout its length (Fig. 8). This was caused by a development of dense fibrous tissue, among which were swollen, vacuolated cells. The number of these foamy cells varied from place to place and was inversely proportional to the amount and density of the fibrous tissue. In the most fibrous parts they lay singly, separated by fibrous tissue, and many had a degenerated appearance; sometimes only remnants of dead cells were recognizable in spaces between the fibrous bundles. In one place at the base of a cusp, old hyaline fibrous tissue had been calcified.

Arteries. The coronary arteries on the surface of the heart showed striking changes (Figs. 9 and 10). The intima was immensely thickened in an almost uniform, concentric manner, so that the lumen was greatly reduced. The thickened intima was composed of fibrous tissue, in the interstices of which were numerous large foamy cells. The surface endothelium was intact. The internal elastic lamina could be traced round most of the circumference, but had suffered fragmentation at a few points. The media was stretched and thin and had been slightly invaded by foamy cells, especially in the inner part, immediately external to the elastic lamina, but here and there also in the outer part. The radial, brachial (Fig. 11) and anterior tibial arteries showed changes of the same nature as those in the coronary arteries, but differing in two respects: the intimal thickening was not concentric, but more on one

side than the other, and the abnormal tissue that was responsible for it was more densely fibrous and contained fewer foamy cells.

The axillary artery showed no pathological changes.

Dura Mater. The deposit on the inner surface of the dura mater was composed of sheets of foamy cells, with a small amount of supporting fibrous tissue and blood vessels (Figs. 12 and 13).

Brain. Sections were taken from the frontal, central and occipital cortex, basal ganglia, cornu ammonis, midbrain, cerebellum, medulla, spinal cord, choroid plexus, basilar artery and peripheral nerve. The peripheral nerve, choroid plexus and basilar artery were healthy. All the other parts showed similar changes. In all the nerve cells, especially the larger ones, in the cortex, basal ganglia, brain stem, cerebellum and spinal cord, there were intracytoplasmic granules of a substance that was isotropic and did not stain with Scharlach red. In some cells the Nissl substance was evenly distributed amongst the granules; in others it lay peripherally in a concentric or eccentric manner. The nerve cell population was not affected, except in the substantia nigra, where one cell was found degenerating and undergoing phagocytosis. Histiocytes containing deposit were present in the perivascular spaces. In the cerebral white matter, especially, this was associated with a wide, net-like, concentric distension of the adventitia of the blood vessels, as if abnormal material were lying in an extracellular position. In the subarachnoid space there were moderately numerous histiocytes, and distension of the subarachnoid meshes by extracellular material was a striking feature.

Lymph Nodes. Nodes from various situations showed many foamy cells in the lumina, and attached to the walls, of the sinuses throughout the glands. Some of the sinuses were crowded with these cells (Fig. 14).

Thymus Gland. This showed foamy cells in considerable numbers in the medullary portions, especially in relation to blood vessels, but these were scanty in the cortical parts.

Intestine (Ileum). A few foamy cells were found in the lymphoid tissue of a Peyer's patch.

Testis. In the interstitial tissue were numerous foamy cells. Their presence caused the tubules to be more widely separated than usual.

Pituitary Gland. Most of the cells in the pars anterior had a foamy character (Fig. 15). Normal pituitary cells were scanty and mostly of oxyphil type. The pars posterior was not affected.

Eye. Small deposits of foamy cells were found in the cornea and in the sclera, especially near the corneo-scleral junction. No other abnormality was noted.

Lung. The lung was oedematous. In the alveoli were many histiocytes containing dust particles. No foamy cells were present.

Kidney. The kidney showed no specific changes. Fatty degeneration affected the cells of the loops of Henle.




FIG. 5.

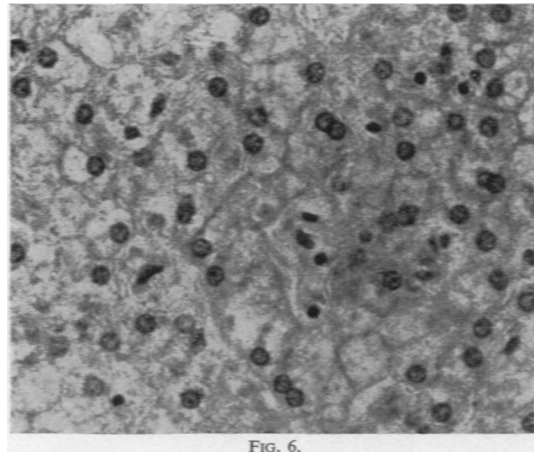


FIG. 6.

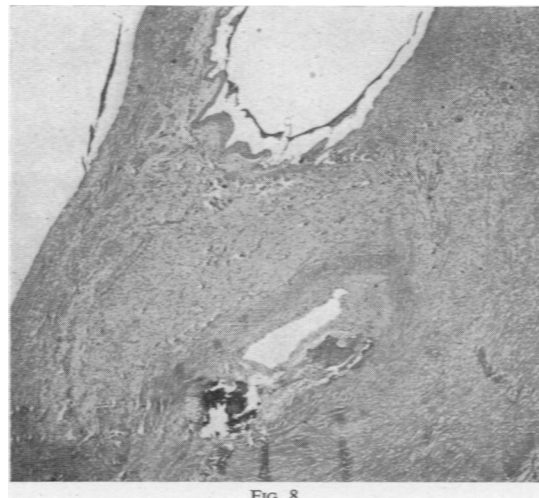


FIG. 8.

FIG. 5.—Liver section in Case 1. The epithelial cells are swollen and vacuolated and the sinusoids have been compressed and are inconspicuous. H. & E. $\times 100$.

FIG. 6.—Liver in Case 1. H. & E. $\times 400$.

FIG. 7.—Spleen in Case 1. The endothelial cells lining the sinusoids are swollen and vacuolated. Most of them remain attached to the walls. H. & E. $\times 400$.

FIG. 8.—Mitral valve cusp in Case 1. The area shown is at the base of the anterior cusp. There is great thickening, with dense fibrous tissue containing foamy cells. Calcification has occurred in a small area. H. & E. $\times 13$.

FIG. 9.—The coronary artery in Case 1. The intima is thickened all round the circumference with fibrous tissue containing many foamy cells. The lumen is greatly reduced. H. & E. $\times 45$

FIG. 10.—The coronary artery in Case 1. Part of intima shown in Fig. 9 to show detail of abnormal tissue. H. & E. $\times 400$.

FIG. 11.—Brachial artery in Case 1. The intima is greatly thickened on one side by fibrous tissue containing many foamy cells, and the lumen is much reduced. H. & E. $\times 13$.

FIG. 12.—Dura mater in Case 1. The deposit on the inner surface is composed of sheets of vacuolated histiocytes. H. & E. $\times 100$.

FIG. 13.—Dura mater in Case 1. High power view of part of field shown in Fig. 12 to show detail of the foamy cells. H. & E. $\times 400$.

FIG. 14.—Mesenteric lymph node in Case 1. The sinus endothelium has proliferated and fills dilated sinuses. All these cells have a foamy character. H. & E. $\times 400$.

FIG. 15.—Pituitary gland, pars anterior in Case 1. Most of the cells are distended and vacuolated. The few normal cells are mostly of eosinophil type. H. & E. $\times 400$.

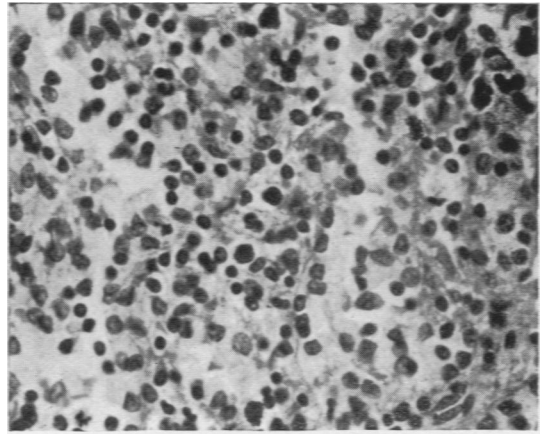


FIG. 7.

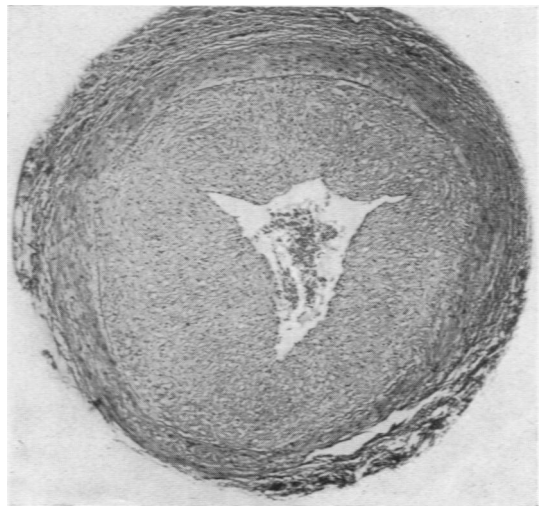


FIG. 9.

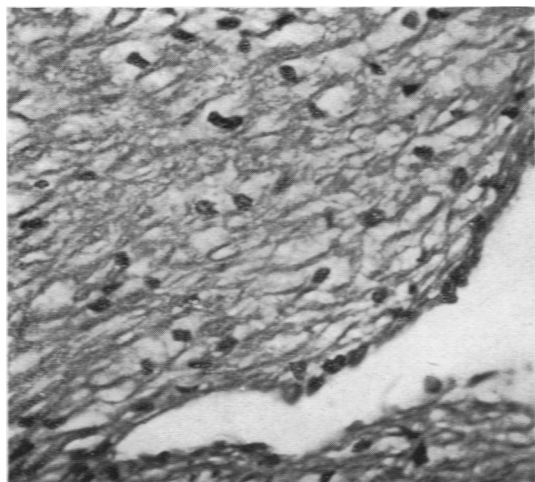


FIG. 10.

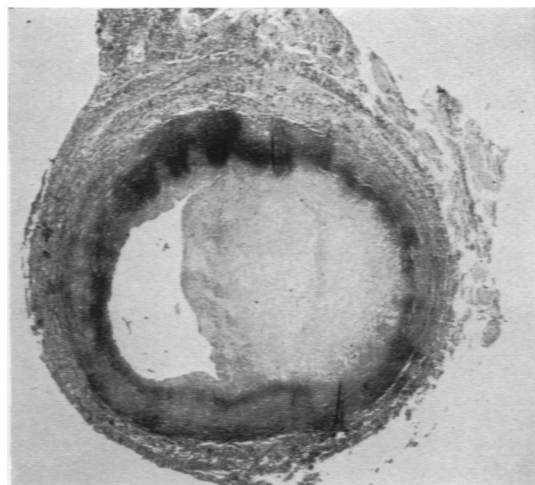


FIG. 11.

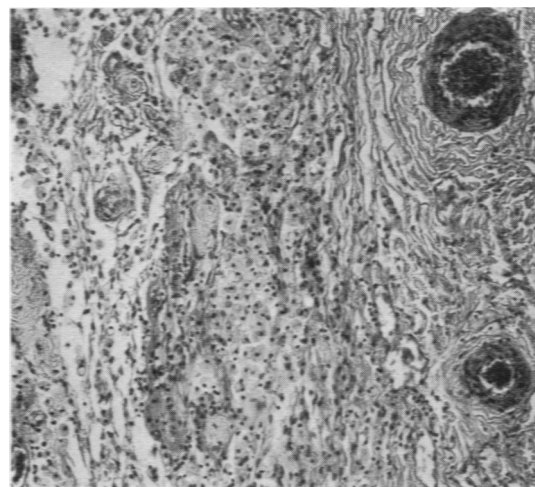


FIG. 12.

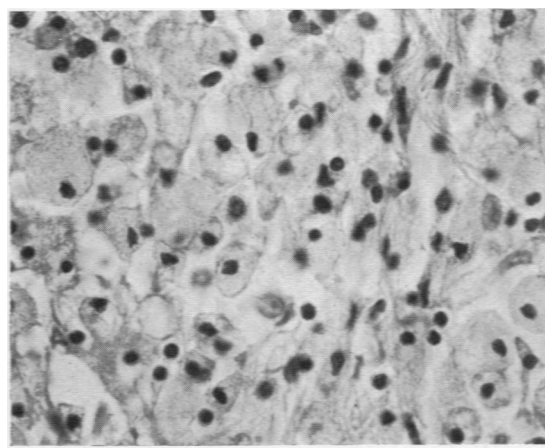


FIG. 13.

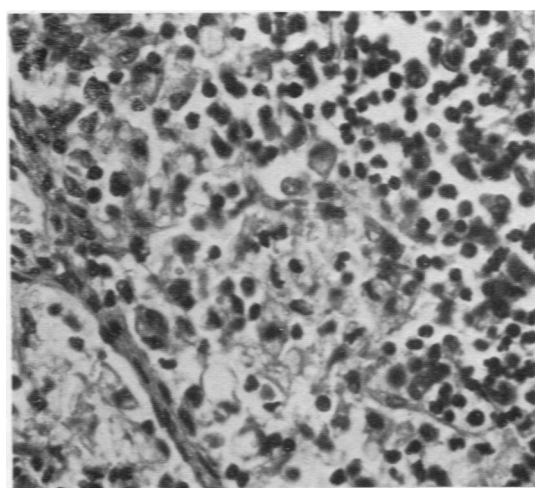


FIG. 14.

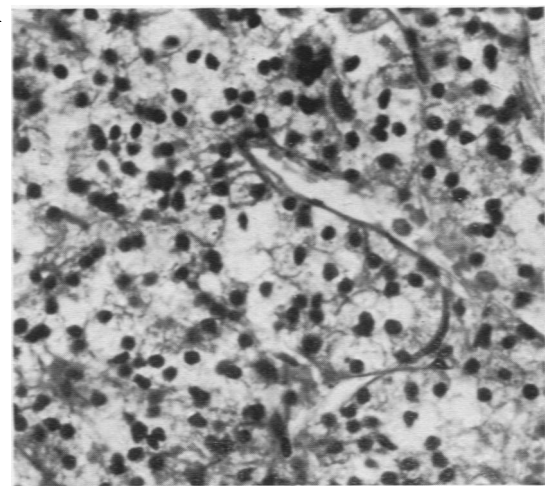


FIG. 15.

Pancreas, Suprarenal and Thyroid Glands. These showed nothing of pathological interest.

Skin. The skin was healthy.

Bones. Sections of a rib and a vertebra showed no abnormality in the bone or marrow. Ossification at the costochondral junction was quite normal.

Bone Marrow. The marrow was active, with normal leucoblastic and erythroblastic elements. Foamy cells were not found.

Attempts to stain the abnormal intracellular and extracellular deposit by Sudan III and Scharlach red, by the osmic acid method, by Nile blue sulphate and by Hoyer's thionin method were unsuccessful.

Specimens of liver and spleen preserved in 10% formalin were examined. The differential lipid analysis is recorded in Tables 1 and 2.

TABLE 1
DIFFERENTIAL LIPOID ANALYSIS OF LIVER IN CASE 1*

	Dry Tissue (mg. 100 mg.)			
	Normal (Age 8 Months)	Case 1 (Age 6 Years)	Normal (Age 6 Years)	Normal Adult
Total fatty acids	7.2-8.5	7.4	9.0	8.6-13.0
Phospholipids				
Total	5.4-6.3	4.6	7.8	9.0-11.0
Saponifiable	5.4-6.1	4.3	7.8	8.7-10.5
Sphingomyelin	0.0-0.2	0.3	0	0.3-0.5
Cholesterol				
Total	0.4-0.6	1.2	0.4	2.1-2.6
Free	0.3-0.4	1.1	0.4	0.4-0.6
Ester	0.1-0.2	0.1	0	1.7-2.0
Neutral fat†	3.4-3.9	4.10	3.3	1.2-4.0
Cerebrosides		0.46		0.1-0.5

* Estimations done by S. J. Thannhauser and R. Holden, Pratt Diagnostic Hospital, Boston, Mass.

† Formula of Thannhauser and Reinstein: neutral fat g.% = g.% total fatty acids minus (g.% cholesterol ester $\cdot 0.72$ - g.% total phospholipid $\cdot 0.69$) $\cdot 1.04$.

TABLE 2
DIFFERENTIAL LIPOID ANALYSIS OF SPLEEN IN CASE 1

	Dry Tissue (mg. 100 mg.)			
	Normal (Age 8 Months)	Case 1 (Age 6 Years)	Normal (Age 6 Years)	Normal Adult
Total fatty acids	1.2	6.3	5.0	4.0-6.2
Phospholipids				
Total	3.1	5.1	4.5	5.5-11.0
Saponifiable	3.1	4.0	4.1	4.8-10.0
Sphingomyelin	0	1.1	0.4	0.7-1.0
Cholesterol				
Total	0.23	1.8	0.6	0.6-2.3
Free	0.19	1.7	0.5	0.5-1.1
Ester	0.05	0.1	0.1	0.2-1.2
Neutral fat†	0.0	2.7	2.8	0.1-0.0

† Formula of Thannhauser and Reinstein.

Case 2. E.D., a girl, was examined on February 2, 1941, aged 3 years. She died in January, 1944, aged 5 years 8 months.

The father, aged 30 years, and the mother, aged 28 years, appeared healthy, also an elder brother aged 5½ years. There had been a miscarriage at 3 months between the birth of the two children. There was no history of consanguinity or of physical or mental peculiarities on either side of the family.

The antenatal history was apparently normal. The baby was born at the Simpson Maternity Hospital, Edinburgh (No. 9343), at full term. Delivery was spontaneous by vertex presentation. Labour lasted for 10 hours. The infant was slightly shocked at birth, and had two cyanotic attacks on the second day. No abnormality of structure was noted.

She was breast fed for three months ('did not feed as well as brother'). She seemed to thrive in infancy, but the mother noticed that the legs always seemed thin. She noticed kyphosis at 6 months, and a radiograph showed a defect in the dorso-lumbar spine. The first tooth appeared at 16 months. The child first smiled at about 6 months, began to walk round chairs at 2½ years, and to feed herself with a spoon at 2 years. She was still doubly incontinent. Speech was greatly delayed, with no sentence formation. The mother believed she knew the difference between friends and strangers, and between right and wrong. Nasal discharge, first noticed at 10 days old, had persisted ever since, sometimes being more profuse and yellow. The mouth had always been kept open and the tongue projected. The mother first noticed corneal clouding at about 9 months. At 6 months the child began to have (?) epileptiform seizures which usually lasted 'a few minutes'. There were many such 'turns' in any day for about six weeks, then they ceased. She had bronchitis aged 'a few weeks', measles at 2 years and left otitis media at 2½ years.

The patient was a typical gargoyle. She was a dwarfed girl (height, 33 in.). The head was large (occipito-frontal circumference, 20½ in., anterior fontanelle closed). There was a high frontal region, and the occipital ridge was prominent. There was definite bulging of the temporal bones above and behind the ears. The ears appeared low-set and as large as those of an adult. The nose showed a flattish bridge with wide nostrils. The mandible looked rather wide. The tongue lay just inside the lower lip but did not look abnormally large. The teeth were rather widely separated, short, and hypoplastic-looking.

The neck was very short. The trunk also showed numerous abnormalities. The antero-posterior diameter of the thorax was moderately increased. The body of the sternum was abnormally prominent. There was an angular dorso-lumbar kyphosis of moderate degree. The abdomen was moderately enlarged. There were no herniae.

The arms showed limitation of movement at the shoulders, elbows and fingers. When the arms were abducted the scapulae were rotated into the axillae. The elbows could not be quite straightened. There was a permanent semiflexion of all the fingers giving a claw-handed appearance. The legs looked very slender in comparison with the other parts of the body. There was slight limitation of movement in the hips and knees.

Nutrition was satisfactory, and there was a good layer of subcutaneous fat in all areas.

SURFACES. The skin looked healthy and showed good elasticity. The hair was long and flaxen and not unduly fine or coarse. The eyebrows were dark, coarse, and thicker than usual, meeting in the midline. The

complexion was not remarkable. A moderate degree of hypertrichosis was observed on the upper part of the back of the chest and on the back of the upper arms. This hair was fine and fair. The eyes showed slight but definite cloudiness of both corneae. An ophthalmological examination under general anaesthesia was made by Dr. J. R. Paterson and showed a slight but definite degree of papilloedema in both fundi.

MUSCULAR CONDITION. The general muscle volume was below average. The legs were relatively thin, particularly below the knees. The gait was unsteady on walking with assistance. The co-ordination of hand movements was fair.

MENTAL CONDITION. The child was mentally defective. She noticed what was happening around her and looked at one quite knowingly. She became very cross when undressed for examination and resented examination. Said 'Mammy' and occasionally one or two indistinct words accompanied by a movement towards something desired. She tried to help when being dressed and was inclined to be playful.

ALIMENTARY SYSTEM. The abdomen was moderately enlarged. The liver was slightly enlarged, the lower border being palpable two fingerbreadths below the costal margin in the mid-clavicular line. The spleen was not palpable.

RESPIRATORY SYSTEM. There was a slight mucopurulent discharge from both nostrils and a similar post-nasal discharge. There was noisy, snorting breathing. She often stopped breathing for a short time, and this was usually followed by one or two loud snorting expirations. The mother said she had always breathed in this manner.

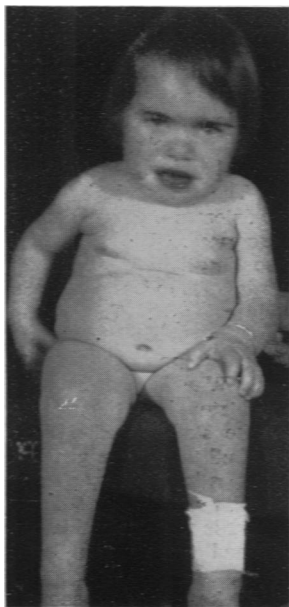

FIG. 16.—E.D. (Case 2) aged 2 years 4 months. The facies and claw-hand are typical of gargoylism.

X-RAY EXAMINATION OF SKELETON. All of the most characteristic features of gargoylism were present in the skeleton. The sella turcica was enlarged. The ribs were broad. The body of the first lumbar vertebra was small and had a hook-like appearance in the lateral view owing to a defect in the upper half of the anterior part of the body (Fig. 17). The limb bones were thickened and roughly formed, and the smaller long bones showed an abnormal degree of rarefaction and trabeculation. There was severe deformity at the bases of the metacarpals and there was great delay in the appearance of carpal and metacarpal centres of ossification (Fig. 18).

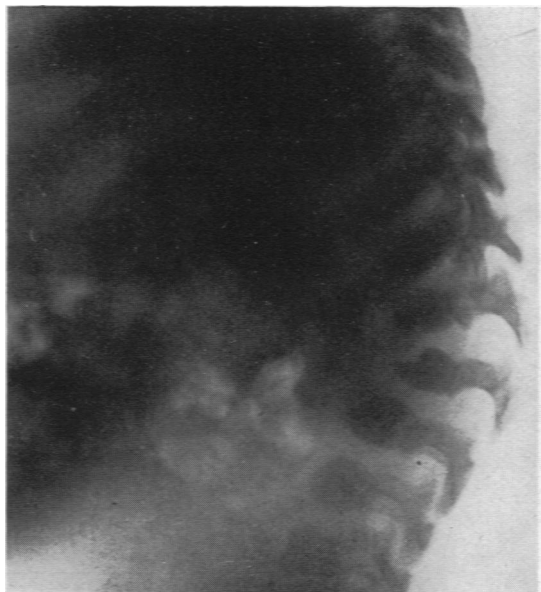


FIG. 17.—Lateral radiograph of dorso-lumbar spine in Case 2, showing typical hook-like deformity of the body of the first lumbar vertebra. The characteristic broad ribs are also found.

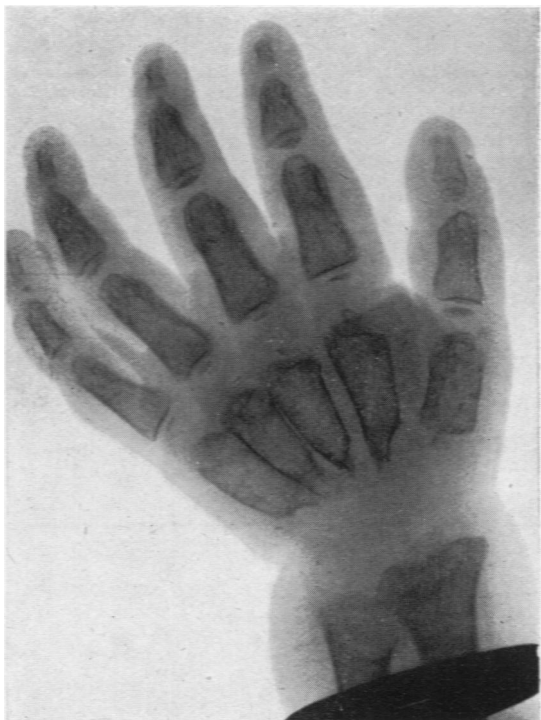

FIG. 18.—Radiograph of hand in Case 2, showing a severe degree of malformation of the metacarpal bones and generalized thickening and irregularity.




FIG. 19.

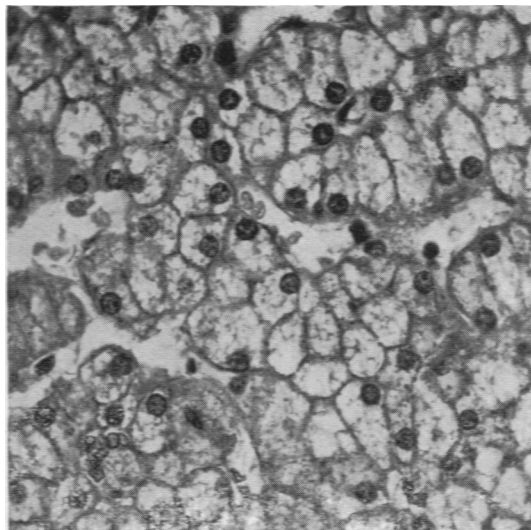


FIG. 20.

When the child was 3 years 9 months (weight, 33½ lb.; height, 34 in.) the adenoids were removed to try to diminish the chronic nasal discharge.

At 4 years specimens of liver, spleen and tibia were taken for biopsy.

At 5 years 8 months the child died at home. There had been progressive oedema for the last few months which was maximal in the dependent parts, and probably an indication of heart failure.

Histological Report

The following report was made from the biopsy specimens.

Liver (Figs. 19 and 20). The epithelial liver cells were greatly swollen. The cytoplasm contained many vacuoles. The nucleus retained its central position. All zones of the hepatic lobule were equally affected. The sinusoids had been compressed by the swelling of the cells, and were inconspicuous. The Kupffer cells appeared normal and were not vacuolated. The portal tracts and the structures in them were unaltered. Frozen sections stained with Sudan III revealed very little fat in the cells. The material in the vacuoles was not stained by this method.

Spleen (Fig. 21). The sinusoids of the pulp were unusually conspicuous. Their lining endothelial cells were swollen so much that they occupied about half the lumen of the sinusoids; their cytoplasm had a foamy character on account of numerous fine vacuoles. The Malpighian bodies were very large; the lymphocytes appeared normal, but among them there were small groups of large, foamy cells.

Bone. The specimen of tibia examined showed no pathological changes.

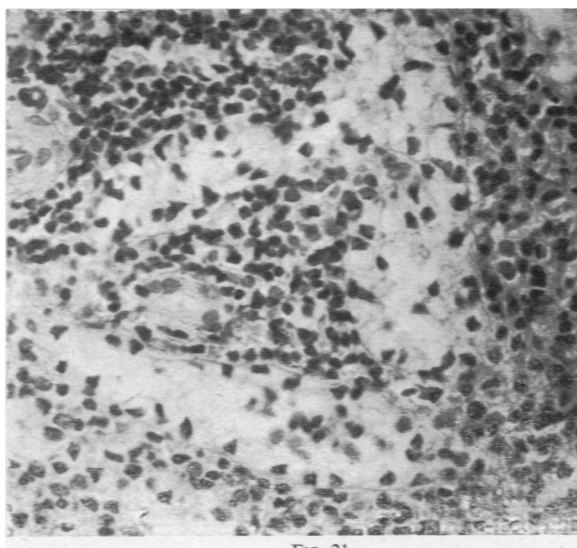


FIG. 21.

FIG. 19.—Liver in Case 2: all the epithelial cells are swollen and vacuolated. The sinusoids have been compressed and are inconspicuous. H. & E. $\times 100$.

FIG. 20.—Liver in Case 2: the epithelial cells are finely vacuolated. The nuclei are neither compressed nor displaced. H. & E. $\times 400$.

FIG. 21.—Spleen in Case 2: the endothelial cells lining the sinusoids are swollen and vacuolated, and cause the sinusoids to be unusually clearly defined. H. & E. $\times 400$.

Case 3. L.D., a girl, was the sister of E.D. (Case 2). She was examined on March 24, 1950, aged 2 years 4 months.

The family history is described under Case 2. After the death of E.D. (Case 2) a fourth pregnancy resulted in a stillborn infant, a fifth in the birth of this child, and a sixth in the birth of a male infant now aged 10 months and quite normal.

The baby was born at full term by breech delivery after a normal pregnancy (birth weight, 7½ lb.) at the Western General Hospital, Edinburgh. Nothing abnormal was observed in the neonatal period. She was breast fed for three months.

Development is retarded, and she cannot yet assume a sitting position by herself. She began to walk around objects at 1 year 8 months, but still falls readily. Speech began at 2 years, but is still poor. She still has urinary incontinence. She has never had any fits.

At 7 months a lump began to grow on the top of the head.

Her appearance (Fig. 22) is typical of gargoylism. (height, 33 in.; weight, 31 lb.; head circumference, 19 in.). The cranium is long and narrow, with a low, narrow forehead. A large, oval, bony prominence in the region of the anterior fontanelle is seen; also bony swellings behind and above the ears. The occipital ridges are prominent, the nose bridge depressed and wide. The eyes are slightly protuberant and corneae slightly opaque, the eyebrows thick, the mouth a little large, and the tongue large but not fissured. The cheeks are ruddy.

There is pronounced dorso-lumbar kyphosis, a protuberant abdomen, but no umbilical hernia. The limbs look short and there is genu valgum. Extension is limited at the shoulders, elbows and fingers, and to some extent in the legs. There are moderate claw-hands with incurving little fingers.

A systolic murmur is heard in all areas of the heart.

The liver is enlarged to three fingerbreadths below the costal margin in the mid-clavicular line. The spleen is moderately enlarged and easily palpable.

She is a mentally defective child of moderate degree. The eyes show a vertical nystagmus, more on the right than on the left, particularly when looking at an object. No other abnormal nervous signs were found.

There is a continuous mucopurulent rhinorrhoea and post-nasal discharge. The chest is normal.

Urine and blood examination were normal.

X-ray examination of the skeleton showed the typical features of gargoylism (Figs. 23 and 24), also the peculiar osseous swelling in the region of the anterior fontanelle observed clinically (Figs. 25 and 26).

Histological Report

Liver (Figs. 27 and 28). Frozen sections of a biopsy specimen were examined for glycogen and fat, also paraffin sections.

In the routine haematoxylin and eosin sections the liver cells appeared swollen and vacuolated. Most of

the vacuoles were small, but some filled most of the cell. The nucleus was sometimes central, but often lay to one side of the cell; it retained its round shape and was never flattened. The sinuses were compressed and narrow and the tissue appeared bloodless. The Kupffer cells were not swollen. The portal tracts showed no increase of fibrous tissue, but they were conspicuous on account of cellular infiltration. The cells were lymphocytes and histiocytes, and among the latter some were immensely swollen and foamy. In the small portal tracts there were only two or three cells in this condition, but in some of the larger ones the foamy cells were quite conspicuous.

In the frozen sections stained for fat by the Scharlach red method, stained fat was present in excess in some of the liver cells, but was far from accounting for all the vacuolation. It was not detectable in the foamy histiocytes in the portal tracts. In sections stained for glycogen, only a small quantity was present; the majority of the cells contained none.

The histological features were typical of the liver in gargoylism. The stored substance failed to stain by ordinary methods for either fat or glycogen.

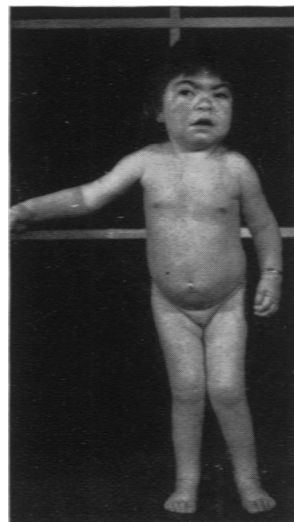


FIG. 22.—L.D. (Case 3) aged 2 years 4 months. The appearance is typical of gargoylism, particularly the facies. Note also the claw-hand.

Biochemistry

A biopsy specimen of liver was submitted to Dr. S. L. Thompson. The results are shown in Table 3.

TABLE 3
BIOCHEMICAL ANALYSIS OF BIOPSY SPECIMEN OF LIVER IN CASE 3

	Dry Tissue (mg./100 mg.)*			
	Normal (Age 8 Months)	Case 3 (Age 2 Years 8 Months)	Normal (Age 6 Years)	Normal Adult
Total fatty acids ..	7.2-8.5	8.0	9.0	8.6-13.0
Cholesterol ..	0.4-0.6	1.0	0.4	2.1-2.6
Glycogen	13.3	..	4.4-25.2 [†]

* Estimations were done on fresh tissue. Figures for dry tissue calculated on the assumption that wet tissue contains 75% of water.

† Range of glycogen content in fresh biopsy specimens of liver from 10 adults with normal livers (MacIntyre, Pedersen and Maddock: 1941). In glycogen storage disease the liver contains 40 mg. or more per 100 mg. of dry tissue.

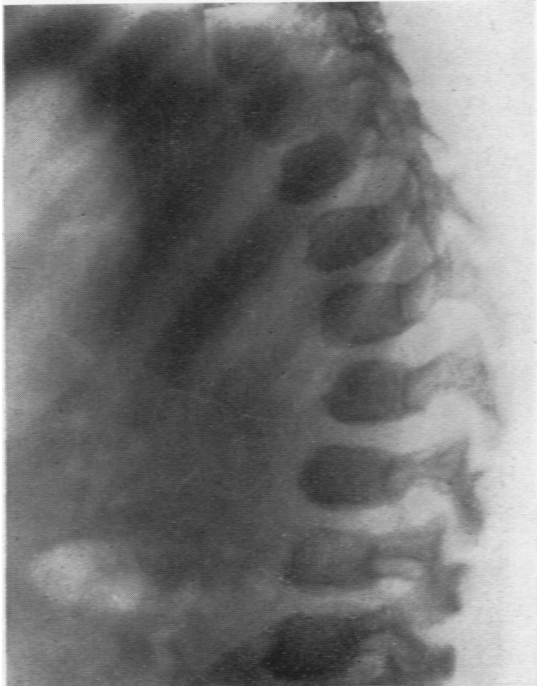

FIG. 23.—Lateral radiograph of dorso-lumbar spine in Case 3, showing the characteristic defect of the anterior part of the body of the lower dorsal and upper lumbar vertebrae.

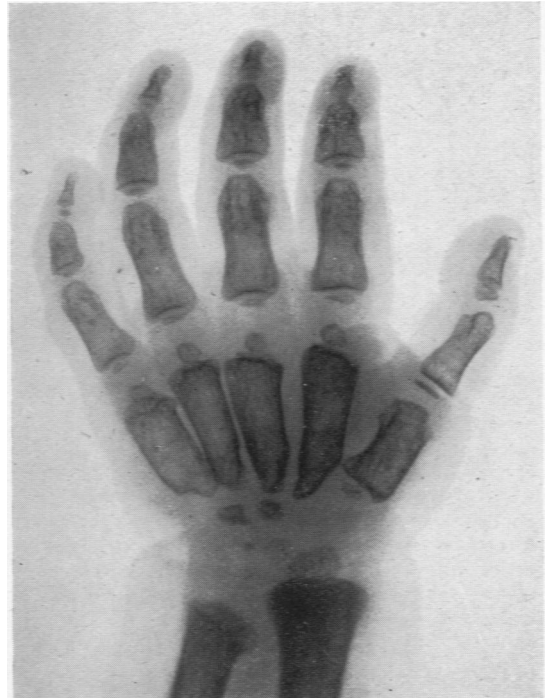

FIG. 24.—Radiograph of hand of Case 3, showing characteristic malformation of the metacarpal bones.

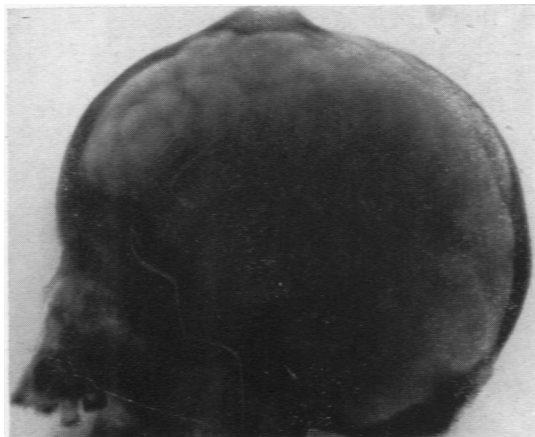


FIG. 25.—Lateral radiograph of skull of Case 3, showing the osseous swelling in the region of the anterior fontanelle. The deep convolutional markings indicate a long-standing increase of intracranial pressure.

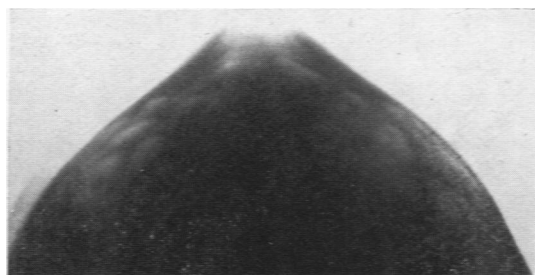

FIG. 26.—Antero-posterior radiograph of skull of Case 3.

THE LITERATURE ON THE PATHOLOGY OF GARGOYLISM

The pathology in each individual organ will be reviewed, and the local features will then be linked together by a discussion of the general pathological features of the disease. The incompleteness of most of the case reports precludes an accurate assessment of the incidence of characteristic lesions of the disease in most of the organs of the body.

The Liver

Morbid Anatomy. This was described in 23 cases, though often briefly. The organ was enlarged in 16, of normal size in four, small in one, and the size was not mentioned in two. The anterior border was rounded in a few of the cases with enlargement. Abnormal pallor was described in the majority, particularly of the cut surface. It was described as soft in four cases and firm in four cases. Two of the firm livers had distinct lobular markings suggestive of cirrhosis.

Histology. Microscopic examination was done in 24 cases, including six biopsy specimens. The parenchymal cells were enlarged and contained vesicular or foamy cytoplasm in a high proportion of cases; an eccentric nucleus was noted in several instances, also a disturbance of the normal cord arrangement of the cells. Increased connective

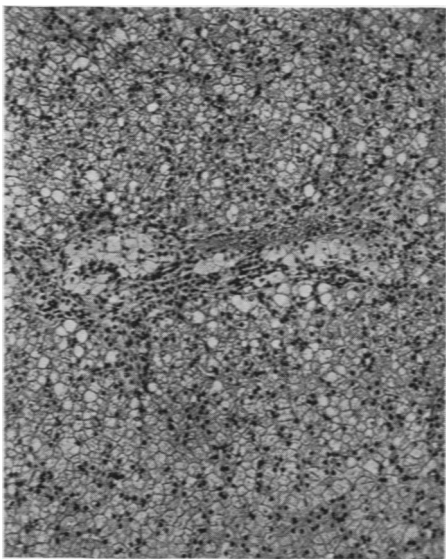


FIG. 27.—Liver of Case 3: the cells are swollen and contain fine vacuoles in the cytoplasm; some have larger vacuoles. A group of 'foamy' histiocytes lies in a portal tract in the centre of the field. H. & E. $\times 85$.

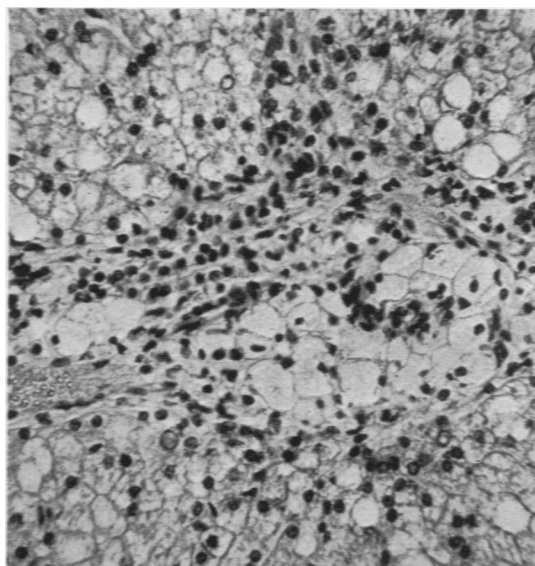


FIG. 28.—Liver of Case 3: higher magnification of part of field shown in Fig. 27. Note detail of vacuolated liver cells, and 'foamy' histiocytes in a portal tract. H. & E. $\times 250$.

tissue in the portal spaces, causing the hepatic lobules to be more distinctly outlined than normally, was observed in several cases, and in three instances irregular strands of hyaline connective tissue were observed throughout the parenchyma.

The Kupffer cells showed vesiculation resembling that seen in the parenchymal cells in five cases. No histological abnormality was detected in the liver in three cases.

The Spleen

Morbid Anatomy. The spleen was described in 21 cases, briefly in most of them. It was enlarged in 15, usually moderately, and normal in size in six. In some the cut surface looked normal, in others the Malpighian bodies were not visible. A few were 'pale'. The consistence was seldom mentioned and was therefore presumably normal, as a rule, but it was described as firm in three cases and soft in two.

Histology. Microscopy was done in 17 cases, two of the specimens having been obtained by biopsy. The lymphoid follicles were described as widely spaced and small in a minority of the cases. The most striking abnormality, observed in most instances, was enlargement of the reticulo-endothelial cells lining the sinusoids and the presence of many large mononuclear cells in the intersinusoidal spaces; both types of cell were

distended and vacuolated. Enlargement and vesiculation was seen in some of the lymphoid cells in the Malpighian bodies in two cases. The pulp was described as normal in five cases.

The Heart

Morbid Anatomy. The heart was described in 21 cases. It was enlarged in the majority. Hypertrophy of the left ventricle was a notable feature, as a rule. The pericardium had a normal appearance in all cases, but the epicardium showed areas of opaque thickening over the ventricles in three instances. The myocardium looked normal in all cases except two in which it was pale. The endocardium had a normal appearance in most of the specimens but in six it was thickened and opaque: in one case this change was apparently generalized, in another it was limited to the left auricle, in two to the left ventricle, and in one to both ventricles. The coronary arteries were described as abnormal in three cases, including our Case 1: the main vessels on the surface of the heart showed conspicuous, rigid, nodular white cords caused by extreme thickening.

The most constant abnormality in the heart was in the valves, particularly the mitral valve, and in the chordae tendineae of affected atrio-ventricular valves. One or more abnormal valves were described in 14 of the 20 cases. The mitral

valve was affected in all of the 13 cases in which the various valves were specified, the tricuspid valve in eight, the aortic in seven and the pulmonary in two. There were only two cases in which all the valves were affected. In most cases the affected mitral and tricuspid valves were thickened and opaque, though in some this was not so: thickening was not accompanied by shrinkage in the few cases in which this aspect was mentioned; Kressler and Aegerter (1938) observed some deposition of calcium in the thickened mitral valve. In the majority of cases the mitral valve showed numerous small fibrous nodules along the free edge and line of closure of the cusps; these were sometimes discrete and sometimes had coalesced. Nodules were found in a few cases in which the cusps were said not to look thickened. In our case and that of Strauss (1948) there were fibrous nodules at the attachment of the chordae to the cusps. The chordae of affected mitral and tricuspid valves were thickened and shortened in varying proportion and degree.

Affected aortic and pulmonary valves were described as thickened; in two cases this was said to be more pronounced at the free edges. In one case there was a deposit of calcium at the base of an affected aortic cusp.

Histology. Heart tissues were examined microscopically in 16 cases. The pericardium was mentioned in eight instances. It looked normal in two cases and thickened in two. In three cases there was a slight lymphocytic infiltration, while in two, swollen mononuclear cells of the type seen in other tissues were observed, particularly in the vicinity of blood vessels. The epicardium was examined in two cases in which its naked-eye appearance was normal, and it did not show any abnormality.

The myocardium was mentioned in 12 cases and vacuolation of the fibres was a feature in eight instances, two of which also showed brown atrophy; in one case vacuolation of muscle fibres was a notable feature in the auricles but none was seen in the myocardium of the ventricles. Groups of muscle fibres were replaced by delicate connective tissue with vacuolated cells in three cases, this change being adjacent to the abnormal valvular endocardium in one of these. The interstitial tissue of the myocardium was mentioned in four cases: the fibrous tissue was increased in amount and the connective tissue cells were swollen and vacuolated in three instances; in two cases small lymphocytic collections were found in a few places.

The mural endocardium was normal in two cases and thickened in six, with changes similar to those to be described in the valves. The

endocardium over a papillary muscle in one case and in the vicinity of a valve in another showed similar changes.

The abnormal valves and the endocardium of abnormal chordae tendineae were thickened and consisted of an increase of fibrous tissue in various stages of development with swollen vesicular connective tissue cells between the collagenous fibres; the number of these cells was usually inversely proportional to the amount and density of the fibrous tissue. In three cases with less advanced fibrosis the cells were arranged in columns and the tissue had the 'appearance of fibrocartilage'. With the exception of one case no vascularization was seen; inflammatory cells were not found. Degenerate foci in the valves, with calcification, were seen in four cases.

The coronary arteries were thickened in five cases.

The Blood Vessels

Morbid Anatomy. Certain of the blood vessels were described in 12 cases. No abnormality was observed in two of these.

The naked-eye appearance of the aorta was mentioned in 11 cases and it was abnormal in eight: several small, pale yellow intimal plaques were observed just distal to the aortic valve in five cases; in one case similar lesions were found in the descending aorta, particularly near the openings of the intercostal vessels; the lesions were 'longitudinal' in two cases. The large branches of the aorta were similarly affected in one case.

The coronary arteries were described in seven cases and gross changes were observed in three of them, one being our Case 1. They looked normal in the other four cases. In our case 'the thickened condition of the coronary arteries was most arresting. They were straight, prominent and hard. They felt like nodular cords and were studded with numerous small, pale yellow flecks. Not only the main branches but even the smallest visible twigs on the surface of the heart were affected in this way.' Lindsay *et al.* (1948) in two of their cases (Nos. V and VII) found 'all the main coronary arteries extremely thickened due to the deposition of greyish translucent material within the intimal layer. This process left a small cleft-like lumen in these vessels.'

The surface cerebral arteries were mentioned in four cases. They looked normal in two over the cortex and in one at the base of the brain, but in our Case 1 the arteries at the base of the brain showed white flecks in their walls resembling atheromatous deposits. In four cases the cerebral white matter showed many tiny perivascular

cystic spaces $\frac{1}{2}$ -1 mm. in diameter. They contained 'pale translucent mucoid material'.

The pulmonary vessels appeared normal in two cases, but the large branches showed slight thickening in one.

In one case a main pancreatic artery showed mild eccentric thickening of the intima.

Histology. Histological descriptions of some vessels were given in 14 cases. In 13 cases the vessels examined were specified and were as follows:

ABNORMAL. Aorta eight, main coronary seven, brain five, spleen three, pancreas three, kidney two, pulmonary one, carotid one, mesenteric one, radial artery one, anterior tibial artery one.

NORMAL. Basilar two, hepatic two, and each of the following one, small coronary, axillary, internal carotid, vertebral, renal, lingual and choroid plexus.

In the aorta the localized zones of intimal thickening had the same features as in other arteries, namely connective tissue fibres with cleft-like spaces and swollen vesicular connective tissue cells. The media in the affected areas showed unusually distinct elastic fibres separated by fusiform clefts containing swollen connective tissue cells. In some cases the adventitia was said to show similar changes and in others to be normal.

The histological features in the medium-sized arteries listed above were fairly uniform, and the description given in our Case 1 is representative. The coronary arteries on the surface of the heart showed striking changes. The intima was immensely thickened in an almost uniform concentric manner. It was composed of fibrous tissue in the interstices of which were numerous large foamy cells. The surface endothelium was intact. The internal elastic lamina could be traced round most of the circumference but had suffered fragmentation at a few points. The media was stretched and thin and had been slightly invaded by foamy cells, especially in the inner part, immediately external to the elastic lamina, but here and there also in the outer part. In some of the other arteries, such as the radial and anterior tibial in our case, the changes which were essentially the same differed in two respects: the intimal thickening was not concentric, but more on one side than the other, and the abnormal tissue that was responsible for it was more densely fibrous and contained fewer foamy cells.

The cerebral vessels in the white matter showed a great widening of the adventitia with wide spaces which contained irregular fragmented collagenous fibres, a variable number of distended connective

tissue cells and in some cases a deposit of extra-cellular amorphous material, hence the small cysts observed macroscopically when these changes are extreme.

In one case a large renal artery at the junction of cortex and medulla showed interesting changes, since this is the only record of the muscle fibres of the media showing vacuolation; they were extremely vacuolated and had small pyknotic nuclei. The internal elastic membrane was distinct. The other layers of the vessel were normal. In another case a large intrarenal artery showed focal intimal thickening.

The Meninges

Morbid Anatomy. Reference was made to the meninges in 11 cases. Gross pathological changes were found in three cases, the seventh case of Lindsay *et al.* (1948), Magee's (1950) case, and our Case 1. In the first of these the superior and anterior surfaces of both cerebral hemispheres were covered with encapsulated collections of dark brown, viscous, sanguineous fluid which had no doubt exuded from subdural haematomata. Elsewhere the subdural space was lined with thick, yellowish-green fibrin indicating recent meningitis. No gross subarachnoid exudate was seen.

In Magee's case the dura mater looked normal, and had a smooth, glistening inner surface, but the pia arachnoid covering the convexity of the left cerebral hemisphere was either enormously thickened, or adherent to a smooth, opaque, grayish covering of firm tissue which measured 0.5 cm. or more in thickness in some places. This densely organized tissue completely obscured the convolutional pattern. There was a similar, though thinner, layer over the right frontal lobe, and a large encapsulated subdural haematoma covered most of the right hemisphere.

Our case showed 'adhesions between the dura mater and the pia arachnoid over the vertex of the brain. Over this area there was a deposit of yellowish material which adhered to the inner surface of the dura and to the arachnoid. The leptomeninges showed a peculiar greyish opacity which intensified to whiteness over the temporal poles. The subarachnoid space was slightly enlarged and contained a quantity of gelatinous material'.

Minimal data are given about the other eight cases which showed some abnormality. In five cases the leptomeninges showed local or diffuse thickening with a varying degree of opacity. In one 'the dura was considerably thickened' and in another 'the dura was adherent to the anterior part of the left frontal lobe'. In one case 'the

meninges, especially over the frontal lobes, were thickened and greyish'.

Histology. Some microscopical data are given in eight cases. In the seventh case of Lindsay *et al.* (1948) the microscopic changes were consistent with the changes produced by subdural haematomata and meningitis.

Microscopically the thick, firm tissue in Magee's case was seen to be composed mainly of thick, dense, collagenous connective tissue which resembled dura mater. The arachnoid could not be distinguished, but there was a clear line of cleavage between the leptomeninges and the surface of the cerebral cortex. Large numbers of elongated 'macrophage' cells with small, darkly staining nuclei and abundant, lightly staining reticulated cytoplasm lay between the strands of coarse connective tissue. The cytoplasm was honeycombed with small, round, non-staining vacuoles. Nearer the surface of the cortex there were irregular sheets of cells with large, densely staining, pleomorphic nuclei and abundant honeycombed cytoplasm; these cells had a more rounded, fuller appearance than those lying in the interstices of the denser collagen fibres. In some places the cells were so closely packed that large masses of them were contiguous. Fine strands of connective tissue ran into these densely cellular areas. By means of a variety of staining methods they concluded that the major portion of the substance in the distended cells was a neutral fat, but that 'the consistent failure to stain all the cytoplasm leaves doubt about the nature of the unstained portion'.

In our case 'the deposit on the inner surface of the dura mater was composed of sheets of foamy cells with a small amount of supporting fibrous tissue and blood vessels. In the subarachnoid space there were moderately numerous histiocytes, and distension of the subarachnoid meshes by extra-cellular amorphous material was a striking feature' (Figs. 12 and 13).

Tuthill (1934) found 'a universal distribution of lipid particles in conglomerate masses in the thickened meninges, particularly at the base of the brain'. She believed that these changes could have been caused by the associated tuberculous meningitis. In one case the arachnoid showed 'fibrous thickening and oedema', in another 'some of the connective tissue cells showed typical enlargement', while in another 'the subarachnoid space was wide and contained an increase of collagenous fibres and the fibroblasts were swollen and vesicular'. In Green's (1948) case the leptomeninges over the brain and spinal cord were

thickened and contained scattered compound granular cells intermingled with large macrophages.

The Brain

Morbid Anatomy. The macroscopic appearance of the brain was mentioned in 22 cases, sometimes only briefly. The brain was enlarged in 11 of 17 cases in which size was mentioned. Symmetrical internal hydrocephalus was a feature in nine cases. The convolutions were flattened in three cases, in one of which the brain looked swollen and oedematous; in two cases they showed some atrophy. Small perivascular cysts containing mucoid material were observed in the white matter on sectioning the brain in five cases; this feature was revealed in even more cases on microscopy. In two cases, including Case 1, a moderate degree of atrophy of the white matter was found. In one case the cortical layers of the cerebral hemispheres were widened and had an unusual grey, translucent appearance; scattered throughout this layer were numerous small, yellow, opaque zones of softening. In another case the cortical layers of the cerebral hemisphere were less distinctly outlined than normally, and were apparently separated into an outer and an inner cortical layer. Green (1948) reported moderate reduction in the grey matter of the cerebral hemispheres and increased consistency of the white matter.

Ependymal changes were observed in two cases. In one case it appeared thickened in the lateral ventricles and had minimal brownish pigmentation. In the other, in the same situation, it was oedematous, congested and opaque and covered in part with a fibrinous exudate.

Histology. Microscopy was done in 20 cases. The most detailed reports of the histology of the central nervous system were given by Tuthill (1934), Ashby *et al.* (1937) (Case 1) and Green (1948). Pathological changes were found in the brain in all cases except two, the mentally defective patient of De Lange *et al.* (1944), who was regarded as a *forme fruste* of gargoylism, and the 4½-month-old infant recently described by Lindsay (1950). In both cases the central nervous system was found to be completely normal on careful examination of all portions.

Abnormal cortical cytoarchitecture was described in seven cases. This was usually described as 'irregularity of nerve cell layers'. Ashby *et al.* in their first case described 'a loss of the normal columnar arrangement of the nerve cells'. Tuthill found disturbed cell arrangement only in the temporal lobes near the cornu ammonis. Reduction of the cortical nerve cell population was mentioned

in four cases, but may well have occurred in some others.

In 16 of the 18 cases showing pathological changes in the brain the cortical nerve cells were affected. In one of the remaining two cases they were 'not enlarged' and in the other they were not mentioned. The following is a typical description of the cortical cells: 'The majority of the cortical cells are swollen, rounded or oval, and are interspersed with normal and disintegrating cells. The nuclei are usually displaced eccentrically and in some cells are degenerate or absent. The cytoplasm consists of greyish, granular non-staining material; it is sometimes vesicular, and contains either no or a greatly diminished amount of Nissl substance'. Little was said about the cell processes in most of the cases. In several of their cases Lindsay *et al.* made the rather vague and sweeping statement that 'the cell processes had usually disappeared'. Some other authors gave a more detailed description: the dendrites were described as 'nowhere conspicuous' by Ashby *et al.* in their first case, 'slightly puffy' by Tuthill and 'wide and distended' by Kressler and Aegerter (1938). The axons showed less abnormality than the dendrites: Ashby *et al.* in their first case described them as normal and in their second as 'relatively well preserved'; Tuthill found them 'slightly puffy' and Kressler and Aegerter 'wide and distended'.

The nerve cells were not equally affected in all parts of the central nervous system, though as a rule some abnormal cells were found everywhere. The distribution of the more severely affected cells varied considerably from case to case though in a majority certain areas showed a predilection for the optimal changes. In 14 cases in which the distribution of pronounced cell changes was mentioned, the cortex was specified in 11; in some instances certain areas of the cortex were more severely affected than others. The basal nuclei showed optimal nerve cell changes in nine cases; the various nuclei were not specified, as a rule, but when they were, some, such as the optic thalamus, were usually more affected than others. Certain nuclei of the brain stem showed pronounced cell changes in 10 cases. The cerebellum was usually less severely affected than the cerebrum, but it also showed pronounced changes in seven cases; the Purkinje cells in four cases, the external granular layer in two cases, and the dentate nucleus in one. Severe changes were observed in the anterior horn cells of the spinal cord in six cases; two of these also showed similar changes in the posterior horn cells. Minimal cell changes were described in the cortex in two cases, in certain of the brain stem nuclei such as the hypoglossal in

four, and in the cerebellum, particularly in the Purkinje cells, in three. The ganglion cells in the anterior horn of the spinal cord showed minimal changes in one case and moderate in one case, in addition to the five cases showing severe changes.

The myelin sheaths of the nerve fibres were referred to in eight cases. No demyelination was observed in three cases, but it was present in five instances. Tuthill found universal thinning of the myelin sheaths in the white substance of the cerebral hemispheres, and typical fat granules in a few large areas which showed destruction of myelin sheaths; the optic nerves showed an entire loss of myelin with a heavy mantle of fat granule cells. In one of their cases Lindsay *et al.* found 'the fibre pattern unusually rarefied with little myelin substance present in the fibre tracts', while in another 'there was mild demyelination in the anterolateral columns of the spinal cord'. Green (1948) reported minimal demyelination in the cortical white matter and in the basal ganglia. Jervis (1950) found large areas of active demyelination frequently in the white matter.

Gliosis was referred to in only a few cases. Ashby *et al.* found several zones of pronounced gliosis in the basal ganglia in both of their cases. Lindsay *et al.* described an excess of glial and microglial cells in the cortical white matter of their case which showed some demyelination in that situation. In another case of the latter authors the glial cells in the cortex showed changes resembling those seen in the nerve cells, but they were less severe. Green reported considerable glial proliferation in the grey and white matter of the cortex, in the basal ganglia and spinal cord, and minimal proliferation in the brain stem and cerebellum. He also observed distension of cell bodies of some glial cells. Jervis observed considerable neuroglial reaction in the cortex in one of his cases. Lindsay *et al.* observed that the astrocytes and oligodendrocytes in the cortical and subcortical layers in one of their cases had abundant, clear, vacuolated cytoplasm similar to that seen in the nerve cells.

Sympathetic ganglia were examined in three cases (Magee, 1950; Jervis, 1950) and, in all, the neurons showed changes similar to those described in the neurons of the central nervous system.

A greatly widened adventitial coat and very wide perivascular spaces surrounded the medium-sized and smallish vessels of the cerebrum in all cases in which the cerebral vessels were mentioned. The histological appearance has been described in the section on blood vessels.

A deposit of variable amount was found in the nerve cells in all parts of the central nervous

system. Ashby *et al.* showed that the granular deposit in the nerve cells seldom failed to be revealed in cells even of normal contour and size. It was, however, most abundant perivascularly, the largest amount in this situation being seen in the globus pallidus and in the following regions in diminishing amounts: putamen, caudate nucleus, optic thalamus, zona reticulata of the substantia nigra and dentate nucleus. In the cerebral cortex it was found around the blood vessels only in the pre- and post-central zones. A small amount of deposit was also found in the grey matter of the cerebellar hemispheres where, in one or two situations, it lay free between folds of pia mater covering the folia. None was found in the white matter of the cerebrum or cerebellum. In their second case Ashby *et al.* found small amounts of deposit in the nerve cells, but it was insufficient to cause either ballooning of the cell body or displacement of the nucleus except in one or two regions. No free lipid could be identified with polarized light in this case; a very detailed examination of the deposit was not made because of the age of the material. Tuthill found that all of the nerve cells contained 'lipoid' regardless of the degree of morphological change, and the amount varied with the degree of swelling; in common with others he found perivascular 'lipoid' infiltration of the medium and smaller sized cerebral vessels; unlike others he found 'lipoid'-containing cells scattered throughout the white matter. Kressler and Aegerter merely stated 'about the nuclei of many of the nerve cells were clear, crescent-shaped areas which contained considerable quantities of lipid material'. In our case the nerve cells in all parts examined showed granules of an isotropic substance in the cytoplasm; histiocytes containing 'lipoid' were present in the perivascular spaces; in the cerebral white matter especially this was associated with distension of the adventitia of the blood vessels with extracellular 'lipoid'.

Eyes

Morbid Anatomy. Reports on the eyes are available in 10 cases, in six of which the eyes were examined post-mortem by ophthalmologists. The reports in the latter cases will be considered, because they are the more authoritative. They were published by Berliner (1939), Rochat (1942) and Zeeman (1942), each one case, and by Cordes and Hogan (1942) three cases. The latter authors state that corneal clouding is present in over 75% of cases, generally appears before the age of 3 years, and has been observed at birth. Apart from the ground-glass appearance and diffuse haziness there is no

sign of inflammation in the eye or of vascularization of the cornea. On examination with the slit lamp the haze is resolved into uniformly distributed, tiny, grey or yellow-grey dots which at first occupy the middle and deeper layers of the cornea. Later they are distributed throughout the stroma. These dots do not appear to be crystalline and are only slightly refractile. After a certain degree of opacity is reached the cornea remains unaffected. Hyaline or calcareous degeneration of this material in the cornea has not been reported.

Histology. Microscopy was done in 11 cases, six being reported by ophthalmologists. The reports of the ophthalmologists were in agreement. In all cases pathological changes were limited to the cornea where they were concentrated in or near Bowman's membrane. In this membrane numerous defects were scattered across the whole cornea, and these were occupied by large cells containing vacuolated cytoplasm, the cells varying from spindle-shaped to globular. Their cytoplasm contained numerous glistening granules which were sometimes confluent and looked like snowflakes. They were soluble in ether and alcohol but were not doubly refractile in polarized light. Reactions with fat stains such as osmic acid and Sudan III were negative. Sometimes two corneal lamellae were separated and the resulting space was filled with large granular cells of the same type. Scattered swollen corneal corpuscles containing granules were also observed. Cordes and Hogan pointed out that both normal tissue cells and phagocytes are therefore involved. These authors concluded that the numerous corneal opacities, seen as tiny dots with the slit lamp, are produced by the infiltration of phagocytic cells into the region of Bowman's membrane causing thinning and ruptures in it by the swelling of these corneal corpuscles. There was no other cellular or fluid extravasation into the stroma to account for them.

Lindsay *et al.* in their seventh case described changes in the eyes additional to the characteristic changes in the cornea. The epithelial cells on the surface of the ciliary body and the posterior surface of the iris were enlarged and vacuolated. The connective tissue of the iris, ciliary body and choroid was loosely arranged and contained numerous vacuolated macrophages. Many of the nerve cells in the nuclear layer of the retina were enlarged and vacuolated.

Bone and Cartilage

Morbid Anatomy. The skeletal malformations are too well known to need recapitulation.

Histology. Reports on bone and/or cartilage

have been given in 20 cases. The specimens were obtained by biopsy in several instances. There were eight individual reports before Lindsay and his colleagues described the histology of certain bones in eight of their cases. In the earlier cases the bones, which were cartilage bones taken from a variety of situations, were described as normal in three cases, and as showing hypoplastic chondrodystrophy in two cases. In three cases, however, swelling and vacuolation of cartilage cells was observed: Schmidt (1942) was the first to report this feature. No abnormality was seen in the bone examined in our two cases, or in the costal cartilage in the two cases recently reported by Jervis (1950). More extensive examination would probably have revealed some abnormality in those cases in which none was found in the single specimen examined, since abnormal morbid anatomy of the bones is almost a constant feature of the disease.

Lindsay *et al.* demonstrated fairly uniform changes in each of the eight cases in which the bones were examined. The most striking feature was swelling and vesiculation of cartilage cells, though several other characteristic changes were observed. The costochondral junctions were examined in several cases, and in all of them the cartilage cells were unusually large and almost completely filled the lacunar spaces in the cartilaginous matrix. The cytoplasm of the cartilage cells was more abundant than usual and was granular and vesicular. The osteocytes were similarly affected as a rule. Some of the connective tissue cells in the outer layer of the periosteum also showed similar changes and the periosteum was usually thickened. In some cases there was no distinct epiphyseal line with little evidence of growth. In all cases the cortical layer of rib was thin and usually irregular also. Abnormal lumbar vertebrae were examined in two of the cases of Lindsay *et al.* The epiphyseal lines were extremely irregular, and all the cartilage cells both of hyaline cartilage, and of fibrocartilage in the intervertebral discs, as well as the osteocytes and periosteal connective tissue, showed distension of cytoplasm by granular, grey material. The bony trabeculae of the vertebral bodies were thin and irregular and showed no osteoblastic activity. Anteriorly at the point of the characteristic indentation the cartilage was deficient and was replaced by dense fibrous tissue; it appeared as though the vertebral body had collapsed anteriorly because of the unusually thin layer of cortical bone forming the anterior portion of the vertebral body.

Strauss (1948) gave a detailed account of the histology of a rib and an abnormal lumbar vertebra in her case. In a rib

the resting cartilage of the epiphysis was normal. The zone of proliferating cartilage was shortened and the cartilage columns were plump, and in places missing. Where the proliferating cartilage cells were absent there was an area of vascular connective tissue containing many large, swollen, vacuolated cells similar to those seen elsewhere in the connective tissues. This area lay approximately in the centre of the epiphyseal zone, close to the costochondral junction. At its base there was a thin, transversely disposed layer of newly-formed bone which lacked a calcified cartilage ground substance, in contrast to bony trabeculae normally formed from the cartilage. The cancellous portion of the rib showed normal trabeculae. In the periosteum and perichondrium the collagen fibres appeared separated by large numbers of vacuolated, spindle-shaped cells having small eccentric nuclei. The periosteum was markedly thickened by the presence of the large cells and a conspicuous increase in the number of collagen fibres. The infiltrated periosteal tissue appeared to be engaged in the resorption and reconstruction of cortical bone which, along the surface of contact, showed many shallow and deep lacunae filled with the swollen cells. Occasionally, small fragments of newly-formed bone were completely embedded in the infiltrated periosteal tissue, and the osteocytes still resembled the swollen periosteal cells. It thus appears that bone may be formed directly within this tissue. The cortex itself was thick. The endosteum was thin and delicate, and there were very few osteoblasts and osteoclasts. The perichondrium also showed infiltration with large cells. These appeared to become incorporated in the cartilage, which was more cellular in its peripheral portions than in its depth. Also, the cartilage cells there appeared somewhat larger, but otherwise were not remarkable. One of the ribs showed a circular periosteal band interposed between the epiphyseal cartilage and the metaphysis, thus producing a marked constriction of the epiphyseal zone. The peripheral parts of the shaft were formed directly from the periosteal band instead of from cartilage. The same foam cells present elsewhere in the periosteum were scattered throughout the periosteal wedge, which otherwise was formed by dense collagen fibres. A sagittal section of the lumbar vertebra showed the structure of the spongiosa to be normal. The marrow was cellular and there were few fat cells. Proliferating cartilage was very scanty; columns of cartilage either were missing or very short. Thus, much of the cartilage which would normally proliferate had remained in the resting stage. Penetration of marrow cavities into the cartilage was very slight and occurred only where the short columns were present, in the centre of the epiphyseal line. The zone of provisional calcification was almost absent, and bone was laid down directly at the border of the epiphyseal cartilage, as a transverse layer. Accordingly ossification was mainly perichondral. The longitudinally directed trabeculae seen in normal bone were rare. The deep concave groove along the anterior border of the vertebra was filled with thick collagen fibres forming interlacing bundles. Adjacent to the cortex there was a layer of vacuolated cells which appeared to penetrate into the cortical bone, giving it an eroded border. Very few osteoclasts were seen, but the vacuolated

cells appeared to exert osteoclastic activity. Small fragments of bone were laid down in the infiltrated zone of the periosteum. Another lumbar vertebra showed a marked overgrowth of cartilage along its anterior border. Apparently this was the result of the poor endochondral bone formation from the epiphyseal cartilage. Thus the spongiosa of the vertebra became disproportionately small and its outline deformed. The anterior border of the vertebra became shorter than the posterior border and much more concave. The concavity was filled with periosteal and perichondral tissue consisting of interlacing fibres which blended with the overhanging cartilage, and of numerous vacuolated cells which appeared to become incorporated in the cartilage.

Similar changes were seen in various other bones. In three cases the skull did not show any separation into inner and outer tables. The bronchial cartilages were examined in four cases and the tracheal cartilages in three; changes similar to those seen in epiphyseal cartilages were the rule.

The Kidneys

Morbid Anatomy. The gross appearance was described in 14 cases. There was no abnormality of size. The capsule appeared thickened in only one case but stripped easily in all. Cortico-medullary differentiation was diminished in only one case. The cut surfaces of the cortex and medulla were noticed to be pale in three cases and the cortex in another two.

Histology. Microscopy was done in 14 cases. No abnormality was observed in five.

Two cases showed evidence of deposition of an abnormal substance. There was distension and vacuolation of certain cell elements in one of these cases, and a deposition of a non-staining granular material in certain cells and interstitial tissues in the other. In the third case of Lindsay *et al.* the interstitial tissue of the glomeruli showed a deposition of granular non-staining material and the collecting tubules showed epithelial swelling with similar material in the cells; the majority of the glomeruli had normal epithelium though several showed epithelial crescents; most of the convoluted tubules were normal. In the seventh case of the same authors there was moderate vacuolation of the cytoplasm of the cells of both limbs of Henle's loop, but the most striking vacuolation of the tubular cytoplasm was seen in the larger collecting tubules near the renal pelvis. The connective tissue adjacent to the renal pelvis showed swelling and vacuolation of the cells and similar changes were seen in the pelvic connective tissue. This case also showed increased epithelial cellularity of the glomeruli and diminished

vascularity of the glomerular capillaries, also thickening and fraying of the basement membranes of the tufts: two other cases showed similar features.

Three cases showed evidence of early glomerulonephritis with epithelial crescent formation. One of these was the third case of Lindsay *et al.* mentioned in connexion with the deposition of granular material in the interstitial tissues of the glomeruli.

Three cases had fatty degeneration of convoluted tubules and another cloudy swelling. In one case there were scattered vacuolated cells in the interstitial connective tissue.

The Gonads

Morbid Anatomy. These were described as normal in the six cases mentioned. Three were male and three female. Hydrocoele was present in no fewer than four of the male patients; it was bilateral in two.

Histology. Testes were examined in seven cases, but only one ovary was examined. In the testes enlargement and vesiculation were features in both parenchymal and interstitial cells in four cases; two showed these changes in interstitial cells only and one was said to have been normal. In one case characteristic connective tissue cells were described. In another the epididymis and vas deferens were normal. The ovary showed primordial and growing follicles. An occasional small group of foam cells was present in the stroma.

Urinary Tract and Prostate

Morbid Anatomy. No abnormalities were mentioned in the six cases reported.

Histology. The prostate was examined microscopically in two cases. It was normal in one but the acinar cells showed characteristic vacuolation in the other.

The Lymph Nodes

Morbid Anatomy. Enlargement of lymph nodes was mentioned in six cases. In five they were abdominal and in one tracheo-bronchial. In one case they were as much as 1½ cm. in diameter. They were soft and pale yellowish-pink. In another case they were strikingly yellow.

Histology. Nodes from nine cases were examined. In most cases the peripheral lymphoid follicles were small and indistinct, and the sinusoids were widened, the lining reticulo-endothelial cells being enlarged and vesicular and the lumina containing many similar cells.

Thymus Gland

Morbid Anatomy. This gland was described as enlarged in four of the 14 cases in which it was mentioned and normal in 10.

Histology. Microscopic examination was done in 14 cases. In several cases the lobules were described as large. Most showed a diminution in the number of lymphocytes and diffuse enlargement and vesiculation of reticular cells, particularly in the medullary zones.

The Pituitary Gland

Morbid Anatomy. This gland, described in 13 cases, was said to have been normal in seven cases and enlarged in six. The sella turcica was described in 14 cases and it was enlarged in all except one.

Histology. This was reported in 14 cases. The anterior lobe was examined in 10 cases and was normal in only two. In eight cases there was pronounced vacuolation of most of the cells, particularly the chromophobe cells. The nuclei of some of the heavily infiltrated chromophobes tended to be pyknotic. De Lange *et al.* (1944) observed some colloid-like masses and some diffuse increase of connective tissue. In our case most of the normal cells, which were scanty, were oxyphilic. Infiltration of the anterior pituitary cells appears to be a feature in a high proportion of cases, if not all.

The posterior lobe was described in eight cases. It was said to be normal in five cases and abnormal in three. The latter three were reported by Lindsay *et al.* (1948) and in them the glial cells showed abundant vacuolated cytoplasm with fragmentation of the glial fibres.

The middle lobe was mentioned in two cases and appeared to be normal in one and cystic in the other.

Pineal Gland

Morbid Anatomy. This gland was mentioned in three cases. It was said to have been normal in one, small in one, and absent in one.

Histology. Microscopy was done in two cases. It was normal in one but in the other many of the glial and pineal cells were enlarged and had increased amounts of clear, vesicular cytoplasm.

The Thyroid Gland

Morbid Anatomy. This gland was described as normal in eight cases and enlarged in one case.

Histology. Microscopy was done in 11 cases. The gland looked normal in six cases. In two the acini were enlarged and in two there were many

small follicles resembling the foetal type of gland. In another there was a considerable degree of parenchymatous atrophy with pronounced fibrosis. In the two cases with acinar enlargement most of the epithelial cells had abundant, clear vacuolated cytoplasm. It would thus appear that the thyroid gland usually does not show characteristic changes in gargoylism.

The Adrenal Glands

Morbid Anatomy. This was mentioned in nine cases. Eight appeared normal and the glands were small in one.

Histology. Microscopy was done in 13 cases. The appearance was normal in eight. The medullary cells showed characteristic swelling and vacuolation in four cases, while occasional foam cells were observed in the connective tissue in another case.

The Pancreas

Morbid Anatomy. No abnormality was noted in 10 cases mentioned.

Histology. Ten cases were examined. No characteristic infiltration of the cells was observed in any of them. Vacuolation of some connective tissue cells was mentioned in one case.

Parathyroid Glands

Histology. Microscopy was done in only one case and the appearance was normal.

The Lung and Pleura

Morbid Anatomy. Nothing significant was observed in any of the cases.

Histology. Microscopy was done in 14 cases. In nine there was evidence of cellular infiltration. In most of these the alveolar walls were greatly thickened and in some they showed fibrosis and infiltration with lymphocytes and plasma cells. Distension and vesiculation of the alveolar epithelium was a constant feature, also the presence of many of these altered cells in the alveolar spaces. Numerous vacuolated macrophages were also found in the alveoli. Characteristic cartilage changes were described in the bronchial cartilage in four cases. Other changes mentioned were characteristic infiltration in the tracheal epithelium and fibrous thickening in the trachea and bronchi.

The pleura was described in only a few cases. It usually showed fibrous thickening and some infiltration with lymphocytes and with macrophages showing the characteristic distension and vesiculation.

The Alimentary Tract

Morbid Anatomy. This was mentioned in 10 cases and all appeared normal.

Histology. Observations were recorded in seven cases. In four the ganglion cells in the intestine were swollen and vesiculated; in one of these the ganglion cells in the oesophagus and pylorus were similarly affected. In our case a few foam cells were seen among the lymphoid cells of a Peyer's patch. In one case the squamous epithelium of the oesophagus showed vesiculated cytoplasm; in another the outer squamous cells of the tongue had a large amount of clear vacuolated cytoplasm with indistinct cell outlines and invisible intercellular bridges. No abnormality was observed in one case.

The Gall Bladder and Bile Ducts

Morbid Anatomy. The gall bladder was mentioned in 11 cases and the main bile ducts in four. In one case the gall bladder mucosa showed some yellow stippling.

Histology. Microscopy of the gall bladder was done in two cases. It was normal in one case but in the other the connective tissue showed characteristic changes in the fibrocytes and collagen fibres.

Bone Marrow

Histology. This was described in four cases. It was normal in three cases, but infiltrated macrophages and connective tissue elements were observed in the marrow spaces of teeth, the mandible, and the petrous temporal bone in the very detailed seventh case of Lindsay *et al.* They did not observe these changes in the ribs or spine.

The Skin

Morbid Anatomy. This has not been described.

Histology. This was described in five cases. No abnormality was observed in two cases, but two showed enlargement and vacuolation of the epithelial cells of sweat glands and hair follicles. In one of these cases many of the squamous cells were vacuolated also.

Skeletal Muscle

Histology. Microscopy was done in only one case. Muscle fibres taken from several areas were normal, but the perivascular connective tissue showed characteristic changes.

The Leucocytes

Reilly (1935, 1941) described abnormal eosinophilic granules in the leucocytes in gargoylism. They

varied in size from fine, dust-like to large, coarse particles. Usually 60% to 90% of the neutrophils contained them, though the percentage of cells containing them varied widely. Lindsay *et al.* examined blood films in seven of their series and found these abnormal granules in the cytoplasm of the neutrophils in four cases. The granules were present in smaller numbers in the monocytes but were not seen in the lymphocytes. They were observed in marrow cells in only one case. Appropriate staining methods suggested that the granules consisted of glycogen.

THE CELLULAR LESION

The review of the pathology of the disease has shown how almost all the tissues of the body may be affected. Certain tissues, such as the brain, liver and spleen, are invariably involved in typical cases, whereas other tissues such as the lungs, pancreas and suprarenal glands frequently show no abnormality. The changes are essentially similar in all affected tissues, and have features which suggest a disease of abnormal storage.

The characteristic cellular lesion is cytoplasmic swelling which usually causes enlargement of the cell. The cytoplasm may be clear, vacuolated or granular. Most types of cell are involved in the abnormal process: epithelial cells such as those of the liver, anterior lobe of the pituitary gland, epidermis and skin glands; reticulo-endothelial cells in many tissues, particularly in the lymph nodes and spleen, and nerve cells in all parts of the central nervous system. The pathological changes were as pronounced in the mesodermal connective tissues as anywhere. Chondrocytes, osteocytes and fibrocytes all showed characteristic enlargement and vacuolation. Lindsay *et al.* demonstrated the universality and characteristic appearance of the connective tissue changes very clearly in their Case VII which had a much more detailed histological examination done than any other reported case of the disease. They believe that the widespread connective tissue involvement is responsible for the malformation of the skeleton and soft tissues and for the diminished growth. Abnormal osteoblastic activity, particularly in the epiphyses, was undoubtedly the main cause of retarded and aberrant skeletal growth. The same authors also believe that the abnormal microscopic appearance of the intercellular matrix in many situations is a logical accompaniment of the cytological changes, since the matrix supporting these cells is derived from their cytoplasm. The intercellular substance had usually lost its normal fibrillary appearance and the collagenous fibres appeared swollen and

imparted an abnormally homogeneous appearance to it.

THE ABNORMAL DEPOSIT

The nature of the abnormal deposit in gargoylism has been the subject of much speculation, also of detailed investigation in several of the reported cases. Ellis, Sheldon and Capon (1936), in reviewing the features of the 17 cases reported up to that time, had little pathological evidence on which to speculate, only the incomplete report by Tuthill on Hurler's (1919) case, but, on the basis of the analogy with established diseases of lipid storage, they suggested that gargoylism might prove to belong to that group. Since that time gargoylism has generally been classed as a lipoidosis though proof has never been forthcoming. Washington (1948) coined the term 'lipochoondrodystrophy' which is often used in connexion with the disease. Within the last few years several authors have expressed doubt about the disease being a lipoidosis because of the persistent failure to demonstrate the lipid nature of the deposits by staining methods, or by chemical analysis of heavily infiltrated tissues. It has been suggested by De Lange *et al.* (1944) and Strauss (1948) that the deposit might be a glycogen compound, and Lindsay *et al.* (1948) claim to have demonstrated by a histochemical method that the substance is glycogen or a glycogen compound.

An attempt was made to identify the abnormal deposit in three cases before the publication of the series of Lindsay *et al.* Histochemical examination of the deposit was carried out in three cases: the brain was examined in the case of Tuthill and in the first case of Ashby *et al.*, and various tissues in the case of Kressler and Aegerter. Chemical analysis of brain tissue was performed in one, the first case of Ashby *et al.* Investigation of the deposit with a variety of methods of fixation and of staining methods did not yield consistent results or enable identification of the substance to be made in any of the three cases studied. The deposit was, for instance, stained by Scharlach red in the case of Tuthill and the first case of Ashby *et al.*, but not in the case of Kressler and Aegerter. Moreover, in the case of Ashby *et al.*, in which the deposit was studied more thoroughly than in the other cases, the intracellular and extracellular staining reactions were dissimilar, that for Scharlach red, for instance, being intracellular positive and extracellular negative.

Biochemical analysis of the brain tissues in the first case of Ashby *et al.* also failed to identify the abnormal deposit. They compared the results in their case with the results of analysis in three

controls. The total lipoids of the white and grey matter were slightly subnormal, but the cerebroside content was very low in the cortex, being only about half that of the controls. There was no significant reduction of cerebrosides in the white matter. By a process of exclusion with the aid of solubility and melting-point tests and staining reactions, they came to the conclusion that the extracellular lipid in the perivascular region of the brain in their case was composed mostly of cerebrosides, namely phrenosin or kersin or a mixture of both. The concentration of cerebrosides in the perivascular spaces appeared to these workers to be in process of removal from the grey matter, which, as stated, showed a reduction of cerebroside to half the normal amount. Such a process is a result of cerebral degenerative disease and has no direct bearing on the nature of the intracellular deposit in the nerve cells and the parenchymal cells of other organs.

Lindsay *et al.*, in several of their cases, demonstrated small amounts of lipid in many of the swollen cells with various histological stains, but the lipid which these stains revealed did not account for the tremendous increase in the volume of cytoplasm and often was not greater than the amount normally found. They felt, therefore, that the possibility of the stored substance being a lipid seemed remote. The intracellular substance could not be stained consistently with a variety of the common protein stains, and was presumed, therefore, not to be purely protein in nature. They failed to demonstrate glycogen in significantly large amounts in tissue fixed in alcohol from two of their cases. The interval between death and necropsy in their cases was long and they felt that post-mortem glycolysis of fairly large quantities of glycogen had probably occurred before fixation of the tissues. This hypothesis led these workers to investigate fresh biopsy specimens for glycogen and they claimed to have demonstrated abundant intracellular glycogen deposits in the swollen liver, costal cartilage and fibial epiphyseal cells which they examined; it was present in quantities sufficient to account for the cellular enlargement. The specimens were fixed in a solution of diosane, trinitrophenol, formaldehyde and acetic acid and stained by the Feulgen-Bauer method. With similarly fixed hepatic tissue from a case of von Gierke's disease as a control, incubation of hepatic tissue with saliva caused a loss of the granular material which had stained with the Feulgen-Bauer method. They regarded this evidence as proof that the carbohydrate stored in the hepatic cells in gargoylism is a polysaccharide, presumably glycogen, rather than a less complex carbohydrate.

These workers consider that the glycogen may be combined in some instances with a protein as a glycoprotein or mucoprotein. They believe that similar histochemical examination of the other tissues affected in gargoylism will reveal intracellular storage of glycogen or a glycoprotein wherever they are found.

De Lange *et al.* (1944) described an abnormal galactose tolerance test in their case, the blood level being unduly elevated and sustained. Lindsay *et al.* did carbohydrate tolerance tests in six of their patients; galactose tolerance tests were done in three and an abnormal result was obtained in one. In this case the blood galactose level remained elevated for an unduly prolonged period, a result which could be explained by structural alteration of the hepatic cells. Blood glucose curves after administration of insulin and adrenalin were normal in this case. These authorities believe that the large deposits of carbohydrate in gargoylism may be metabolically inactive and may not be involved in the turnover of an otherwise normal carbohydrate metabolism. They think that its possible combination with protein as a glycoprotein supports this thesis.

The quantitative differential lipid analyses of the liver and spleen done by us in Case 1 (Tables 1 and 2) showed values within the normal range. This demonstrates the absence of an increase of any lipid fraction in a typical case of gargoylism. The disease can therefore no longer be considered as a lipid storage disease resulting from an abnormal intracellular lipid metabolism. There is no doubt that staining reactions may give a very misleading impression of the amount of a tissue metabolite present in organs; only quantitative chemical methods give a reliable indication of an increase or decrease. Unfortunately, Lindsay *et al.*, who claimed to have demonstrated the deposit in gargoylism to be a complex polysaccharide, based their conclusions on qualitative staining methods only. Without the support of quantitative chemical analyses of the stained substances in the affected organs, and in the corresponding organs of controls, their interesting hypothesis remains unproven. There was no evidence of abnormal lipid or glycogen content in the fresh biopsy specimen of liver in our Case 3 in which there was typical vacuolation of the liver cells (Figs. 27 and 28); the specimen was examined both by standard staining methods for lipid and glycogen and by quantitative chemical analysis.

There is no satisfactory evidence that the deposit in gargoylism is either a lipid or pure glycogen. It should be possible to demonstrate by bio-

chemical methods whether it is, or is not, a glycogen compound. No opportunity of doing quantitative estimations of glycogen compounds, necessarily by indirect means, on fresh tissues obtained from typical cases of gargoylism should be missed. In this way it should be possible to prove or disprove the latest theory of the pathogenesis of this peculiar, inherited, metabolic disease.

SUMMARY

Three cases of gargoylism are recorded.

An extensive study of the pathology and biochemistry in one case was made. Biopsy specimens in the other two cases were examined histologically, and in one of these also biochemically.

The gross vascular and meningeal pathology were notable features in the child who came to necropsy. These features had not been described before, but have since been observed by others.

The literature relating to the pathology and biochemistry is reviewed in detail.

The pathogenesis of the disease remains unproven. The intracellular deposit is neither a lipid nor glycogen. Further biochemical studies should demonstrate whether the substance is a glycoprotein or mucoprotein as has been suggested.

We are grateful to Dr. D. N. Nicholson for permission to publish Case 3, and to Dr. W. Blackwood for his neuropathological examination and report in Case 1.

REFERENCES

- Ashby, W. R., Stewart, R. M. and Watkin, J. H. (1937). *Brain*, **60**, 149.
- Berliner, M. L. (1939). *Arch. Ophthalmol., Chicago*, **22**, 97.
- Cordes, F. C. and Hogan, M. J. (1942). *Ibid., Chicago*, **27**, 637.
- Lange, C. De (1942). *Psychiat. neurol. Bl., Amst.*, **46**, 2.
- , Gerlings, P. G., De Kleyn, A. and Lettinga, T. W. (1944). *Acta paediatr., Uppsala*, **31**, 398.
- Debré, R., Marie, J. and Thieffry, S. (1946). *Sem. Hôp., Paris*, **22**, 309.
- Ellis, R. W. B. (1937). 'British Encyclopaedia of Medical Practice.' vol. 5, p. 496.
- , Sheldon, W. and Capon, N. B. (1936). *Quart. J. Med.*, **29**, (n.s. 5) 119.
- Green, M. A. (1948). *J. Neuropath.*, **7**, 399.
- Höra, I. (1939). *Virchows Arch.*, **305**, 298.
- Jervis, G. A. (1950). *Arch. Neurol. Psychiat., Chicago*, **63**, 681.
- Kny, W. (1942). *Z. Kinderheilk.*, **63**, 366.
- Kressler, R. J. and Aegerter, E. E. (1938). *J. Pediatr.*, **12**, 579.
- Lindsay, S. (1950). *Brit. Heart J.*, **12**, 17.
- , Reilly, W. A., Gotham, T. J. and Skahen, R. (1948). *Amer. J. Dis. Child.*, **76**, 239.
- MacIntyre, D. S., Pedersen, S. and Maddock, W. G. (1941). *Proc. Soc. exp. Biol., N.Y.*, **47**, 354.
- Magee, K. R. (1950). *Arch. Neurol. Psychiat., Chicago*, **63**, 282.
- Njå, A. (1945). *Acta paediatr., Uppsala*, **33**, 267.
- Reilly, W. A. (1935). *Endocrinology*, **19**, 639.
- (1941). *Amer. J. Dis. Child.*, **62**, 489.
- Rochat, G. F. (1942). *Ophthalmologica*, **103**, 253.
- Schmidt, M. B. (1942). *Zbl. allg. Path. path. Anat.*, **79**, 113.
- Stoekel, K. H. (1941). *Mscr. Kinderheilk.*, **86**, 348.
- Straus, R., Merliss, R. and Reiser, R. (1947). *Amer. J. clin. Path.*, **17**, 671.
- Strauss, L. (1948). *Amer. J. Path.*, **24**, 855.
- Tuthill, C. R. (1934). *Arch. Neurol. Psychiat., Chicago*, **32**, 198.
- Washington, J. A. (1948). Brennemann's 'Practice of Pediatrics', ed. McQuarrie, I. J., vol. 4, Ch. 30. Hagerstown, Maryland.
- Wolff, D. (1942). *Laryngoscope, St. Louis*, **52**, 218.
- Zeeman, W. P. C. (1942). *Acta Ophthalmol., Kbh.*, **20**, 40.