

Rat ultraviolet ray B photodermatitis: an experimental model of psoriasis vulgaris

H. NAKAGUMA, T. KAMBARA AND T. YAMAMOTO

*Division of Molecular Pathology, Department of Neuroscience and Immunology,
Kumamoto University Graduate School of Medical Sciences, Kumamoto, Japan*

Received for publication 18 January 1994

Accepted for publication 7 November 1994

Summary. Ultraviolet ray B (UV-B) induced dermatitis in the rat may be a model for human psoriasis vulgaris. Detailed studies of this model are reported. Rat skin responded to UV-B irradiation quite differently from human, guinea-pig, or mouse skin. Rat UV-B dermatitis was characterized by a sharply demarcated brownish-red lesion with scale formation lasting for 10 days. Histologically, microvascular dilatation, intraepidermal accumulation of polymorphonuclear leucocytes with microabscess, mononuclear cell infiltration at the papillary dermis and hyperproliferation of epidermal cells were observed. These features were similar to those of clinical psoriasis vulgaris in man. Leucocyte suppression, induced by systemic ferritin administration to the irradiated rats, resulted in loss of the epidermal hyperproliferation and inhibition of the tissue leucocytosis. This leucocyte suppression remodelled the picture of the rat UV-B dermatitis into that seen in other mammalian species, where microvascular dilatation and degeneration of keratinocytes (so-called sunburn cells) are characteristic. The irradiated epidermis of the rats treated with ferritin possessed an *in vitro* PMN chemotactic property.

Rat UV-B dermatitis seems to be a useful model to investigate aetiopathogenic mechanisms in psoriasis vulgaris. However, the former heals after injury and does not relapse as does psoriasis.

Keywords: UV-B dermatitis, rats, psoriasis vulgaris, intraepidermal microabscess, epidermal hyperproliferation, leucocyte chemotactic factor

Exposure of the skin to ultraviolet ray B (UV-B) causes an inflammatory reaction (sunburn), characterized by severe redness and swelling macroscopically, and by microvascular dilatation and oedema histologically, in human as well as in many other mammalian species. We have recently noticed that rat skin responds to the

same injury in a different manner with marked leucocyte infiltration and occasional intraepidermal microabscess formation, containing predominantly polymorphonuclear leucocytes (PMN). During the process of rat UV-B dermatitis (but not of the guinea-pig or the mouse), a remarkable elevation of leukotriene B₄ (LTB₄) content of the skin was also observed (Nakaguma & Takahashi 1990). Interestingly, these characteristics of rat UV-B dermatitis resemble those of psoriasis vulgaris in man.

Correspondence: Dr T. Yamamoto, Department of Molecular Pathology, Kumamoto University Graduate School of Medical Science, Kumamoto 860, Japan.

Psoriasis vulgaris is a chronic relapsing and remitting dermatitis characterized by enormous proliferation of keratinocytes. However, in an early phase prior to the epidermal proliferation, a variety of inflammatory histological changes are seen. Although psoriasis vulgaris is one of the most common skin diseases in Caucasians with a prevalence of 1 or 2% (McKee 1992), its pathogenesis is still obscure.

Since there is no good animal model of psoriasis, we thought that rat UV-B dermatitis was worth more detailed study. We have focused our attention on intra-epidermal microabscess formation, dermal mononuclear cell infiltration and hyperproliferation of epidermal cells in rat UV-B dermatitis.

Materials and methods

Animals

Male Wistar, F-344, Sprague-Dawley and Dark Agouti (DA) rats weighing around 200 g, Hartly male guinea-pigs weighing around 300 g and ddY male mice weighing around 30 g were used.

All experimental procedures in the animals were conducted with the prior approval of the Animal Care and Use Committee of Kumamoto University School of Medicine. Guidelines set by the National Institute of Health and Public Health Service Policy on the use and care of laboratory animals were followed at all times.

Reagents

3-Amino-9-ethylcarbazole was obtained from Aldrich (Milwaukee, WI, USA); 5-bromo-2-deoxyuridine (BrdU), pepsin, fast red, and ferritin were obtained from Sigma (St Louis, MO, USA). The optimum cutting temperature compound was obtained from Miles Diagnostic Division (McLean, VA, USA). A peroxidase-conjugated anti-mouse IgG sheep IgG antibody was obtained from Amersham International (Buckinghamshire, UK). An anti-BrdU mouse monoclonal antibody, and an alkaline phosphatase-conjugated anti-mouse IgG sheep IgG antibody, were obtained from Dakopatts A/S (Copenhagen, Denmark). Lympholyte-Rat separating medium was purchased from Cedarlane Laboratories Limited (Ontario, Canada). Other chemicals were obtained from Wako Pure Chemicals (Osaka, Japan). Zymosan activated rat serum (ZAS) was prepared as described previously (Matsubara *et al.* 1991).

UV-B irradiation

UV-B irradiation was performed as described previously

(Nakaguma & Takahashi 1990). Briefly, hair on the dorsal skin of the experimental animals was clipped and carefully shaved with a new razor blade. An area ($1.5 \times 2.5 \text{ cm}^2$) on one side of the flank was irradiated for 15 min (1.5 J/cm^2) at a vertical distance of 20 cm from the five lamps (Toshiba Torex FL-40S-E-30, 20 W).

In a time course study, rats were divided into three groups, each of 5 rats. In the first group, one flank was irradiated one day before the biopsy, and the other side was irradiated two days before the biopsy. The rats of the second group were similarly irradiated 3 and 5 days before the biopsy, and the rats of the third group were irradiated 7 and 10 days before.

Ferritin treatment of rat

Immediately after the UV-B irradiation, a sterile ferritin solution (100 mg/ml in saline) was administered intraperitoneally to rats at a dose of 200 mg/kg body weight. Otherwise, these rats were treated in the same way as the untreated rats.

Histological examination

The irradiated rats were killed by decapitation under ether anaesthesia. Skin biopsies were taken immediately, fixed in 10% formalin and embedded in paraffin. The tissue sections were $4 \mu\text{m}$ thick and were stained with haematoxylin and eosin.

DNA labelling was performed according to the method of Morimoto *et al.* (1991). In brief, 20 mg/kg of BrdU was administered intraperitoneally 8 hours before decapitation. Biopsy specimens were embedded in optimum cutting temperature compound and frozen tissue sections ($8 \mu\text{m}$) were prepared with a cryostat (Tissue-Tek, Miles). The sections were then fixed in acetone for 10 min, 4% paraformaldehyde containing 1% CaCl_2 (pH 7.0) for 10 min and 1% glutaraldehyde for 5 min, in that order. After fixation, sections were digested with 0.006% pepsin in 10 mM HCl for 10 min at 37°C , and incubated in 4 M HCl for 30 min at ambient temperature to denature DNA. They were then incubated with anti-BrdU mouse monoclonal antibody and then with alkaline phosphatase-conjugated anti-mouse IgG sheep IgG antibody. Antibody-binding sites were visualized with naphthol and fast red at pH 9 in the dark. The numbers of labelled as well as unlabelled cells at the epidermal basal layer or outer root sheath cell layers of the hair follicles were counted in five high-power fields to a total of at least 100 cells. The intensity of BrdU incorporation

was demonstrated by a labelling index as the following formula:

$$\text{labelling index (\%)} = \frac{\text{number of labelled cells}}{\text{total cell number counted}} \times 100$$

Sampling of epidermis and preparation of epidermal extract

The epidermis of irradiated lesions or of the control area of rats treated with ferritin was removed with a piece of adhesive cellophane tape ($1.5 \times 1.5 \text{ cm}^2$) under ether anaesthesia. The tape bearing epidermis was cut with scissors into pieces $3 \times 3 \text{ mm}^2$. In one group of experiments, three pieces of the specimens were examined directly in the polarization assay as described below. In the other group, ten pieces of the specimens were extracted by phosphate-buffered saline ($750 \mu\text{l}$ PBS) for 15 min (on ice with occasional shaking) and the extract was examined in the polarization assay.

Preparation of circulating PMN

Blood was obtained from healthy Wistar rats by cardiac puncture with 5 U/ml heparin and 10 mM EDTA (final concentrations). The blood (5 ml) was layered on 5 ml of the separating medium (Lympholyte-Rat) and centrifuged at 1500 r.p.m. for 25 min at ambient temperature. The leucocyte layer was washed three times with Hanks' balanced salt solution (HBSS, pH 7.2) by centrifuging at 1050 r.p.m. for 5 min to remove contaminated platelets. After washing, the cells were suspended in HBSS containing 0.5% BSA. The proportion of PMN in the cell preparations was usually 15%; the rest were principally lymphocytes.

Morphological polarization assay in chemotaxis

The polarization assay of PMN was performed according to the method of Cianociolo and Snyderman (1981) with modifications. In brief, $300 \mu\text{l}$ of cell suspension (1×10^6 cells/ml) was incubated with 3 pieces of an epidermal tissue specimen on the cellophane tape, or $150 \mu\text{l}$ of the cell suspension was incubated with $150 \mu\text{l}$ of the epidermal extract (which had been prepared as described above) for 10 min at 37°C in a polypropylene tube. After the incubation, 1 ml of ice-cold paraformaldehyde (8%) in 100 mM phosphate buffer (pH 7.2) was added to each tube to fix the cells. After fixing for 60 min at 4°C , leucocytes were stained with gentian violet dye for the counting chamber. An aliquot was taken onto a glass slide and the numbers of PMN exhibiting either

polarized or non-polarized morphology were counted (at least 200 total cells observed at random) by microscopy (Olympus, BH). Polarized cells can be identified by their triangular shape characterized by a flattened lamellipod at one side (the leading edge) and pointed uropod at the opposite side, so called 'head and tail' (Smith *et al.* 1979). The polarization activity of the samples was expressed as the percentage of PMN that exhibited the polarized morphology. Serially diluted ZAS (from 10 to 0.01%) and PBS were used respectively as positive and negative controls (Matsubara *et al.* 1991; Kukita *et al.* 1987).

Results

Macroscopic observation

In the Wistar rat, biphasic erythema was observed. Immediately after irradiation, initial faint erythema appeared, disappearing within 30 min. The second phase of erythema started 6 h after the irradiation and gradually increased, peaking between 24 and 48 h. The colour was brownish-red, and the reaction was confined to the exposed area with a sharp boundary. By 48–72 h after irradiation, dark-brown scale was formed on the erythematous lesion. Pieces of the scale were relatively thick. The scale separated and the erythema decreased daily. The skin sites returned to normal about 10 days after irradiation. No spontaneous haemorrhage was observed.

Similar reaction patterns to UV-B were observed in all other strains of rat examined (such as F344, Sprague-Dawley and DA), although the reactions of these were weak and delayed in comparison with the Wistar rat.

In contrast, in the guinea-pig and the mouse, only erythema, disappearing after a few days post-irradiation, was observed.

Histological observations

The histological changes of UV-B dermatitis in the Wistar rat are shown in the following figures. Two days post-irradiation, intraepidermal infiltration of PMN forming spongiform pustulosis was observed; the papillary dermis was oedematous, and mononuclear cell infiltration was obvious (Figure 1a). Microvascular dilatation was also observed (not clear in Figure 1a). Three days after irradiation, the intraepidermal micropustules developed into microabscesses in the stratum corneum (Figure 1b). By 5 days post-irradiation, thickening of epidermis (composed of about 6 squamous layers) became obvious. Microabscess in the corneum still

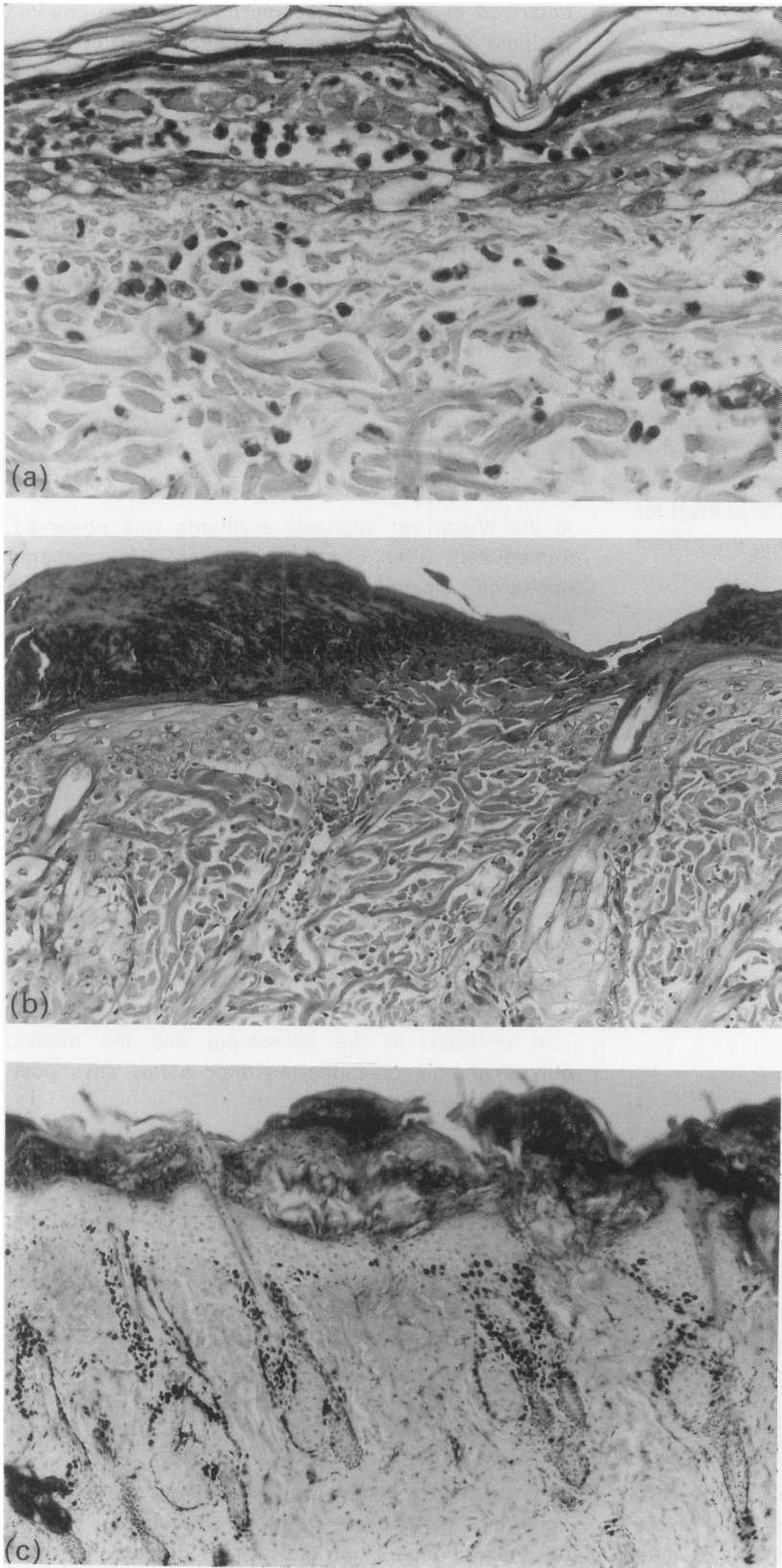


Figure 1. Photomicrographs of Wistar rat skin a, 2 days; b, 3 days and c, 5 days after ultraviolet B ray (UV-B) irradiation. After shaving skin hair, UV-B irradiation (1.5 J, 15 min) was given on one side of the flank of rats. a, b, The skin paraffin sections were stained with haematoxylin and eosin ($\times 300$ and $\times 100$, respectively). c, BrdU incorporated cells in the frozen skin section were visualized using anti-BrdU mouse monoclonal antibody, phosphatase-conjugated anti-mouse IgG sheep IgG antibody, and naphthol fast red, in that order, and weakly counterstained with haematoxylin. $\times 50$.

remained. In addition to the histological changes, strong DNA labelling (BrdU incorporation) was observed in the upper portions of the outer root sheath of hair follicles (Figure 1c). Detachment of the stratum corneum and the microabscess started around 7 days. Consequently, the number of epidermal layers was reduced to 2 or 3 (not shown), and the histological pattern returned to normal about 10 days after irradiation.

The same pattern of histological changes was observed in all the other strains of rats examined.

In the guinea-pig and mouse, only microvascular dilatation was observed, consistent with the macroscopic picture.

Therefore, only Wistar rats were used in the following experiments.

Proliferation of epidermal cells

Hyperplastic change of the epidermal layers of the lesions of UV-B dermatitis was obvious as described above. To analyse it quantitatively, the number of keratinocyte layers was initially counted in the epidermis and in the upper portion of outer root sheath of hair follicles. Their chronological changes are shown in Figure 2. Under normal conditions there are usually two keratinocyte layers, including the basal layer, in the skin of the rat flank. An increase in the number of keratinocyte layers apparently started at 2 days and rose to a maximum of 5 or 6 layers between 5 and 7 days after irradiation. The number of layers returned to normal 10 or more days after irradiation. At unexposed areas, a slight increase in the number of layers (in both the epidermis and the outer root sheath of hair follicles) was observed on day 2. This could be an effect of the hair shaving. The differences in the thickness of the exposed and unexposed skin were statistically significant ($P < 0.02$) at 5, 7, and 10 days after the irradiation.

To evaluate the intensity of the epidermal proliferation further and to identify the proliferating site, the irradiated lesions were studied quantitatively with regard to intra-nuclear BrdU incorporation. The time course of the BrdU incorporation by keratinocytes in the epidermis and in the outer root sheath of hair follicles is shown in Figure 3. Outer root sheath cells at the upper portion of hair follicles from exposed skin specimens showed high DNA labelling indices, up to 50%, from 2 to 7 days after irradiation. This increase returned to normal 10 days after irradiation. The indices of specimens from unexposed skin sites were elevated on day 2; again, this is probably an effect of the hair shaving. The differences in the DNA labelling indices of the unexposed and exposed

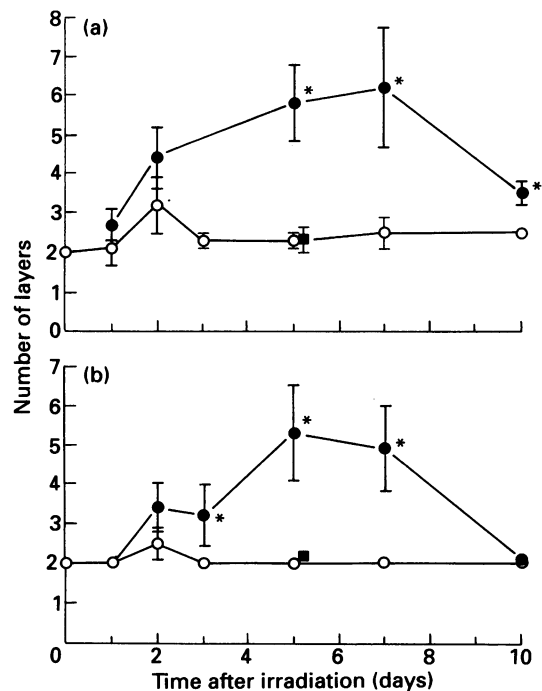


Figure 2. Chronological changes of thickness of keratinocyte layers at a, the epidermis and b, hair follicles. Frozen skin sections were stained with haematoxylin and eosin, and the numbers of the keratinocyte layers including the basal layer were counted by direct microscopy. ●, ■, Irradiated lesions; ○, unirradiator sites of ●, ○, normal or ■, the ferritin-treated rats. Ferritin was administered at a dose of 200 mg/kg body weight i.p. immediately after irradiation. Values are shown as mean \pm s.e. ($n = 5$ at each time point). *Statistical difference with $P < 0.02$ (t -test) compared with the unirradiated sites at corresponding time point.

skin sites from 5 to 7 days after the irradiation were statistically significant ($P < 0.02$) (Figure 3b). In contrast, the DNA labelling index of the epidermal basal layer was not significantly different between the exposed and unexposed sites by 5 days after irradiation. Although the indices were significantly higher at the exposed sites on days 7 and 10, the values themselves were not very high (Figure 3a). These results indicate that the major proliferation sites of epidermal cells in the response to UV-B was the upper portion of the epidermal sheath of hair follicles; the basal cells of this portion seemed to be the proliferating elements.

The observations described above led to the conclusion that rat UV-B dermatitis is characterized by intraepidermal PMN infiltration and microabscess formation, epidermal cell proliferation, and mononuclear

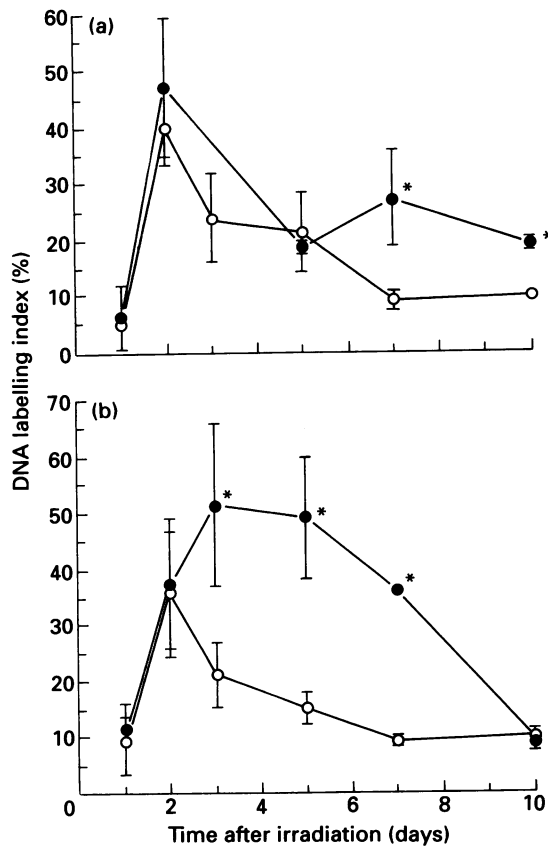


Figure 3. Chronological changes of DNA labelling indices at a, epidermal basal layer and b, epidermal layers of hair follicles. BrdU incorporated cells in the frozen skin sections ($8\ \mu\text{m}$ thick) were visualized as Figure 1c. Thereafter, the DNA labelling indices were obtained as described in Materials and methods. ●, Irradiated lesions; ○, unirradiated sites. Values are mean \pm s.e. ($n = 5$ at each time point). *Statistical difference with $P < 0.02$ (t -test) compared with the unirradiated sites at corresponding time point.

cell infiltration of the papillary dermis along with vascular dilatation and oedema.

Effect of ferritin treatment on UV-B-induced inflammatory reaction

To elucidate the role of the inflammatory cell infiltrate in this dermatitis, rats were irradiated with UV-B in the same manner but treated with ferritin to suppress leucocytes.

Whereas the inhibitory effect of ferritin on granulocyte-macrophage progenitor cells has been reported

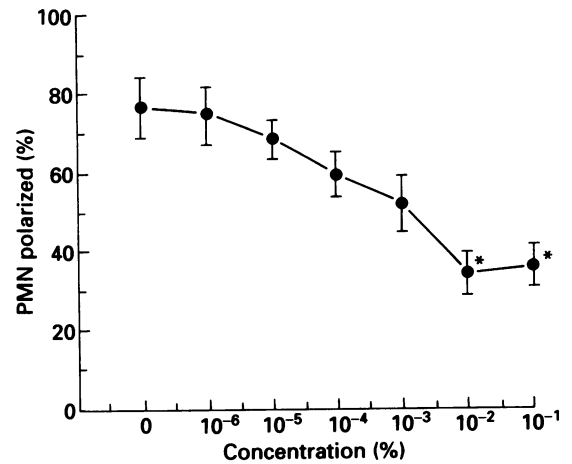


Figure 4. Effect of ferritin on polarization response of rat peripheral blood polymorphonuclear leucocytes (PMN) attracted by zymosan activated serum (ZAS) *in vitro*. PMN were incubated with 1% (v/v) ZAS for 10 min at 37°C in the presence of ferritin at various concentrations which are indicated on the horizontal axis, and the proportion of PMN with the polarized configuration (vertical axis) were examined as described in Materials and methods. Data are shown as mean \pm s.e. of the three experiments. *Statistical difference with $P < 0.01$ (t -test) compared with the absence of ferritin. Negative control value with Hanks' balanced salt solution (HBSS) instead of ZAS in the absence of ferritin as $8.6 \pm 3.0\%$.

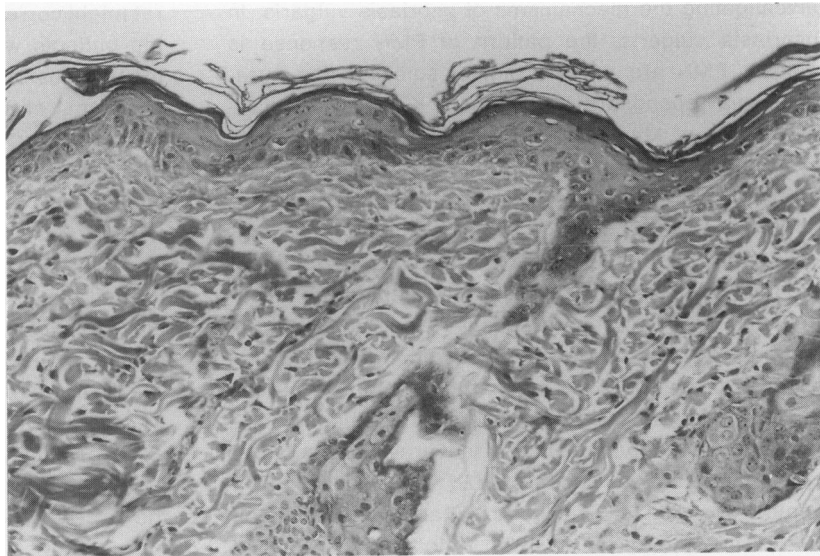
(Dezza *et al.* 1988; Williams *et al.* 1988), an effect on circulating leucocytes has not been described. Prior to *in vivo* experiments, the suppressive effect of ferritin on PMN chemotaxis was examined *in vitro*. As shown in Figure 4, in the presence of ferritin at concentrations of $100\ \mu\text{g}/\text{ml}$ or more, the polarization response of rat circulating PMN to ZAS was significantly reduced.

Consistently, ferritin treatment of rats *in vivo* almost completely blocked intraepidermal PMN infiltration and mononuclear cell infiltration of the papillary dermis in UV-B dermatitis (Figure 5). Interestingly, ferritin treatment also suppressed epidermal cell proliferation (Figure 2). Because of the absence of these epidermal changes, degenerated keratinocytes (the so-called sunburn cells) became more obvious (Figure 5). In addition, the scale formation disappeared with ferritin treatment, while erythema was not affected macroscopically.

Appearance of chemotactic property to PMN in irradiated epidermis

To investigate the mechanism of induction of intraepidermal PMN infiltration, the ability of irradiated

Figure 5. Photomicrograph of the effects of ferritin on the UV-B dermatitis. Immediately after irradiation, ferritin was administered into the rats at the dose of 200 mg/kg body weight i.p. The skin paraffin tissue section of an irradiated lesion was stained 2 days after irradiation with haematoxylin and eosin. $\times 100$.



epidermis to attract PMN chemotaxis was examined by the morphological polarization assay. To rule out secondary products derived from the accumulated PMN (which occasionally synthesize chemoattractants themselves), the animals used in this experiment were treated with ferritin as described above.

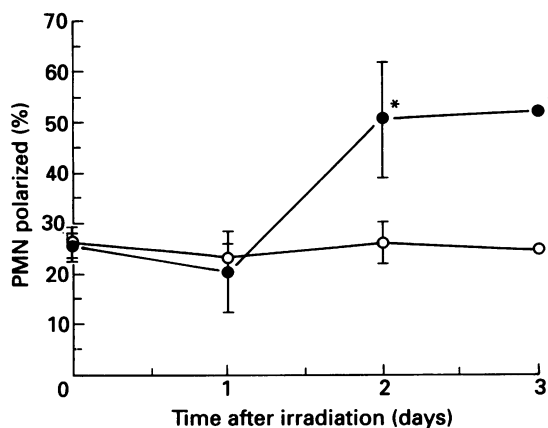


Figure 6. Chronological changes of PMN polarization promoting activity of irradiated epidermis obtained from ferritin treated rats. PMN were incubated with three pieces of epidermis biopsied with adhesive cellophane tape ($3 \times 3 \text{ mm}^2$) for 10 min and the polarization response was measured. The values are shown as mean \pm s.e. at ●, the irradiated sites ($n = 5$) and ○, the unirradiated sites ($n = 5$). *Statistical difference with $P < 0.02$ compared with the unirradiated site. One per cent (v/v) ZAS and HBSS were used as positive and negative controls with polarization values of 78 and 23%, respectively.

As shown in Figure 6, the PMN polarization activity of epidermis was significantly elevated ($P < 0.02$) 2 and 3 days after irradiation. Plain adhesive cellophane tape without epidermis as a control did not possess polarization activity. When pieces of tape containing epidermis from 2 days post irradiation were extracted with PBS (as described), the PMN polarization activity moved to the liquid phase. The polarization capacity of the extracts was equivalent to that of 0.1% (v/v) of ZAS. Therefore, the chemotactic factor(s) in the irradiated epidermis were thought to be extractable by the salt solution.

Discussion

As demonstrated herein, rat UV-B dermatitis is characterized macroscopically by sharply demarcated brownish-red lesion with scale formation and histologically by microvascular dilatation and oedema in the dermis, intraepidermal PMN infiltration with microabscess formation, mononuclear cell infiltration of the papillary dermis and hyperproliferation of epidermal cells. These characteristics, together with the elevation of intra-dermal LTB_4 as described previously (Nakaguma & Takahashi 1990), suggest that rat UV-B dermatitis resembles psoriasis vulgaris macroscopically, histologically and biochemically. However, the former heals approximately 10 days after the injury and does not relapse as does psoriasis.

The aetiology of psoriasis vulgaris is still obscure and is not simply a consequence of UV irradiation so the rat UV-B dermatitis is not a perfect model for the aetiology of the human disease. However, it may be useful for

investigating the mechanisms of psoriasis vulgaris. In psoriasis vulgaris, the pattern of PMN response is unique. PMN are present almost solely in the intraepidermal spongiform pustules of Kogoj and microabscesses of Munro. It is speculated that there is a cyclic stage within a narrow range of time within which PMN extravasate in the upper dermis, migrate into the epidermis, and accumulate beneath or within the parakeratotic layers; this process seems to be so rapid that the intermediate steps before the intraepidermal accumulation of PMN are not easily observed by usual histological means (Pinkus & Mehregan 1966). Therefore, the presence of strong chemoattractant(s) to PMN in the parakeratotic layers of psoriasis has been postulated. Indeed, the presence of several kinds of PMN chemotactic factors such as LTB_4 (Fogh *et al.* 1989), complement C5a (or C5a des Arg) (Takamatsu & Tagami 1993; Christopheres *et al.* 1989; Kato *et al.* 1989), and interleukin-8 (Takamatsu & Tagami 1993; Christopheres *et al.* 1989; Kato *et al.* 1989) have been reported in extract from psoriasis vulgaris. In the present study of rat UV-B dermatitis, the chronological localization and apparent behaviours of PMN were quite similar to those described in psoriasis. In addition, the appearance of a property chemotactic to PMN has been demonstrated at a period (2–3 days after irradiation) just prior to the appearance of intraepidermal spongiform pustules and microabscesses. This chemotactic property must be derived from the injured epidermis, since it was demonstrated after the suppression of leucocyte infiltration by ferritin treatment. The epidermis-derived chemotactic molecule(s), extractable with PBS, has not yet been identified. It is too early to postulate similarities between these molecules from the rat epidermis and those chemoattractants from psoriasis scale, because such scale always contains accumulated PMN which have the ability to produce many recognized PMN chemotactic factors (Ford-Hutchinson *et al.* 1980; Bazzoni *et al.* 1991; Strieter *et al.* 1990). The epidermal property that we have demonstrated might be the initiation factor(s) of the intraepidermal accumulation of PMN.

Other important features of psoriasis are the mononuclear cell infiltration at the papillary dermis and the epidermal hyperproliferation. Whereas rat UV-B dermatitis possesses both of these features, one might claim that the latter change in the rat UV-B dermatitis model is not as large as in psoriasis. However, under normal conditions rat epidermis comprises only two keratinocyte layers including the basal layer, whereas the human epidermis is constituted by more than 10 layers. Therefore, the increment up to 6 layers observed in the

rat might correspond with that up to 30 layers or more in the patients with psoriasis. In the present study, the major locus of the epidermal cell proliferation was the epidermal sheath layers of the hair follicles. It is not clear whether this proliferation pattern is made by way of compensation for the epidermal basal cell damage caused by UV irradiation.

To analyse the phenotype of the mononuclear cells infiltrated at the papillary dermis of rat UV-B dermatitis, tissue frozen sections of the skin lesions were immunohistochemically examined with an anti-rat macrophages mouse monoclonal antibody (PM-2K) (Takeya *et al.* 1991). However, most of these cells were negative, whereas many mononuclear cells in the deep dermis were positively stained (data not shown). Therefore, most of the mononuclear cells of the upper dermis of the rat UV-B dermatitis seemed to be lymphocytes or others.

One of the most interesting findings of the present study is that epidermal proliferation was apparently prevented by ferritin treatment concomitant with the suppression of the leucocyte infiltration. It is of interest to speculate whether there is a correlation between the mononuclear cell infiltration of the upper dermis and epidermal cell proliferation.

When the leucocyte infiltration was blocked by ferritin treatment, the presence of the sunburn cells (degenerated keratinocytes) in the epidermis became more obvious. It is possible that one role of the leucocytes infiltrating the epidermis may be the removal of the sunburn cells prior to epidermal replacement by proliferation. When leucocyte infiltration and epidermal proliferation were blocked, the histological picture of the UV-dermatitis of rat was characterized by epidermal sunburn cells and by the microvascular dilatation of the papillary dermis. These histological observations resemble those of UV-B dermatitis in other mammalian species. Therefore, the features of rat UV-B dermatitis that differ from other mammalian species seem to be attributable directly or indirectly to the leucocyte infiltration. In the present study, Wistar rats were mainly used. We have also examined rats derived from other strains such as F344, DA and Sprague-Dawley, in the same way with UV-B irradiation. Their dermal response was essentially the same as the Wistar rat, apart from some minor differences in their time course or intensity. The pattern of response to UV-B irradiation in the rat seems to be a unique property of this species.

Acknowledgements

The authors thank Ms T. Kubo (Kumamoto University)

for her technical assistance in histological tissue preparations; and Dr M. Jono, Professor emeritus H. Takahashi and Dr T. Imamura (Kumamoto University) for their helpful discussions.

References

- BAZZONI F., CASSATELLA M.A., ROSSI F., CESKA M., DEWALD B. & BAGGIOLINI M. (1991) Phagocytosing neutrophils produce and release high amount of the neutrophil-activating peptide 1/interleukin 8. *J. Exp. Med.* **173**, 771–774.
- CHRISTOPHERS E., SCHRÖDER J.M. & MROWIEZ U. (1989) Identification of two endogenous neutrophil activating peptides in psoriatic skin and inflammatory cells: C5a des Arg and NAP. *Dermatologica* **179** (Suppl. 1) 9–15.
- CIANOCIOLO G.J. & SNYDERMAN R.J. (1981) Monocyte responsiveness to chemotactic stimuli is a property of subpopulation of cells that can respond to multiple chemoattractants. *J. Clin. Invest.* **67**, 60–68.
- DEZZA L., CAZZOLA M., BERGAMASCHI G., STELLA C.C., PEDRAZZOLI P. & RECALDE H.R. (1988) Effect of recombinant human H subunit and L-subunit ferritins on *in vitro* growth of human granulocyte-monocyte progenitors. *Br. J. Haematol.* **68**, 367–372.
- FOGH K., HERLIN T., & KRAGBALLE K. (1989) Eicosanoids in acute and chronic psoriatic lesion: leukotriene B₄, but not 12-hydroxy-eicosatetraenoic acid, is present in biologically active amounts in acute guttate lesions. *J. Invest. Dermatol.* **92**, 837–841.
- FORD-HUTCHINSON A.W., BRAY M.A., DOIG M.V., SHIPLEY M.E. & SMITH M.J.H. (1980) Leukotriene B, a potent chemokinetic and aggregating substance released from polymorphonuclear leukocytes. *Nature* **286**, 264–265.
- KATO T., TERUI T., TAKAMATSU H. & TAGAMI H. (1989) Effects of psoriatic scale extracts on oxidative metabolic responses in granulocytes assessed by chemiluminescence. *Inflammation* **13**, 59–66.
- KUKITA I., YAMAMOTO T., KAWAGUCHI T. & KAMBARA T. (1987) Fifth component of complement (C5)-derived high-molecular-weight macrophage chemotactic factor in normal guinea pig serum. *Inflammation* **11**, 459–479.
- MATSUBARA S., YAMAMOTO T., TSURUTA T., TAKAGI K. & KAMBARA T. (1991) Complement C4-derived monocyte-directed chemotaxis-inhibitory factor. *Am. J. Pathol.* **138**, 1279–1291.
- McKEE P.H. (1992) *Pathology of the skin with clinical correlation*. Gower Medical Publishing. London. pp 8.3–8.8.
- MORIMOTO Y., SAGA K., BANDO M. & TAKAHASHI M. (1991) *In-vitro* DNA synthesis of keratinocytes in normal human skin, psoriasis, Seborrhoeic keratosis, Bowen's disease and basal cell carcinoma. *Br. J. Dermatol.* **125**, 9–13.
- NAKAGUMA H. & TAKAHASHI H. (1990) Remarkable elevation of leukotriene B₄ in rat skin after induction of UV photodermatitis. *Inflammation* **14**, 195–203.
- PINKUS H. & MEHREGAN A.H. (1966) The primary histologic lesion of seborrheic dermatitis and psoriasis. *J. Invest. Dermatol.* **46**, 109–116.
- SMITH C.W., HOLLERS J.C., PATRICK R.A., & HASSETT C. (1979) Motility and adhesiveness in human neutrophils effects of chemotactic factors. *J. Clin. Invest.* **63**, 221–229.
- STRIETER R.M., KASAHARA K., ALLEN R., SHOWELL H.J., STANDIFORD T.J. & KUNKEL S.L. (1990) Human neutrophils exhibit disparate chemotactic factor gene expression. *Biochem. Biophys. Res. Commun.* **173**, 725–730.
- TAKAMATSU H. & TAGAMI H. (1993) Quantification of chemotactic peptides (C5a anaphylatoxin and IL-8) in psoriatic lesional skin. *Arch. Dermatol.* **129**, 74–80.
- TAKEYA M., TSUCHIYA T., SHIMOKAWA Y. & TAKAHASHI K. (1991) A new monoclonal antibody, PM-2K, specifically recognized tissue macrophages but not blood monocytes. *J. Pathol.* **163**, 315–321.
- WILLIAMS D.E., COPPER S. & BROXMEYER H.E. (1988) Effect of hematopoietic suppresser molecules on the *in vitro* proliferation of purified murine granulocyte-macrophage progenitor cells. *Cancer Res.* **48**, 1548–1550.