

## Section of **Odontology**

President—A. H. PARROTT, O.B.E., M.D.S. Birm.

[November 28, 1938]

### **Radiological Findings in Some Less Common Jaw Affections**

By H. M. WORTH, M.R.C.S., L.D.S., D.M.R.E. (Camb.)

CERTAIN specified affections of the jaw are considered, which are relatively rare and infrequently met with. Because of this their radiographic appearance is unfamiliar.

#### SCLEROSING OSTEITIS

Most of us are familiar with the appearance of bone sclerosis at the apices of teeth, either in association with rarefying osteitis or occurring alone. It is also not infrequently encountered at the sides of apparently healthy teeth or sometimes surrounding and obscuring retained roots. It is generally regarded as being an infective process. What is not so well understood is that these areas of sclerosis may sometimes reach large size, so that some doubt is cast upon the radiographic interpretation (fig. 1). Apart from the greater extent of the sclerosed area, the

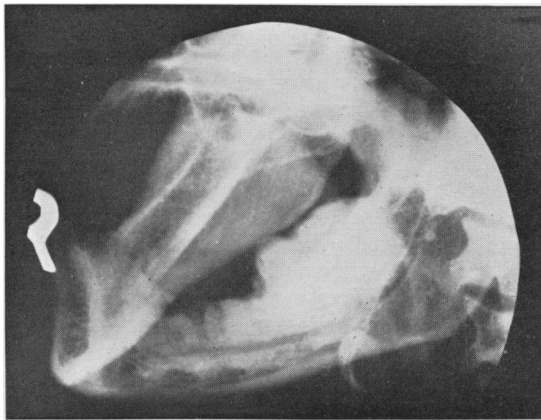


FIG. 1.—Massive sclerosing osteitis.

radiographic features resemble those of the small areas in that the bone structure is obscured by the filling in of the bone spaces by new bone, so that the whole involved portion is white in appearance and homogeneous in density. The margins tend to be more sharply defined than in the small areas. Those cases in which a large area is involved are rare and, in my experience, have occurred only in the mandible. They have been sent for radiographic examination on account of pain and, in one case, the pain was so severe that it had been considered necessary to operate upon the Gasserian ganglion. Fortunately, however, the local condition was recognized and excised, with complete relief of the symptoms. It is interesting to speculate on the ætiology of these large areas of bone sclerosis and it might be thought that they may follow osteomyelitis, but I have never found any evidence to suggest that such

was the case. Radiographically they have to be differentiated from : (1) *Composite odontome* ; (2) *osteitis fibrosa* ; (3) *osteoma*.

A *composite odontome* has a thin, dark line surrounding it which represents the site occupied by its fibrous capsule. Sclerosing osteitis is devoid of this capsule and is continuous with the surrounding bone.

*Osteitis fibrosa* is not likely to be so homogeneous in density, neither is it likely to be so sharply defined from the surrounding bone, or to involve only the alveolar portion of the jaw. *Osteitis fibrosa* is, as we shall see, usually a more diffuse involvement of the mandible.

True *osteomata* tend to arise from the body of the mandible, but it might not be possible to differentiate the two conditions radiographically.

Sarcoma might have to be considered as a differential diagnosis, but it is not likely to be so homogeneous and so dense, although it might be. The clinical features would probably suggest the innocence or otherwise of the condition.

#### PAGET'S DISEASE (OSTEITIS DEFORMANS)

A recent census of cases of osteitis deformans which have been radiographed in the X-ray departments at Guy's Hospital, shows that the condition is seen in those departments with a frequency of about one case a week. Notwithstanding this fact, I cannot recall having seen more than a few cases associated with changes in the bones of the jaws. Brailsford has recorded the fact that Paget's disease produces three different types of bony changes in the long bones, and he has described them thus :—

The *osteolithic* type in which there is uniform increase in density of the bone with obliteration of the cancellous trabeculæ so that a "ground-glass" appearance is produced (fig. 2).

The *osteoporotic* type : In this the affected bone is less dense than normal and its trabeculæ are coarser and irregularly arranged (fig. 3).

The *lithocystic* type in which there is a combination of the two preceding types (fig. 4).

These three different appearances of the condition as it may occur in the long bones are reproduced somewhat closely, but not exactly, in the jaws. Excluding the osteoporotic type, there is a resemblance between the other two and *osteitis fibrosa* from which it can be differentiated by the fact that in the latter condition only one portion of the jaw is involved, whereas in Paget's disease the whole of the jaw is usually affected. There is an interesting change in the appearance of the teeth which is sometimes found in Paget's disease, a more or less globular "exostosis" of some of the tooth roots. In one of the cases that I saw there were several teeth involved and the "exostosis" was even more marked (fig. 2). Such a condition of the teeth alone might lead one to investigate the long bones and skull for evidence of bony changes.

#### OSTEITIS FIBROSA

This is an interesting, if rare, condition, which has a way of appearing in unexpected places. In the well-developed cases the condition is not difficult to recognize, but in the early cases of small extent its recognition may be very difficult, or perhaps I should say it may not even be thought of. *Osteitis fibrosa* is the name given to different conditions ; for instance there is *osteitis fibrosa cystica* which is associated with parathyroid tumour or hyperplasia. In this condition there is decalcification of the bones with cyst formation and increase of calcium in the blood-serum. The jaws may be involved by cystic formation, but I have never seen a case.

There is another type of *osteitis fibrosa* which produces cysts in the long bones, but which is unassociated with general decalcification of the bones or with parathyroid change. The blood-serum is normal in this condition. More than one bone may be affected at the same time.

The third type is also unassociated with parathyroid or blood-serum changes. There is no general decalcification, but there is, in the affected bone or bones, a structural change, the normal bone being replaced by bone or fibrous tissue. Either of these structures may predominate, so that the radiographic appearances will depend upon which is in excess, the bone or fibrous tissue. This is the type of osteitis fibrosa that I wish to discuss.

Without wishing to attempt any classification except according to radiographic appearances, one recognizes three different "types" which are found in the jaws. There may be, however, a merging of any of the "types" in one individual.

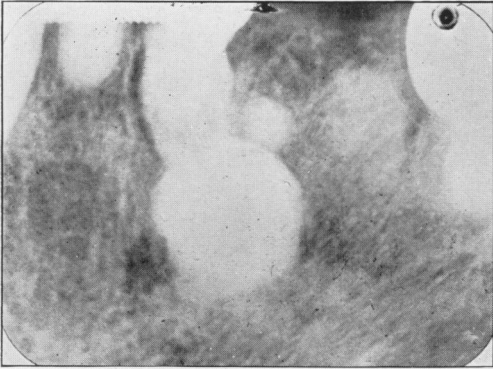


FIG. 2.—Paget's disease.

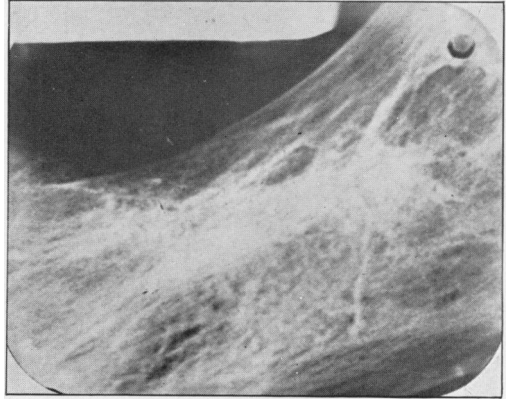


FIG. 3.—Paget's disease.

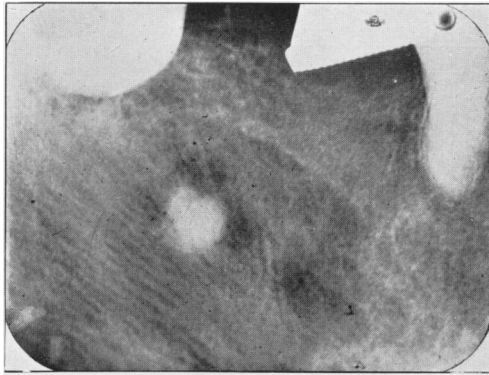


FIG. 4.—Paget's disease.

One "type" is found in the maxilla in young subjects. There is new bone formation which is relatively soft and which, on radiographic examination, resembles the outer surface of the rind of an orange (fig. 5). It may cause considerable enlargement of the affected side of the maxilla and encroach upon the antral cavity. It is sometimes said that the condition is infective, but pathologists do not agree with this.

A second "type" occurs in the maxilla in adults of any age and results in an increase in the size of the affected part, either laterally or downwards into the mouth, or both. The new bone is hard and produces a radiographic appearance which is best described as granular or simulating "ground glass". In one case there was also a very extensive involvement of the anterior aspect of the cranium (fig. 6).

The third "type" occurs in the mandible and, in my experience, has always commenced in young subjects. The depth of the jaw may be increased considerably and the width less so, or the disease may be localized to a portion of one side of the jaw.

The radiographic appearances vary from a fairly homogeneous "ground-glass" appearance to an irregularly calcified condition with more or less dark cyst-like

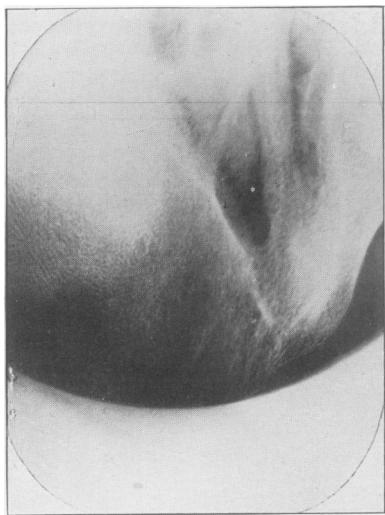


FIG. 5.—Osteitis fibrosa. Type I.

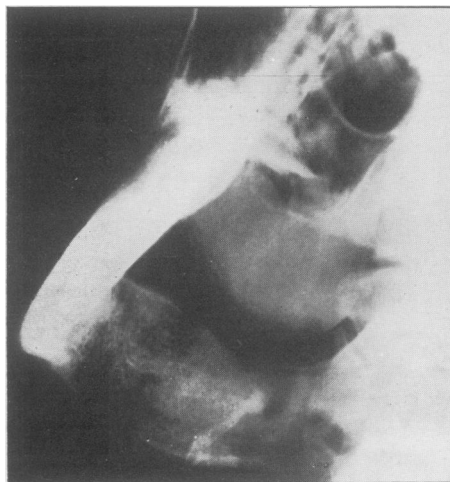


FIG. 6.—Osteitis fibrosa. Type II.

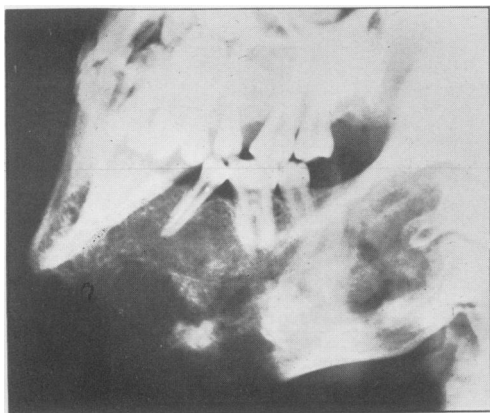


FIG. 7.—Osteitis fibrosa. Type III.

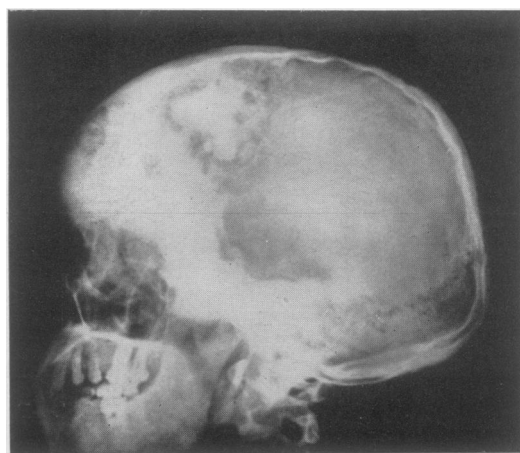


FIG. 8.—Osteitis fibrosa in skull. (Same patient as in fig. 7.)

irregular cavities in the bone (fig. 7). In all those cases that have been submitted to operation, the bone has been very hard. In one case there was extensive involvement of the anterior aspect of the cranium which was clearly not a direct extension of the disease, but a separate focus (fig. 8). I do not suggest that these three "types" are different clinical entities, but different radiographic manifestations of the same disease. So far we have only considered the extensive condition, but it is sometimes encountered in very small foci in which the possibility of osteitis fibrosa is not con-

sidered frequently enough. The localized areas vary in appearance from what looks like a condensation of bone simulating sclerosing osteitis, but lacking its homogeneous density and possibly associated with obviously new tissue formation (fig. 9) to, at the other end of the scale, obvious replacement of bone by a less dense substance, but having calcified areas in it.

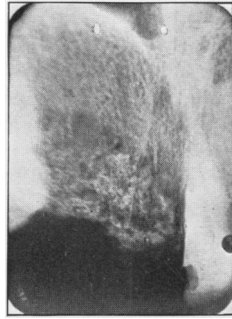


FIG. 9.—Localized osteitis fibrosa.

There are types of the same condition which show any combination of the two appearances just described.

#### MID-LINE CYSTS (INCISIVE CANAL CYSTS)

The anterior palatine foramen or incisive fossa as it is now called, may or may not appear in a radiograph, and when it does appear it is recognized by its central position in the maxilla. It varies very considerably in size and clarity in different individuals, and may be very large without any suggestion that there is a pathological condition present. Occasionally, however, the clinical and radiographic appearance leads to the diagnosis of a pathological process in the fossa. Such a condition is usually

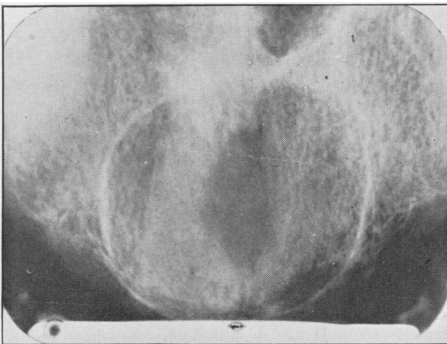


FIG. 10.—Mid-line cyst.

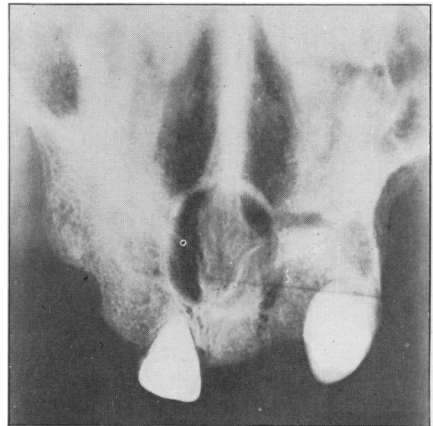


FIG. 11.—Mid-line cyst.

regarded as being a cyst, but without causal relationship with the teeth, although the disease process may spread and involve the teeth. In my experience these cysts have predominated in edentulous patients, probably on account of the fact that pressure upon the papilla in the palate by the denture has made the patient aware of an abnormality (fig. 10). Cases have been encountered which have the incisor teeth standing and, on the whole, they have offered more difficulty in diagnosis (fig. 11).

But whether dentulous or edentulous, there is revealed in the radiograph an area of bone destruction in the mid-line of the palate in the incisor region. The cavity is clearly defined by a corticated wall and varies in size considerably. The larger cysts in edentulous cases offer no difficulty in recognition, but the small ones may not be readily differentiated from a normal, but large foramen. In such a case the clinical findings would be the determining factors. In cases with teeth present, there is difficulty in differentiating the large cysts from dental cysts arising from one of the incisors. This differentiation can only be made by the recognition of persistence of normal lamina dura. A cystic cavity in the mid-line unassociated with changes in the lamina dura is almost certain to be an incisive fossa cyst. In the case of a small enlargement of the foramen in a patient with incisor teeth standing, the clinical findings would determine the diagnosis. If a radiograph shows what appears to be a large foramen, I usually consider the condition is an anatomical one in the absence of clinical evidence to the contrary. There is no appearance in the radiograph which enables the differentiation to be made, but I am always suspicious when I see a rounded "foramen" with dense cortical lining.

#### EPITHELIAL ODONTOME (MULTILOCLULAR CYST; ADAMANTINOMA)

Notwithstanding that the literature suggests that this condition is common, it is considered a rarity at Guy's Hospital, where few cases of adamantinoma are seen. Most of the cases in my experience have occurred in the mandible in men, and I can only recall having seen it in the maxilla on two occasions. There are two types, the cystic and the solid, but they may occur together. The radiographic features differ in both, and as a rule it is possible to differentiate them radiographically. The cystic type is the more common of the two. The usual site is at the posterior aspect of the horizontal ramus and in the ascending ramus. The cystic type may present one of two appearances.

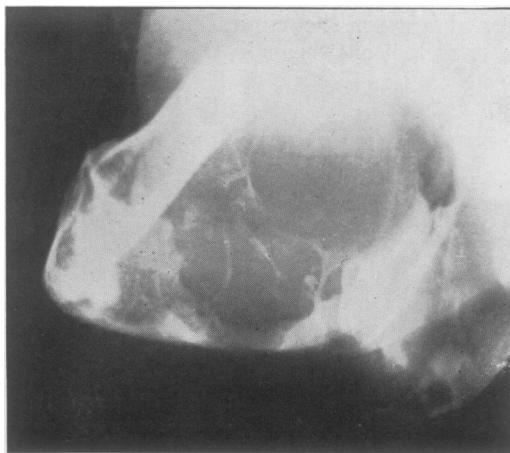


FIG. 12.—Epithelial odontome. Cystic type.

Taking the commoner type first, it is found in the ascending ramus chiefly, and extends in a greater or less extent along the horizontal ramus. From the radiographic appearances there is nothing to suggest the name of "multilocular cyst." There is a large area of bone destruction with well-defined borders, but not very clearly corticated, somewhat suggesting the presence of a large cyst which has suppurated. Indeed the only feature which permits diagnosis from a cyst is the presence of a very coarse trabeculation in the middle of the area of destruction. These coarse striæ are quite characteristic of the condition and make the diagnosis easy (fig. 12).

Another point of value is the relatively small amount of bone destruction as compared with the size of the tumour clinically.

The other cystic type is well fitted to have the name "multilocular cyst", for it is made up of well-defined cystic cavities. The cystic spaces are large and well defined while the walls are relatively thin (fig. 13). There is sometimes an unerupted tooth in the middle of the cyst.

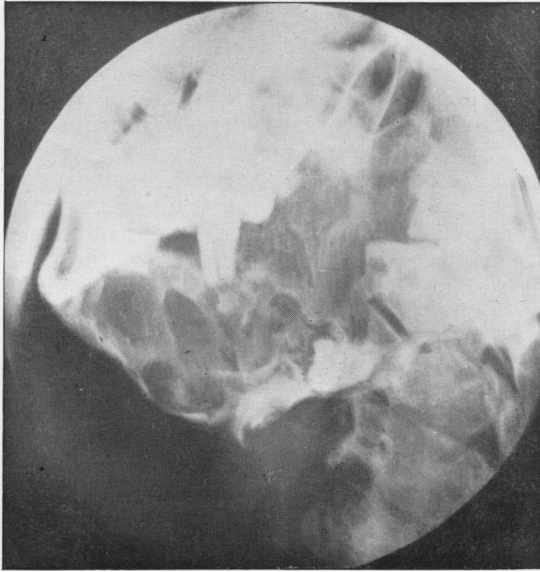


FIG. 13.—Epithelial odontome. Multilocular cystic type.

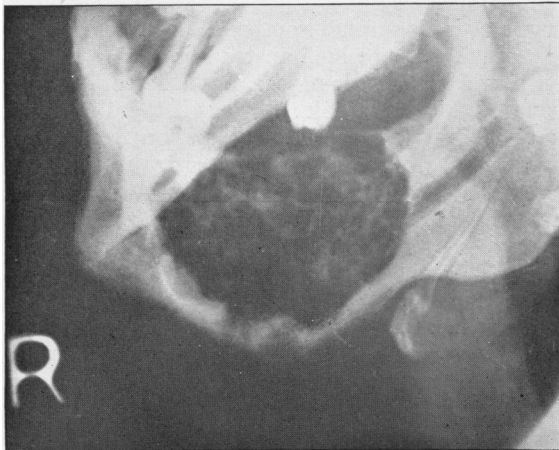


FIG. 14.—Epithelial odontome. Solid type.

The solid type of epithelial odontome shows a more or less multicystic appearance, but the spaces are smaller and the walls may be thicker. The condition is seen to resemble the previous type, but the bone spaces are smaller, less well defined, and with more bone present (fig. 14). In some cases the little spaces are well defined and

corticated, while in others the appearances suggest a honeycombed destruction of bone, so that individual holes have no clearly defined margin.

Other cases reveal the same appearance of a group of small cell-like spaces rather resembling a honeycomb. The walls of the individual cells are not very sharp, "fluffy" might describe it, but in the smaller tumours this may not be quite so apparent. In one case the radiograph revealed a combination of the cystic type posteriorly and the solid type anteriorly. It is usually possible to differentiate the cystic and solid types, but the latter is very easily mistaken for osteoclastoma. Experience of a number of radiographs shows that if the large cystic condition is present, the diagnosis can be made at once, but in the absence of the large cyst, the differentiation between the solid adamantinoma and osteoclastoma may be very difficult. There may be nothing in the radiographic appearance to assist in a differential diagnosis, but it should be remembered that an adamantinoma occurs late as a rule and osteoclastoma is a condition usually found in younger people.

An epithelial odontome may become epitheliomatous, and I once obtained a radiograph of a patient in which that change had just taken place. The radiograph clearly showed the localized infiltration of the bone by the malignant change, whereas the rest of the tumour presented the typical appearance of an epithelial odontome.

#### OSTEOCLASTOMA (GIANT-CELLED BONE TUMOUR)

This condition very closely resembles other conditions from the radiographic point of view and so it has been included for consideration. Osteoclastoma of the jaws is not by any means so frequently seen as epithelial odontome. It appears to occur in younger subjects than epithelial odontomes and, like them, has been found more often in the mandible than in the maxilla. The situation of most of my cases was anterior, but I have seen the condition in all parts of the jaws. These two points of difference between the age incidence and the sites are of some value in the differentiation of osteoclastoma from epithelial odontome. The radiographic appearances of different osteoclastomata may vary very considerably, and while a confident opinion may be given in some cases, in others it is not possible to do so. The simplest type of radiographic appearance of this condition is that in which there appears to be a cystic cavity which, instead of having a clearly defined cortical, bony lining, there is a well-marked demarcation of the cavity. The margins are not quite so definite as with a cyst and look rather as if there were abortive attempts to wall off the tumour. This is one point of distinction from a cyst, another is that there is some bony structure, perhaps very slight trabeculation only in the cavity (fig. 15). I have found this point of the greatest value in the differentiation of osteoclastoma from cyst. It is surprising how very slight the amount of trabeculation may be to enable a confident opinion to be given. The trabeculation is fine, not like that in the epithelial odontome.

Another type of radiographic appearance is one in which there is considerable expansion of the jaw with central destruction, but with more and coarser trabeculation, which is irregularly arranged (fig. 16). The walls of the expanded cavity remain bony in contra-distinction to those of a cyst of commensurate size. Furthermore, a cyst wall is usually smooth, whereas that of an osteoclastoma may be irregular; and this point has proved of value in radiographic diagnosis (fig. 17).

The third radiographic type closely resembles the solid type of epithelial odontome; indeed it may not be possible to differentiate between the two.

Points of value in the differentiation are that the osteoclastoma may show a slightly more dense cortex, and the bony walls to the cellular spaces tend to be distinct and somewhat "fluffy" in appearance. There is an impression of greater osseous reaction in the tumour with an osteoclastoma (fig. 18). It is difficult to convey an accurate description of these appearances which are clearly shown in



the radiographs. The radiologist has the radiographic features alone to guide him, and these may not be sufficient to enable a differential diagnosis to be made; with all the evidence before him the clinician, however, may be able to decide what the

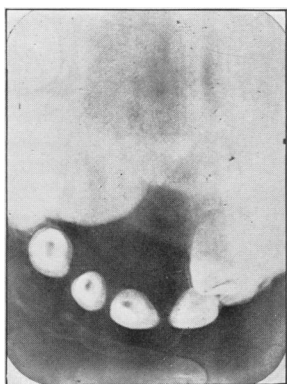


FIG. 15.—Osteoclastoma. Very fine trabeculation.

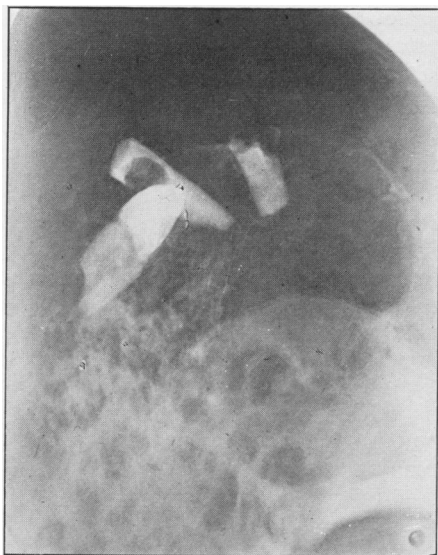


FIG. 16.—Osteoclastoma, showing bony cortex.

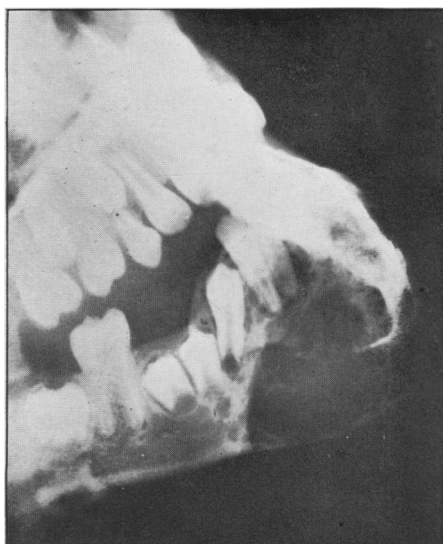

FIG. 17.—Osteoclastoma.

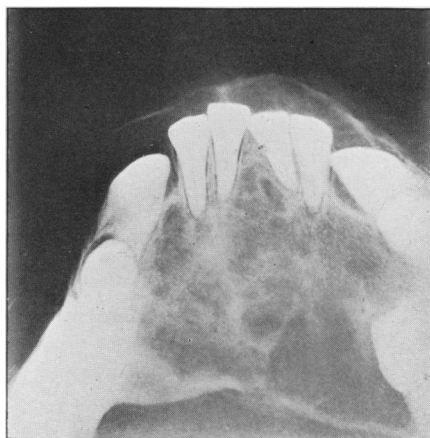


FIG. 18.—Osteoclastoma, simulating epithelial odontome.

condition really is. There will probably be a certain number of cases which can only be decided after operation and histological section. In this respect there is one case in which because the gross enlargement of the mandible was associated with

enlargement of the glands, the radiographic diagnosis was considered to be inaccurate (fig. 17). Section after biopsy produced a diagnosis of osteitis fibrosa which was obviously not correct; but on full operation, the condition was found to be osteoclastoma and further section proved it so. This experience is not very uncommon in the case of bone tumours, and it goes to show that only by a consideration of all the features, clinical, radiographic, histological, and subsequent history, can accurate diagnosis be made in doubtful cases. There have been cases in which the radiographic appearance of an osteoclastoma very closely resembled osteitis fibrosa of the focal type; and the differentiation was suggested by the fact that only a relatively small portion of the jaw was affected or by absence of typical radiographic features of either condition (fig. 18).

#### NEOPLASMS

Of the malignant neoplasms, *epithelioma* is the commonest in the jaws. It may arise anywhere in the mandible and maxilla, but it is probable that the most frequent site in the mandible is at the junction of the ascending and horizontal rami, while in the maxilla the mucous membrane of the antrum is the commonest place. The tumour does not arise in the bone but involves it by invasion, and the radiographic appearances are those of bone destruction with no evidence of any bone reaction. With the columnar or squamous-celled growths the area of bone destruction contains no bone and the edges are irregular and serrated. This irregular, serrated edge, when present, is typical of a neoplasm, not necessarily an epithelial one, but a

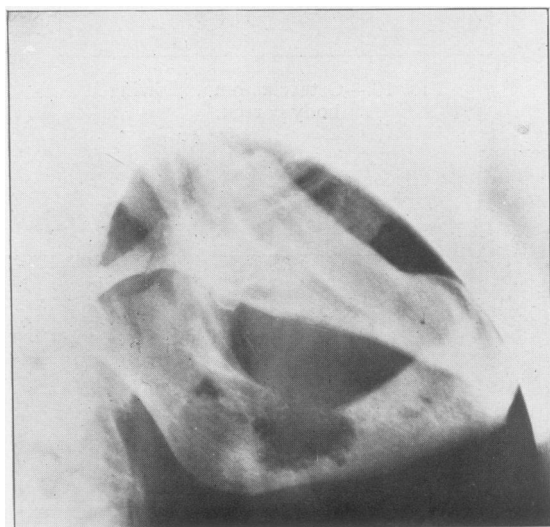


FIG. 19.—Carcinoma of mandible.

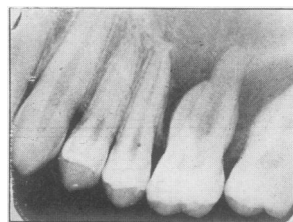


FIG. 20.—Carcinoma of alveolus arising in antrum.

malignant one of some kind (fig. 19). There is no evidence of any new bone at the edges of the growth, nor of sclerosis in the bony walls. The typical picture is that of bone destruction. In the case of the antral involvement there will be destruction of that part of the wall which is adjacent to the growth and in the affected portion of the maxilla (fig. 20).

Here again there will be no bony lining such as we may see in the case of sarcoma and which is always present with cysts and innocent growths which extend from the maxilla into the antrum. Occasionally in the case of basal-celled carcinoma a number of which have, in my experience, been seen at the posterior aspect of the

horizontal ramus, there is a saucer-shaped defect in the alveolar border, or there may be what appears to be an unhealed socket present (fig. 21). The absence of history of recent extraction and the sharply defined margins of the bony defect lead one to suspect a growth of this type, but it is not possible to be certain in the absence of histological section. One such case which I examined developed a wide destruction of mandible, notwithstanding that the tumour had been dealt with surgically and by surgical diathermy.

*Sarcoma.*—Is not very frequently encountered in the jaws, but it is occasionally seen. It may present a variety of different appearances as it does in any other bone, depending upon the type of growth that is present.

There is the frankly bone-destroying tumour which may not be differentiated on radiographic evidence from carcinoma; but in complete contrast with this there is the type of growth which results in much new bone production with little, if any, bone destruction. The first is termed the osteolytic type and the latter osteogenetic, and there is a wide variation of combinations of the two processes in different tumours. As has already been intimated, the osteolytic type has similar features

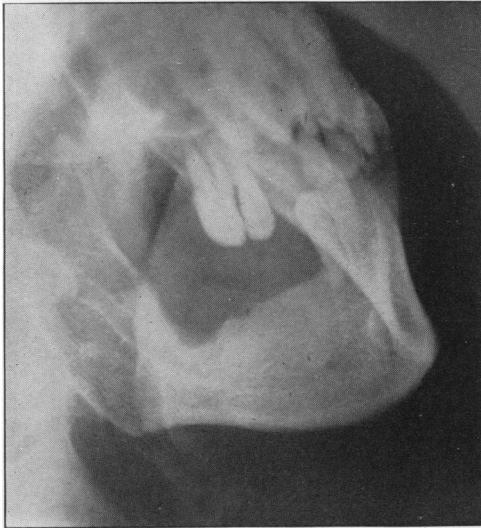

FIG. 21.—Basal-celled carcinoma in mandible.

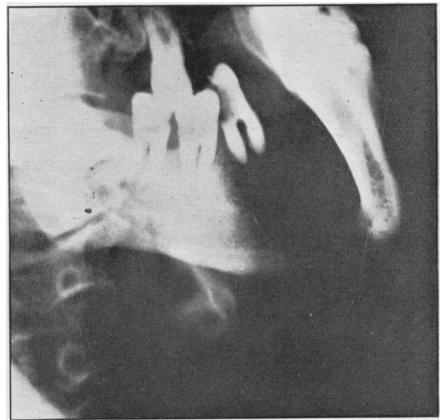


FIG. 22.—Osteolytic sarcoma.

to carcinoma and, in my experience, the only point of difference which has been of slight value in differentiating the two is that sarcoma appears to involve a wider area and greater depth of bone more quickly than does carcinoma, but this is by no means a constant finding and is not a reliable criterion (fig. 22). The edges of the bone present the irregular infiltration which is so typical of neoplastic invasion. The tumours which result in a small amount of bone reaction tend to have better-defined bony margins and may indeed be corticated. Though it resembles an osteoclastoma it may be differentiated in some cases by the sharpness of the trabeculae in the sarcoma, as compared with the "fuzzy" outline of the trabeculae in an osteoclastoma. These are not certain means of differentiation, but they are helpful.

In other sarcomata there is no well-defined line of demarcation of the bone, but the presence of new bone formation in the centre is of value in suggesting the probability of sarcoma. Other points of value in the recognition of a sarcomatous growth may be, that in addition to one of the former appearances, there is a definite

invasion of a normal cavity such as the antrum (fig. 23). This is a very valuable point, because the simple tumours which involve the antrum invaginate the sinus, but do not invade it. The edge of the tumour may present useful evidence: a sarcoma may be devoid of bone at its periphery (fig. 24) or there may be irregular new bone production contrasting with the smooth expansion of the bone by a cyst and the less smooth, but usually continuous, shell of the osteoclastoma.

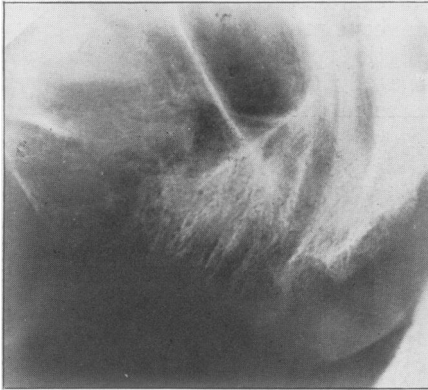


FIG. 23.—Sarcoma invading antrum.

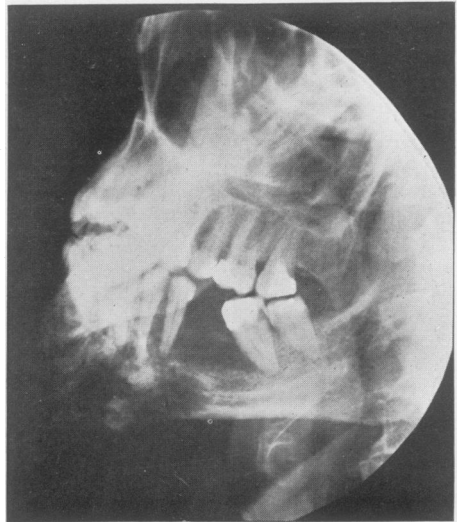


FIG. 24.—Sarcoma of mandible.

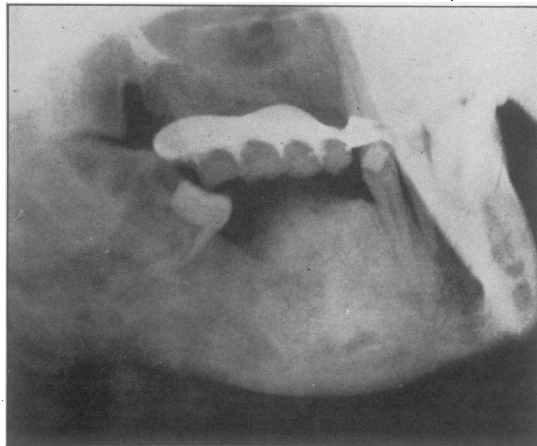


FIG. 25.—Osteogenic sarcoma of mandible.

In those sarcomata which present a large amount of new bone formation, there may be close similarity with simple hyperostosis, and only the clinical features may suggest the presence of a serious lesion. One sign which is said to be typical of osteogenetic sarcoma is the presence of vertical spicules of bone situated at more or less right angles to the bone. When present, they certainly do suggest the probability of sarcoma, but they are not absolutely pathognomonic (fig. 25). In

sarcoma, perhaps more than most bony diseases, the diagnosis can only be made by a consideration of all the evidence available and, in some cases, only by a consideration of the subsequent history. It is sometimes useful to re-examine a suspected tumour after a short lapse of time, when there may be further evidence of the greatest value. Against this it might be said that delay is not justifiable, but this would not be vital if the interval were only a few weeks.

Dr. DAVID A. IMRIE said he was very interested to hear that in many cases of osteitis fibrosa Dr. Worth found the bone to be of great density. In his experience the bone in osteitis deformans and osteitis fibrosa was soft, and in many cases the extraction of the teeth, which were often markedly exostosed, was easy. In fact it frequently happened that some portion of the bone was removed with the tooth. Assuming the correctness of the theory propounded by Lawford Knaggs that osteitis fibrosa and osteitis deformans may be due to the same condition, in individuals at different age-periods, the density of the bone encountered in young subjects suffering from osteitis fibrosa may be due to the greater activity of the osteoblastic element. In view of the comparative rarity of the osteitis deformans encountered in the dental as opposed to the general radiographic department, he suggested that Dr. Worth might examine the jaws of cases from the general department to determine whether the changes in the alveolar bone were an early or late manifestation of the disease.

## The Dental Stigmata of Congenital Syphilis

By LEWIS G. CRUICKSHANK, L.R.C.P. & S., L.D.S.

*Introduction.*—Over eighty years have elapsed since Sir Jonathan Hutchinson, in 1857, published his original account of the dental changes associated with congenital syphilis. He stated that the upper central incisors were to be considered the “test teeth”, and that statement still holds good to-day. Congenital syphilis, like acquired syphilis, is becoming more and more a disease which in many cases can only be diagnosed by serological methods. The reason for this is either a natural mitigation of the disease, or more probably the effect of the “914” group in treatment. In only a very small percentage of cases does one see the classical skin and bone lesions of the textbooks.

Experience shows that there are two chief age-periods at which congenital syphilitics come under observation:—

(1) Within the first few months of birth—the period of “snuffles”, skin rashes, &c.

(2) About school age—the commonest presenting symptom being interstitial keratitis, most frequently occurring between the ages of 8 and 15, although 17–19 is a common age in females, and cases have been recorded as late as 34 (Lees, 1937).

The most diagnostic of the dental stigmata, the Hutchinsonian incisor, is present from about the 7th year onwards, and its more frequent recognition by dental surgeons might often lead to the recognition of congenital syphilis before some dramatic occurrence such as interstitial keratitis caused medical aid to be sought. The ability to recognize the clinical variants of the Hutchinsonian incisor, and a knowledge of the less common dental stigmata of congenital syphilis, are thus a matter of importance to the practising dental surgeon, the importance being from the patient's point of view rather than the dentist's, as congenital syphilitics become non-infective within a short time of birth.

*Stigmata in the deciduous dentition.*—Hutchinson (1887) described a condition in which “the tooth sacs suppurate, and the crowns of the teeth, almost always the upper central incisors, are exfoliated before they are cut”. This he attributed to “congestion of the gums and tooth sacs during the secondary stage of syphilis in infants”.