

Mr. GEOFFREY JEFFERSON said that the idea was put forward, in Germany particularly, that if the common carotid were tied there was a greater risk of embolism than if one tied the internal. The idea was that one had a thrombus at the site of the tying of the ligature, and the returning blood from the external carotid might sweep off a clot and carry it into the internal carotid. One of his assistants had been making a survey of cases from the point of view of ligature of the carotid for aneurysms only. The earlier literature was entirely unreliable. Although on the whole perhaps the tying of the common carotid was a poor operation as compared with the tying of the internal, it should at least reduce the risks of rupture, and so far, in the series in which a ligature of the common carotid—or in some cases of the internal—had been made no patient had as yet died of rupture, although he was fully aware that that might occur. Referring to the first case shown at that meeting by Dr. Carmichael, it was well to remember that no aneurysm had ever calcified over the whole of its circumference; there was always a weak point where the aneurysm joined the main trunk, and it was at that point that it was most likely to leak if it occurred at all. Up to a point calcification was a sign of stability. In a case with an aneurysm of the size shown by Dr. Carmichael one would expect the patient to have papilloedema. In the analysis he published a year ago a number of the cases with papilloedema were included, though most had optic atrophy. There were few aneurysms of the size observed by Dr. Carmichael.

In reply to the President, who asked what was the relative efficacy of tying the internal and of tying the common carotid in aneurysms, Mr. Jefferson said that perhaps in a few months' time he might be able to answer that question because the whole matter was at present being surveyed. He did not think embolism occurred; what did happen was that the blood supply was cut down with subsequent thrombosis.

Myopathic Weakness of Quadriceps.—D. DENNY-BROWN, M.B.

L. W., female, aged 42, attended the Neurological Clinic of St. Bartholomew's Hospital complaining of a weakness of the lower limbs of very gradual onset and progressive increase of severity over a period of five years. There is a family history of tremor of the hands, from which she also suffers. Her husband has had a specific infection which was early and adequately treated. The patient's blood Wassermann reaction has been consistently negative.

She noticed the weakness in the lower limbs by falling down when attempting to hurry. This was especially liable to happen when she was descending stairs, but gradually she had more difficulty in walking up steps. The weakness was more obvious if she were distressed or excited, and she was then more liable to fall, but she had not fallen as a direct consequence of emotion. Very gradually she had lost ability to run or move quickly without her knees collapsing.

On examination.—Rapid fine tremor of both hands, but no weakness or wasting in upper limbs. Cranial nerves normal. Moderately severe weakness of extension of both knees; quadriceps muscles on both sides wasted, especially vastus internus. All other movements of the lower limbs were of full power, and no other wasting was found. The shoulder and pelvic girdle musculature was unaffected, and there was no impairment of stability of the trunk in walking. There was no sensory loss, and no fibrillation. The tendon-jerks were brisk and equal except that the right knee-jerk was absent and the left reduced to a slight flicker in the wasted vastus internus. Plantar responses flexor.

It is thought that the condition is that described by Bramwell in *Proc. Roy. Soc. Med.*, 1922, 16 (Neur. Sect., 1), under the title "Symmetrical Atrophic Paresis of the Quadriceps Muscle of Probable Myopathic Origin". The onset is much earlier than in the cases described by Bramwell (53 and 59), and in two other cases personally observed.

The patient has been having glycine, 5 grm. twice daily, since June 1938, with considerable improvement, both in increased ability to mount stairs and in increased bulk of the quadriceps muscles. The knee-jerks are as when first observed. She still has great difficulty in walking downstairs.

Discussion.—Dr. ANTHONY FEILING said that the peculiar distribution of the wasting in this case recalled the appearance seen in the thighs in cases of peroneal muscular atrophy when well-marked signs were present—foot drop, and so on. Was it possible that this might be an atypical case of peroneal atrophy where the wasting began in the thighs in this peculiar manner?

Dr. C. P. SYMONDS believed this was a true example of the condition described by Bramwell. The unusual feature was the age of the present patient. These patients did represent a definite group. There were rare cases in which the wasting and weakness of the quadriceps, however long the condition persisted, remained limited to that region, with no fibrillary twitching and only slight disability. He agreed with Dr. Denny-Brown that the muscular atrophy associated with hyperthyroidism was not so limited. In the cases he had seen it had been present and obvious in the upper before becoming evident in the lower limbs. One hesitated to generalize from a limited experience. The thyrotoxic cases were rare, but in those he had seen or read about the atrophy had been fairly widespread in the upper limbs at an earlier stage. Whilst agreeing with Dr. Feiling on the resemblance of the muscular atrophy so far as the thighs themselves were concerned, he did not accept his suggestion that this might be an atypical case of muscular atrophy, because he believed that in that disease the wasting ascended from the feet upwards. Others than neurologists were very apt to regard these elderly people as suffering from hysteria. The patients might still preserve their knee-jerks at a time when they had considerable disability. It was rather an accident of the localization of the atrophy that they lost their knee-jerks. They had considerable difficulty in walking over rough ground and getting upstairs.

In reply to the President, who asked if there was any evidence that this condition was myopathic, Dr. Symonds said that he did not know whether Bramwell had any observations on that point. He had not persuaded his own patients to allow any biopsies to be done.

Dr. DENNY-BROWN said that he, too, did not know of any biopsy.

POSTSCRIPT (D. D.-B., 1.5.39).—The patient has since submitted to further investigation which hitherto she had refused. Cerebrospinal fluid normal. Wassermann negative. Biopsy: Right vastus externus muscle shows myopathic changes of the type

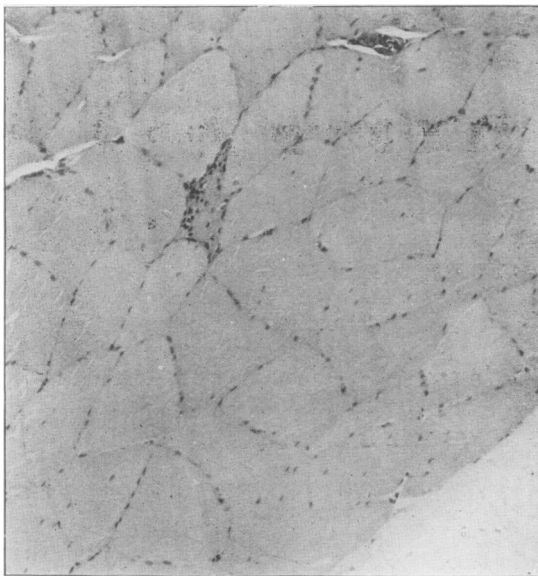


FIG. 1.

recorded by Nevin in a study of senile myopathy of more widespread distribution (*Quart. Journ. Medicine*, 1936, 29, 51). There are small necrotic muscle-fibres scattered throughout the muscle. These show a great increase of nuclei, and the sarcoplasm

stains deeply with eosin (fig. 1). In longitudinal section the necrotic change extends throughout the length of the fibre. In places small fibres in a more advanced stage are represented by bands of nuclei. The remaining muscle-fibres are larger than normal, and the majority show nuclei in the substance of the fibre, instead of the normal arrangement around the periphery. There is no inflammatory reaction.

Communicating Hydrocephalus simulating Cerebral Tumour.—
C. WORSTER-DROUGHT, M.D., and G. C. KNIGHT, F.R.C.S.

P. C., aged 12 years. Admitted to West End Hospital for Diseases of the Nervous System, on 5.12.38.

History of present condition.—Four weeks ago developed a severe headache with nausea and vomiting. Diplopia for two weeks. Headache became less and vomiting ceased.

Past history.—Scarlet fever when aged 5 years.

Physical examination.—Diplopia for past two weeks. Right superior oblique paresis. Nystagmus present to right and left. Papillœdema: Right: + 1.5 D. Left: + 3 D. Hæmorrhages present around both discs. Slight intention tremor on finger-nose test.

Cerebrospinal fluid (6.12.38): Naked eye, clear and colourless. Cells, none. Total protein: 0.025%. Globulin: No excess. Wassermann and M.K. reactions negative. Lange 0011000000.

Blood Wassermann and M.K. reactions negative.

Ventriculography, 8.12.38 (G. C. Knight).—Under local anæsthetic 76 c.c. air injected showed gross internal hydrocephalus, including fourth ventricle.

Operation, 12.12.38 (C. P. G. Wakeley and G. C. Knight).—Suboccipital decompression. Transverse incision. Posterior arch of atlas exposed. Needle inserted in the previous ventricular opening led to escape of air under pressure. Occipital bone removed widely on both sides, the dura was opened, and the sinus secured between silver clips. Considerable downward displacement of the cerebellar tonsils forming a pressure cone with impaction was noticed. There was no widening of the vermis, enlargement of the cerebellar hemispheres, or broadening of the cerebellar tonsil, to indicate possible tumour. Both cerebellar hemispheres were tapped and the vermis incised. The fourth ventricle was opened and appeared dilated at this point, suggesting an obstruction at a lower level, possibly due to numerous though slight adhesions which were found between the dura and cerebellar surface.

15.12.38: Still complains of headache and has vomited on three occasions. Temperature and pulse normal.

21.12.38: Cerebrospinal fluid removed by lumbar puncture. Examination (Dr. W. E. Carnegie Dickson) showed moderately turbid fluid, giving centrifugized deposit of compact reddish-brown red blood-cells, &c. Supernatant fluid remained brownish-red in colour, due to mixture of both fresh and partially hæmolyzed R.B.C. The films showed that the cells probably amounted to many hundred per c.mm. Varieties of cell (200 counted): Polys. 43.5%; small lymphos. 42.5%; small endos. 10.0%; large endos. (monos.) 4.0%. In both: Total protein 0.5% approximately. The cell count was made on those cells which were still identifiable, but there were also numerous "ghosts" too degenerated for identification. A few hæmatoidin crystals also found. The condition is evidently one of hæmorrhage, and no bacteria were detected in Leishman, Gram, and Ziehl-Neelsen films of the centrifugized deposit.

Culture: No growth in any of the twelve tubes inoculated. Films, 22.12.38: Examined from all 12 cultures, and no micro-organisms of any kind found on forty-eight hours' incubation.

Commentary.—When first seen, considering the headache, vomiting, papillœdema and nystagmus, the diagnosis certainly appeared to be one of subtentorial neoplasm, especially as within a week the papillœdema increased from 1 dioptre in