

TISSUE CHANGES ASSOCIATED WITH VITAMIN A DEFICIENCY IN THE RAT *

M. DAWSON TYSON, M.D., AND ARTHUR H. SMITH, Ph.D.

(From the Department of Pathology and the Laboratory of Physiological Chemistry, Yale University School of Medicine, New Haven, Conn.)

The conception of the vitamins as specific dietary requirements rests in part upon the uniformity and reproducibility of the effects resulting from a lack of these substances in the food. Not only are food intake and growth affected but other alterations in physiology and structure can be demonstrated. It was early pointed out by Osborne and Mendel (1913)¹ that when rats are given a simple ration, adequate except for vitamin A, there ultimately develops a type of eye disease which may be cured by incorporating butter fat in the food. This was long considered the principal lesion associated with this dietary deficiency.

In a further study of the changes associated with vitamin A deficiency Mori (1922)² concluded that the principal lesion is an atrophy of the glandular epithelium and a loss of secretory power on the part of the lacrymal gland. He stated that the drying of the eye and the xerosis of the corneal epithelium (xerophthalmia) are entirely dependent upon the lack of glandular activity. This investigator also found cornification of the mucosa of the larynx and trachea and of the ducts of the submaxillary, sublingual and parotid glands to be present. He said that if two per cent cod liver oil be added to the diet of rats with ophthalmia the conjunctival sac becomes moistened and the xerosis disappears. At the same time the lacrymal and salivary glands become normal histologically and show evidence of secretion. In contrast to the above are the papers reported by Yudkin and Lambert (1923).^{3,4} These authors concluded that the ocular manifestations of vitamin A deficiency are dependent upon the presence of a low-grade inflammatory process which commences in the nictitating membrane and palpebral conjunctiva, and spreads to the cornea, and that the keratinization of the corneal epithelium is

* Received for publication September 1, 1928.

secondary to the inflammatory process. Infection, according to them, plays an important rôle. Wason (1921)⁵ concluded that the corneal changes are due to infection. She found no pathological changes other than those in the eye.

Wolbach and Howe (1925)⁶ have made an extensive study of the pathological changes throughout the body of the rat. They concluded that the primary change is in epithelium and comprises "the substitution of stratified keratinizing epithelium for normal epithelium in various parts of the respiratory tract, alimentary tract, eyes and the paraocular glands and the genito-urinary tract." They did not state definitely in what order the above systems are involved, though in their experience the epithelium of the turbinate bones and of the submaxillary gland is always affected early. They mentioned the formation of large cysts in the accessory glands at the base of the tongue and described them as being lined by keratinizing epithelium. The cysts often attain a large size, sufficient to interfere with swallowing. They did not say in what proportion of cases this lesion occurred, but they believe that the process of keratinization and cyst formation can take place in the absence of infection. The submaxillary gland has received more attention from these authors and it is their opinion that changes in this structure precede those in the eye. They concluded that the lack of secretion of the glands throughout the body does not play a primary rôle in producing the metaplasia; that infection also is a secondary manifestation; and that the lack of the single vitamin A factor is directly responsible for the metaplastic activity of the epithelium.

It has been pointed out by Goldblatt and Benischek (1927)⁷ that the diets employed by Mori, and by Wolbach and Howe, were deficient in vitamins D and C as well as vitamin A. Goldblatt and Benischek, however, carried on experiments of their own and were able to reproduce the lesions described by the previous authors when vitamin A alone was lacking in the diet. They also noted the great frequency of abscesses at the base of the tongue in rats which were on a deficient diet and believed that the infectious process is "coincident with or subsequent to the epithelial metaplasia and is not responsible for the initiation of the changes." No metaplastic changes were found by them in other structures when there was none in the sublingual glands and respiratory tract. Tongue lesions have also been noted by Sherman and Munsell (1925)⁸ who found

them in seventy-six per cent of rats on a diet deficient in vitamin A. The antirachitic potency was not considered in their experimental diet. According to Osborne and Mendel (1917)^{9, 10} and Van Leersum (1928)¹¹ there is a high incidence of urolithiasis in rats deprived of vitamin A. In Van Leersum's experience accompanying infection of the kidney is uncommon.

All workers thus far are in accord in finding epithelial metaplasia to be present in vitamin A deficiency. There is still some question about the rôle of infection in the early stages of the epithelial transformation. A satisfactory correlation of the appearance of xerophthalmia with the occurrence of lesions elsewhere in the body has not been made. The order in which the several parts of the body are affected has not been established, and the sequence of events, if the deficient diet is corrected, has not been adequately described. It is therefore of interest to investigate these phases of the question with a view to correlating the sequence of events with respect to the age and weight of the animal, the relation of xerophthalmia to the appearance of other lesions in the body and the effect of correcting the deficient diet.

EXPERIMENTAL PROCEDURES

Animals and Diet: White (albino) rats were used in this experiment. They were of the strain of the Connecticut Agricultural Experiment Station and were bred in the laboratory. The special diets were started as soon as the animals were at the age of 21 to 24 days. The rats were kept in individual wire cages which were supplied with false bottoms, thus preventing coprophagy. The cages and food cups were kept scrupulously clean and each cage was sterilized with steam once a week.

Individuals from each litter were divided into four groups. Group I comprised animals which were to be observed early in the course of the experiment. In Group II were those which were to be allowed to develop outspoken vitamin A deficiency or to die of the disease. The animals in Group III were to develop symptoms of vitamin A deficiency and were then to be placed on a corrected diet. Group IV comprised the positive control rats. All animals were weighed at least twice a week and sometimes every day. The food intake was determined every four days.

The diet consisted of the following:

Extracted Casein *	18 per cent
Cornstarch	51 per cent
Crisco	27 per cent
Salt Mixture (Osborne and Mendel)	4 per cent

The Crisco was melted and the other constituents thoroughly mixed with it. When allowed to cool the food was of a pasty consistency which prevented spilling. This mixture was given the rats *ad libitum*. Vitamin B was provided by giving 200 mg. daily of dried yeast which was placed in a separate dish. For vitamin D a quantity of dried yeast was irradiated under a mercury vapor lamp for one-half hour at a distance of one foot, Hess (1927).¹² Two hundred milligrams of this were fed every day. Vitamin C was lacking in the diet but it has been shown by Parsons (1920),¹³ by Parsons and Hutton (1924),¹⁴ and by Lepkovsky and Nelson (1924)¹⁵ that the absence of this factor in the diet has no effect on the rat. The drinking water was distilled. In addition to this diet the animals in Group IV received 10 drops of cod liver oil (Squibb) each day.

Histological Technique: All tissues were fixed in 10 per cent formalin and mounted in paraffin. Hematoxylin and eosin stains were made routinely and in addition Gram and connective tissue preparations were used occasionally.

The accessory salivary glands at the base of the tongue, the submaxillary gland, the trachea and bronchi and the renal pelvis were studied in all cases. The base of the tongue has received particular attention as the lesions occur more uniformly in this region, and because of its size it is possible to make a more complete study of the tongue. Accordingly, five blocks of the tongue were mounted in each case, and from each of the blocks two to six microscopic sections were made. From the other areas one or two blocks were mounted.

RESULTS

Clinical Course and Gross Findings: The animals on the deficient diet gained steadily for a time but always less rapidly than the control rats in the same litter. Xerophthalmia appeared on an average when the rat had been on the diet forty days, though the extremes

* 95 per cent alcohol for 2 hours; ether, 2 hours; ether, 1 hour. Dried in oven at 105° C for 48 hours.

were twenty-seven and fifty days. The sequence of events in the development of xerophthalmia were: first, a slight swelling of the eyelids accompanied by photophobia (slit-like eyes); second, a clear discharge from the eyes which sometimes became blood-tinged; third, drying of the eyes, the lids becoming glued together and the eyeball appearing to sink into its socket. Occasionally corneal ulceration and hypopyon developed. Anterior staphyloma occurred in one case.

The appearance of xerophthalmia in relation to weight loss was variable. Sometimes eye changes appeared before there was any loss of weight. Again, several grams of body weight would be lost before eye changes became manifest. Occasionally xerophthalmia appeared and the body weight continued to increase and reached a maximum level several days later. The most usual sequence was an increase in weight to a point where it remained stationary for two or three days, then, appearance of xerophthalmia and rapid decline in weight. In Group I the animals were sacrificed early in the course of the deficiency. Some were killed when a few grams of weight had been lost, others when weight had been lost and the very earliest eye changes were observed. Rat 12 was killed before any changes were observed and Rat 26 had had xerophthalmia for six days when it was sacrificed. At autopsy no gross lesions were noted in the animals in this group. In Group II all the animals had varying degrees of xerophthalmia. All showed great emaciation and every rat had abscesses at the base of the tongue from which pus could be expressed. The latter lesions probably cause pain on swallowing and may account for the terminal falling off of food intake as is suggested by Goldblatt and Benischek. The tongue and eye lesions were the only constant gross findings. The submaxillary gland was often atrophied and occasionally contained abscesses. Urinary calculi were found in some cases and where obstruction occurred pyonephrosis was present.

The animals in Group III were allowed to develop xerophthalmia, and after several days when the eye changes were outspoken and considerable weight had been lost, cod liver oil was given. Often the rats were so weak that the oil had to be given by dropper. As a rule the response to diet correction was rapid. The xerophthalmia disappeared in from one to five days and the weight curve rose abruptly. Half the animals planned for this group could not be used as compli-

cations caused the death of the rat in spite of treatment. However, Rat 7 gained weight rapidly and was apparently well when autopsy revealed an extensive unilateral pyonephrosis. Rat 18 was allowed to develop xerophthalmia twice. The second time cod liver oil did not cure, as a pyonephrosis and perinephritic abscess were present. Following cod liver oil administration the rats were sacrificed at varying intervals. In the oldest cases no gross lesions were visible except in Rat 7. In those killed soon after cod liver oil was given, tongue lesions were present.

When cod liver oil was provided from the start (Group IV) the animals gained weight rapidly, and showed no gross evidence of disease whatever even after as much as one hundred and forty-four days of the diet.

Histological Findings: The earliest changes (Table I) are found in the salivary glands at the base of the tongue. These changes consist in dilatation of the main ducts with metaplasia of the duct epithelium to the squamous keratinizing type. Infection is always present even in the earliest detectable lesion and is often found in parts of the tongue where keratinization has not appeared. The infection is characterized by a polymorphonuclear leukocytic exudate and by necrosis of the acinar epithelium.

The serous type of gland is always affected before the mucous type in the tongue, and advanced destruction of the former is always present before the latter shows definite abnormalities. The submaxillary gland is affected after the tongue has developed outspoken changes. In the submaxillary gland the same sequence of events is noted, namely, dilatation and epithelial metaplasia of the main ducts, accompanied by infection. In both the tongue and submaxillary glands it is frequently noted that only slight metaplastic changes are present while the glands are diffusely infiltrated with polymorphonuclear leukocytes. In every case the dilated ducts are filled with these cells.

Changes in the trachea, bronchi and renal pelvis follow those in the tongue and submaxillary gland. Alterations in the trachea and bronchi are inconstant. The first change is an atrophy of the surface epithelium. This is followed by a dilatation of the ducts of the glands which are filled with polymorphonuclear leukocytes. Changes in the epithelium of the renal pelvis are sometimes observed before those in the respiratory tract. The earliest alterations consist of a

TABLE I
Group I — Basal D₄₄

Number of rat	Initial weight gm.	Maximum weight gm.	Final weight gm.	Days on diet	Eyes at death	Histological Findings				
						Tongue	Submaxillary gland	Trachea	Bronchi	Renal pelvis
12.....	46	150	150	47	Normal	Normal	Normal	Normal	Normal	Normal
20.....	36	112	110	45	Normal	Normal	Normal	Normal	Normal	Normal
21.....	38	92	86	45	Watery discharge for one day	Early metaplasia Infection	Normal	Normal	Normal	Normal
10.....	46	132	124	51	Watery discharge for one day	Early metaplasia Infection	Few leukocytes in ducts	Atrophy of epithellum	Normal	Normal
23.....	32	102	92	49	Discharge for six days	Marked metaplasia and infection	Duct metaplasia and infection	Normal	Normal	Metaplasia Infection

piling up of the epithelium and an infiltration of polymorphonuclear leukocytes in the subepithelial tissues.

As the disease advances the ducts of the lingual glands dilate more and more, and the infection progresses so that in animals which die of vitamin A deficiency (Table II) the serous glands of the tongue are entirely destroyed by pressure and by infection, with the result that all that can be seen are large abscesses lined by squamous epithelium and filled with polymorphonuclear leukocytes, keratin and necrotic débris. In all advanced cases the epithelial lining of the abscesses is deficient at several points and the surrounding muscle is heavily infiltrated with polymorphonuclear leukocytes and shows extensive necrosis. Gram stains show the abscesses to contain large masses of bacteria in which Gram-positive cocci predominate. In these late cases the submaxillary gland is nearly always involved though occasionally no change other than atrophy is noted. The most frequent finding is large epithelium-lined spaces filled with polymorphonuclear leukocytes while the rest of the gland is diffusely infiltrated with the cells. It is a picture similar to that in the tongue. In a few instances the entire submaxillary gland is converted into an abscess.

The late manifestations in the trachea and bronchi are not uniform as the changes vary all the way from simple atrophy to metaplasia of the surface epithelium and cyst formation in the glands with extensive infection of the surrounding tissue. The epithelium of the renal pelvis is always involved in the late cases. Here the epithelial layer is deeper, keratinization is marked and in some instances the entire renal pelvis is filled with keratin and leukocytes. In several cases calculi blocked the urinary outflow in either the bladder or ureter with the development of pyoureter and pyonephrosis. Two instances of perinephritic abscess developed following rupture of obstructed ureters. The tendency toward hyperplastic activity of the epithelium which has undergone transformation to the squamous type is noted by Wolbach and Howe (1925).⁶ This is sometimes very striking and occurs with particular frequency in the tongue and renal pelvis. In the tongue the circle of epithelium surrounding one of the abscesses may be very broad and the outer layers often contain mitotic figures. Occasionally long, finger-like epithelial processes extend into the surrounding tissue and with distortion due to infection the picture may be one difficult to distinguish from malignancy.

TABLE II
Group II — Basal Diet

Number of rat	Initial weight gm.	Maximum weight gm.	Final weight gm.	Days on diet	Eyes at death	Histological Findings				
						Tongue	Submaxillary gland	Trachea	Bronchi	Renal pelvis
14.....	35	102	74	42	Xerophthalmia	Metaplasia Abscess	Normal	Atrophy of epithelium	Atrophy of epithelium	Metaplasia Pyonephritis
2.....	36	107	94	48	Xerophthalmia Hypopyon	Metaplasia Abscess	Slight metaplasia. Slight infection	Metaplasia Infection	Metaplasia Infection	Slight metaplasia Infection
8.....	44	88	72	56	Xerophthalmia	Metaplasia Abscess	Atrophy	Normal	Normal	Early metaplasia Infection
3.....	38	96	82	57	Xerophthalmia Hypopyon	Metaplasia Abscess	Slight metaplasia Infection	Atrophy of epithelium	Atrophy of epithelium	Metaplasia Infection
6.....	45	110	82	61	Xerophthalmia	Metaplasia Abscess	Early metaplasia Infection	Atrophy of epithelium	Normal	Metaplasia Infection
27.....	32	92	68	63	Xerophthalmia	Metaplasia Abscess	Metaplasia Abscess	Atrophy of epithelium	Normal	Metaplasia Pyonephrosis
4.....	45	126	80	75	Xerophthalmia Corneal ulceration	Metaplasia Abscess	Metaplasia Abscess	Atrophy of epithelium	Atrophy of epithelium	Metaplasia Infection

TABLE III
 Group III — Basal Diet + Cod Liver Oil after Ophthalmia and Loss in Weight

Num- ber of rat	Initial weight gm.	Maxi- mum weight before oil gm.	Weight when oil given gm.	Days on oil	Eyes at death	Histological Findings				
						Tongue	Submaxillary gland	Trachea	Bronchi	Renal pelvis
17....	33	120	106	4	Normal	Metaplasia Abscess Fibrosis regeneration	Metaplasia of ducts. Infection	Normal	Normal	Hyperplasia Infection
25....	30	56	56	14	Normal	Metaplasia Small abscess Fibrosis	Normal	Normal	Normal	Hyperplasia Infection
18....	36	116	98	5	Xeroph- thalmia	Metaplasia Abscess	Abscess	Normal	Normal	Metaplasia Pyonephrosis Perinephritic abscess
13....	49	112	112	56	Normal	Normal	Normal	Slight infection	Peribronchial fibrosis	Infection
7....	44	124	88	91	Normal	Slight meta- plasia Chronic infection	Normal	Normal	Peribronchial fibrosis	Pyonephrosis Perinephritic abscess

In the renal pelvis the hyperplastic changes always overshadow the keratinization. The lining epithelium becomes piled up into a broad layer and columns or sheets of epithelial cells extend into the sub-epithelial tissue.

After the administration of cod liver oil to rats which have developed xerophthalmia (Table III) the healing process depends upon the extent of destruction of the particular portion by the infectious

TABLE IV

Group IV — Basal Diet + Cod Liver Oil from Beginning

Number of rat	Initial weight	Maximum weight	Final weight	Days on diet	Lesions
	gm.	gm.	gm.	gm.	
24.....	30	144	144	47	None
22.....	30	110	110	49	None
19.....	33	152	152	49	None
9.....	47	166	166	51	None
26.....	30	140	140	65	None
1.....	47	212	212	73	Bronchitis; bronchopneumonia
15.....	38	152	126	100	None
5.....	46	170	170	106	None
11.....	40	214	200	144	None

process. In the tongue there may be almost complete regeneration of the glandular epithelium with only a few scarred areas remaining. The submaxillary gland often shows no evidence of previous damage. The trachea and bronchi may appear perfectly normal though there is usually some fibrosis of the surrounding tissue. The epithelium of the renal pelvis has shown evidence of hyperplasia with keratinization and infection as long as ninety-one days after the animal has gained weight and is apparently well. The usual picture for as much as two weeks after correction of the diet is the persistence of infection and abnormal epithelium in the tongue and kidney and apparently normal epithelium in the trachea and bronchi. At this

stage there is usually extensive fibroblastic activity and round cell infiltration surrounding the tongue abscesses with evidence of epithelial regeneration in less severely affected portions of the gland. In one animal the only evidence of previous damage to the tongue is a collection of small round cells and endothelial leukocytes replacing part of one of the lobules of the lingual gland.

The control animals (Table IV) were all well nourished at the time of autopsy. The sections from one rat show slight bronchitis and bronchopneumonia. No other abnormal findings were observed in any of the rats in this group.

The tissue changes in the various structures studied have been correlated with age and weight changes and are summarized in the four tables.

SUMMARY

The principal changes associated with vitamin A deficiency in rats are a metaplasia of cuboidal or columnar epithelium in certain parts of the body, epithelial hyperplasia in various structures and infection.

The metaplastic changes involve the following structures in order: the sublingual glands, the submaxillary glands, the epithelium of the renal pelvis and of the trachea and bronchi. The tongue is regularly involved before xerophthalmia appears. The serous type of sublingual gland is the first to be affected. The lesion in the tongue and submaxillary gland begins with a dilatation of the ducts and a metaplasia of the lining epithelium accompanied by infection. In late cases the glandular tissue may be entirely destroyed by pressure from the dilated ducts and by necrosis due to infection. The submaxillary gland is not involved as constantly as the tongue. The epithelium of the renal pelvis may be involved quite early. Metaplasia and infection are always present in the advanced cases. Renal calculi are prone to occur and when obstruction to the urinary outflow is present pyonephrosis develops which is sometimes followed by perinephritic abscess. Epithelial metaplasia of the trachea and bronchi is not common. The most usual finding is an atrophy of the lining cells.

Epithelial hyperplasia is striking in the tongue and renal pelvis. In the latter the hyperplasia overshadows the keratinizing process.

Infection is always present even in the earliest stages and in late cases dominates the picture. No metaplastic activity has been seen without an accompanying infection, but infection has been observed in parts where metaplasia is absent.

If the results of the dietary deficiency are not too severe, xerophthalmia clears rapidly with the administration of cod liver oil and the weight curve rises abruptly. The extent of healing in the various organs depends largely upon the amount of destruction due to infection which is present. Following cod liver oil administration abnormal epithelium and chronic or acute infection persist in the tongue and renal pelvis when the rat is apparently healthy.

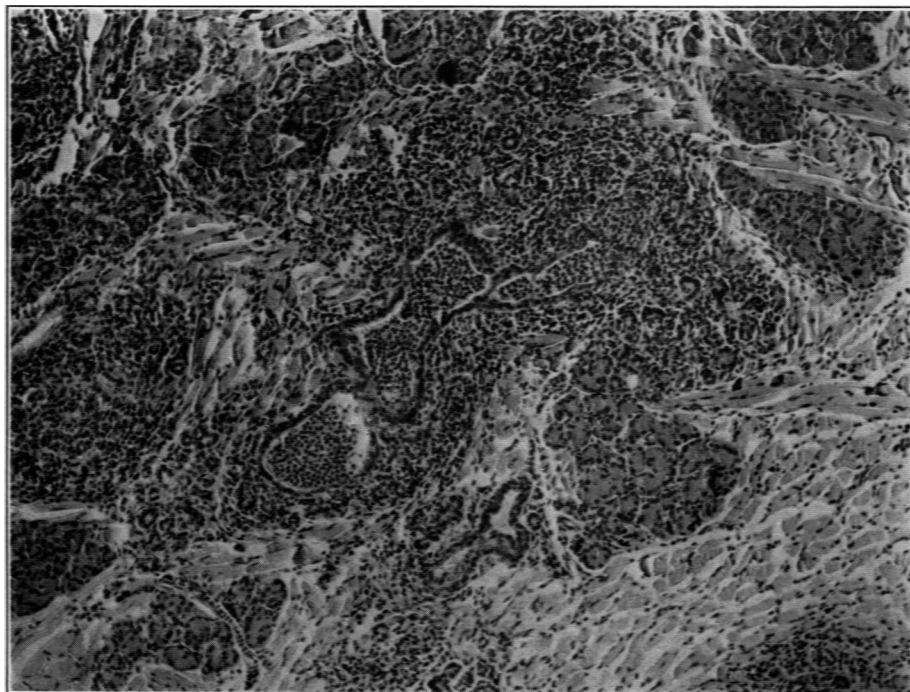
REFERENCES

1. Osborne, T. B., and Mendel, L. B. *J. Biol. Chem.*, 1913, xvi, 423.
2. Mori, S. *Bull. Johns Hopkins Hosp.*, 1922, xxxiii, 357.
3. Yudkin, A. M., and Lambert, R. A. *J. Exper. Med.*, 1923, xxxviii, 17.
4. Lambert, R. A., and Yudkin, A. M. *J. Exper. Med.*, 1923, xxxviii, 25.
5. Wason, I. M. *J. A. M. A.*, 1921, lxxvi, 908.
6. Wolbach, S. B., and Howe, P. R. *J. Exper. Med.*, 1925, xliii, 753.
7. Goldblatt, H., and Benischek, M. *J. Exper. Med.*, 1927, xlvi, 699.
8. Sherman, H. C., and Munsell, H. E. *J. Am. Chem. Soc.*, 1925, xlvii, 1639.
9. Osborne, T. B., and Mendel, L. B. *J. A. M. A.*, 1917, lxi, 32.
10. Osborne, T. B., and Mendel, L. B. *J. Biol. Chem.*, 1919, xxxvii, 557.
11. Van Leersum, E. C. *J. Biol. Chem.*, 1928, lxxvi, 137.
12. Hess, A. F. *J. A. M. A.*, 1927, lxxxix, 337.
13. Parsons, H. T. *J. Biol. Chem.*, 1920, xlv, 587.
14. Parsons, H. T., and Hutton, M. K. *J. Biol. Chem.*, 1924, lix, 97.
15. Lepkovsky, S., and Nelson, M. T. *J. Biol. Chem.*, 1924, lix, 91.

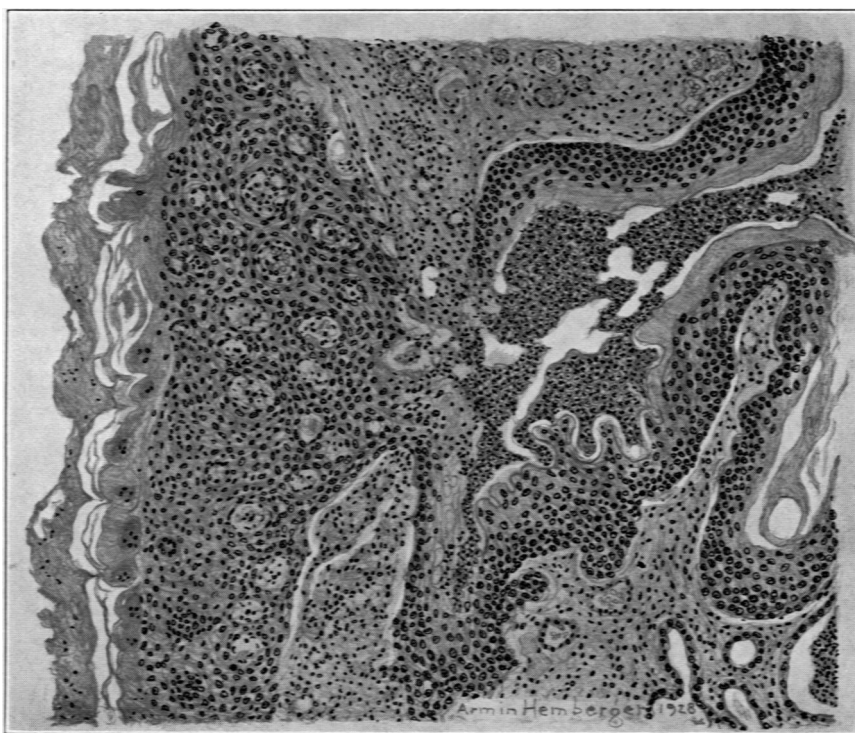DESCRIPTION OF PLATES

PLATE 17

- FIG. 1. Rat 21. Serous portion of sublingual gland. Early lesion. Dilatation of ducts with metaplasia of the lining epithelium. Polymorphonuclear leukocytic exudate in ducts and adjacent glandular tissue. $\times 125$.
- FIG. 2. Rat 6. Cross-section of tongue. Advanced lesion. Great dilatation of ducts with epithelial metaplasia. Exudate in ducts and surrounding muscle. Necrosis of muscle and supporting tissue. Hyperplasia of the surface epithelium. Drawing $\times 1150$.



1

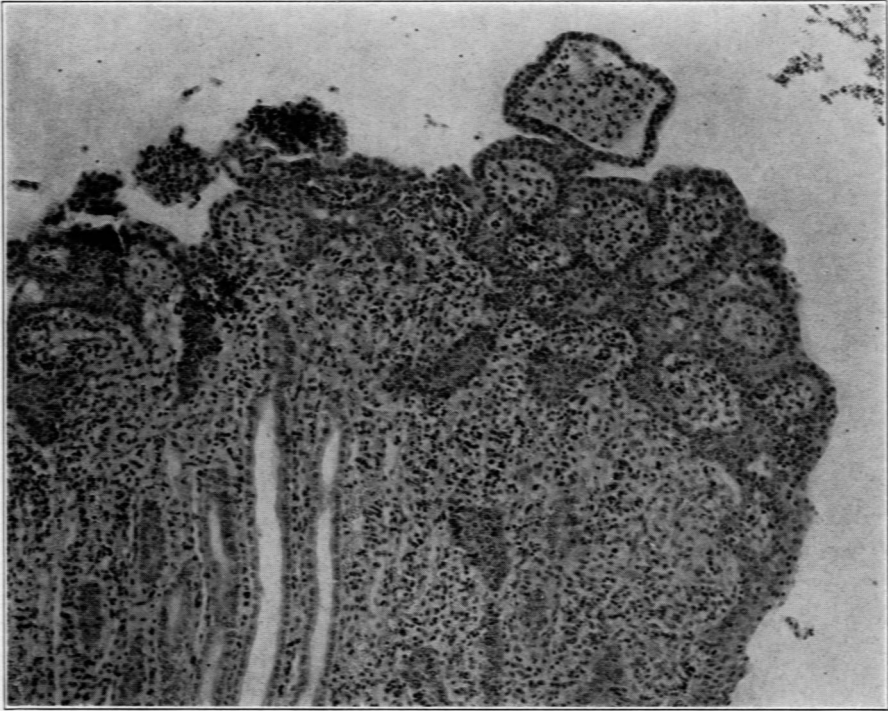


2

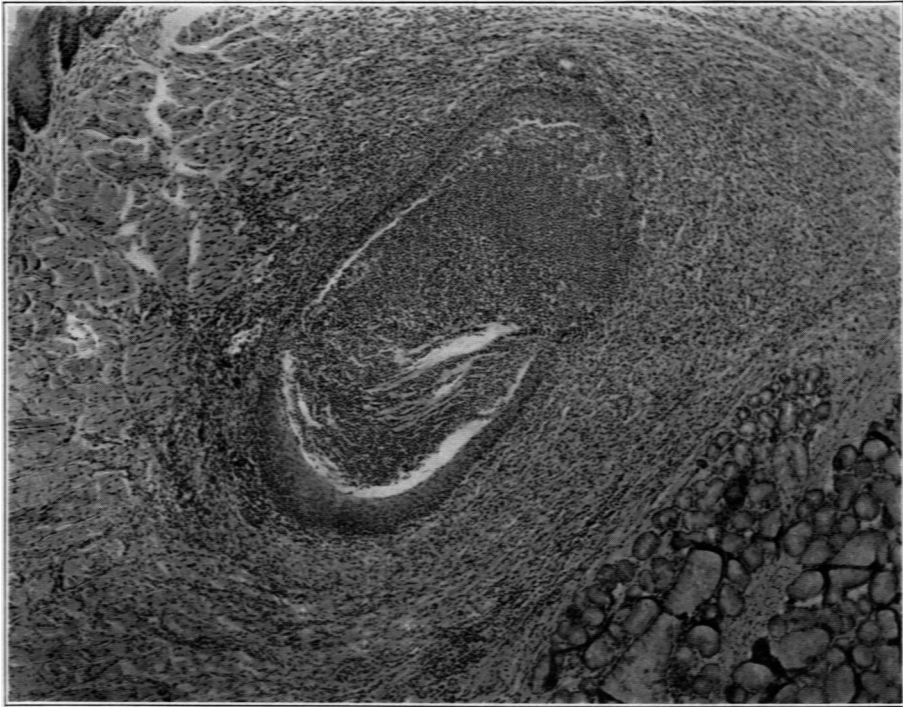
Plate 18

FIG. 3. Rat 25. Hyperplasia of epithelium of renal pelvis. Exudate in epithelial layer and subepithelial tissues. $\times 125$.

FIG. 4. Rat 25. Abscess of tongue partly lined by metaplastic epithelium. Keratosis not marked. Extensive fibroblastic activity surrounding the abscess. $\times 65$.



3



4