

CHEMICAL CONTRASTS BETWEEN COLLAGENOUS AND RETICULAR CONNECTIVE TISSUE*

NATHAN CHANDLER FOOT

*(From the Department of Pathology, College of Medicine, University of Cincinnati and
Cincinnati General Hospital, Cincinnati, Ohio)*

INTRODUCTION

It is now some thirty years since Mall¹ first described reticular tissue and differentiated it from the collagenous by means of tryptic digestion; it is almost twenty since a number of German investigators popularized the Bielschowsky-Maresch technic of impregnating reticulum with silver salts and studied its distribution. In spite of this, very little is known as to the chemical nature of collagen and reticulin. Shortly after Mall published his work, Siegfried² made a chemical analysis of the residue of pigs' intestinal submucosa after subjecting it to tryptic digestion and obtained the substance he named "reticulin." Mall had noted that reticular tissue did not yield gelatin on boiling with water and that it was more resistant to tryptic digestion than was collagen; he differentiated the two on the basis of these peculiarities and upon their morphological dissimilarity. Young³ contradicted Mall's contention, stating that the two substances were chemically identical as they both yielded gels after extraction with hot water. Siegfried, in turn, found that, although a substance resembling gelatin could be obtained by boiling reticulum in water, this was not true gelatin, but something more labile and more readily extracted; furthermore, there was a residue that could be precipitated with ammonium acetate or common salt, a grayish powder, his "reticulin." The gelatinoid material was obtainable after a short period of boiling, formed a firm gel, but differed from gelatin in that it yielded a heavy precipitate with acetic acid, formed no glutamic acid after boiling with hydrochloric acid for seventy-two hours, and contained phosphorus, which is absent in pure collagen and gelatin. Hammarsten⁴ gives the following composition for tendon collagen and reticulin, the latter being cited from Siegfried's paper:

* Received for publication June 9, 1928.

Reticulin: C, 52.88; H, 6.97; N, 15.63; S, 1.88; P, 0.34.

Collagen: C, 50.75; H, 6.47; N, 17.87; S, 0.57; P, none.

Siegfried's work was challenged in 1902 by Miss Tebb,⁵ working under Halliburton, and her paper elicited an answering article from Siegfried⁶ in the same journal and the same year. He had performed additional experiments to reinforce his statements and devised a more rapid method for isolating reticulin, by boiling the tissue in 0.05 per cent hydrochloric acid. His ideas have been accepted by Hammarsten and by Robertson⁷ and are quoted in their respective text-books. Abderhalden,⁸ on the other hand, contents himself with the mere statement that reticulin is probably an altered form of collagen, less readily convertible into gelatin, thus admitting a chemical difference between the two, but reversing Siegfried's opinion as to the ease with which reticulin is converted into gelatin.

It is difficult to find any definite statements on this subject, even in recently published text-books, although it is probable that much might be found in the voluminous literature on leather and glue research, could one but sift out the more fundamental articles from those of a technical or commercial type. Indeed, the subject seems to elicit very little curiosity in the minds of those who deal with these two connective tissue components.

In the realm of histology and histopathology, the question has been equally slighted; Strong and Elwyn's⁹ latest edition of Bailey's text-book and Prentiss and Arey's¹⁰ Text-Book of Embryology merely state that reticulum differs from collagen in its resistance to peptic digestion and in its staining reactions. The histological text-book mentions the possibility of reticulin's being a precursor of collagen. Miller,¹¹ in his study of the pulmonary reticulum, has said that this is a probability and, in subsequent publications and private conversation, has adhered to this belief. That reticulum is of a somewhat different chemical composition from collagen has been generally assumed by investigators of reticular tissue, but the very close relationship between collagen, reticulin and elastin has always been kept in mind.

Last year, Mallory and Parker¹² seriously questioned any chemical difference between collagen and reticulin; they consider that the silver method is incapable of differentiating two chemically unlike groups of fibers — it merely impregnates those that are readily accessible to the silver bath and fails to penetrate the denser, closely

felted and hence inaccessible bundles of collagen. They conclude: "Reticulum as a chemically distinct intercellular substance does not exist; it is collagen in separated form, rendered prominent by the silver stain." This statement, if generally accepted, closes the door on any further discussion of the subject; it is the purpose of this paper to prevent this by showing that there are chemical differences between reticulin and collagen and that they present a fertile field of investigation to the biochemist. So far as ascertainable, no one has attempted to link the biochemical with the microchemical method of attacking this problem, and it is proposed, in the following report, to do just that. The work will be divided into an histological and a biochemical section and the two will be correlated in the discussion; the spleen has been chosen as the organ of election for this undertaking, other organs being used for confirmatory and secondary objects of investigation.

HISTOLOGICAL SECTION

TECHNICAL METHODS

Methods of Fixation: 10 per cent neutral formalin (4 per cent formaldehyde); 10 per cent formalin with 0.5 per cent HCl and 0.5 per cent NaOH (to test out acid and alkaline fixation); Zenker's fluid; Bouin's fluid; absolute alcohol, acetone and ether (respectively); coagulation with boiling water and alcohol.

Sections: Paraffin embedding was used as a routine, although frozen sections were employed in part of the investigation and celloidin was used in the case of the Bouin-fixed tissue and frequently flooded over sections to prevent their becoming detached from the slides.

Impregnations and Stains: The Hortega silver-ammonium carbonate method was used as a routine impregnation, either alone or with a counterstain of Harris' hematoxylin and Van Gieson's stain.

Directions for Impregnating: Wash the deparaffinized sections in distilled water, after removing mercuric chloride with alcoholic iodine and hypo, in the usual manner. Chromium salts may be removed with KMnO_4 and COOH_2 (see later). After washing in distilled water, impregnate the sections for 15 minutes in a silver-ammonium carbonate bath which is made up as follows: to 10 cc. 10 per cent AgNO_3 , add 40 cc. 5 per cent Na_2CO_3 ; allow the white precipitate to settle, decant the supernatant fluid, wash with distilled water and

redecant, dissolving the precipitate by adding, drop by drop, just enough strong NH_4OH to put it almost into solution, leaving five or six gray granules undissolved; make up to 100 cc. with distilled water. Although the impregnation may be carried out in the cold, it is more satisfactory to warm the bath to the steaming point, driving off the excess NH_3 , and cool to 50°C . Then place in an incubator at 37°C , or thereabout, for 15 minutes.

Wash the sections in two or more changes of distilled water and reduce them with 1 per cent formalin, for two minutes. Wash at the tap and tone for two minutes in 1:500 aqueous AuCl , which tends to render the impregnation more precise and converts the yellowish brown collagen into grayish pink, or old rose. After washing, the sections are treated with 5 per cent hypo ($\text{Na}_2\text{S}_2\text{O}_3$) to remove excess silver or gold. The process depends upon the impregnation of the tissue by the double salt of silver and ammonia and its conversion, probably by reduction, into a black compound. That the double salt is silver-ammonium oxide, rather than silver-ammonium carbonate, is probable. It is usually advantageous to counterstain the sections for five minutes in Harris' hematoxylin followed by forty-five seconds in Van Gieson's picric acid-acid fuchsin solution, with a wash between. The sections should be run directly into ascending strengths of alcohol, otherwise water will decolorize the acid fuchsin. Van Gieson's solution is best made up of 10 per cent of 1 per cent aqueous acid fuchsin to 90 per cent of picric acid, water saturated at room temperature.

Staining Characteristics: The simple, untuned impregnation colors reticulum black, collagen yellowish brown; toned with gold chloride, the reticulum is still black, the collagen grayish pink to old rose; counterstained with Van Gieson, the reticulum is unaffected, while the collagen becomes bright vermilion. If the reticulum be unimpregnated with silver salts, it will stain rose-red with Van Gieson's solution.

Other Silver Methods: Another Hortega "variant," in which saturated Li_2CO_3 replaces the Na_2CO_3 ; the Bielschowsky-Maresch silver-ammonium oxide method, as modified by Mènard and myself;¹³ the Achucarro silver tannate method (Foot¹⁴) and some minor modifications of these were all employed as controls. No marked difference could be detected between these and the routine procedure, while many of them are more laborious and complicated. It may be said,

however, that the modified Bielschowsky-Maresch method gives the most reliable and clean-cut pictures, if one wish to devote the time to it.

HISTOLOGICAL EXPERIMENTS

Effects of Fixation: It was found that, of the fixatives mentioned, only one made any marked difference in the resulting impregnation: absolute alcohol prevented the blackening of the reticulum fibers almost completely; all the other fixatives gave good results and acted very similarly. In order to determine why absolute alcohol should inhibit the impregnation, a set of simple experiments, aimed at lipin extraction, were performed.

Unfixed Frozen Sections: Fresh spleen was cut on the freezing microtome and treated by the routine method; no impregnation of the reticulum or collagen resulted, although the refractile fibers were clearly visible.

Alcohol-Fixed Frozen Sections: Sections of fresh spleen were then soaked in absolute alcohol and ether for two hours, after which they were fixed to slides with celloidin and took the usual impregnation (Fig. 1). Where the sections were thin, the reticulum seemed broken up and the argyrophil material was diffused through the tissue; where they were thick, the impregnation was satisfactory. Next, sections were soaked in this mixture over night and treated as usual; the reticulum no longer became impregnated, there were a few black beads and clumps of reduced silver (Fig. 2). To test the fixation, sections were stained with hematoxylin-Van Gieson, with good success.

Paraffin Sections: Tissue fixed in ether, absolute alcohol, absolute acetone and 5 per cent NaOH was subsequently fixed in 10 per cent neutral formalin and embedded in paraffin. The sections from this material became impregnated very much in the usual way, excepting in the case of spleen treated with NaOH, in which the reticulum failed to become black; the collagen was unaffected. This rules out the possible extraction of lipins that might combine with the silver as a factor in the failure of alcohol-fixed tissue to become impregnated, for all these fluids are fat solvents. Some other explanation must, therefore, be sought.

Fixation in Boiling Water or Alcohol: Boiling water was used as one of the types of fixation to be tested, but it proved more interest-

ing as an extractor. Thin blocks of spleen were boiled for 4.5 hours under a reflux condenser in distilled water; half of them were then removed and run into paraffin, the remaining half being again boiled for the same length of time in absolute alcohol. To avoid injuring the knife on these bone-hard blocks, they were softened over night in 80 per cent alcohol three parts, to glycerol one part. This rendered them soft and they cut more easily than the water-boiled blocks.

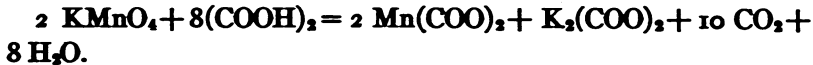
The following changes were noted in sections from these two lots of tissue after impregnation: in the water-boiled spleen the reticulum was clumped into swollen, somewhat dendritic masses of black material (Fig. 3), occupying the normal site of that tissue. The collagen was *quite unstained*, a counterstain with Van Gieson's solution brought out a faint roseate tinge in the capsule and trabeculae, but the bright vermilion was no longer forthcoming. The elastic tissue now appeared as isolated, sinuous strands; if the impregnation were preceded by treatment with the oxidizing mixture (KMnO_4) + $(\text{COOH})_2$ these took on a brilliant orange. Sections from the alcohol-boiled spleen were quite similar to those fixed in cold absolute alcohol.

EFFECT OF OXIDIZING AND REDUCING AGENTS UPON THE IMPREGNATION OF RETICULUM

I have noticed, in experimenting with silver impregnations of brain tissue, that the process was definitely affected by previous treatment with oxidizing and reducing agents. Ménard, in this laboratory, and the technicians at the U. S. Army Medical Museum at Washington (personal communication) have found that reticulum will impregnate better if first treated with permanganate of potash and oxalic acid. As this might depend upon (a) oxidation, (b) a salt of manganese, (c) oxalic acid, both oxidizing and reducing agents; a manganese salt and oxalic acid alone were applied to reticular tissue fixed in a variety of ways (see "*Fixation*") in order to ascertain what differences would result.

(A) *Oxidizing Agents*: KMnO_4 , 0.25 per cent, for five minutes, followed by oxalic acid [$(\text{COOH})_2$] for ten, was first tested. The reticular impregnation was sharply intensified; fibers not demonstrable after simple formalin fixation (Fig. 4) became black and clear-cut after "oxidizing" (Fig. 5). These photomicrographs were from serial sections from the same block of tissue. The treated section

showed fibers that were somewhat stouter than those in the controls, the collagen was pinkish, if not counterstained with fuchsin, somewhat lighter than the controls if this were used; the cytoplasm and nuclei became paler and insignificant, which is an advantage — for they may then be better counterstained with organic dyes. The same feature was demonstrable with Zenker-fixed material; the untreated controls showed somewhat sharper impregnation of the reticulum than did the formalin-fixed controls, and the cytoplasm was brownish as a result of the formation of silver chromate; the “oxidized” sections showed sharper impregnation of the reticulum and markedly inhibited impregnation of the cytoplasm and nuclei. It is this fact that makes our (Foot,¹² Foot and Ménard¹³) modifications of the Hortega method peculiarly adapted for use with routine, Zenker-fixed material. In Bouin-fixed spleen, the results were materially the same, but after alcohol fixation, the impregnation of the reticulum was always slight, although the counterstain took very well. Subsequent fixation of alcohol-fixed tissue in 10 per cent formalin rendered the tissue suitable for first-rate silver impregnation. The reaction involved in the permanganate-oxalic acid treatment does not indicate oxidation on the face of it, as will be seen from the following:



Other Oxidizing Agents: Sections were treated respectively with commercial peroxide of hydrogen, acidified KClO_3 (1 per cent with 0.5 per cent HCl) and 30 per cent NaNO_2 with HCl to acidity. They were then impregnated as usual, always with untreated sections as controls in each lot. The reticulum was no better, if as well impregnated in the oxidized sections, although the nuclei were more sharply and precisely demonstrated. This would seemingly point away from oxidation as a factor in the improvement seen after the KMnO_4 — $(\text{COOH})_2$ treatment, but it might depend upon the more feeble oxidizing power of these reagents.

(B) *Potassium Permanganate Alone:* This was tried alone in 0.25 per cent concentration for five minutes. After impregnation, as compared with untreated controls, the manganated sections were much better, but rather spotty and filled with a brownish deposit from the manganese salts; the reticulum was, on the whole, more sharply impregnated. As the silver-bath contains NH_4OH , this

would oxidize the KMnO_4 as follows: $2 \text{KMnO}_4 + 2 \text{NH}_4\text{OH} = 2\text{K} \cdot \text{NH}_4\text{MnO}_4 + \text{H}_2\text{O} + \text{Oxygen}$; continuing: $2 \text{K} \cdot \text{NH}_4\text{MnO}_4 + 2 \text{H}_2\text{O} = 2 \text{MnO}_2 + 2 \text{KOH} + 2 \text{NH}_4\text{OH} + 2 \text{Oxygens}$. This, then, may be construed as a true oxidation.

Potassium Permanganate and Hydrochloric Acid: In order to test out a more powerful oxidizing combination, KMnO_4 was used as usual and followed by ten minutes in from 1 per cent to 3 per cent HCl . The reaction here is: $2 \text{KMnO}_4 + 6 \text{HCl} = 2 \text{MnCl}_2 + 3 \text{H}_2\text{O} + 5 \text{Oxygens}$. The permanganate was not bleached out of the sections by the HCl as it was by the $(\text{COOH})_2$, and the resulting impregnations were very dense. The reticulum was probably even better blackened than in the oxalic acid technic, but the background was so intensely impregnated that the contrast was very slight and the reticulum obscured. Compare Figs. 6 and 7, made from the same block, the former with oxalic, the latter with hydrochloric, acid.

Inert Manganese Salt: It might be thought, in spite of this, that the superior results after KMnO_4 were due to the presence of the Mn ion, therefore sections were treated with $\text{KMnO}_4 + \text{HCl}$, as above, for a control and with MnCl_2 , followed by HCl . As compared with the controls, the MnCl_2 sections were vastly inferior, which would rule out the Mn ion as a controlling factor.

(C) *Oxalic Acid Alone:* As this is a constituent of the most successful method, it was used alone for 10 minutes in 5 per cent concentration. There was no impregnation of the reticulum, although it was well demonstrated in the controls. This should be compared with the results obtained with the reducing mixture, as given later on, for oxalic acid is a feeble reducer.

EFFECTS OF REDUCING AGENTS ON IMPREGNATION

A mixture of pyrogallol and NH_4Br , 0.5 per cent each and thiosulphate and sulphite of soda, 1 per cent each (in distilled water), was applied to sections for 15 minutes in warm solution before impregnating them with silver; this totally inhibited any impregnation of the reticulum (Fig. 8), except when absolute alcohol had been the fixative, when a partial impregnation (superior to untreated controls) resulted. The mixture of reducing agents was found to be superior to any one of them used separately. The function of the NH_4Br is not known; it possibly restrains the reduction, as in photography. While this is not striking proof, it at least strengthens the

assumption that the oxidation effected by KMnO_4 is the explanation of the improved impregnation following its use. (Cf. "*Oxalic Acid Alone.*") Alcohol-fixed tissue probably impregnates better after treatment with the reducing mixture for the same reason that it does after treatment with 10 per cent formalin, which is a reducer. The function of reduction and oxidation in this process must be further investigated; it is very bewildering.

EFFECT OF THE HYDROGEN ION CONCENTRATION OF THE FIXATIVE ON IMPREGNATION

As acids figure largely in the pretreatment of sections when KMnO_4 is used, it might be considered as the determining factor. Against this assumption is the unsuccessful impregnation after NaNO_2 and MnCl_2 , both of them followed by HCl. To strengthen this proof, sections were made from spleen fixed in 10 per cent formalin to which was added 0.5 per cent HCl in the one case, 0.5 per cent NaOH in the other. In both instances the sections became fairly well impregnated, but treatment with KMnO_4 and $(\text{COOH})_2$ produced the usual brilliant and superior impregnation; acidity or alkalinity of the fixative, therefore, appear to play no part in the process.

OTHER SILVER IMPREGNATIONS

The action of KMnO_4 and acid was found to improve the impregnation of sections by the Bielschowsky-Maresch technic, the Hortega Li_2CO_3 variant and the Achucarro silver tannate technic; the reducing mixture inhibited impregnation in all these methods.

REMARKS

All this indicates that it is best to treat sections with KMnO_4 before impregnating with silver. This should be followed by 5 per cent oxalic acid, if a light background suitable for counterstaining be desired; it should be followed by 1 per cent to 3 per cent HCl, if a denser impregnation is wanted and counterstaining is dispensed with. The great difficulty, in this method, is the liability of the sections becoming detached from the slides in the silver bath. This may be avoided (*a*) by careful drying of the mounted sections in the paraffin oven for forty-eight hours and a day or two at room temperature; (*b*) by driving off the excess NH_3 in the silver bath be-

fore impregnating, cooling to 50° C before the sections are immersed; (c) by removing the slides from the "descending absolute alcohol," after deparaffinizing in xylol, and flooding them with very thin celloidin (as in Mallory and Wright's frozen section technic), allowing this to set and continuing with the hydration, through 95 per cent alcohol.

BIOCHEMICAL SECTION

Preliminary Experiments: The first thing to do was to check up on Siegfried's original findings, therefore, splenic tissue was treated as he treated intestinal submucosa. Human spleen was used for two reasons — it contains more reticulum than most organs, has plenty of collagen for comparison and had been used in the experiments just recorded in the histological section. Spleens, fresh from the necropsy table, were ground in a meat mill, thoroughly washed in water, followed by several changes of distilled water and digested for two or three days with 0.25 per cent Parke, Davis & Co. pancreatin and 0.5 per cent NaHCO₃, in distilled water at 37° C. The solution was filtered off each day through a kitchen strainer, renewed, and toluol added to keep down putrefaction. Finally the tissue was washed in 0.05 per cent HCl and boiled in the same concentration of the acid under a reflux condenser for two or three hours. The connective tissue broke up into a muddy precipitate, mostly without going into complete solution, although there was considerable reprecipitation on adding NaCl.

The precipitate and broken-down tissue were dried by gentle heat and some of the material was fixed in formalin, run into paraffin and sectioned; when stained, the sections showed some unmistakable tissue-débris, bits of capsule, trabeculae, consolidated reticulum and the like (Fig. 8). The remainder was extracted with chloroform and alcohol, but the extracts were so crude that more exact methods were used later. Thus far the results bore out Siegfried's statements in many particulars; there was far more tissue débris than he described and the watery extract would not jell. Siegfried did not examine his reticulin with the silver method, which had not yet come into being, so it was imperative to use it here. The bits of capsule and trabeculae were found to contain argyrophil fibrils and there were clumps of black material adhering to their margins, evidently compacted reticulum. This stained blue with Nile blue

sulfate, showing that it was not blood, which is faintly greenish yellow with that dye. Extracted "reticulin" showed somewhat less argyrophil material when impregnated with silver salts. There was a good deal of elastic tissue in the residue, which was to be expected, as it is very resistant to tryptic digestion and weak acids.

Following this experiment, a dozen or more were run off, each one representing increased refinement in technic and giving somewhat different results. Over ten kilograms of spleen were thus treated. It was found best to slice the organ, rather than to grind it, cutting slices about 2 mm. thick. It was also found necessary to wash the material repeatedly after digestion, in distilled water, in order to get rid of the last traces of digested cellular material. This was best accomplished by rotating the splenic framework in a liter of water in a beaker, using a glass stirring-rod belted to a low speed motor.

All the vicissitudes of these experiments need not be recorded here, but it would be well to indicate that a bewildering number of substances were isolated in earlier trials, subsequent improvement in technic showing many of them to be impurities. Siegfried's "reticulin" was recovered by boiling the digested splenic framework in dilute HCl, as already noted, the "collagen" fraction being separated by tedious filtration. It was found, however, that the following method, in which the "reticulin" was completely dissolved in NaOH and reprecipitated by neutralization and salting out, gave the best yield of the two fractions and simplified their separation.

ROUTINE METHOD FOR ISOLATING RETICULIN

About half a kgm. of the organ, at a time, was sliced, washed and digested in the incubator with either Parke, Davis & Co's., or Squibbs' pancreatin, 0.25 per cent to the liter of distilled water and 0.5 per cent sodium bicarbonate. After twenty-four hours' digestion at 37° C, the foul fluid was run off through a strainer, the material that was held back was washed in the mechanical separator for an hour or two in frequent changes of water, followed by distilled water, and then put back to digest in fresh fluid for another day. This usually sufficed; if not, another day's digestion was enough. The splenic framework, now reduced to an oyster-colored network of lacy reticulum and coarser trabeculae, was given a final

cleaning in several changes of tap water, followed by distilled water, in the washing machine, and it was then boiled in 200 cc. of distilled water under a reflux condenser for two or three hours. The tissue shrank considerably and gave off a yellow extract, *the aqueous extract*.

Following this, the extract was filtered off and set aside, the residue being rinsed in distilled water and digested in the incubator with 0.5 per cent NaOH for twelve or more hours. A peculiar greenish brown, fluorescent fluid, with scraps of undissolved connective tissue (elastin?) as a sediment, resulted. The residue was filtered out and again treated with NaOH, to insure as complete solution as possible, the dissolved material being pooled with that of the first run.

If the reader recall the histological section, the reason for these two steps will be clear; it was found that hot water extracted all the fuchsinophil material from the splenic trabeculae and capsule, while NaOH extracted the argyrophil material from the reticulum. What more natural, then, than to boil first in water to extract the "collagen" and follow this by digestion with NaOH to extract the "reticulin"?

The alkaline solution was then filtered through two thicknesses of filter paper in a Seitz vacuum filter, refiltered through four layers and then through an asbestos disc; the filtrate was deep brown, the process time-consuming. Hydrochloric acid was then added carefully to the filtrate until it was just acid to litmus paper. A putty colored precipitate immediately formed and was much increased by adding NaCl in considerable amounts, 5 per cent. The precipitate was then removed by centrifugation and dried over a water-bath, whereupon it became an amorphous, blackish powder. This was extracted for four hours in a Soxhlet apparatus, with 95 per cent alcohol, which removed a heavy extract of deep brown lipins. This was followed by extraction with distilled water for a like period, to remove the salt and any water-soluble material that might remain. Caprylic alcohol was added in small quantity, to keep down the troublesome foaming. The extracted residue was then dried over a water-bath, becoming a dark brown, somewhat crystalline powder.

DESCRIPTION OF FRACTIONS

Aqueous Extract: When evaporated to dryness over a water-bath, this yellow, water-soluble fraction became a glue-like sheet of brittle, hygroscopic material that powdered into flat, shining, brown flakes. On dissolving this in a little water, spreading on a microscopic slide, drying and fixing in Zenker's fluid, it could be handled like a section. After the routine silver impregnation and Van Gieson counterstain, it became bright red and showed no argyrophilic material; there were fibrillar artefacts, resulting from coagulation, that resembled collagen fibrils. With Van Gieson's stain alone, it stained rose-red; with acid fuchsin, somewhat deeper; with Mallory's connective tissue stain it became light blue; with Weigert's elastic tissue stain, pinkish; with silver carbonate alone, yellow-brown to amber. Commercial gelatin, treated in the same way, stained yellow with picric acid in Van Gieson's solution, orange with the orange G. in Mallory's stain, and deep brown with silver carbonate alone. Therefore our aqueous extract apparently differs from gelatin.

It gave a heavy, flocculent precipitate with tannic acid and a lighter one with Zenker's fluid; gold chloride, hydrochloroplatinic acid and other heavy metals produced varying degrees of turbidity. It did not reduce Fehling's solution and gave a pinkish biuret reaction. Its reactions, therefore, resembled those of pure gelatin to a certain extent.

Sodium Hydroxide-Soluble Fraction: Under the microscope, before alcoholic extraction, this appeared as a mixture of amorphous yellow granules, brownish plates and small crystals. Under the polarizing microscope, the crystals were anisotropic. Some of the yellowish granules proved to be iron-containing pigment, derived from splenic deposits and readily removed by treatment with HCl. The anisotropic crystals disappeared after alcoholic extraction. The partially purified precipitate, after neutralizing the alkaline solution, when fixed and impregnated on a slide, became impregnated with silver and did not take the acid fuchsin of the counterstain. It was composed of two sorts of material, black granules or even threads, and yellowish brown amorphous masses with some crystalline material, presumably salt (Fig. 9). The fibrils were sometimes continuous, sometimes beaded, and the impregnated and counterstained smear showed a striking resemblance, in its color scheme, to sections

impregnated by the Hortega method. Unimpregnated control smears showed no black material and the threads were invisible until impregnated with silver. These were not always obtained, sometimes the argyrophil matter was purely granular, particularly in the purified reticulin.

Alcohol Soluble Fraction: This extract was a deep mahogany-brown. On cooling, a precipitate settled out, identified as a mixture of glycolipins. It was very inconsiderable in bulk, reduced Fehling's solution and gave a modified Pettenkofer's test with sulphuric acid, without the addition of sugar. Dried on a water-bath, about one-third of the remaining material was found to be acetone soluble and to contain fats, fatty acids and some cholesterol; it gave a positive Salkowski reaction. The remaining two-thirds, soluble in cold alcohol and insoluble in acetone, was found to be composed of impure lecithin; it gave a Pettenkofer reaction with sugar and sulphuric acid, became whitish and swelled in water, and formed myelin figures when properly treated. These lipins gave very unsatisfactory impregnations with silver as they were difficult to hold on glass slides and the pictures were rather atypical. They do not seem to be the determining factor in the argyrophilia of the reticulum.

REMARKS

It may be said, then, that it is possible to extract a material with the staining properties of the collagen of histological parlance, by boiling the digested framework of the spleen in distilled water; it is also possible to dissolve the residue from this in weak caustic soda and to reprecipitate a substance from this solution by neutralizing with hydrochloric acid and salting-out with sodium chloride. Alcohol extraction removes lipins from this, leaving an insoluble residue which may be redissolved in sodium hydroxide, reprecipitated by acidifying and purified of the contained salts and water-soluble material by extraction with distilled water in a Soxhlet extractor. The purified product is very similar to Siegfried's description of his "reticulin."

This method was applied to spleen as a routine measure, but similar treatment of lung and heart, both rich in reticulum, gave precisely similar results, excepting that there was a copious, insoluble residue (resisting boiling in weak acids or alkalis) in the case of the lung, presumably largely composed of elastin.

In short, extraction with hot water has been found to remove the fuchsinophil material from connective tissue fibers and NaOH to remove the argyrophil. Hot water extract, on evaporation and fixation in Zenker's fluid, is strongly fuchsinophil; sodium hydroxid extract, when dried and purified of the lipins and water-soluble substances, is argyrophilic (after formalin fixation and treatment with KMnO_4 and $(\text{COOH})_2$) and does not stain with fuchsin. This would argue that there are two extractable substances in connective-tissue, leaving elastin out of the reckoning; the one may be extracted without destroying the fibers, the other (recovered after alkaline digestion) probably representing the digested fibers and the argyrophil material that coats, or is closely bound up with them.

DISCUSSION

What are "Reticulin" and "Collagen"? These terms must first be defined, a difficult task.

Reticulin: (a) From Mall's standpoint: a tissue that resists tryptic and peptic digestion and gives no gelatin on boiling with water.

(b) From Siegfried's: a tissue composed of two substances that resist tryptic digestion; one of them soluble in boiling, weak hydrochloric acid and gelling on cooling, the other precipitating out with ammonium acetate or sodium chlorid. Reticulin contains phosphorus.

(c) From the point of view of the histologist: any reticular connective tissue becoming black when impregnated with double salts of ammonium and silver.

(d) According to Mallory and Parker: merely a separated, more compactly fibrillary form of collagen fiber.

(e) From the viewpoint of many of us, frankly agnostic: it is a possible forerunner of collagen, very closely related to it, but chemically different; it might be oxidized, or hydrolyzed collagen, or collagen plus or minus some side chain, or an isomer of collagen.

There is little need for discussing these further, with the exception of the definition of Mallory and Parker, which is too categorical and is, apparently, backed by very little chemical proof. If the substances were chemically identical and their differences in staining merely a matter of physical accessibility to the silver-bath, we should expect: (a) that the surface of the section, all of it equally accessible to the fluid, would have a superficial, mirror-like, black

coating, which it does not; (b) that the two substances would be extracted by the same solvents, again untrue; (c) that the action of oxidizing and reducing solutions would affect both in equal degree, which is contrary to the facts.

It should be understood that reticulin and collagen are apparently very closely related from a chemical standpoint and that the differences in their staining reactions, solubility, etc., depend upon presumably trifling differences in their chemical composition — the one seems to glide over into the other in the most gradual sort of transition. For this reason, the statements made in the paper of Mallory and Parker are probably not much overstressed, but their explanation of these phenomena on a purely physical, or mechanical basis seems to be unwarranted.

The origin of these fibers need not detain us here, for we have not been investigating that aspect of the subject; suffice it to say that the precipitation of argyrophil fibrils from a solution that was filtered several times, argues against any but a chemical, or secretory agency on the part of fibroblasts, or other cells of mesenchymal type.

Collagen: Definitions of collagen may be briefly discussed and dismissed.

(a) From the standpoint of the chemist: a substance with a somewhat variable chemical formula and hydrolyzed into gelatin on boiling with water over long periods. It contains no phosphorus.

(b) From the standpoint of the histologist: a tissue component that stains red with acid fuchsin and blue with anilin blue (disregarding its other staining characteristics) and is found in the white fibrous connective tissue.

To elaborate further: the chemist believes that the collagen fiber is gradually broken up and converted into a jelly (gelatin) by hydrolysis, so that his conception of collagen includes the fiber; the histologist believes that any fibrous tissue with the characteristic staining reactions mentioned is collagenous, hence he implies that the whole fiber is composed of collagen, just as the chemist does.

But we have seen that there is, apparently, a more complicated arrangement of the components of collagenous tissue; the fuchsinophilia disappears after boiling the tissue in water without the fibers being destroyed, the collagen fiber apparently gives up a substance with which it has been impregnated, or saturated, without itself going into solution.

CONCLUSIONS

We may, then, speculate on the probable significance of the data set forth in this paper. These would indicate that the connective tissue is composed of a protoplasmic ground substance which is stained by ordinary acidophil dyes such as eosin, picric acid, etc. After extraction with boiling water and weak caustic soda, there remains a stainable framework. After brief extraction with alkaline solution, the collagenous trabeculae and capsule, and the reticulum of the spleen are still fuchsinophil, but the reticulum is no longer argyrophil; after extraction with boiling water alone, this fuchsinophilia disappears, but the argyrophilia remains. Hence it appears that the fibrous and fibrillar framework is composed of one substance and that all this is associated with a water-soluble, fuchsinophilic material; that the reticular tissue contains in addition to this an alkali-soluble argyrophilic substance.

On leaching connective tissue, freed of cellular material by tryptic digestion, in weak NaOH over a considerable period, the fibrous ground substance is also broken up to a greater or lesser extent. Therefore our "reticulin," recovered by chemical isolation, would be a mixture of the protoplasmic ground substance of the fibers *plus* the very scanty argyrophil matter that characterizes reticulum. This is borne out by the silver impregnation, which shows a brownish yellow background of amorphous material in which black granules and (or) threads are demonstrable. Furthermore, in one batch of tissue that was forgotten and left in the NaOH solution in the incubator for four days, the "reticulin" that was recovered showed considerable fuchsinophilia in smears, which indicates that the reticulin had been hydrolyzed by the NaOH into collagen, an assumption quite in accord with the idea that reticulin is a forerunner of collagen. Young tissue shows more of the former, old tissue more of the latter; take cicatrization as an example.

Phosphorus tests on the isolated "collagen" and "reticulin" fractions were very unsatisfactory; the collagen gave a heavy precipitate with ammonium molybdate in acid solution; this dissolved in ammonia, giving a greenish fluid, and reappeared as a bluish green precipitate on adding nitric acid. The reticulin was quite insoluble in acid, unless boiled in concentrated nitric acid; it gave a questionable precipitate with the molybdate, and the addition of ammonia

changed the fluid to a deep orange-brown. This must be worked out more carefully by a skilled chemist. As Siegfried used different methods and as we have seen that our reticulin is apparently a mixture, while our "collagen" is admittedly different from the usual conception of collagen, the presence or absence of phosphorus is relatively unimportant.

There is another point that is not in accord with the usual conception of collagen and gelatin and this is the almost complete failure on my part to obtain any jellies in the aqueous fractions. This might be explained on the basis that the tryptic digestion had removed most of the gelatinous material from the connective tissue; the combination of digestion with very thorough centrifugal washing may be responsible. Once in a while partial jelling of the aqueous fractions would occur, but not often. A review of the literature will show the greatest lack of unanimity on the part of Mall, Young, Siegfried and Tebb on this very question.

In closing, it should be noted that this work is merely a beginning and that there remains a great deal to be done, as the reader has probably already discovered; it is hoped that the results here set forth may interest some skilled biochemist, who will be in a position to prosecute the chemical investigation and identification of the substances isolated by the methods herein described far more successfully than could a pathologist, who lacks the requisite intensive training in biochemistry and the critical chemical judgment that are essential in running down and identifying the various substances involved.

The kindly and ready assistance of various members of the Department of Biochemistry of our College of Medicine has helped the writer over many hard places in this investigation and is most gratefully acknowledged. Messrs. Mènard and Homan have been very coöperative in aiding with the technical details of impregnation and the photomicrography.

SUMMARY

1. In the connective tissue framework of the human spleen, isolated by means of tryptic digestion, there are three main groups of fibrous substances: (*a*) "collagen," (*b*) elastin and (*c*) reticulin.

(*a*) The first may be completely extracted by boiling water, leaving the white fibrous tissue incapable of taking specific collagen

stains. The extract may be coagulated on slides by means of gentle heat and fixation in Zenker's fluid and a substance will be recovered that gives all the characteristic staining reactions of collagen and many of the precipitation tests of gelatin.

(b) The elastin resists boiling water, and weak acid or alkaline solution. It may be digested with pepsin and HCl, 0.3 per cent. (This was not mentioned in the body of the paper; it is given for the sake of completeness.)

(c) The reticulin is composed of a mixture of at least three groups of substances; an alcohol-soluble group (lipins, largely impure lecithin), an alcohol-insoluble group made up of an argyrophil material that may come down as threads and a silver neutral background of amorphous matter that forms the bulk of the fraction; this may be digested fibers.

2. After extracting these substances from the splenic framework, if alkali-digestion be not carried too far, pale fibers that stain neither with silver nor fuchsin remain; these may be stained with eosin, picric acid, or phosphotungstic acid hematoxylin; rose, yellow, and reddish respectively. ("True collagen?")

3. The staining reactions of the substance extracted with boiling water and those of commercial gelatin are not the same.

4. Using the technic herein described, jellies are very seldom produced.

5. The argyrophil matter in the reticulin is best demonstrated after exposure to certain oxidizing agents, while reducing agents apparently inhibit impregnation.

6. There is a possibility that the water-soluble "collagen" and the alkali-soluble "reticulin" constitute stiffening, strengthening, or protective substances for the fibers of the connective tissue; they impregnate these evenly and may be extracted without destroying the fibers.

7. The assumption that reticulin may be hydrolyzed to collagen is not unwarranted.

NOTE: All but the last two figures represent photomicrographs taken with a 16 mm. objective and 10x ocular.

Photomicrographs by author and Prof. J. B. Homan, of the Department of Medical Art, College of Medicine, University of Cincinnati.

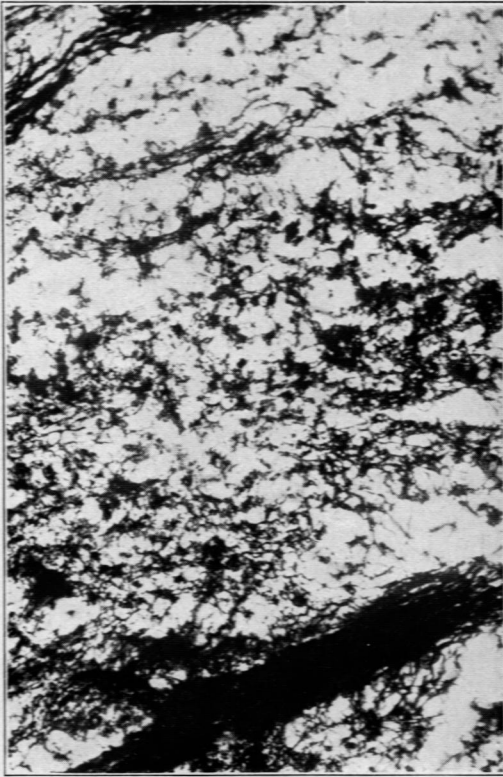
REFERENCES

1. Mall, F. P. Das retikulierte Gewebe und seine Beziehung zu den Bindegewebsfibrillen. *Abhdl. d. math. u. phys. Classe, Kgl. sächs. Gesellsch. d. Wissensch.*, 1891, xvii, 299.
2. Siegfried, M. Ueber die chemischen Eigenschaften des reticulierten Gewebes. *Habilitationsschrift*, Leipzig, 1892. (Quoted in 6, see also Tebb.)
3. Young, R. A. The fibres of retiform tissue. *J. Physiol.*, 1892, xiii, 332.
4. Hammarsten, O. Text Book of Physiological Chemistry, New York, English Ed. 7, 1914.
5. Tebb, M. C. Reticulin and collagen. *J. Physiol.*, 1902, xxvii, 463.
6. Siegfried, M. Reticulin and collagen. *J. Physiol.*, 1902, xxviii, 319.
7. Robertson, T. B. Principles of Biochemistry. Phila., Ed. 1, 1924.
8. Abderhalden, E. Handbuch der Biologischen Arbeitsmethoden. Berlin, 1922. Abt. 1, Teil 8, 567.
9. Strong, O. S., and Elwyn, A. Bailey's Text Book of Histology. New York, Ed. 7, 1926.
10. Prentiss, C. W., and Arey, L. B. Laboratory Manual and Text Book of Embryology. Phila., Ed. 3, 1920.
11. Miller, W. S. The reticulum of the lung. *Am. Rev. Tuberc.*, 1923, vii, 141.
12. Mallory, F. B., and Parker, F., Jr. Reticulum. *Am. J. Path.*, 1927, iii, 515.
13. Foot, N. C., and Ménard, M. C. A rapid method for the silver impregnation of reticulum. *Arch. Path. & Lab. Med.*, 1927, iv, 211.
14. Foot, N. C. A silver tannate technic for paraffin sections from the central nervous system. *Arch. Path. & Lab. Med.*, 1927, iv, 36.
15. Foot, N. C. A technic for demonstrating reticulum fibers in Zenker-fixed paraffin sections. *J. Lab. & Clin. Med.*, 1924, ix, 777.


 DESCRIPTION OF PLATES

PLATE 119

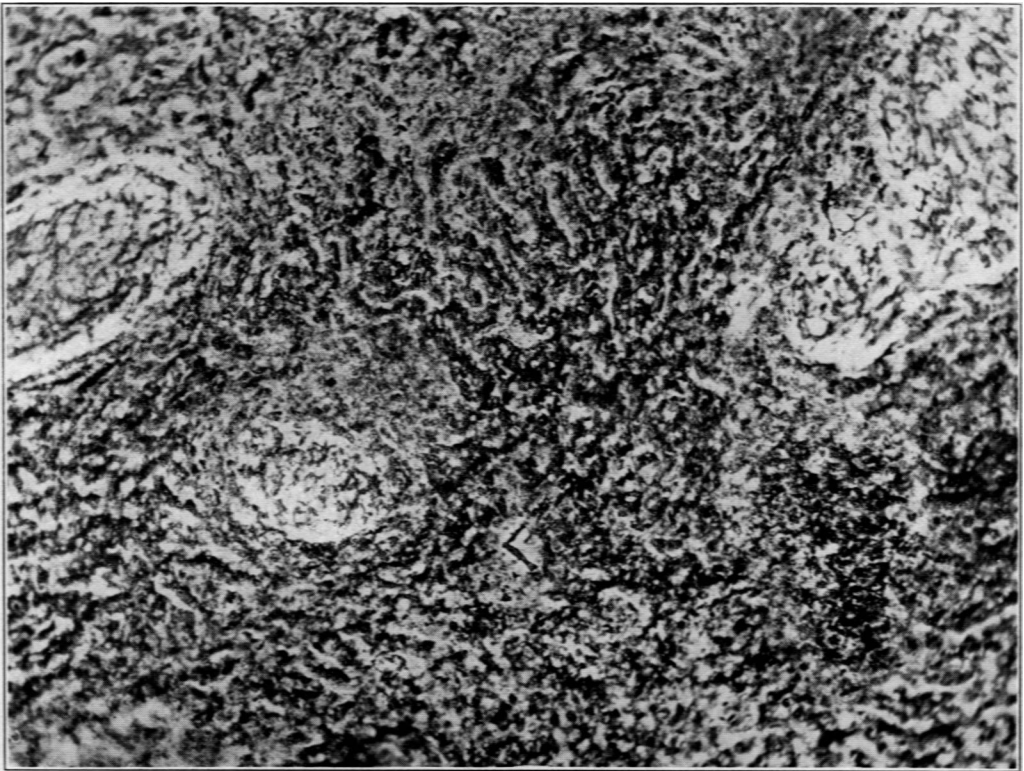
- FIG. 1. A frozen section of fresh spleen, subsequently fixed for two hours in absolute alcohol and ether, *aa*. Simple silver impregnation. Reticulum fairly well impregnated.
- FIG. 2. Another frozen section from the same lot, after soaking 20 hours in absolute alcohol and ether. Silver impregnation. Note that the reticulum is no longer well impregnated, although the section is from the same block as the preceding. A Van Gieson hematoxylin stain on a control section from this batch, after 20 hours in alcohol and ether, took perfectly.
- FIG. 3. A paraffin section of water-boiled spleen, silver-Van Gieson technic. The unstained trabeculae should be noted; when they no longer take acid fuchsin they photograph white, instead of black, and the elastic tissue and reticular fibers in them become evident. Notice the masses of coagulated reticulum, well impregnated, in the splenic pulp.



1



2



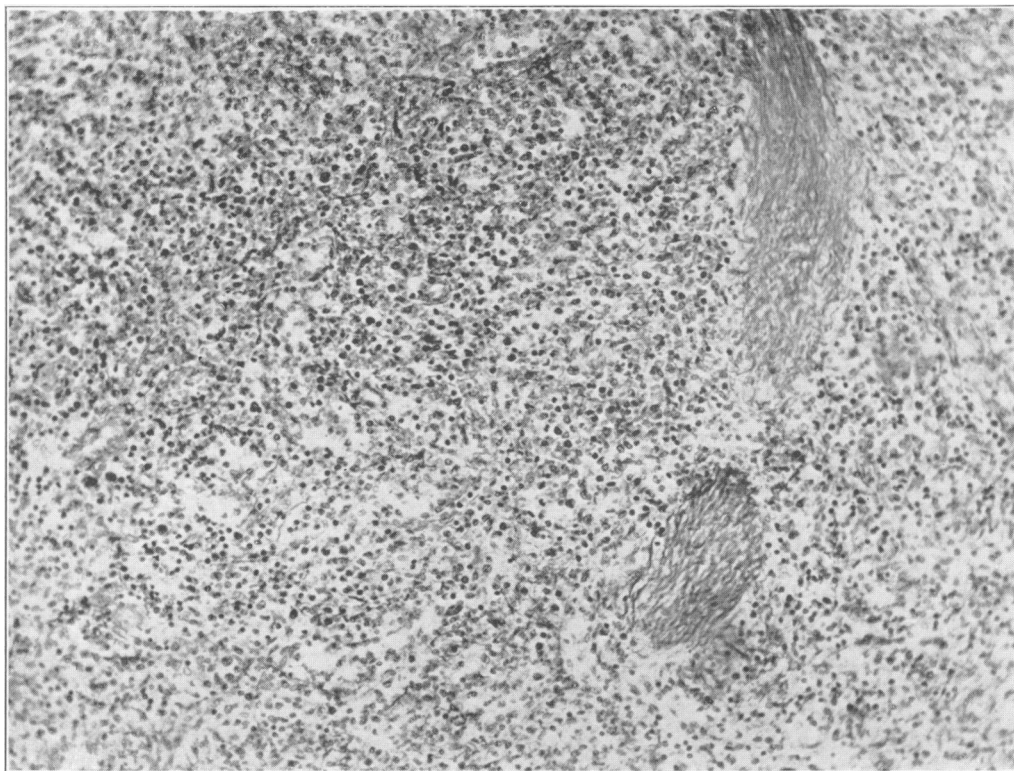
3

Foot

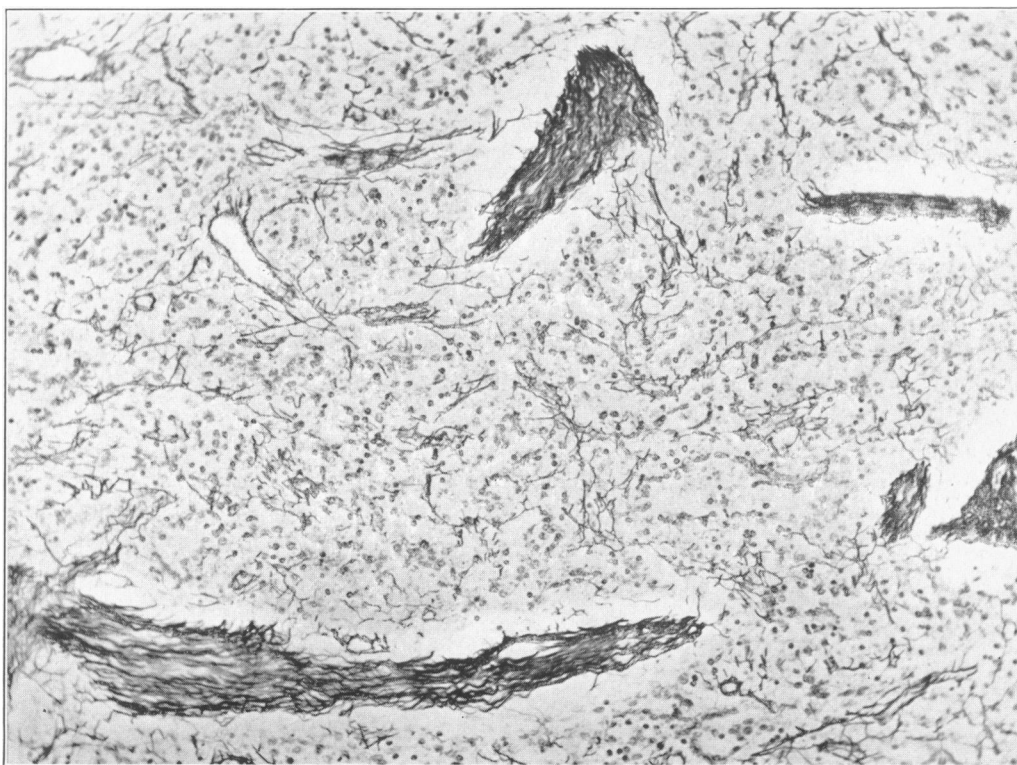
Collagenous and Reticular Connective Tissue

PLATE 120

- FIG. 4. A section of formalin-fixed spleen after silver-Van Gieson impregnation. No pre-treatment with permanganate of potash and oxalic acid. This is an unusually poor impregnation.
- FIG. 5. Serial section from same block as Fig. 4 after silver impregnation *preceded* by permanganate of potash and oxalic acid. The difference in the impregnation is self-evident.



4



5

Foot

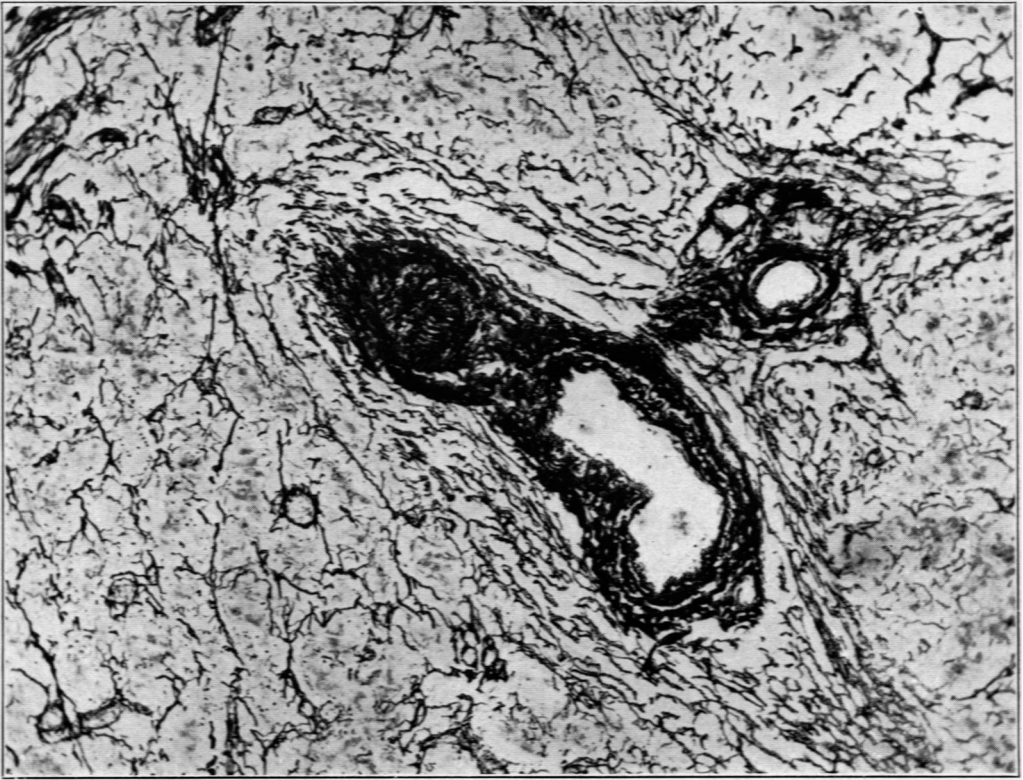Collagenous and Reticular Connective Tissue

PLATE 121

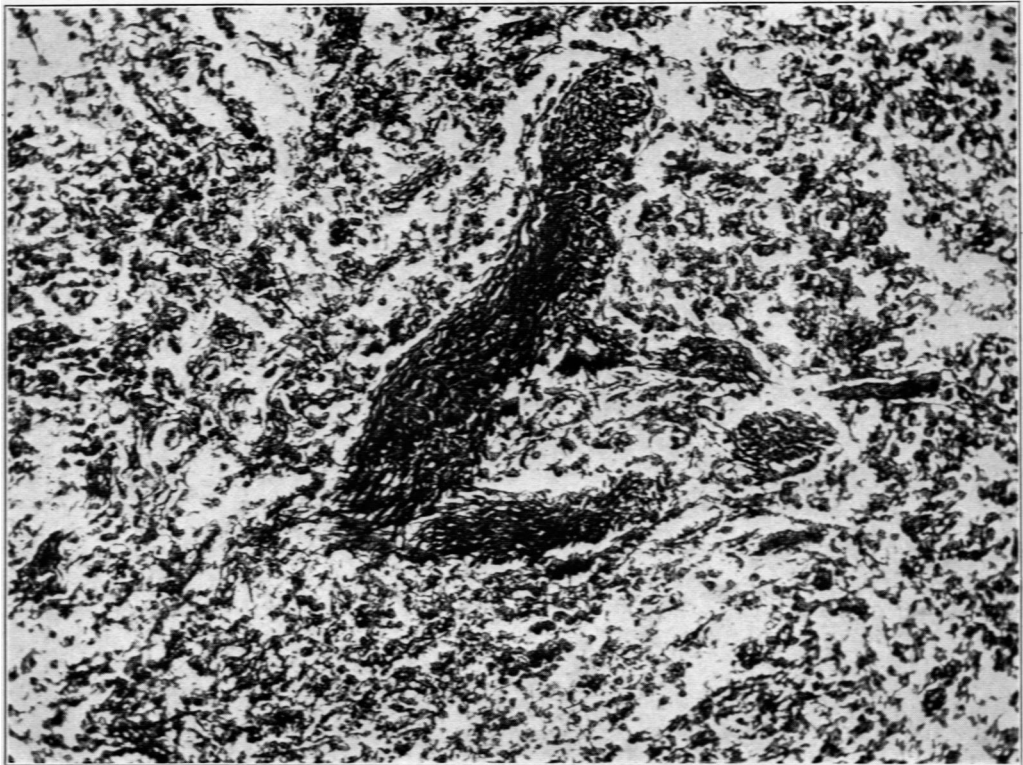
FIG. 6. Same technic as preceding, but from another block of tissue; for comparison with Fig. 7.

FIG. 7. From same block as Fig. 6, with the oxalic acid replaced by 3 per cent hydrochloric acid. Note the totally different type of impregnation resulting from the continued oxidation.

(Figs. 4 to 7, inclusive, were from sections in which the Van Gieson counterstain was omitted.)



6



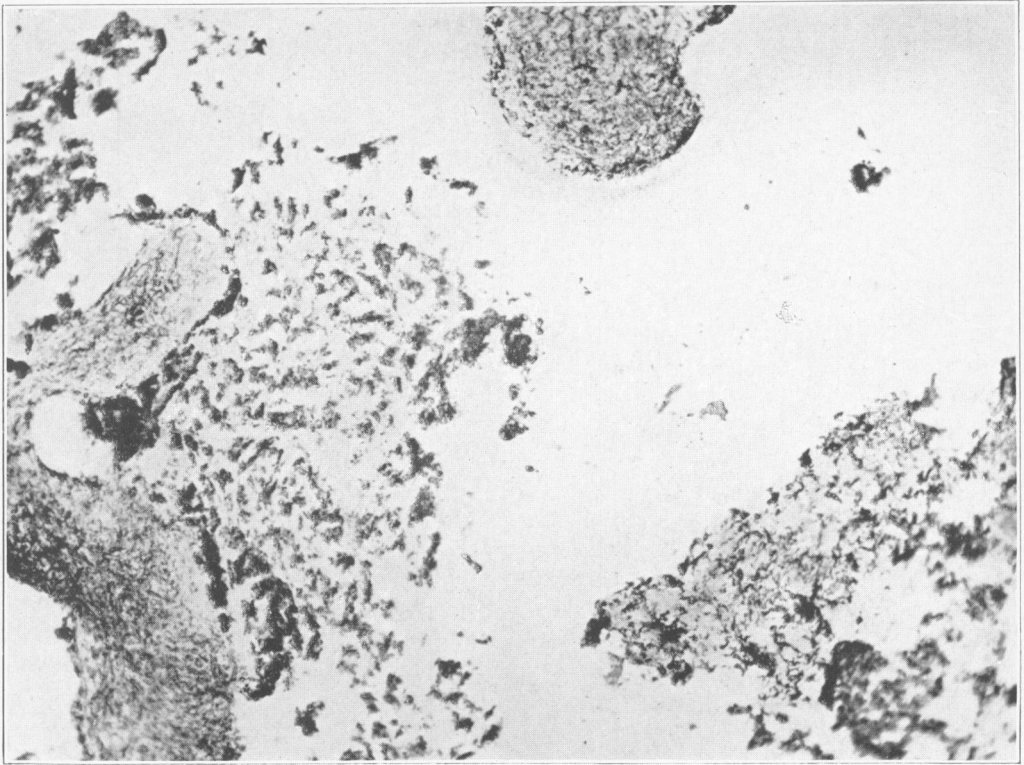
7

Foot

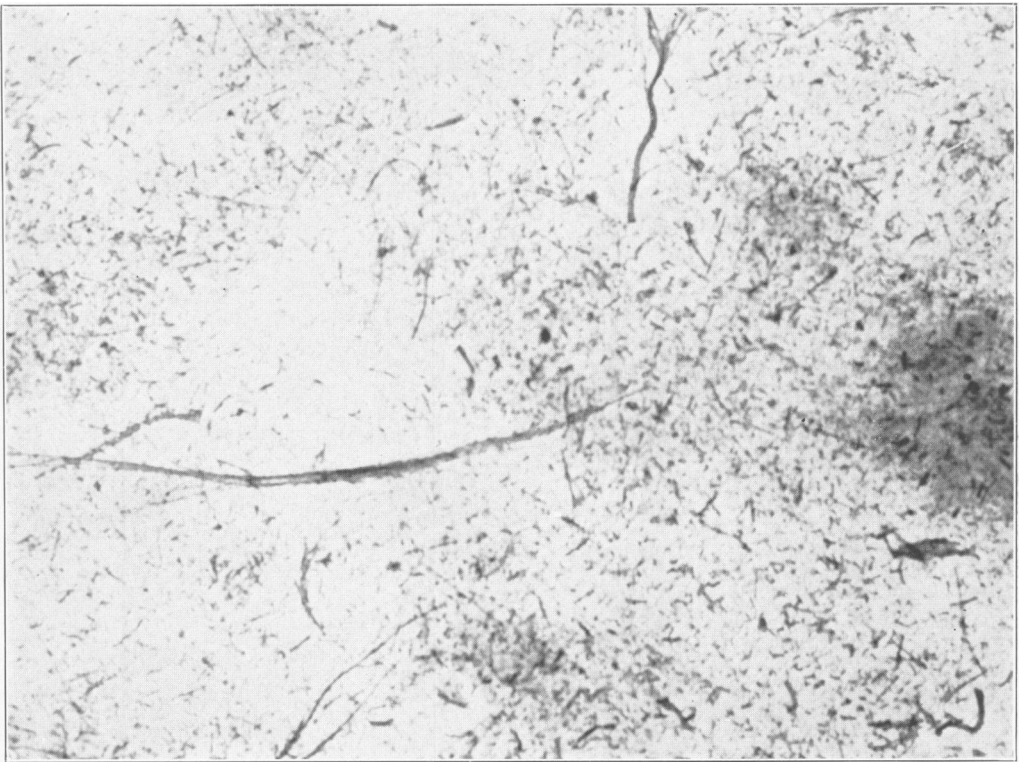
Collagenous and Reticular Connective Tissue

PLATE 122

- FIG. 8. Paraffin section of a mass of precipitate resulting from the boiling of isolated splenic framework with weak HCl. The tissue-like character of the material is perfectly evident. Silver-Van Gieson technic.
- FIG. 9. Silver-Van Gieson impregnation of a smear of the precipitate obtained by neutralizing and salting-out the alkaline solution of isolated splenic framework after filtration through filter-paper. The fibers are presumably thrown down by the reprecipitation. Note the disparity in their size and configuration, the beaded appearance of some of them and their general resemblance to reticulum fibers as shown in the preceding figures. The yellowish brown background has been largely eliminated by the yellow-green filter used in taking the photomicrograph.



8



9

Foot

Collagenous and Reticular Connective Tissue