

## ENDOCARDIAL POCKETS \*

OTTO SAPHIR, M.D.

*(From the Departments of Pathology of the Cleveland City Hospital and Western Reserve University, Cleveland, O., and the Michael Reese Hospital, Chicago, Ill.)*

### INTRODUCTION

In cases of insufficiency of the aortic valve, a coincidental and striking finding is that of endocardial pockets imitating the form of aortic valve leaflets on the surface of the interventricular septum of the left ventricle. These pockets are often multiple, their openings directed toward the aorta. Even more rarely such pockets are observed with their openings directed toward the apex of the heart.

### LITERATURE

Zahn,<sup>1</sup> who first directed attention to these formations in aortic insufficiency, interpreted them as anatomical signs of incompetence of the aortic valves. He believed that such pockets occurred on the basis of simple endocardial thickenings which were brought about by the chronic irritation of the impulse of the regurgitating blood. In his opinion, the prolonged irritation of the regurgitating blood produced the pockets or pseudovalves only secondarily. He observed plain endocardial thickening in the left auricle in cases of insufficiency of the mitral valve, but he did not describe pockets in the left auricle. Herxheimer,<sup>2</sup> Dewitzky,<sup>3</sup> Rosenbusch,<sup>4</sup> Wilke,<sup>5</sup> and Cohn,<sup>6</sup> similarly believe in the mechanical genesis of circumscribed endocardial thickenings and endocardial pockets. Kaewel,<sup>7</sup> who states that the formation of endocardial pockets may aid in the diagnosis of aortic insufficiency, also traces back their origin in most of the cases to the mechanical irritation of the regurgitating blood. He thinks that continuous pressure of a thickened aortic leaflet of the mitral valve upon the opposite side of the interventricular endocardium of the left ventricle often cannot be ruled out as a contributory cause. Ziegler,<sup>8</sup> Aschoff,<sup>9</sup> and later Böger<sup>10</sup> emphasize that circumscribed endocardial thickenings are primarily inflammatory in nature, end

\* Received for publication June 20, 1930.

stages of acute mural endocarditis. The pockets are formed secondarily, following the mechanical excavation of the thickened areas, by the regurgitating blood impulse after an insufficiency of the aortic valve has been established. Krasso <sup>11</sup> maintains that primarily all types of pockets are formed on the basis of endocardial thickenings which are caused mechanically by the force of the regurgitating blood stream, but infectious thrombi with organization, formed in such areas, might also play a rôle in the formation of circumscribed endocardial thickenings.

Schmincke <sup>12</sup> and Borst <sup>13</sup> are of the opinion that the formation of endocardial pockets is a sign of functional adaptation.

Sotti <sup>14</sup> holds that most of the pockets are abnormal muscle bridges converted into connective tissue, or aberrant muscles, or chordae tendineae, and therefore should be classified rather as malformations of the heart.

Ribbert, <sup>15</sup> in Henke and Lubarsch's handbook, says that several causes might lead to pocket formation; a primary circumscribed endocarditis, a continuous friction of thickened or calcified aortic leaflets of the mitral valve upon the opposite endocardial surface of the interventricular septum, the mechanical irritation of the regurgitating blood in aortic insufficiency, and finally, congenital anomalies.

The foregoing short survey of the literature shows the different views expressed as to the origin of endocardial pockets. While many writers believe they occur on a purely mechanical basis, others believe them to be of inflammatory origin, while the opinion is expressed by some authors that they are formed on the basis of congenital malformation. A possible relation of the endocardial pockets to the type of valvular disease has not attracted attention.

The present study was undertaken, first, to determine whether or not by the use of serial sections one definite etiological factor might be demonstrated as to the cause of the formation of pockets; secondly, to see if in different types of valvular diseases a different cause could be found to explain such formations. Endocardial pockets of the left auricle which were present in one case were similarly studied.

#### METHODS

Six hearts were studied. A detailed description of the hearts will be given subsequently. The hearts were obtained from routine post-

mortem examinations. No museum specimens were used for this investigation. The endocardial pockets with the adjacent myocardium were cut out, hardened in 10 per cent formalin and embedded in paraffin. Serial sections were made from the various pockets. The first, fourth, seventh, etc., sections were stained with iron hematoxylin and eosin; the second, fifth, eighth, etc., according to Van Gieson's method, while the third, sixth, ninth, etc., were prepared with a combination of iron hematoxylin and orcein stain, using a method described elsewhere (Saphir<sup>16</sup>).

#### CASE REPORTS

*Endocardial Pockets in Hearts Showing Acute Ulcerative and Chronic Endocarditis (Subacute Bacterial Endocarditis with Positive Blood Culture of Streptococcus Viridans)*

**CASE 1. Pathological Diagnoses:** Acute ulcerative and vegetative endocarditis superimposed on chronic endocarditis of the aortic and mitral valves, with insufficiency of both valves.

**Gross Description:** The heart was enlarged, weighing 450 gm. The free margins of the cusps of the aortic valve showed several fresh vegetations. The cusps themselves were retracted and shortened. There were a few small ulcers throughout the ventricular surface of the left aortic cusp. Many recent vegetations were found extending over the aortic leaflet of the mitral valve. The free margins of the mitral valve leaflets were retracted and thickened, the chordae tendineae were firm and shortened. The endocardium below the left aortic cusp showed many recent, grayish red vegetations. The endocardium surrounding them was of a grayish white color. At a distance of 6 mm. from these vegetations, in an area 2 cm. below the aortic valve, situated on the interventricular surface of the left ventricle there were two small circumscribed endocardial pockets measuring 3 and 5 mm. in width. These pockets were open toward the aortic valve.

**CASE 2. Pathological Diagnoses:** Acute vegetative, superimposed on chronic endocarditis of the aortic valve. Acute vegetative and ulcerative endocarditis of the mitral valve superimposed on chronic endocarditis. Insufficiency of the aortic and mitral valves.

**Gross Description:** The heart was enlarged, weighing 500 gm. The free margins of the aortic cusps were thickened, the cusps re-

tracted and to some extent adherent to one another. A few small, recent vegetations were found attached to the free margins. The mitral leaflets were markedly thickened, in part calcified, and covered with large, partly firm and partly friable vegetations. Throughout the aortic leaflet of the mitral valve on its ventricular aspect, several ulcers were noticeable. The endocardial surface showed throughout the interventricular septum of the left ventricle, beginning from an area of about 3 cm. below the aortic valve and extending down to an area of about 2 cm. from the apical portion, a number of pockets. These pockets varied in size from 4 to 12 mm. in width. Some of the pockets extended in the form of fibrous bands over several trabeculae carneae and reached the papillary muscles. All pockets were open in the direction of the aortic valve. While some pockets were found in the vicinity of vegetations of the aortic leaflet of the mitral valve, others showed no apparent relation to these vegetations. There were no thrombi close to the pockets. The cusps of the pockets were grayish in color, firm in consistency, and free from vegetations.

*Histological Examination:* The histological findings in the pockets of both cases were about identical. The endocardium in some of the sections was fibrosed and showed only a moderate number of nuclei. Many sections, however, showed a diffuse infiltration of lymphocytes, endothelial cells, and a few polymorphonuclear leukocytes and eosinophiles. The cells were apparently more abundant close to the point of attachment of the cusp of the pockets to the endocardium. Some slides showed the extension of the inflammatory cells into the subendocardial layer. The heart muscle fibers found in the subendocardial region were markedly atrophic, their cytoplasm distinctly granular in appearance. There were only a few inflammatory cells present in these portions. The cusps of the pockets showed in some of the sections a dense fibrous tissue with only a few cellular elements, but some of the sections again showed large numbers of endothelial cells, lymphocytes and a few polymorphonuclear leukocytes. A few fields showed the formation of small-sized blood vessels extending from the endocardium into the cusps. There were remnants of blood pigment present. In some of the sections remnants of organizing thrombi were recognizable. Sections which were taken from the bands extending over the trabeculae carneae showed the latter to be surrounded by connective tissue and elastic fibers with

many lymphocytes and endothelial cells. The trabeculae carneae themselves were outlined indistinctly and many of them could be recognized only with the aid of the Van Gieson stain. Between the fibers, inflammatory cells were observed. The elastic stain showed an abundance of elastic lamellae of the cusps. They were found in parallel rows. Some of the fields showed the extension of the endocardial elastic lamellae into the cusps.

*Endocardial Pockets in Hearts Showing Syphilitic Involvement  
of the Aortic Valve*

CASE 3. *Pathological Diagnoses:* Syphilitic aortitis with involvement of the aortic valve. Insufficiency of the aortic valve.

*Gross Description:* The heart was hypertrophic and dilated, weighing 650 gm. The aorta showed characteristic lesions of syphilitic aortitis. The cusps of the aortic valve showed a separation of the commissures extending over areas measuring 3 to 4 mm. in extent. There was a marked insufficiency of the aortic valve. The aortic leaflet of the mitral valve was free from pathological changes. The upper portion of the left ventricle, just below the aortic valve, seemed much narrowed as compared with the size of the remainder of the ventricle which was markedly dilated and hypertrophic. The impression was gained that this area which Krasso calls "conus arteriosus sinister," was the seat of a relative bottle-neck stenosis. The endocardium of the interventricular septum of the left ventricle showed a series of pockets in four parallel horizontal rows. The pockets measured 2 to 6 mm. in width. In the region of the trabeculae carneae a few connective tissue bridges were seen. All these pockets were open toward the aorta. Just below the left aortic cusp, however, another pocket was found which measured 3 mm. in width. This pocket was open toward the apex of the heart. In the vicinity of this pocket, the endocardium was grayish white in color and thickened.

CASE 4. *Pathological Diagnoses:* Syphilitic aortitis with involvement of the aortic valve. Insufficiency of the aortic valve.

*Gross Description:* The heart weighed 700 gm. It was markedly hypertrophic and dilated. The aortic lesions were characteristic of syphilitic aortitis. There was a distinct separation of the commissures of all three cusps and insufficiency of the aortic valve. The

mitral valve leaflets showed no changes. The conus arteriosus sinister (Kraso) was apparently the seat of a relative stenosis. The endocardium of the left ventricular surface of the interventricular septum showed many thickened areas which were of stringy appearance and which were found in an area about 2 cm. below the aortic valve. In and below this region several typical pockets were found which measured from 2 to 8 mm. in width. The cusps of these pockets were firm in consistency. Most of the pockets were in one horizontal row, but several were found above and below this row. All these pockets were open toward the aortic orifice. Just below the left aortic cusp there was one pocket which measured 5 mm. in width, and which was open toward the apex. The endocardium close to this pocket was grayish white in color and of much firmer consistency than the surrounding portions.

*Histological Examination:* The endocardium in the region of the pockets was fibrosed. There was an occasional lymphocyte and endothelial cell found, but the tissue in general was very poor in cells. In some portions the endocardium was hyalinized. The fibrosis extended into the surrounding subendocardial layer. But here, too, very few cellular elements were seen. The muscle fibers close to the endocardium were atrophic and in some fields present in the form of a light pink-stained material assuming the shape of heart muscle fibers. By use of the Van Gieson method these fibers stained yellow. The cusps of the pockets showed a dense connective tissue overgrowth with a varying number of fibroblasts. There were hardly any blood vessels found in this portion nor was there any evidence of organization. Both types of pockets, the ones with the openings directed toward the apex and the ones with the mouths open toward the aorta, showed identical lesions. The elastic tissue stain showed an abundance of elastic fibers throughout the cusps. Some of the sections showed clearly the extension of the elastic lamellae from the endocardium into the cusps.

*Endocardial Pockets in Hearts Showing Rheumatic  
Endocarditis*

CASE 5. *Pathological Diagnoses:* Healed endocarditis of the aortic valve. Stenosis of the aortic orifice.

*Gross Description:* The heart was enlarged and dilated, weighing 400 gm. The free margins of the aortic valve were thickened and

showed adhesions between the lateral portions of the cusps, producing a stenosis of the aortic orifice. The myocardium histologically showed several Aschoff bodies. The endocardium in an area about 1 cm. below the left aortic cusp showed a pocket measuring 8 mm. in width. This pocket was open toward the apex. The margin of this pocket was thin and sharp. The endocardium in the neighborhood of this pocket was thickened and fibrosed.

*Histological Examination:* The sections of the endocardium showed a marked increase of connective tissue with only very few nuclear elements. The fibrosis extended into the surrounding portions of the myocardium. The heart muscle fibers in this region were apparently atrophic. The cusps themselves showed a hyalinized connective tissue with few spindle-shaped cells. There were no blood vessels found, nor was there any other evidence of organization.

CASE 6. *Pathological Diagnoses:* Acute verrucous, superimposed on chronic endocarditis of the aortic and mitral valves. Insufficiency of both valves.

*Gross Description:* The heart was enlarged and dilated weighing 300 gm., (patient was a child 6 years of age). The cusps of the aortic valve were shortened and retracted. Their free margins were studded with a row of bead-like vegetations. The free margins of the mitral valve were thickened and retracted. Some of the chordae tendineae were fused by confluence. They were much shorter than normal, and thickened. The myocardium upon histological examination showed many Aschoff bodies. In an area about 2 cm. above the mitral valve, the auricular endocardium showed two pockets. The pockets measured 3 and 5 mm. in width. They were quite separate and were open toward the mitral valve. The surrounding portions of the endocardium were grayish white in color and thickened.

*Histological Examination:* The histological examination of the endocardium in the region of the pockets showed a diffuse infiltration of many polymorphonuclear leukocytes, a few lymphocytes and endothelial cells. There was a moderate amount of connective tissue with many spindle-shaped cells. The cusps similarly contained a large number of polymorphonuclear leukocytes, many lymphocytes, endothelial cells, and, in addition, many connective tissue fibers with a large number of fibroblasts. There were small-sized blood vessels found extending into the cusps. Some of the fields showed

remnants of blood pigment and phagocytic cells. The elastic tissue stain showed a great number of elastic fibers without any particular arrangement. Some of the sections showed these fibers extending from the endocardium into the cusps.

#### DISCUSSION

##### *Endocardial Pockets in Hearts Showing Subacute Bacterial Endocarditis*

The endocardial pockets which were found in the two cases of subacute bacterial endocarditis showed evidence of inflammation. There were still remnants of inflammatory cells, mainly lymphocytes, a few eosinophiles, endothelial cells and occasional polymorphonuclear leukocytes. Besides, a new formation of small-sized blood vessels was easily noticeable. Young connective tissue fibers were seen throughout some of the sections, while other sections showed scar tissue which in some portions was hyalinized. The sections emphasized the importance of serial sections as the only means of studying these changes. It easily can be understood why, by the use of only a few sections, hyalinized scar tissue alone might have been found. The sections showed that there must have been primarily an acute inflammatory exudate which secondarily became organized. Whether this was primarily a mural endocarditis or whether the initial lesion was brought about by contact with the diseased aortic leaflet of the mitral valve cannot be decided.

Both of our cases showed an insufficiency of the aortic valve. It seems plausible that the force of the regurgitating blood and pressure during diastole, continuously irritating the primary inflammatory area of the parietal endocardium, finally resulted in the formation of the pockets. The question arises whether the pockets were formed during the process of organization of the circumscribed parietal endocarditis, or whether they were formed secondarily after the scar formation had been completed. It is conceivable that as soon as the insufficiency of the valve was established, and as soon as irregularities were formed along the course of the regurgitating blood and pressure, the irregularities provided a foothold for the regurgitating blood which, with oft repeated insults to these areas, finally led to the formation of pockets. These irregularities might be either an organizing exudate or circumscribed endocardial thickenings, *i. e.*,



end stages of a parietal endocarditis. In many sections of the cusps of the pockets, blood vessels were seen extending from the endocardium through the bases of the pockets into the cusps. In addition, the cusps also showed inflammatory cells and blood pigment. These findings speak more for the fact that the formation of the pockets occurred during the period of organization. If the pockets had been formed secondarily upon an endocardial scar after the inflammation had subsided, we would rather expect to find in the cusps of the pockets hyalinized connective tissue without blood vessels or remnants of inflammatory exudate, mere evidence of mechanical irritation. I believe, therefore, that the regurgitating blood and pressure in aortic insufficiency produced the pocket formation in the area which was the seat of a parietal endocarditis undergoing organization. The finding of remnants of muscle fibers, with marked atrophy but without signs of inflammation in some portions, showed that the atrophy was more likely the result of a continuous mechanical pressure which brought about the formation of pockets, than evidence of past inflammations extending into the myocardium.

*Endocardial Pockets in Hearts Showing Syphilitic Involvement  
of the Aortic Valve*

Both of our cases showed pockets which were open in the direction of the aorta. But in addition, each case showed one pocket which was open in the direction of the apex of the heart. The sections of the pockets open toward the aorta showed an abundance of connective tissue with hardly any nuclear elements, no blood vessels, but many elastic fibers. A primary inflammation and secondary organization therefore can be ruled out. The only explanation I can offer for the formation of these pockets lies in the aortic regurgitation. The degree of insufficiency of the aortic valve in both cases was very marked. It must be assumed that the regurgitating blood and pressure acting as a chronic irritant primarily produced circumscribed fibrosed areas of the endocardium. As soon as irregularities of the endocardium were formed, the continuous regurgitation with formation of eddies in these regions finally resulted in the formation of pockets.

The pockets which were open toward the apex were found below the left aortic cusp very close to white, fibrosed areas in both cases.

This location of such pockets was commonly encountered by most of the investigators. Histologically none of the pockets showed remnants of an acute inflammatory exudate. In both instances they revealed only connective tissue which was poor in nuclei. Ribbert believes that the thickened endocardium in such areas was due to an extension of the syphilitic process from the valves to the endocardium. But these areas showed histologically nothing characteristic of syphilis. Libman,<sup>17</sup> in discussing Cohn's paper, does not believe in the syphilitic origin of endocardial pockets. Krasso believes that primary endocardial thickening, similar to that preceding the formation of pockets open toward the aorta, is due to the continuous pressure of the regurgitating blood in aortic insufficiency. He states that in the case of a relative stenosis of the conus arteriosus sinister, such thickened areas were secondarily transformed into pockets by the force of the systolic pressure. The location of such pockets just below the aortic valve, however, makes it seem unlikely that they were primarily the result of mechanical pressure of the regurgitating blood. Furthermore, there are cases reported, without evidence of insufficiency of the aortic valves, showing such pockets. Case 5 of this series, similarly did not disclose an aortic regurgitation.

The following table is offered to show the reported cases in which mention was found of pockets open toward the aorta. The table gives the name of the author, the diagnosis of valvular disease, the number of the particular case, and the number of pockets.

TABLE I

*Case Reported with Pockets open Toward the Aorta*

Author	Main diagnosis	Case No.	Number of systolic pockets
Wilke	Stenosis of the aortic orifice due to a papillary tumor of the aortic valve.	3	Several
Wilke	Recurrent endocarditis of the aortic valve. Stenosis of the aortic orifice and insufficiency (?) of the aortic valve.	4	Several
Kaewel	Syphilitic involvement of the aortic valve. Insufficiency of the aortic valve.	6	2
Kaewel	Syphilitic involvement of the aortic valve. Insufficiency of the aortic valve.	7	1
Kaewel	Syphilitic involvement of the aortic valve. Insufficiency of the aortic valve.	8	2
Kaewel	Acute, superimposed on chronic endocarditis of the mitral and aortic valves.	21	3
Böger	Healed thrombo-endocarditis, <i>ulcerosa lenta</i> . Stenosis of the aortic orifice and insufficiency of the aortic valve.	7	2
Böger	Healed rheumatic endocarditis of mitral valve.	12	1
Krasso (first paper)	Recurrent malignant endocarditis. Insufficiency of the aortic valve and moderate stenosis of the aortic orifice.	1	1
Krasso (second paper)	Healed endocarditis of the aortic and mitral valves. Insufficiency of the aortic valve and stenosis of aortic orifice.	1	1
Krasso (second paper)	Recurrent malignant endocarditis. Insufficiency of aortic valve and stenosis of aortic orifice.	2	1
Krasso (second paper)	Recurrent verrucous endocarditis. Insufficiency of aortic valve and stenosis of aortic orifice.	3	1
Krasso (second paper)	Syphilitic involvement of the aortic valve. Insufficiency of the aortic valve.	5	2
Krasso (second paper)	Healed endocarditis of aortic valve. Insufficiency of aortic valve.	6	1
Krasso (second paper)	Healed endocarditis of aortic valve. Syphilitic involvement of the aortic valve. Insufficiency of aortic valve.	8	Several

Seven cases out of the fifteen shown in the table were the seat of an unquestionable stenosis of the aortic orifice. Five cases showed a syphilitic involvement of the aortic valve; but the hearts of these cases were the seat of a marked hypertrophy and dilatation leading, as Krasso specifically pointed out, to a relative stenosis of the aortic conus. In his case (No. 6) showing an insufficiency of the aortic valve without organic stenosis of the orifice, Krasso emphasized the presence of a relative stenosis of the aortic conus. In Kaewel's case (No. 21) showing an acute, superimposed on chronic endocarditis of the aortic and mitral valves, the diagnosis of stenosis of the aortic orifice was not mentioned, but the hypertrophy and dilatation of the heart was emphasized. Böger's case (No. 12) showed a healed rheumatic mitral endocarditis. But neither the size nor the weight of the heart was given, so that nothing can be said about a possible relative stenosis of the aortic conus. Both of our cases of syphilitic involvement of the aortic valve, in which pockets open toward the apex were found, were the seat of a relative stenosis of the aortic conus brought about by the marked hypertrophy and dilatation of the heart. It is possible that the friction of the systolic blood stream, and pressure, is sufficient to produce a mechanical irritation of an area situated in the region of the stenosed conus. At the same time, the continuous impulse of the systolic blood stream, and pressure, might result in the formation of pockets. Krasso calls pockets which are open toward the aorta diastolic pockets, and those open toward the apex, systolic pockets. It seems that this nomenclature is justifiable and should be adopted.

#### *Endocardial Pockets in Rheumatic Endocarditis*

Case 5, which showed a healed rheumatic endocarditis resulting in a stenosis of the aortic orifice, presented only one systolic pocket just below the aortic valve area. However, the surrounding endocardium was diffusely thickened. The sections of both, the cusp of the pocket and the surrounding endocardium, revealed no indications of organization or remnants of an inflammatory exudate. The sections showed only fibrous tissue with a few nuclear elements. The aortic leaflet of the mitral valve showed no changes. This pocket, similar to the systolic pockets of the last two cases, was apparently the result of the continuous irritation and friction of the systolic

blood stream and pressure upon the area below the stenosed aortic orifice, producing, first, simple thickenings of the endocardium with secondary formation of pockets. The pathogenesis of the systolic pockets of this case and of the last two cases is apparently identical.

Sections of the auricular pockets of the second case of this group showed the presence of inflammatory cells, lymphocytes, polymorphonuclear leukocytes, endothelial cells and a new formation of connective tissue. The surrounding portions of the myocardium showed similar inflammatory cells. It is evident that the primary changes were inflammatory in nature. As in the first group of cases, the impulse of the regurgitating blood directed upon an area of organizing parietal endocarditis of the left auricle, caused the formation of pockets after the insufficiency of the mitral valve was established.

This case is especially noteworthy because a search through the literature disclosed only one other case, described by Abbott,<sup>18</sup> which showed pockets in the left auricle. This author found a thick-walled endocardial pocket in the left auricle of a heart which was the seat of a large open foramen ovale and button-hole stenosis of the mitral orifice. The depths of this pocket lay in close contiguity to a muscular channel running from an accessory chamber in the right auricle. The auricular endocardium was greatly thickened. The histological details, however, are lacking and it is, therefore, difficult to decide whether this pocket was inflammatory in origin or evidence of another malformation of the heart.

The various pockets in our cases, therefore, seem of different origin. Some are primarily inflammatory in nature, results of organizing parietal endocarditis, while others seem to be the result of primary mechanical irritation. The formation of the pockets themselves, however, is in the final analysis, always caused by the force of either systolic or diastolic regurgitating blood columns and pressure.

In the discussion of the pathogenesis of diastolic endocardial pockets, the ultimate cause for their formation appears to be the regurgitation of blood and pressure. Wiggers<sup>19</sup> in his "Circulation in Health and Disease" states that in aortic insufficiency only a small volume of blood actually regurgitates, and that the essential dynamic disturbance is brought about not by the volume of blood which regurgitates, but by the regurgitation of pressure during diastole. However, more recently, Wiggers and Green<sup>20</sup> found that in

artificially produced aortic insufficiency, the total regurgitation under optimum conditions can equal 50 to 60 per cent of the normal tidal volume in the perfused heart. It seems unlikely that the regurgitating pressure in aortic insufficiency is able to act upon one circumscribed area of the endocardium and produce there, in time, diastolic pockets. It is more likely that the regurgitating pressure occurring without fluid movement would extend equally in the various directions. The only possible explanation of the pathogenesis of the formation of endocardial pockets lies in the assumption of a regurgitation of blood. The regurgitation of pressure might play an additional, but much less important rôle. Whether the actual friction of the regurgitating blood, or whether eddies formed by the regurgitating blood and directed upon a circumscribed portion of endocardium produce the chronic inflammation which is the basis for the formation of some of the pockets, cannot be decided.

All the sections revealed the presence of a great number of elastic lamellae. Some of the sections showed the direct continuation of the internal elastic lamellae of the endocardium into the pockets.

Wilke, as stated before, is of the opinion that the pockets are manifestations of functional adaptation. A similar view was more lately expressed by Borst. Functional adaptation, however, implies that the part involved adapts itself to new functional demands (Karsner<sup>21</sup>) and actually fulfills the demanded functions (Borst). The endocardial pockets, however, only resemble pockets of aortic valves. Even though they are brought about by the force of the blood stream and are often found to be multiple, yet they cannot have any marked function because they are small and hold only a very insignificant amount of blood. To fulfill a function, it would be necessary that the pockets be close enough together to allow their cusps to touch during diastole as aortic cusps do. If such pockets were found in an entire row just below the aortic valve, a teleologist might be justified in assuming them to be evidence of functional adaptation.

#### SUMMARY AND CONCLUSIONS

1. In two cases of subacute bacterial endocarditis of the aortic and mitral valves with insufficiency of the aortic valve, endocardial pockets with openings toward the aorta were found on the interventricular septum of the left ventricle. The initial lesion which

brought about the pocket formation was a circumscribed parietal endocarditis. The continuous regurgitation formed the pockets secondarily.

2. In one case of rheumatic endocarditis of the mitral valve with insufficiency of this valve, endocardial pockets were present in the left auricle. These pockets were open toward the mitral valve. They also were primarily inflammatory in origin and formed secondarily by the regurgitation after the insufficiency of the mitral valve had been established.

3. In two cases of syphilitic involvement of the aortic valve with insufficiency of this valve, endocardial pockets open toward the aorta were found. These pockets were caused primarily by the mechanical irritation of the regurgitating blood columns.

4. Two cases of syphilitic involvement of the aortic valve with insufficiency of this valve and marked stenosis of the conus arteriosus sinister, and one case of rheumatic endocarditis of the aortic valve with stenosis of its orifice, showed endocardial pockets on the interventricular surface of the left ventricle. These pockets were open toward the apex of the heart. They were brought about by the mechanical irritation of the systolic blood stream acting as a trauma upon the endocardium in the region of the stenosed portions.

5. Diastolic endocardial pockets are evidence in favor of the view of actual regurgitation of blood volume.

6. The nomenclature of "diastolic pockets" referring to those open toward the aorta and "systolic pockets" referring to those open toward the apex (Kraso) is justified.

7. Endocardial pockets cannot be regarded as manifestations of functional adaptation.

I am indebted to Prof. H. T. Karsner for his valuable suggestions.

#### REFERENCES

1. Zahn, F. W. Ueber einige anatomische Kennzeichen der Herzklappeninsuffizienzen. *Verhandl. d. Kong. f. inn. Med.*, 1895, 13, 351.
2. Herzheimer, G. Ueber Sehnenflecke und Endokardschwien. *Beitr. z. path. Anat. u. z. allg. Pathol.*, 1902, 32, 461.
3. Dewitzky, W. Ueber Endokardialflecken. *Frankfurt. Ztschr. f. Path.*, 1912, 9, 82.
4. Rosenbusch, H. Ueber mechanische Endocardveränderungen. *Frankfurt. Ztschr. f. Path.*, 1913, 14, 342.

5. Wilke, A. Veränderungen am Endokard der Pars aortica bei Insufficienz und Stenose des Aortenostiums. *Deutsches Arch. f. klin. Med.*, 1910, **99**, 108.
6. Cohn, A. E. The formation of endothelial pockets in aortic insufficiency. *Proc. New York Path. Soc.*, 1914, **14**, 24.
7. Kaewel, H. Endocardtaschen auf dem Septum ventriculorum. *Beitr. z. path. Anat. u. z. allg. Pathol.*, 1928, **79**, 431.
8. Ziegler, E. Lehrbuch der speziellen pathologischen Anatomie. Jena, 1898.
9. Aschoff, L. Pathologische Anatomie. Jena, 1919.
10. Böger, A. Ueber die Endocardsklerosen. *Beitr. z. path. Anat. u. z. allg. Pathol.*, 1929, **81**, 441.
11. Krasso, H. Ueber atypische endocardiale Taschenbildungen bei Aorteninsuffizienz. *Frankfurt. Ztschr. f. Path.*, 1925, **32**, 173. Die pseudovalvulären Bildungen des parietalen Endokards bei Aortenklappenfehlern und ihre Bedeutung. *Frankfurt. Ztschr. f. Path.*, 1929, **37**, 136.
12. Schmincke, A. Endocardiale Taschenbildung bei Aorteninsuffizienz. *Virchows Arch. f. path. Anat.*, 1908, **192**, 50.
13. Borst, M. Das pathologische Wachstum. Aschoff's Pathologische Anatomie, Jena, 1919.
14. Sotti, G. Sulle formazioni pseudovalvolari dell'endocardio parietale ventricolare. *Riv. veneta di sc. med.*, 1906, **16**, 493.
15. Ribbert, H. Die Erkrankungen des Endocards. Henke and Lubarsch's Handbuch der speziellen pathologischen Anatomie und Histologie, Berlin, 1924.
16. Saphir, O. Involvement of medium-sized arteries associated with syphilitic aortitis. *Am. J. Path.*, 1929, **5**, 397.
17. Libman, E. Discussion of Cohn's paper. *Proc. New York Path. Soc.*, 1914, **14**, 24.
18. Abbott, M. E. Two cases of widely patent foramen ovale. *Internat. A. M. Museums Bull.*, 1915, **5**, 129.
19. Wiggers, C. J. Modern Aspects of the Circulation in Health and Disease. Philadelphia, 1923.
20. Wiggers, C. J., and Green, H. Experimental aortic insufficiency. I. Regurgitation maximum and mechanisms for its accommodation within the mammalian ventricle. *Proc. Soc. Exper. Biol. & Med.*, 1930, **27**, 599.
21. Karsner, H. T. Human Pathology. J. B. Lippincott Co., Philadelphia and London, Ed. 2, 1929.

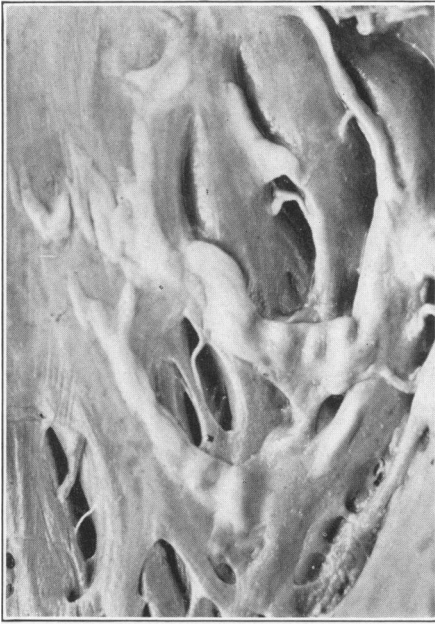---

## DESCRIPTION OF PLATES

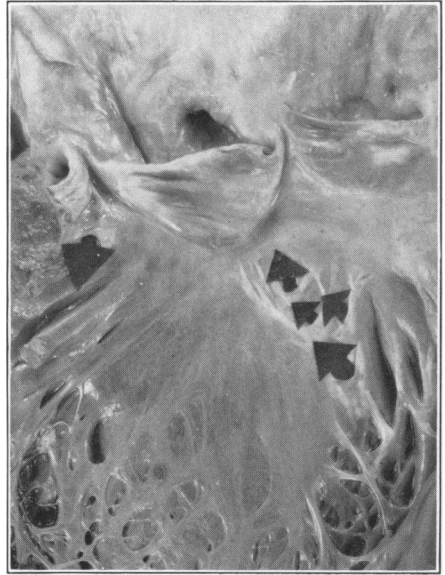### PLATE 137

- FIG. 1. Heart of Case 2. Diastolic pockets of the interventricular septum of the left ventricle.
- FIG. 2. Heart of Case 3. Diastolic pockets on the interventricular septum and one systolic pocket below the left aortic cusp.
- FIG. 3. Heart of Case 4. Diastolic pockets and one systolic pocket below the left aortic cusp. Note the marked dilatation of the heart.

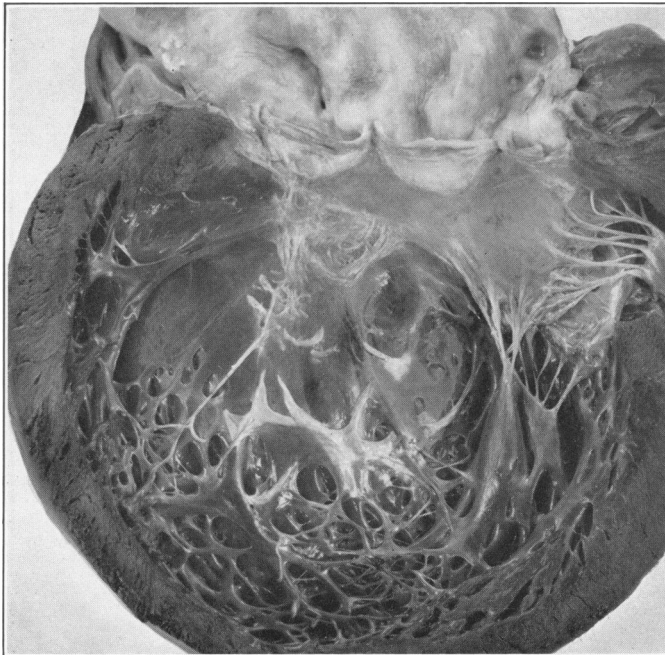




I



2



3

Saphir

Endocardial Pockets

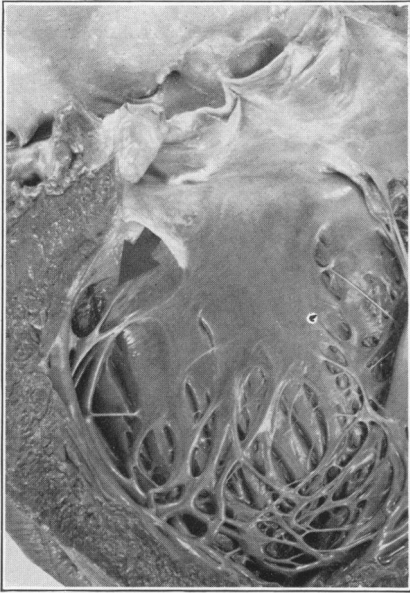
PLATE 138

FIG. 4. Heart of Case 5. One systolic pocket.

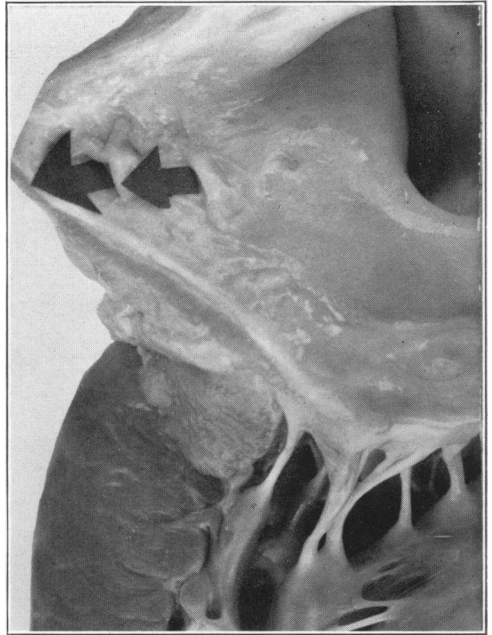
FIG. 5. Heart of Case 6. Note two endocardial pockets on the left auricular endocardium.

FIG. 6. Cusp of pocket of Case 2. Note the inflammatory cells. Iron hematoxylin and eosin preparation.  $\times 260$ .

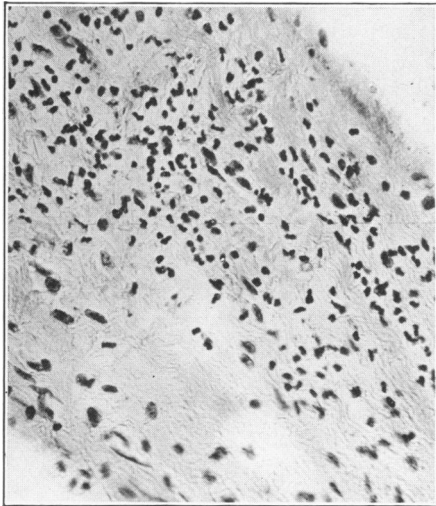
FIG. 7. Section of base of pocket of Case 2. Note the inflammatory cells. Iron hematoxylin and eosin preparation.  $\times 260$ .



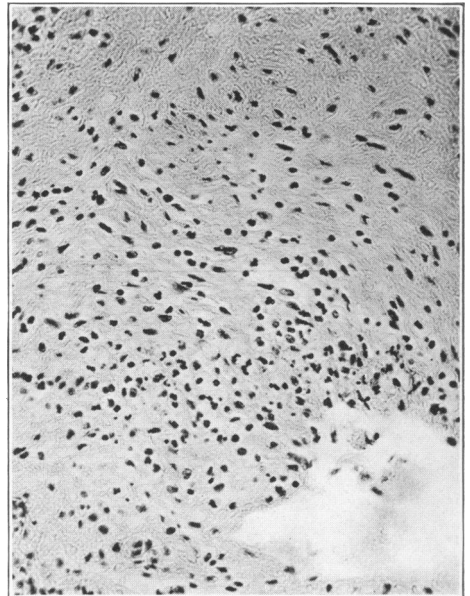
4



5



6



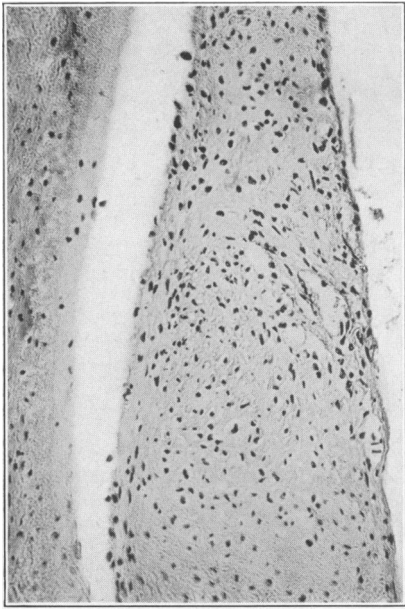
7

Saphir

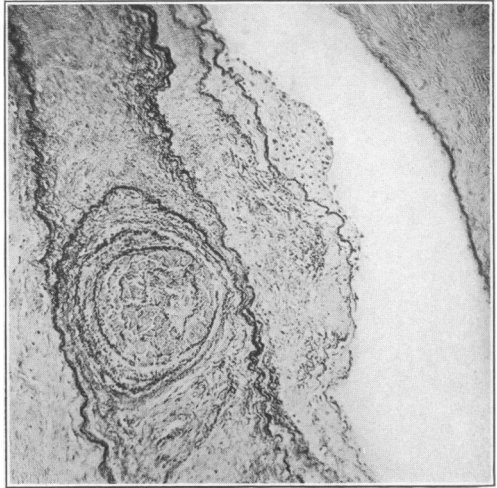
Endocardial Pockets

PLATE 139

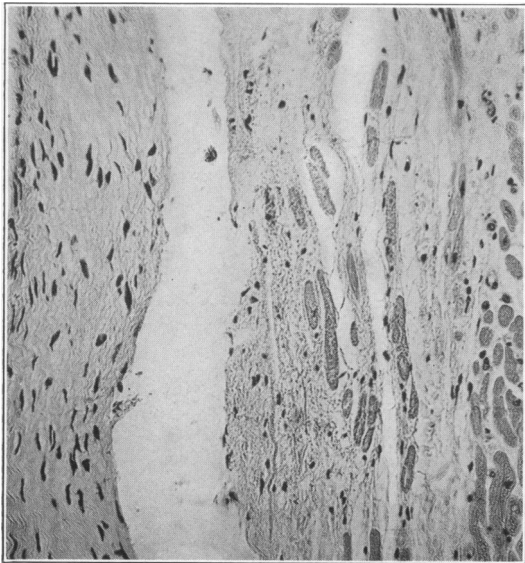
- FIG. 8. Cusp of pocket of Case 2. Note the newly formed blood vessels. Iron hematoxylin and eosin preparation.  $\times 180$ .
- FIG. 9. Fibrous band extending over one of the trabeculae carneae. Note the abundance of elastic lamellae. Orcein and iron hematoxylin preparation.  $\times 80$ .
- FIG. 10. Cusp of pocket and adjacent myocardium of Case 3. Note the spindle-shaped cells of the cusp and the atrophic muscle fibers. Inflammatory cells are not present. Iron hematoxylin and eosin preparation.  $\times 180$ .
- FIG. 11. Section of base of pocket of Case 6. Note the newly formed blood vessels. Iron hematoxylin and eosin preparation.  $\times 180$ .



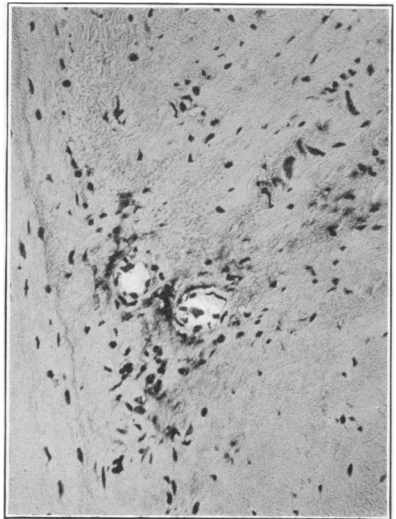
8



9



10



11

Saphir

Endocardial Pockets