

ESSENTIAL PULMONARY HAEMOSIDEROSIS AS AN IMMUNO-HAEMATOLOGICAL PROBLEM

BY

BÉLA STEINER

From the Department of Paediatrics of Szabolcs utca Hospital, Budapest, Hungary

(RECEIVED FOR PUBLICATION APRIL 5, 1954)

The 30 cases of essential pulmonary haemosiderosis hitherto published supply ample data to present not only the classical pattern of this disease but also its latent form. The condition mostly affects children; in adolescents (16 to 20 years of age) it was observed in two instances only (Waldenström, 1944; Walton and Williams, 1951) and the true nature of the adult cases reported by Borsos-Nachtnebel (1942) and by Ellman and Gee (1951) is still disputed. The collapse-like state repeatedly occurring at intervals of weeks or months is characteristic of the disease, whose predominant symptoms are cachexia, fatigue, pallor and cyanosis, dyspnoea and cardiac insufficiency; haemoptysis is frequent and at other times haematemeses, with abdominal complaints. The fingers may become clubbed.

The skin is pale, sometimes more or less icteric, and in certain cases bluish pink. The radiological findings may—in rare instances—be entirely negative or show large foci or an intense density in both lungs, but in a considerable number of cases the change suggests miliary tuberculosis. After the attacks the intensity of radiological signs may decrease, remain unchanged or occasionally progress. In the presence of characteristic symptoms diagnosis is not difficult. The fewer the symptoms the more difficult it is to differentiate the condition from iron-deficiency or haemolytic anaemia, or the radiograph from that of miliary tuberculosis. In the latent form bronchitis alone may be the guiding symptom (Scheidegger and Dreyfus, 1945). In the initial stage recognition of such a case may be possible only by special means. As long as the disease could not be cured and was attended by a 100% mortality, early diagnosis had no particular significance. Since, however, independently of each other, in England Paterson (1946), in Portugal de Castro Freire and Cordeiro (1948; Cordeiro, 1952) and in Hungary Steiner in 1952 have attempted not only to check the progress of the disease, but

also to make it regress by means of splenectomy, diagnosis in the early stage is of paramount importance.

Report of a Case

U.G., a boy, of 6 years of age, had been treated since October 11, 1950, in different hospitals because of weakness and anorexia; on one occasion the sputum had contained blood. A systolic murmur, marked anaemia (Hb 20%, R.B.C. 2,000,000), anisocytosis, poikilocytosis and increased haemopoiesis in the bone marrow had been found. Radiology had revealed a somewhat dense hilar structure and an enlarged heart. On treatment with iron, vitamin B and liver extract, the haemoglobin had increased to 60% and the red cell count to 3,500,000 per c.mm. The child was admitted to our department on five occasions, always on account of sudden malaise and extreme weakness. At the first admission, in July, 1951, he was an underdeveloped, undernourished boy with a yellowish skin, and somewhat enlarged submental and inguinal lymph nodes. The lungs were normal. The heart was slightly enlarged to the left, with a systolic murmur. The pulse was weak at 130 per minute. Radiographs gave a negative picture of the lungs, but the heart was slightly enlarged to both right and left and almost spherical. An electrocardiograph showed the electric axis deviated to the left, a sinus rhythm, tachycardia and a slightly depressed St₁.

Laboratory Findings. The red cell count varied during attacks between 1,600,000 and 2,800,000 per c.mm. After treatment it rose to 3 to 4,000,000. Haemoglobin was 20 to 30% on admission and 50 to 80% before discharge. The white cell count rose from 3,400 to 28,000 and differential counts were normal or shifted to the left, frequently with 10 to 26% eosinophils. Anisocytosis, polychromasia, pseudo-macrocytosis and microcytosis were marked. The reticulocyte count varied from 70 to 230 per thousand cells and became normal when the general health improved. Erythrocyte resistance was often normal; in many instances it was found to be decreased.

Bone marrow counts are presented in Table 1. Myelopoiesis and erythropoiesis were normal but greatly accelerated. While the normal proportion of myeloid to

erythroid elements is 3 to 1, in our case it was 0.6 to 1 or 1 to 1. The colour index was as a rule below 1, sometimes 0.6. The intradermal tuberculin test was repeatedly negative. The serum bilirubin level was 0.5 per 100 ml., and the urinary urobilinogen was not increased. During an attack in March, 1952, there was 4% albumin in the urine and 10 to 40 red corpuscles per visual field. Blood pressure was normal, Rumpel-Leede's sign was negative, bleeding and coagulation times were normal, and no blood could be demonstrated in the stools. The platelet count was once 90,000, at other times normal.

The patient was treated with iron, folic acid and liver extract. In one of the crises blood transfusions only were given. The blood counts returned to normal in about four weeks irrespective of the mode of treatment. Each remission was followed by a relapse. The course of the attacks is shown in Fig. 1.

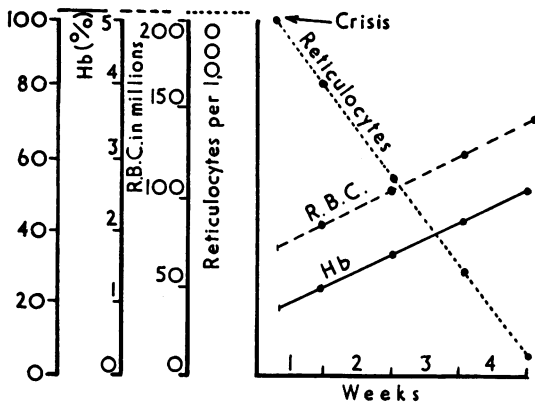


FIG. 1.—Diagram of the haematological response to treatment with iron, vitamin B and folic acid.

Indication for Splenectomy. The child was admitted to the Department three to four times a year with severe anaemia and in a grave state. The negative history, the absence of spherocytosis and the normal level of both bilirubin and urobilinogen were against familial haemolytic anaemia; acquired haemolytic anaemia could be excluded, since no autohaemolysin and agglutinin could be demonstrated. The negative radiological finding was assessed against essential pulmonary haemosiderosis.

The spleen was often hardly palpable; it extended in general by $\frac{1}{2}$ to 1 cm. beyond the costal margin. It must, however, be emphasized that Wiseman and Doan (1942) observed hypersplenism without enlargement of the spleen. In view of the frequent, almost fatal relapses and the failure of the therapy and the fact that the bone marrow count and the reticulocyte count exceeded 200 per thousand cells, splenectomy still seemed justified and accordingly the spleen was removed by Prof. B. Molnar.

Course of the Disease after Splenectomy. The child supported the operation relatively well, but on the third

day pneumonia developed. In spite of this blood counts showed a marked improvement (red cells, 3,710,000, white cells, 4,500 with 1 metamyelocyte, 23 young, 49 segmented neutrophils, 3 monocytes, 4 lymphocytes per 100 cells). There were 4% normoblasts and anisocytosis and polychromasia. Four weeks after the operation the child was discharged, apparently in good health. A blood count then gave 4 m. red cells and 72% Hb. Erythrocyte resistance was either normal or varied between 0.30 and 0.52 % NaCl.

Ten weeks after the operation the patient was brought back to the hospital in a bad condition developing after measles associated with pneumonia, from which time onwards he had frequently vomited and coughed. Clinical examination revealed pneumonia. The radiograph showed miliary tuberculosis. The tuberculin test was negative as before, but on account of the measles this could not be assessed against tuberculosis. No signs of tuberculosis were found either in the cerebrospinal fluid or by ophthalmological examination. The positive x-ray finding after measles had induced us to transfer the child to a tuberculosis ward of John's Hospital for streptomycin treatment. There a collapse-like state was once observed, when the child had tonsillitis accompanied by a temperature of 39° C. Within eight days the severe anaemia was under control. The radiograph did not show any change but the general state remained satisfactory.

When in March, 1953, the case was presented to the Section of Paediatrics with a diagnosis of hypersplenism, and it was pointed out that the primary or secondary character of the condition had not been diagnosed positively, Dr. I. Flesch suggested that the case might still be one of essential pulmonary haemosiderosis.

Laboratory Diagnosis of Essential Pulmonary Haemosiderosis. Certain points, however, were in favour of miliary tuberculosis: (1) the seemingly characteristic x-ray radiological finding, and (2) the recent measles. Against miliary tuberculosis was the fact that a tuberculin test could not have been negative with miliary tuberculosis except at the onset of the disease, soon after the measles. The fact that the Mantoux test remained negative in the subsequent months was a warning signal that the diagnosis of tuberculosis was erroneous.

It is characteristic of essential pulmonary haemosiderosis that macrophages containing haemosiderin are found in the alveoli and also the remnants of recent haemorrhage in the form of many red corpuscles. The alveolar walls and interalveolar septa are thickened, and there is an increased amount of reticulin and collagen fibres. The elastic fibres of the small and medium pulmonary vessels are swollen, brittle, hypoplastic and impregnated with iron. Up to the present, 'heart failure' cells in the sputum were considered of diagnostic value, such cells having been demonstrated in essential pulmonary haemosiderosis by Hanssen (1947), Wyllie, Sheldon, Bodian and Barlow (1948), King (1949) and Gellis, Reinhold and Green (1953). Our patient had no sputum. Blood in the faeces could not be demonstrated either before or after operation. No heart failure cells

were found in the gastric contents. Diagnostic lung puncture had not been tried. It had been applied in three cases of pulmonary haemosiderosis, but it involves a certain risk because of the nature of the disease. This is why a diagnostic procedure hitherto not applied in pulmonary haemosiderosis, exploratory thoracotomy with lung biopsy, was preferred. When we decided to resort to that procedure it was reassuring that, according to Bernatz and Clagett (1953), if the nature of a pulmonary lesion cannot be recognized with certainty and if the patient's life is in danger, thoracotomy has to be performed. The risk is slight, for Bernatz and Clagett have carried out exploratory thoracotomy with lung excision in 47 cases without any untoward results. On the strength of this experience, Dr. K. Joos carried out a lung biopsy.

According to the histological examination made by Dr. Schuler, of the First Institute of Pathological Anatomy and Cancer Research of Budapest Medical University, the alveoli were filled with mononuclear phagocytes containing iron (siderophages) and the interstices were somewhat thickened. The elastic system of the vessels was degenerated and impregnated with iron. The degenerating elastic fibres of the small vessels were phagocytosed by foreign-body giant cells. In some areas perivascular round-cell infiltration appeared.

The diagnosis was pulmonary haemosiderosis. If this is not consequent upon some disease of other organs or of the vessels, the case is one of essential pulmonary haemosiderosis.

Discussion

Effect of Splenectomy. The illness, from the first complaint to the operation, lasted 27 months, during which time the child was in a poor state of health. Seven times he was admitted in a grave state, and on each occasion he spent one to three months in hospital. During the six months after the operation the child had two attacks. In the interval the haemoglobin varied between 69 and 80%, and the red cell count between 3,000,000 and 4,200,000 per c.mm. The red cells did not respond to treatment with liver extract. It seemed instructive to study how far the course of the post-operative exacerbations differed from those before splenectomy. The first attack occurred on October 18, 1952, three months after the operation. It was preceded by measles and pneumonia. It was indicative of the seriousness of the crises that the up to then virtually negative radiograph revealed for the first time a marked change interpreted as typical of miliary tuberculosis (Fig. 2). In spite of the attack the haemoglobin varied between 54 and 63%, as against the 20% of the pre-operative crises. The red cell count varied from 3,340,000 to 2,890,000 per c.mm. while during the attacks before splenectomy it was frequently below 2,000,000 per c.mm.

The second crisis occurred on February 18, 1953,

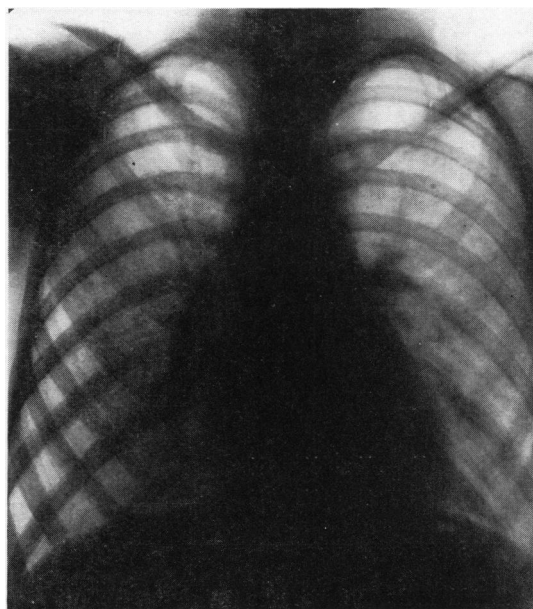


FIG. 2.—Radiograph of U. on October 27, 1952.

with follicular tonsillitis as the primary disease. At this time the child was in a state of collapse, with increasing dyspnoea, and a pulse rate of 160. The red blood cells decreased from 3,340,000 to 2,400,000 and the white cell count was 18,000 (150,000 thrombocytes). On February 22, 280 ml. of blood was transfused and by the next day the general state was considerably improved, with 70% Hb and 2,860,000 red cells. Eight days after the onset of the attack the red cells numbered 3,500,000, Hb was 70% and the platelet count was 210,000. Before splenectomy three to four weeks had been needed to cure the anaemia developing during an attack, but after splenectomy a sudden bout could be controlled in a single week. Blood counts in attacks before and after splenectomy are presented in Table 2.

The bone marrow yielded instructive data (Table 1). In the attacks before splenectomy marked hyperplastic erythropoiesis had been present with 147.6 erythroid to 100 myeloid cells. Immediately after the operation the hyperfunction ceased and only 22.2 erythroid elements were found per 100 myeloid ones. The number of reticulo-endothelial cells decreased from 6.8 to 0.8. In the first attack after splenectomy, in contrast to the previous episodes, a shift to the left in granulopoiesis presented itself. Increased erythropoiesis, anisocytosis, polychromasia, were again demonstrable. Basophilic stippling was present but the myeloid-

TABLE 1
BONE MARROW STUDIES

	Before Splenectomy (Oct. 19, 1951)	After Splenectomy		
		Aug. 4, 1952	Oct. 27, 1952	Nov. 5, 1953
Myeloblasts	0·2	0·6	0·6	0·6
Promyelocytes	4·4	6·0	7·0	5·1
Myelocytes	22·2	20·6	30·6	15·3
Metamyelocytes	20·0	17·2	29·6	20·9
Unsegmented neutrophils	19·6	17·6	15·0	25·1
Segmented neutrophils	7·6	17·8	2·7	17·1
Immature eosinophils	12·0	9·4	4·3	4·2
Mature eosinophils	3·6	3·4	1·0	0·3
Monocytes		0·2		
Lymphocytes	10·4	7·2	9·2	8·4
	100·0	100·0	100·0	100·0
Pronormoblasts	13·2	0·4	1·3	1·2
Macroblasts	23·6	1·8	3·6	3·0
Normoblasts	110·8	20·0	68·0	32·1
	147·6	22·2	72·9	36·3
Macrophages		0·2	0·2	
Lymphatic reticulum cells	3·2	0·2		1·2
Plasma-cellular cells	3·6	0·4	3·0	1·8
	6·8	0·8	3·2	3·0

erythroid ratio did not rise to above 100 to 72·9. At the same time the number of reticulocytes rose to 120 per 1,000 cells. On November 5, 1953, when for nine months no attack had been observed, bone marrow counts were normal, with 36·3 erythroid elements per 100 myeloid ones; anisocytosis and poikilocytosis were slight.

From February 20, 1953, to February 28, 1954, no exacerbation was observed. The child went to school, played football, was free of complaints. Despite the fact that the disease did not progress, a complete cure was not achieved, since the radiological finding, the clubbing of the fingers, the peculiar pinkish-blue tinge of the skin and the dyspnoea on stress have remained unchanged (Fig. 3).

Aetiology of Essential Pulmonary Haemosiderosis. Several theories concerning the aetiology of the disease have been put forward. Ceelen (1931) who

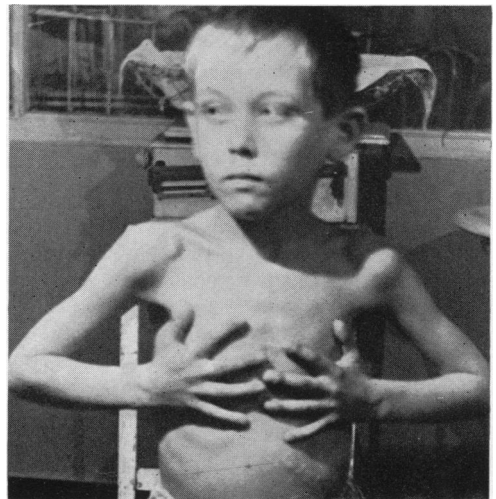


FIG. 3.—Patient's photograph.

TABLE 2
CRISIS BLOOD COUNTS

	Before Splenectomy (1951)			After Splenectomy (1952)	
	Oct. 12	Oct. 29	Nov. 15	Oct. 23	Nov. 28
Haemoglobin (%)	22	43	52	63	70
Red cells (c.mm.)	1·9	2·6	3·2	3·3	4·2
White cells	9,100	8,300	5,700	17,200	28,000
Unsegmented neutrophils	9	4	5	3	6
Segmented neutrophils	52	54	43	63	63
Eosinophils	13	16	20	1	—
Basophils	1	—	—	2	—
Lymphocytes	18	23	28	30	27
Monocytes	7	3	4	1	4
Reticulocytes (per 1,000)	220	95	16	—	—

first described the condition, attributed it to a primary developmental abnormality of the elastic fibres in the lungs, the elastic fibres showing fragmentation. This led to stasis in the capillary vessels, and to the haemorrhages both massive and per diapedesim. The primary defect would amply explain the progress of the disease as a consequence of the repeated haemorrhages.

The elastic fibres become impregnated with iron pigment, but occasionally bundles of elastic fibres which are not impregnated with iron would prove (Flesch, Schuler and Szöke, 1953) that the primary change is the defect of the elastic fibres, and this is followed by the haemorrhages and the formation of haemosiderin. According to this concept, the lethal outcome cannot be averted, and the most one can achieve is to relieve the anaemia developing during the relapse. Nitschke (1944), in view of the accumulation of haemosiderin, considered essential pulmonary haemosiderosis to be a storage disease.

The changes described by Ceelen, provided that the disease ran a protracted course, were observed by all subsequent authors.

It is remarkable that in the case of Scheidegger and Dreyfus (1945), in which the first symptoms had occurred at the age of 3 months and death at 1 year, neither defective development nor fragmentation of the elastic fibres, the very changes considered characteristic of the disease, could be found in the lungs. Nancekievill (1949) reported a similar case in a girl of 2½, in which hardly one and a half months elapsed between the onset of the symptoms and death, and in which a careful histological study could reveal no change in the elastic fibres. According to Nancekievill the so-called fragmentation of elastic fibres and the fibrotic thickening of the alveolar wall are, consequently, sequels rather than the cause of the disease. In the 3½-year-old patient of Reye (1945) the disease lasted 11 months and an increase in the number of elastic fibres could be demonstrated.

The three cases cited make it questionable whether hypoplasia of pulmonary elastic fibres should be truly regarded a primary symptom, and whether it is a consequence of some structural defect in the lungs. Against that assumption are (1) the course of the disease in my patient with its periodical attacks, which are hardly consistent with the permanently extant anatomical lesion, and (2) the increase in number of eosinophils, a finding frequently associated with allergic phenomena. Third is the fact that after splenectomy the attacks decreased in frequency and later completely ceased. Similar observations have been reported by British and Portuguese authors.

It is unlikely that splenectomy would have been capable of improving the state of the primarily defective pulmonary elastic fibres. What then might be the role of the spleen in the aetiology of the condition? Increased splenic activity, so-called hypersplenism, might cause a fall in the number of erythrocytes, either by inhibiting the bone marrow or by bringing about an increased destruction of red corpuscles. Inhibition of marrow activity was not present, since erythropoiesis was increased and the release of erythrocytes did not meet with obstacles. As to the second eventuality, in the removed spleen Malpighian follicles were normal but were fewer than usual and were irregularly situated. Some of these follicles were hyperplastic. The most characteristic feature under the microscope was a marked thickening of the usually delicate reticular basal tissue, which considerably exceeded in amount and took the place of the lymphatic substance. The lymphoid tissues were regular and stained adequately and there were relatively few erythrocytes between them. The number of eosinophils was, however, remarkably high, and these cells were scattered or in groups of eight to 10 in every field. No other kinds of cell occurred in the spleen, giant cells were not found, and there was no sign of increased erythrocyte phagocytosis (Dr. Vécsei). This finding corresponds to the so-called depressive or antihaemopoietic hypersplenism. In haemolytic hypersplenism, the considerable hyperaemia of the pulp, the swelling of the endothelial cells in the sinus, and eventually the presence of pigment macrophages are considered as typical. While in our case the number of Malpighian follicles was markedly reduced, Cordeiro (1952) observed in his patient a hypertrophy and hyperplasia of follicles, and emphasized that neither pulpar nor follicular fibrosis was present. In both cases splenectomy proved beneficial. It seems therefore probable that no increased destruction of red corpuscles ensued in the spleen.

If one wished to outline the aetiology of essential pulmonary haemosiderosis on the basis of the above data, taking into account both the clinical picture and the result of the splenectomy, the following concept appears justifiable. The spleen plays an important role in the origin of the condition, considering that after its removal the number of grave attacks decreased and none at all have occurred for a year. Paterson (1946), de Castro Freire and Cordeiro (1948) and Cordeiro (1952) have reported similar results. This, however, does not mean that the underlying factor is a simple hypersplenism in the old sense of the word; it seems probable that the disease is caused by some unknown sensitizing

agent eliciting auto-antibody formation. In the case of essential pulmonary haemosiderosis these antibodies occur in great quantity in the alveoli of the lungs. We believe that in essential pulmonary haemosiderosis the lung alveoli represent the shock tissue.

If on the impact of a fresh allergen an allergic reaction takes place in the pulmonary tissue sensitized in the above way, then in our opinion this will manifest itself in capillary dilatation, stasis, and an increase of permeability. As a consequence, a protein-rich exudate leaves the vessels, and diapedesic haemorrhages occur. In the present case the decreased resistance of erythrocytes has also contributed to the increase and to the intensity of the haemorrhage.

Wyllie *et al.* (1948) contributed valuable data to the assumption according to which in essential pulmonary haemosiderosis substances are produced which, as auto-agglutinins, viz. haemolysins, promote the increased destruction of erythrocytes. In one of their patients cold agglutinins against his own erythrocytes could be demonstrated in a titre of 1 to 10 million and against the cells of the O group in a dilution of 1 in 64. Wyllie *et al.* considered the high titre of cold agglutinins to be an antibody response to the destruction of erythrocytes in the child's lungs. In our opinion it is more probable that the agglutinins of high titre caused the lesion of the blood corpuscles and that the injured erythrocytes were more easily destroyed.

The fact that attacks occurred even after splenectomy may be explained in several ways. (1) An accessory spleen was left over. This could not be the case since later on the attacks stopped. (2) The spleen had no particular role in the condition except as part of the reticulo-endothelial system which continued to exert its effect after splenectomy. The fact that the bouts ceased favours the supposition that the spleen has an important function in the production of the sensitizing agent and its fixation. It probably also plays a role in the production of antibodies. On the strength of this concept, essential pulmonary haemosiderosis is an allergic disease and the mechanism of its origin is closely related to those of acquired haemolytic anaemia and idiopathic thrombocytopenic purpura.

Conclusions

This concept of the aetiology of essential pulmonary haemosiderosis leads to vitally important conclusions. In the first place it removes the condition from the list of the infallibly lethal

diseases and declares it curable, substituting for the morphological explanation a functional one. On the basis of the old theory no search for an eliciting agent was needed, the anatomical lesion having been considered a basic feature of the disease, whereas today the investigation of the sensitizing agent has come to the fore.

Early diagnosis assumes a far greater importance, since it has become possible to anticipate complete regression, whereas in the case of a belated diagnosis, irreversible changes may have already occurred in the lungs. If the disease has lasted several years certain points in the history may easily escape due attention. Thus, in our case with periodical attacks, no attention was paid to the fact that a tuberculin-negative child had had a haemoptysis. On the strength of recent knowledge this point by itself would justify taking essential pulmonary haemosiderosis into account in the differential diagnosis. At the onset of the disease the chest radiograph may be entirely negative.

The absence of an enlarged spleen is no reason against splenectomy. For the time being this is the only curative procedure. It seems worth while to administer A.C.T.H. (Stefanini, Roy, Zannos and Dameshek, 1950) or cortisone before operation.

Further experience will show whether the beneficial effect of splenectomy will manifest itself in those forms of essential pulmonary haemosiderosis in which (a) heredity can be demonstrated, (b) the resistance of red blood corpuscles is not decreased, (c) no erythroid hyperplasia occurs in the bone marrow.

Summary

A case of essential pulmonary haemosiderosis diagnosed during life is described.

Diagnosis was made by thoracotomy.

As a therapeutic measure splenectomy was performed. Thereafter the disease ceased to progress and not a single attack associated with anaemia was observed for 12 months. This is the fourth case in the world literature improved in this way.

Essential pulmonary haemosiderosis is considered to be an immuno-allergic disease, caused by a still unknown sensitizing agent inducing the production of auto-antibodies. The antigen-antibody reaction causes in the lungs, as the shock organ, capillary dilatation, consequent stasis, diapedesis, rhexis, increased destruction of the injured red corpuscles and deposits of haemosiderin.

Early diagnosis must be aimed at, since in this way there is hope for complete restoration to health.

REFERENCES

- Bernatz, P. and Clagett, O. T. (1953). *J. Amer. med. Ass.*, **152**, 379.
- Borsos-Nachtnebel, O. (1942). *Zbl. allg. Path. Anat.*, **79**, 174.
- Castro Freire, L. de and Cordeiro, M. (1948). *Helv. paediat. Acta*, **3**, 255.
- Ceelen, W. (1931). In *Handbuch der speziellen pathologischen Anatomie und Histologie*, ed. F. Henke and O. Lubarsch, Bd. 3, t. 3. Berlin.
- Cordeiro, M. (1952). *Helv. paediat. Acta.*, **7**, 501.
- Ellman, P. and Gee, A. (1951). *Brit. med. J.*, **2**, 384.
- Flesch, I., Schuler, D. and Szöke, G. (1953). *Gyermekgyógyászat*, **4**, 300.
- Gellis, S. S., Reinhold, J. L. D. and Green, S. (1953). *Amer. J. Dis. Child.*, **85**, 303.
- Hanssen, P. (1947). *Acta. paediat., Uppsala*, **34**, 103.
- King, A. B. (1949). *Proc. roy. Soc. Med.*, **42**, 87.
- Nancekievill, L. (1949). *Brit. med. J.*, **1**, 431.
- Nitschke, A. (1944). *Klin. Wschr.*, **23**, 348.
- Paterson, D. (1946). *Proc. roy. Soc. Med.*, **39**, 131.
- Reye, D. (1945). *Med. J. Aust.*, **1**, 35.
- Scheidegger, S. and Dreyfus, A. (1945). *Ann. Paediat., Basel*, **165**, 2.
- Stefanini, M., Roy, C. A., Zannos, L. and Dameshek, W. (1950). *J. Amer. med. Ass.*, **144**, 1372.
- Waldenström, J. (1944). *Acta radiol., Stockh*, **25**, 149.
- Walton, M. and Williams, A. (1951). *Brit. med. J.*, **2**, 390.
- Wiseman, B. and Doan, C. (1942). *Ann. intern. Med.*, **16**, 1097.
- Wyllie, W., Sheldon, W., Bodian, M. and Barlow, A. (1948). *Quart. J. Med.*, **17**, 25.