

THE CARDIO-OESOPHAGEAL SYNDROME IN CHILDHOOD

BY

ISABELLA FORSHALL

From Alder Hey Children's Hospital, Liverpool

The term 'cardio-oesophageal syndrome' is used to cover all infants and children with incompetence of the cardia. Ninety-three instances of the syndrome have come to our notice during the last three and a half years. In some of these children the cardia was found to be below the diaphragm; in some, above the diaphragm (Table 1).

TABLE 1
CARDIO-OESOPHAGEAL SYNDROME IN 93 CASES

Sliding Hernia Cardia above Diaphragm (35 Cases = 39.5%)		Lax Oesophagus Cardia below Diaphragm (58 Cases = 69%)
35 + 4 = 39 Cases (42%)	←-----→	4 Cases, Cardia herniated through Diaphragm
65%	Vomited from birth 6%	69%
93%	Vomited before 8 weeks 96%	100%
15%	Vomited projectile 25%	43%
51%	Haematemesis 37%	26%
52%	Gross loss of weight 36%	23%
5%	Visible gastric peristalsis 13%	19%
5%	Rammstedt's operation 10%	14%
100%	Cardia incompetent 100%	100%
Usually slightly dilated	Oesophagus	Often grossly dilated
High incidence	Oesophagitis	Low incidence
19%	Definite ulcers	None
19%	Stricture	None

It is proposed to divide the cases on the basis of the position of the cardia. There is a superficial similarity between the two groups but the course of the disease, the prognosis, and perhaps the aetiology, are not the same. We believe that the treatment is entirely different.

* A paper given at the inaugural meeting of the British Association of Paediatric Surgeons in London in July, 1954.

Group 1: Lax Oesophagus

When the incompetent cardia is situated below the diaphragm, we term the condition 'lax oesophagus'. It was first recognized as an entity distinct from hiatal hernia by Neuhauser and Berenberg in 1947. Although it is quite a common condition in babies, it has found scant recognition in the surgical literature (Berenberg and Neuhauser, 1950a and b). Neuhauser used the name 'chylasia of the cardia' because of the obvious incompetence of the cardiac orifice, but we prefer the name 'lax oesophagus', a term coined by our colleague, Dr. Saul Keidan (1953), because we think that it is not only the cardia which is relaxed but also the whole lower two-thirds of the oesophagus.

Incidence. It is difficult to form a definite idea of the incidence of the condition. The 58 cases included in this series were not all directly under our care; records were made available to us by the paediatricians working at the three children's hospitals on Merseyside. Mild examples of the syndrome treated as out-patients are not included in this survey. We compute that there are about 30 to 40 cases amongst the 41,000 babies born each year in the Liverpool region.

Sex. Of the 58 cases, 32 were boys and 26 were girls. There was one pair of fraternal twins, a boy and a girl. Apart from these twins, we have not had two cases in one family, but mothers have mentioned that previous children died or recovered from similar symptoms.

Birth Weight. The birth weights of our cases covered the normal range; few were much below average in weight.

Symptoms and Signs. Vomiting or regurgitation, or both, was the cardinal first symptom in every case. Vomiting dated from birth in a high proportion and almost invariably started before 2 weeks of age. The vomiting occurred during or between feeds and was projectile in 43% of cases.

The following points were noticed about the vomitus:

HAEMATEMESIS. Bright red or brown altered blood was visible to the naked eye in 26%. It was significantly less frequent than in the hiatal hernia group, due to a lower incidence of reflux oesophagitis.

BILE. A few babies vomited bile-stained material for a few days after birth.

MUCUS. Mucus was regurgitated or mixed with the vomitus from birth in some cases, but less often than in babies with hiatal hernia.

Gross loss of weight occurred in 23%. It was much less common than in the other group. This is, at least in part, accounted for by a more ready response to treatment. Failure to gain for longer or shorter periods was common.

Severe dehydration demanded parenteral fluids in 15%.

Anaemia due to bleeding or to malnutrition was found to some degree in about 40%.

Pain, discomfort, flatulence and general misery were noted in various degrees and combinations.

Visible gastric peristalsis was noted in 19% of cases. Visible peristalsis and an association with hypertrophic pyloric stenosis occurred more often in this group (Fig. 1). As our numbers are small, this is possibly not significant. It will be noticed that visible gastric peristalsis occurred more fre-

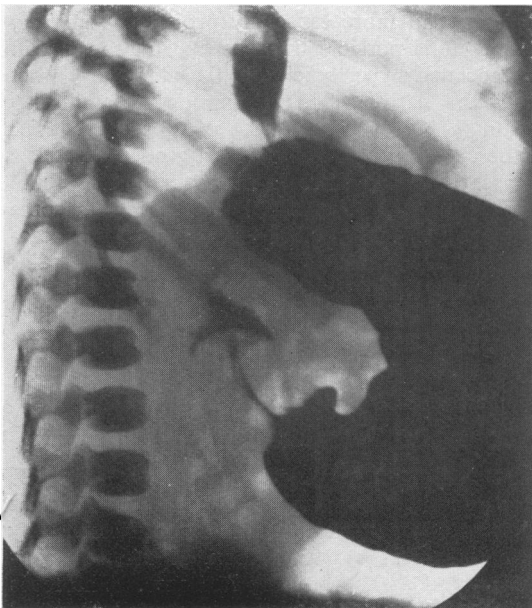


FIG. 1.—Barium swallow showing typical picture of pyloric stenosis. There is free regurgitation from the stomach into the oesophagus. Pyloric stenosis with lax oesophagus.

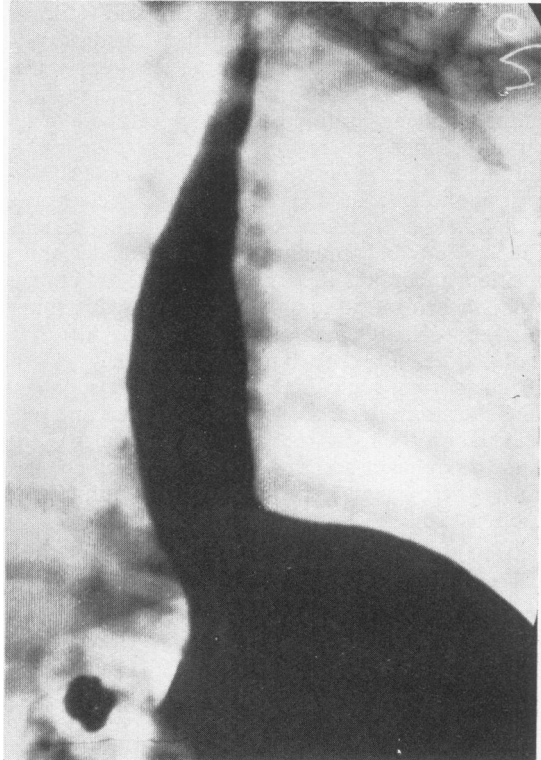


FIG. 2.—Typical lax oesophagus. There is free regurgitation from the stomach into the dilated oesophagus.

quently than can be accounted for by the high incidence of pyloric stenosis; the same is true of projectile vomiting. Eight cases underwent Rammstedt's operation. Six of these operations were done while the babies were under our care; four were irrefutable cases of hypertrophic pyloric stenosis. Two babies were described as having a very small tumour, or some thickening of the pyloric region. Two cases were operated upon before coming to us and we have no certain knowledge of the condition of the pylorus.

It might be argued that in these eight children the cardiac reflux was due to back-pressure from the pyloric obstruction. The following points refute this suggestion: The uncomplicated case of pyloric stenosis never shows a patulous cardia on screening; these eight babies all continued to vomit and regurgitate after Rammstedt's operation, the adequacy of which was proved radiologically; visible gastric peristalsis was seen in a number of babies in whom no pyloric tumour was felt and in whom no radiological evidence of hold-up at the pylorus was demonstrated.

Radiological examination is required to prove

that an incompetent cardia is present and to decide its situation. The technique of the investigation is not easy and misleading reports are common unless the radiologist is used to dealing with young infants and is familiar with fluoroscopic appearances of the cardio-oesophageal region during swallowing in normal babies. The points to note are: (1) Free regurgitation from the stomach of the opaque material (Fig. 2); reflux is increased during inspiration, crying and coughing, in the Trendelenburg position, and if pressure is exerted over the abdomen, that is, when intra-thoracic pressure is reduced and intra-abdominal pressure is increased. (2) The cardia does not close but remains widely patent. (3) The normal acute angle at which the oesophagus joins the stomach on the left side is obtuse and may be equal on the right and left. (4) Muscular waves in the oesophagus are irregular and of small volume. (5) The oesophagus appears wider than normal and is often extremely distensible (Fig. 3).

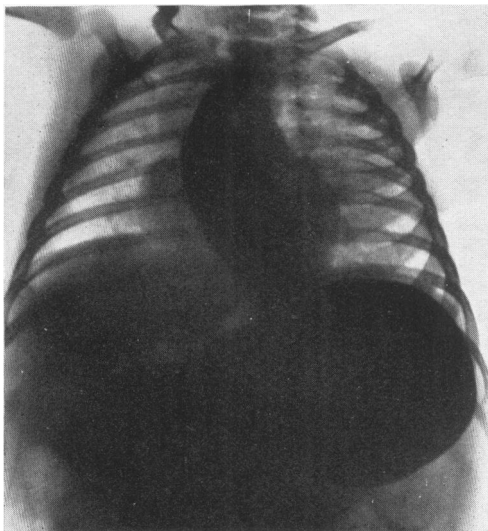


FIG. 3.—Lax oesophagus showing enormous dilatation of the lower two-thirds of the oesophagus in a baby aged 3 days.

The very gross dilatation of the oesophagus in these cases is very remarkable; it is often present within a few days of birth, and sufficient to merit the term 'mega-oesophagus' (Fig. 3.) Only the lower two-thirds of the gullet is affected, that is, the plain muscle portion supplied directly by the vagus and which, according to Lendrum (1937), is supplied by the vagus only.

At oesophagoscopy the lumen of the oesophagus appears voluminous; gastric contents well up from the stomach and the instrument falls through the

patulous cardia. The oesophago-gastric junction can be recognized without difficulty in most cases. Oesophagitis in various stages of acuteness and affecting various lengths of the lower third of the oesophagus may be seen. We have not seen a chronic peptic ulcer or stricture in a case in which the cardia remained below the diaphragm.

It has been suggested that the condition we call 'lax oesophagus' is in fact due to a small hiatal hernia which could be shown by careful screening. There is no doubt, however, that apart from four exceptions to be mentioned later, the cardia in these 58 children was below the diaphragm and remained there. This was proved by repeated radiography and oesophagoscopy.

Necropsy on three cases gave the following information:

The cardia, taken as the junction of stratified and columnar epithelium, was below the diaphragm. The cardia could not be pulled up into the chest until the membranes attaching the oesophago-gastric tube to the diaphragm had been divided. The hiatus was not considered to be unduly large, but it is difficult to assess the size of the oesophageal hiatus at operation, and probably more difficult at necropsy.

It is easy to understand that these children regurgitate and that regurgitation will be encouraged by recumbency and any factor which increases intra-abdominal pressure. It is not so easy to explain why vomiting, and more especially projectile vomiting, occurs. It is possible that the explanation lies in an associated hypertonicity of the alimentary tract below the cardia. This assumption would also explain (a) the high incidence of pyloric stenosis; (b) the occurrence of well-marked gastric peristalsis in cases in which there is no hypertrophy of the pylorus; (c) the bile-stained vomit seen in some cases soon after birth; (d) dilatation of the oesophagus in the absence of obstruction of the cardia; (e) the very interesting fact that one of our 'lax oesophagus' babies developed obstructive jaundice, which, at operation, was found to be due to spasm of the sphincter of Oddi.

Course of Disease, Prognosis and Treatment

The treatment of these cases is more or less standardized. They are nursed in the upright sitting position by means of pillows, harness, or by placing them in a padded box, to reduce regurgitation and make vomiting less easy. The feeds are thickened by the addition of 'nestergerl', 'bengers' or cornflour.

Small, frequent feeds may be used so that the

stomach is not distended. Aludrox, or some other antacid, may be used to discourage oesophagitis. Anti-spasmodic drugs have little effect, though there has been an occasional apparent improvement with pylostoprin.

The response to these measures is often dramatic; vomiting ceases, the child gains weight, and as the regime is gradually relaxed, symptoms do not recur. In some cases, improvement is slow or delayed, or symptoms recur as soon as the child is allowed out of the upright position. Many of these infants have been critically ill for weeks or months and have suffered serious complications (Table 2).

Four children with a proved lax oesophagus and a cardia below the diaphragm developed severe oesophagitis, and, over the course of months, the cardia was gradually pulled up into the chest. Three of these children later developed chronic

upon at the age of 5 months and responded well to simple narrowing of the hiatus by stitches placed through the fibres of the right crus behind the oesophagus. At this single operation for 'lax oesophagus' the cardia was below the diaphragm. The hiatus did not appear larger than could be accounted for by the size of the oesophagus it accommodated.

Seven children died and the immediate cause of death is shown in Table 2.

To summarize, we think, in common with others, that the condition probably has a nervous or neuromuscular basis which involves the lower two-thirds of the oesophagus, the cardia, and perhaps the gastro-intestinal tract below the cardia. We realize that this is no real explanation. We are in doubt about the responsibility which the hiatus bears. The condition is often self-limiting and at least three-quarters of these children will recover with simple treatment.

Lax oesophagus cannot, however, be regarded with complacency as an unimportant condition out of which the child will grow. In our cases, serious complications were common. Many patients were in hospital for long periods, up to nine months, or had more than one admission. During this time they occupied badly needed medical beds and absorbed valuable skilled nursing time. From the mother's point of view, it cannot be much satisfactory to have a baby who sits in a box in a hospital ward. There was a mortality of 12%. We have no evidence that the course of the disease can or should be shortened by operation. If surgery were to be seriously considered, it would be difficult to decide its indications; during a bad phase, these babies would be poor risks, and when they improve, one cannot judge if the improvement is temporary or permanent.

Careful follow-up of these children and repeated radiological examination of those in whom vomiting persists, or in whom weight gain is unsatisfactory and those who relapse is indicated, so that the occasional case in which the cardia herniates above the diaphragm may be picked up as early as possible.

Group II: Sliding Hiatal Hernia

When the incompetent cardia is situated above the diaphragm the condition is usually called a sliding hiatal hernia. Findlay and Kelly (1931) and Kelly (1939) recognized that stricture of the oesophagus in children was associated with a partial thoracic stomach. Wyllie and Field (1946) described six children with partial 'short oesophagus and thoracic stomach' but did not mention that the

TABLE 2
RESULTS IN 58 CASES OF LAX OESOPHAGUS

Medical Treatment	
<i>Satisfactory</i>	
Children doing well, vomiting has ceased, weight increasing	45 cases (79%)
Some had long periods in hospital or repeated admissions due to relapse; the following complications were recorded:	
Gastro-enteritis	6 cases
Pneumonia	4 cases
Bronchitis	1 case
Lung abscess	1 case
<i>Failed</i>	
(a) Unsatisfactory. Child 1½ years old, still vomiting and much below expected weight	1 case
(b) Developed sliding hernia, and included under this heading	4 cases
(c) Operation, aged 5 months, repeated relapses and failure to gain weight	1 case
(d) Deaths due to the following causes	7 cases (12%)
Gastro-enteritis	
Necrosis of lower end of oesophagus	
Oesophagitis and septicaemia	
Haematemesis	
Gastro-enteritis and lung abscess	
Inhalation of vomit	
Induction of anaesthesia for oesophagoscopy; poor-risk infant	

(All cases were initially treated medically).

oesophageal ulcer with stricture (Figs. 4, 5, 6 and 7).

One child, still being treated medically at the age of 18 months, is still vomiting and regurgitating and much below weight.

Forty-five of the 58 cases (79%) are considered to have made, or to be making, a satisfactory recovery. Some of them have been radiologically examined after symptoms have ceased for various lengths of time and in these cases it has been demonstrated that the cardia has contracted, that reflux no longer occurs, and that the lumen of the oesophagus is narrowing.

One child, after repeated relapses, was operated

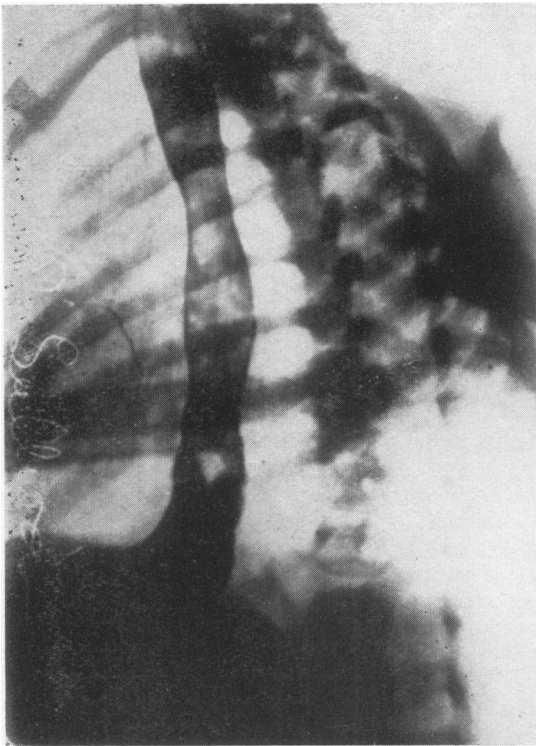


FIG. 4.—A series of barium meal swallows on the same patients taken at two-monthly intervals. This picture shows a typical lax oesophagus with free regurgitation.

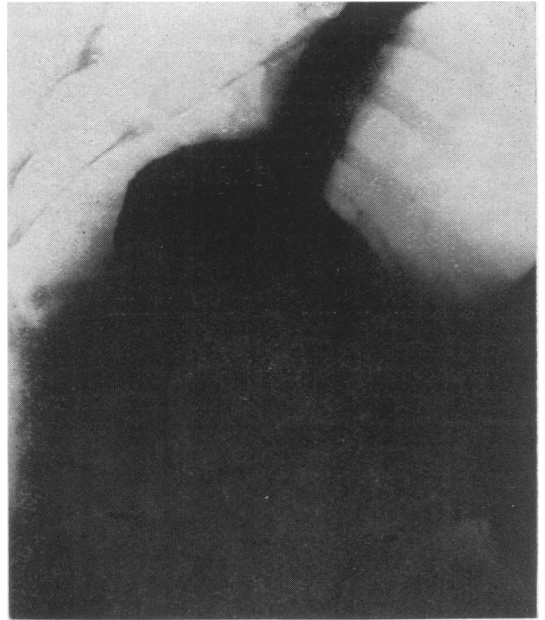


FIG. 5.—A series of barium meal swallows on the same patient taken at two-monthly intervals. In this picture the patient has developed a small hiatus hernia.

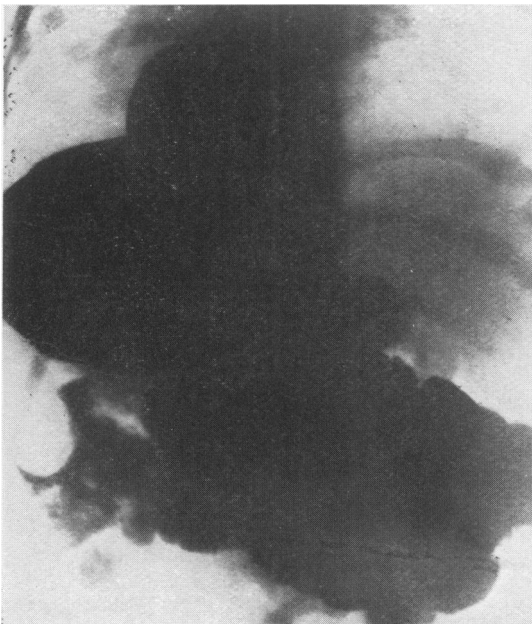

FIG. 7.—A series of barium meal swallows on the same patient taken at two-monthly intervals. In this picture there is an enormous hiatus hernia.

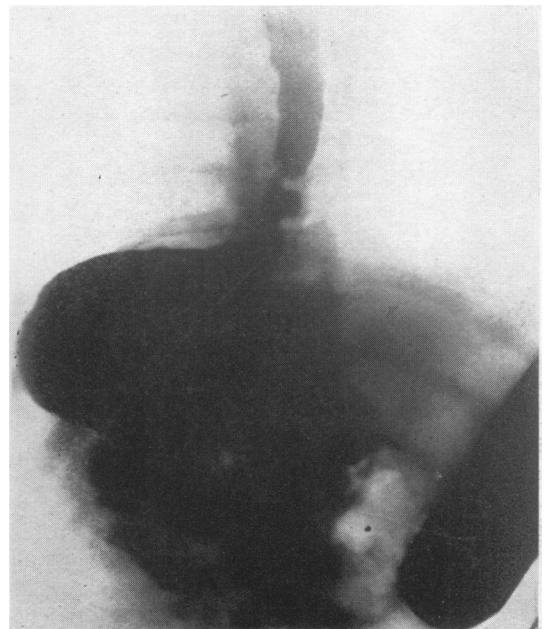


FIG. 6.—A series of barium meal swallows on the same patient taken at two-monthly intervals. In this picture the hiatus hernia has increased slightly in extent. There is a suggestion of stricture formation.

same symptoms are more commonly produced by an incompetent cardia below the diaphragm. There have been many excellent articles in the surgical journals on hiatal hernia during the last few years (Barrett, 1950; Allison, 1946, 1948, 1951; Harrington 1942, 1945; Belsey, 1954, etc.), but few surgeons have published a series of the abnormality in infants and children.

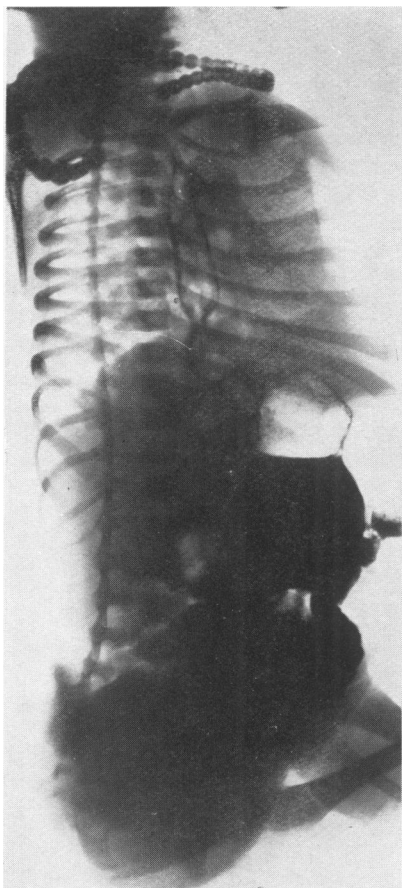


Fig. 8.—Barium swallow on a baby 48 hours old showing definite hiatus hernia.

In 35 of our 93 cases the cardia was above the diaphragm at the initial radiological examination. Some children were radiographed before the age of 4 or 5 days (Fig. 8), but most of them were a few weeks old and some older still.

At operation, the fibres of the right crus which form the hiatus invariably appear poorly developed, especially the part of the crus which forms the left and posterior aspect of the hiatus. In some cases,

the posterior fibres are virtually absent. We think also that the diaphragm as a whole is often unduly thin, almost flaccid to the touch. We do not consider that the oesophagus is initially short; by and large, the younger the child the more easily can the cardia be placed below the diaphragm. Six cases were observed in which, during screening, the cardia was seen to be sometimes above and sometimes below the diaphragm; in all six cases it ultimately settled above. The four cases which started as lax oesophagus and went on to become sliding herniae are also significant. We have failed to find a description of a hernia of this kind in a stillborn infant. We do not certainly know the position of the cardia at birth. We do know that in at least some cases, the cardia has, at some time, been below the diaphragm and that it is drawn up through the hiatus. The migration of the cardia is probably dependent upon the difference in intra-thoracic and intra-abdominal pressures. We are of the opinion that a sac is present though it may be very small.

These facts suggest that the condition is probably a true herniation of the cardia from the abdomen into the posterior mediastinum. They do not prove that the condition is invariably produced in this way. Aetiologically, therefore, we consider that a poorly developed hiatus bears a heavy responsibility and is the 'congenital' element in this type of hernia. We consider that shortening of the oesophagus is secondary and results from oesophagitis and spasm, as in adults. In children, failure of the oesophagus to grow would ultimately produce relative shortening, and it is at least possible that this may be a significant factor in some cases. It will be seen that we do not consider the term 'congenital short oesophagus' justified.

Radiologically the oesophagus is not so dilated as in the lax oesophagus group. The diameter of the gullet is often about the same as that of the small segment of thoracic stomach. The supra-diaphragmatic stomach can be recognized radiologically by coarse vertical gastric rugae outlined by barium and a slight constriction at the cardio-oesophageal junction. On oesophagoscopy the junction can be identified by the transition from relatively smooth to coarse vertically ridged mucosa. The diaphragmatic pinch-cock is absent. Reflux is marked and constant. Oesophagitis is almost invariably seen; the degree of acuteness varies and it has a tendency to wax and wane.

The symptoms of hiatal hernia in infancy are due to the incompetence of the cardia and not to the cardia being situated above the diaphragm. We have, in common with others, had infants with

hiatal hernia in whom half or more of the stomach is above the diaphragm, and yet the cardia is competent, in spite of being divorced from the hiatus. In these cases symptoms may be entirely absent; if present, they conform to an entirely different pattern from the symptoms of the cases under discussion. The symptoms of these 35 children showed significant percentage differences from the lax oesophagus group. Projectile vomiting was less common; it is difficult to account for this. If projectile vomiting is a reflex phenomenon, one would expect it to be more likely to occur in the hernia group. Haematemesis occurred much more commonly due to the higher incidence of reflux oesophagitis. It is not clear why reflux oesophagitis is commoner in the hernia group as the same free reflux occurs in both. Gross loss of weight again was more often noted, at least in part, due to a less ready response to treatment. Visible gastric peristalsis was not seen, apart from the two cases of pyloric stenosis. These cases do not give the same evidence of being associated with a widespread neuromuscular imbalance as do children in the lax oesophagus group.

Course of the Disease. In our experience, the response to posture is often unsatisfactory and a tendency to relapse marked. Complications fall into two groups: (1) The same tendency to contract chest infections, gastro-enteritis and to aspiration of vomit as the lax oesophagus cases; (2) complications in the oesophagus itself as follows:

SHORTENED OESOPHAGUS. Shortening of the oesophagus is a result of continued severe oesophagitis. It is known that once inflammatory changes brought about by the reflux of gastric secretions penetrate deep to the mucosa, fibrosis spreads up and down the oesophagus and results in shortening. It is also known that the different layers of the oesophagus are more loosely adherent in children, and that in them inflammatory spread and fibrosis occur more readily. Shortening of the oesophagus is common and may occur with astonishing rapidity.

PEPTIC ULCERS. In 30% of our cases there was radiological evidence of ulcer formation. The radiological findings were confirmed at oesophagoscopy. The ulcer was invariably in the oesophagus and usually within 1 in. of the cardia. We have not seen a chronic peptic ulcer in the thoracic portion of the stomach, either on screening or on oesophagoscopy. This important and interesting difference from sliding hiatal hernia of adults is probably related to the rarity of chronic peptic ulceration of the stomach and duodenum in children. We have not seen an ulcer at the cardia

or in its immediate neighbourhood, and presume that the extreme lower end of the oesophagus is immune to the action of acid pepsin. One ulcer perforated into the mediastinum and at operation gave much the same picture as a chronic duodenal ulcer which has perforated into the pancreas.

STRICTURE. Some narrowing of the oesophagus occurred in 30% of cases. It was more common in cases with ulcer, but also occurred in cases in which a definite ulcer was not seen. The length of the narrowing varied from $\frac{1}{2}$ to $2\frac{1}{2}$ in.; it is difficult to assess radiologically as the barium is held up at the upper limit of the stricture and then trickles through in a thin stream, giving the impression of a long, narrow area. In the presence of spasm or stricture the proximal oesophagus dilates and hypertrophies (Figs. 9 and 10). In many cases, oesophagoscopy showed less narrowing than the radiograph had suggested; presumably spasm plays a part in producing the radiological appearances. Only one stricture required a gastrostomy.

Dysphagia due to a stricture can be temporarily relieved by dilatation. The amount of dilatation that can be obtained through an oesophagoscope in a small child is not very great. Dilatation encourages further reflux and perhaps encourages shortening, but as a temporary measure to improve swallowing and nutrition it has proved valuable.

With continued severe oesophagitis and associated spasm, or with the development of true

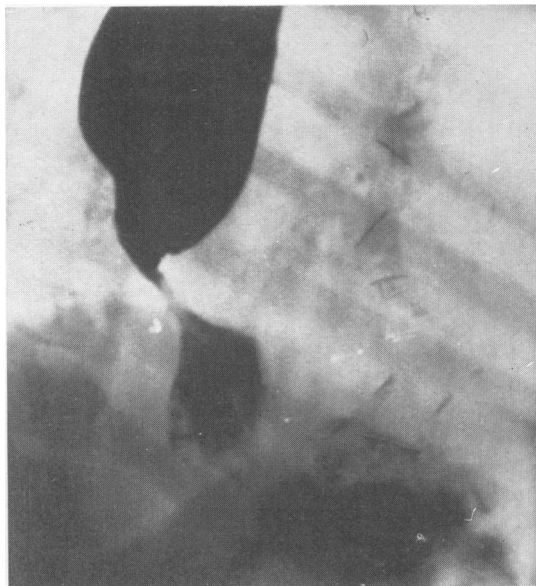

FIG. 9.—Barium swallow in a case of hiatus hernia with stricture showing marked dilatation of the proximal oesophageal segment.

narrowing, the symptoms change; solids and semi-solids are taken with more difficulty than liquids. Some mothers have stated that their baby is never happy until he has vomited. Older children complain of epigastric or retrosternal pain, discomfort or a sense of fullness after food. Some children become resistant to all nourishment.

Regurgitation is more common than true vomiting; mucus in large quantities is sometimes brought up after and between feeds and it may be blood-stained. Sometimes, the chief complaint is of the long time taken by the child to eat a small meal. Occasionally, children induce vomiting by putting their fingers down their throats. Weight gain is slow, or there is none; the patients are small for their age and tend to become self-centred and introspective. One or two children have given the impression that their only pleasure in life is to return, as soon as possible, any nourishment forced upon them.

Not all cases follow this severe course. A few improve with weaning, some have gained weight and appear well and happy with the cardia well above the diaphragm.

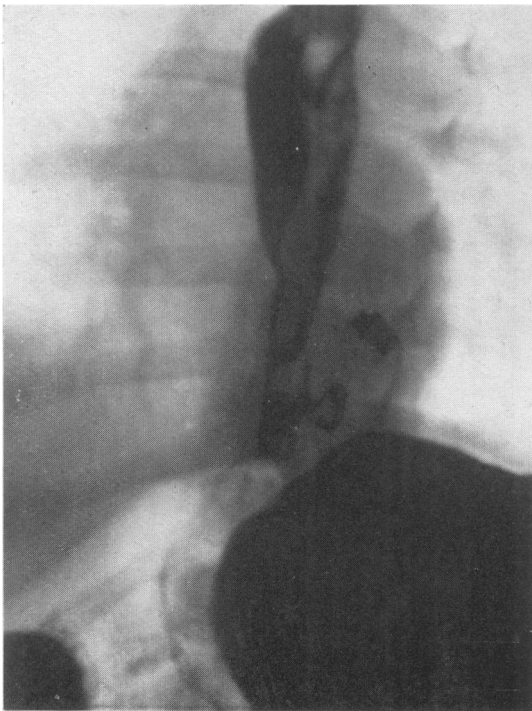


FIG. 10.—Same case as Fig. 9 after operation. The stomach is now well below the diaphragm. There is still slight dilatation of the proximal oesophagus. The level of the diaphragm is indicated by the two Michel's clips.

Operative Findings. The cardia has been found anywhere from just above the diaphragm to the level of D.6. (In one case which we had the opportunity of examining but not of operating upon, it was at the level of D.4-5.)

I consider that there is usually little difficulty in recognizing the position of the cardia at operation; there is generally a slight constriction at the cardio-oesophageal junction and a slight but definite change in the arrangement of the muscle fibres, and, I think, in the direction in which the arteries run. The level at which the cardia has been found at operation has usually conformed to radiological and endoscopic findings. In cases which have had prolonged oesophagitis, ulcers or strictures, there has been a varying amount of fixation of the oesophagus and it is firm and rigid to the touch. Enlarged lymph nodes are common, especially with chronic peptic ulcer.

In small children the vagi are usually of sufficient length not to form an obstacle to replacement of the cardia below the diaphragm. In cases where the cardia is high, and in older children, the vagi have sometimes appeared shorter than the freed oesophagus; twice we have divided the branches connecting the right vagus with the pulmonary plexus in order to get sufficient length.

The four cases of lax oesophagus which developed sliding hernia showed no variation from those in which the cardia was above the diaphragm when they were first examined.

As has been stated in speaking of the aetiology of the condition, the hiatus has invariably been found to be large and lax and to be, to some extent, developmentally deficient. The so-called oesophago-phrenic ligament appears to be a very definite structure; it is firmly attached to the gastro-oesophageal tube and has to be cut with scissors before the cardia can be brought down below the diaphragm. The small arteries to the oesophagus from the aorta appear to me to run transversely from aorta to oesophagus, not more and more obliquely upwards as the cardia rises, as one would expect.

Treatment. We are firmly of the opinion that sliding hernia in children is a surgical condition. It has been suggested that many cases will ultimately do well with medical treatment and that symptoms tend to subside at the time of weaning or later in childhood. The result of medical treatment, as exemplified by nine Liverpool cases, does not suggest that this is so (Table 3).

A child who continues to vomit and fails to gain weight is more likely to fall a victim to infection than is his healthy brother. There can surely be

TABLE 3
RESULTS IN NINE CASES OF SLIDING HIATUS HERNIA

Medical Treatment	total number of cases
(a) Satisfactory; gaining weight, no vomiting	1
(b) Unsatisfactory; below weight for age, vomiting, etc.	5
Included are a boy of 13 years weighing 65 lb. who cannot eat solids, cardia at level of 5 T, stricture, and a boy of 7 years weighing 47 lb., repeated dilatation for stricture. The ages of the other children are 13 yr., 9 yr., 2 yr., 7 months and 6 months.	
(c) Still under observation at 10 weeks old	1
(d) Deaths	2
One child died aged 1 month, pneumonia.	
" " " " 3 months, aspiration of vomit and haematemesis.	
Examples of cases in which medical treatment failed and operation was requested:	
(1) Small hernia at 4 months, large hernia, stricture and perforation at 4 years.	
(2) Recurrent pneumonia, repeated haematemesis, failure to gain at 5 months.	
(3) Weighed 27 lb. at 3½ years; vomiting, haematemesis.	
(4) Increasing hernia; shortening of oesophagus at 3 years.	

little reason to allow a child to remain undernourished, and perhaps in pain, if his abnormality can be corrected. There is no guarantee that a child with a sliding hernia who does well on medical treatment will continue to do so, or that symptoms will not develop in later life when they may be more serious and less easily cured by operation.

There is no tendency for the cardia to become competent; it is permanently separated from the diaphragm and the hiatus is in any case inefficient. The valvular mechanism of the oesophago-gastric angle is obliterated and cannot develop as the gullet grows shorter. We therefore advise operation in all cases in which the cardia is above the diaphragm.

Time of Operation. Continued vomiting and failure to gain weight, severe, persistent or recurrent oesophagitis, progressive shortening of the oesophagus, peptic ulcer of the oesophagus and narrowing of the oesophagus are all absolute indications for operation.

In a child who is symptom free or in whom symptoms are mild, there is no urgency and operation can be undertaken at any convenient time, provided the position of the cardia is checked at frequent intervals.

If operation is advised for all cases it must cure symptoms and prevent complications, give a low recurrence rate and be safe (Table 4).

The important points in successful operation are adequate freeing of the oesophagus up to or above the aortic arch and complete separation of the oesophago-gastric tube from the diaphragm; firm fixation of the fundus of the stomach to the under-surface of the left dome of the diaphragm; careful repair of the hiatus.

We have found a thoracic approach to the oesophagus and a transdiaphragmatic approach to the stomach satisfactory, and since using this method, we have, so far, had no recurrence in 27 cases. Previously we operated on seven cases

TABLE 4
RESULTS IN OPERATIONS FOR CASES OF SLIDING HIATUS HERNIA

Surgical Treatment	total number of cases
(a) Operation above diaphragm	7
(i) Recurrence	4
(ii) Satisfactory	3
(b) Operation above diaphragm and through diaphragm	20 + 4 reoperated
(c) Operation above diaphragm and through diaphragm and dilatation of stricture through gastrostomy	3
(b) and (c)	27
Satisfactory; relief of symptoms and no recurrence of hernia to date	29
Total operations	33
Mortality	1

without opening the diaphragm and had four recurrences. These recurrent cases were later on successfully operated upon by the transpleural transdiaphragmatic approach. Severe strictures are dilated with Hagar's dilators through a small gastrostomy while the chest is open; the three cases so treated have not required post-operative dilatation. The children have stood operation well and post-operative complications have, on the whole, been few and transient. All cases are free of symptoms, except that two children have been slow to gain weight and appetite, in spite of normal or near normal appearances on radiography and oesophagoscopy. The longest follow-up in this small series, is, however, only three and a half years.

To conclude, we believe there is some evidence that lax oesophagus and sliding hiatal hernia are aetiologically distinct conditions. Further study of the former is required to settle the nature of the responsible factor. In sliding hiatal hernia we do not know whether the cardia is ever above the diaphragm at birth. It is natural to want to know the answers to these fascinating problems, but the burden of this discourse is the importance of the position of the incompetent cardia. I reiterate words written by Allison in 1948 about sliding hernia in children:

'The condition is of particular interest to paediatricians because its early recognition may lead to surgical reduction of the hernia, and for the patient, escape from a life of dysphagia and malnutrition.'

I wish to acknowledge the assistance of Mr. P. P. Rickham who performed about half the operations, most of the endoscopic examinations and a large proportion of the time-consuming radiological examinations.

REFERENCES

- Allison, P. R. (1946). *J. thorac. Surg.*, 15, 308.
 — (1948). *Thorax*, 3, 20.
 — (1951). *Surg. Gynec. Obstet.*, 92, 419.
 Barrett, G. M. (1950). *Brit. med. J.*, 1, 245.
 Belsey, R. (1954). *Ann. roy. Coll. Surg. Engl.*, 14, 303.
 Berenberg, W., and Neuhauser, E. B. D. (1950a). *Amer. J. Dis. Child.*, 79, 402.
 — (1950b). *Pediatrics*, 5, 414.
 Findlay, L. and Kelly, A. B. (1931). *J. Laryng.*, 46, 797.
 Harrington, S. W. (1942). *Ann. Surg.*, 115, 705.
 — (1945). *Ibid.*, 122, 546.
 Keidan, S. E. (1953). Lecture to the Liverpool Paediatric Club.
 Kelly, A. B. (1939). *J. Laryng.*, 54, 621.
 Lendrum, F. C. (1937). *Arch. intern. Med.*, 59, 474.
 Neuhauser, E. B. D. and Berenberg, W. (1947). *Radiology*, 48, 480.
 Wyllie, W. J. and Field, C. E. (1946). *Archives of Disease in Childhood*, 21, 218.