

# APPENDICITIS AND ENTEROBIASIS IN CHILDREN

## A HISTOLOGICAL STUDY OF 691 APPENDICES

BY

F. DURAN-JORDA\*

*From the Department of Pathology, Booth Hall Children's Hospital, Manchester*

(RECEIVED FOR PUBLICATION DECEMBER 17, 1956)

When the mucous membranes of the gastrointestinal organs are fixed by a formol-vapour method the surface of these structures appears to be covered by a 'cellular layer' (considered by orthodox histologists to be formed by a debris of cells, mucus and food remnants). This upper structure can be followed from the corneal layer of the stratified tissue of the oesophageal cardia to its ending in the similar layer of the anal skin. It does not stain by any of the mucin stains, it leaves ash after micro-incineration, it contains a large sequence of nuclei and in some places gives the impression that it contains capillaries (Duran-Jorda, 1946). It was to study its morphological changes in appendicitis that a systematic study was made of appendices removed in this hospital during a period of 21 months, in all a total of 691 appendicular organs.

During this histological study *Enterobius vermicularis* was so frequently found in the sections that it was decided to pay it special attention with the purpose of establishing the role, if any, of the parasite in the aetiology of appendicitis.

### Method

The appendix, after removal, was carefully opened and pinned on to the corked lid of a small jar containing undiluted formalin to a depth of 2 cm., and in order to avoid splashing the specimen during transportation to the laboratory, filter paper of the diameter of the jar was left floating in the formalin. After the specimen had been exposed to the fixative for three or four days the jar was opened and the appendix, still attached to the lid, was left for two to three hours in contact with the atmosphere for the surface to dry. It was then cut lengthways, trimmed and immersed in formol-saline. The usual technique of paraffin embedding was then followed, sectioning at  $5\mu$  and staining with haematoxylin and eosin.

### Microscopic Findings

When the appendicular lumen containing a large number of parasites is studied under the dissecting microscope (Fig. 1) it can be seen that most of the *Enterobius vermicularis* appear covered with some material, but others, especially the young forms, can be seen buried in the organ itself. Microscopically, the appendices fixed by formol-vapour show a layer of cells of varying thickness, forming the uppermost layer of the mucous membrane, monocellular in normal areas and multicellular in acute appendicitis. It is within this layer that *Enterobius vermicularis* is generally found, either singly or with other worms forming groups of three or four side by side (Fig. 2), or resting not only on the mucous membrane (Fig. 3) but also on some displaced glands.

For the most part *Enterobius vermicularis* found buried is in an early stage of development; it is more difficult to find in the sections an adult worm completely covered by the upper layer because the continuity of the semisquamous epithelial layer is generally broken during the worm's pre-mortem contractions.

*Enterobius vermicularis* is able to establish itself in the whole of the appendicular organ; it can occupy the space of the mucous membrane (Fig. 4); burrow underneath it (Fig. 5); parasitize the middle of a lymphoid follicle (Fig. 6); or it can invade the peritoneal appendicular layer forming a cyst (Fig. 7). In one of our cases the *Enterobius* was accompanied by the remnant of the carapace of a crustacean (*Cyclops*, fam. *Copepoda*) often found in the drinking water of this city (Fig. 8). We were quite sure that this finding was a genuine one because the crustacean remnants were surrounded by diapedesic cells from the organ.

The different tissues of the appendix showed no undue cellular reaction towards the *Enterobius*, as if

\* Dr. Duran-Jorda died on March 30, 1957.

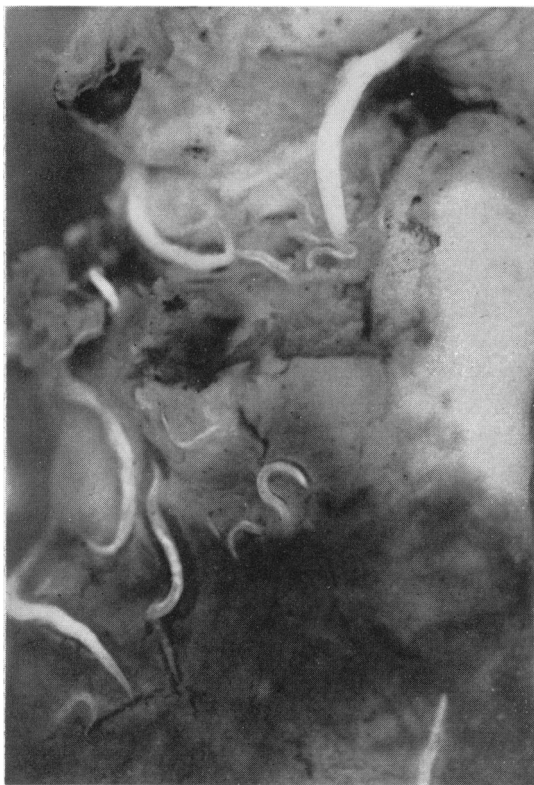

FIG. 1.

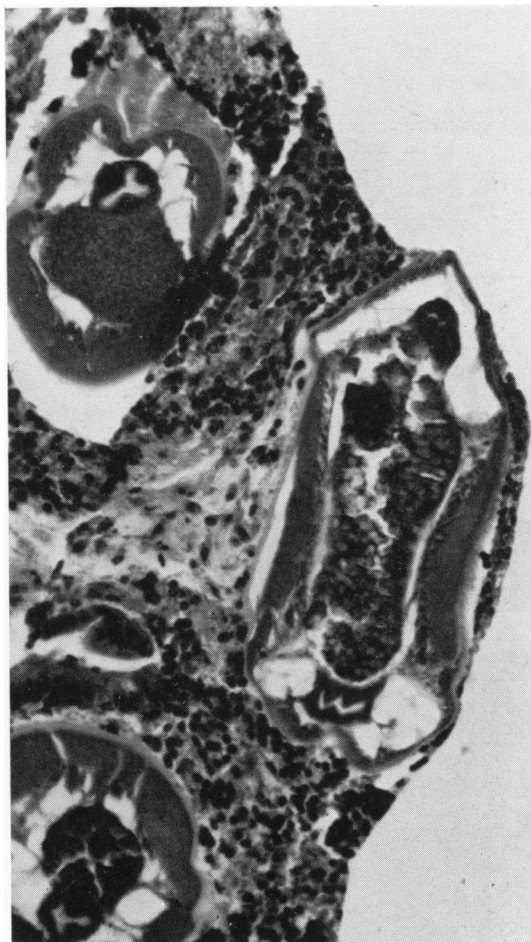

FIG. 3.

FIG. 1.—Fresh appendix showing lumen with extensive parasitosis.  $\times 17$ .

FIG. 2.—Appendix fixed by formol-vapour showing three *Enterobius*. Haematoxylin and eosin.  $\times 150$ .

FIG. 3.—Appendix fixed by formol-vapour showing larger magnification of a field with two layers of *Enterobius*, some in contact with displaced glands. Notice the cellular structure of the covering layer. Haematoxylin and eosin.  $\times 200$ .

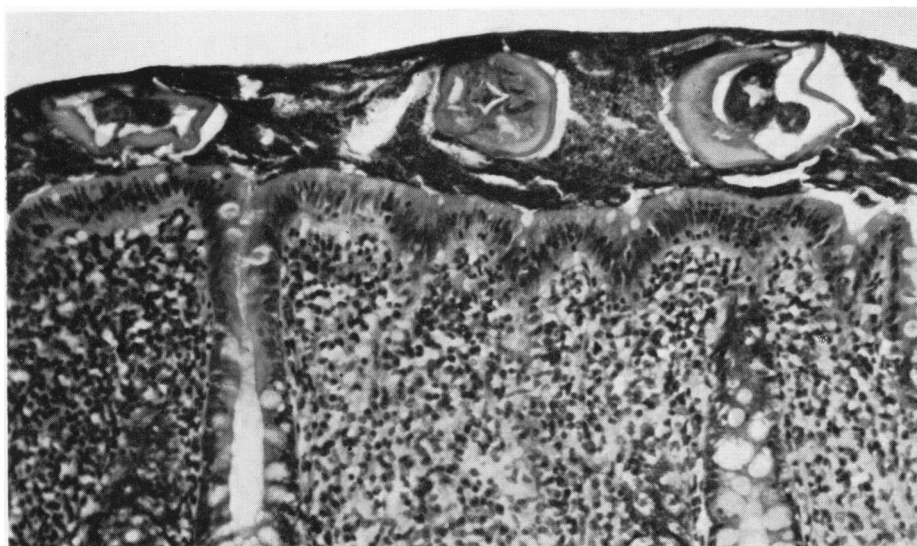


FIG. 2.

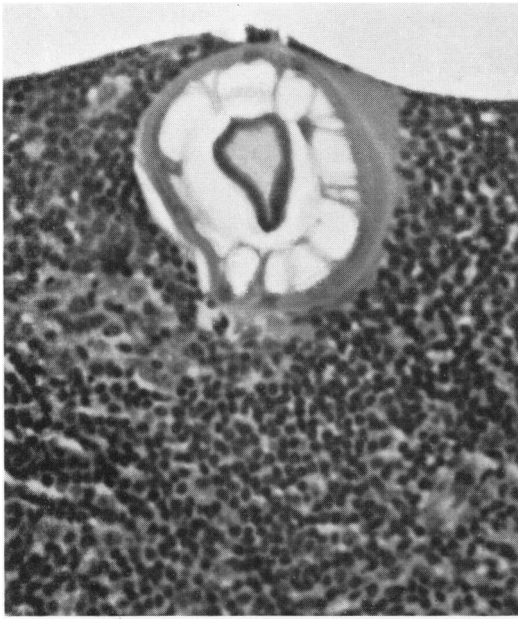


FIG. 4.




FIG. 5.

FIG. 4.—Appendix fixed by formol-vapour. *Enterobius vermicularis* buried in the area topographically belonging to the mucous membrane.

FIG. 5.—Appendix fixed by formol-vapour. *Enterobius vermicularis* buried under the mucous membrane. Notice the keratinous edges and channel built by the appendicular cells. Haematoxylin and eosin.  $\times 200$ .

FIG. 6.—Appendix fixed by formol-vapour. *Enterobius* buried in the middle of a lymphatic nodule. Notice the continuity of the semi-squamous epithelial layer. Haematoxylin and eosin.  $\times 80$ .

FIG. 7.—Appendix fixed by formol vapour. Cyst in the peritoneal appendicular layer with an *Enterobius vermicularis*. Haematoxylin and eosin.  $\times 116$ .

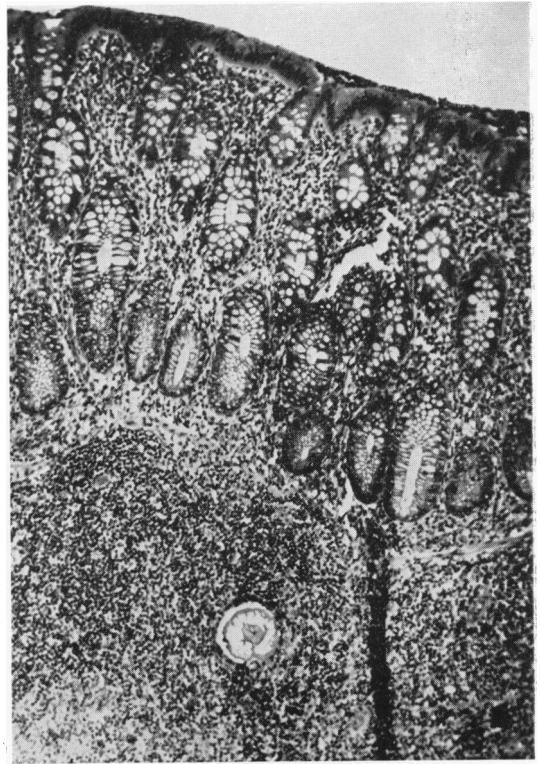


FIG. 6.

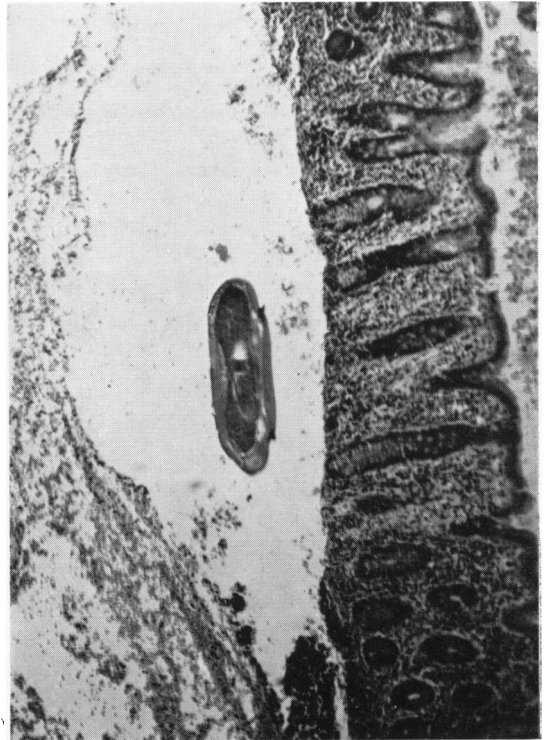


FIG. 7.

the organ and the parasite had been able to establish a perfect symbiotic relationship.

A careful study of *Enterobius vermicularis* shows in its head a double fin-like formation called alae (Fig. 9) from which two very well developed keratinous structures run parallel to the sides of its body. These keratinous structures are serrated (Fig. 10) and when the worm is cut transversally show two very sharp edges similar to a double-edged dagger. The strength of these keratinous structures is demonstrated by the canal built around them by the appendicular cells that house them (Fig. 5). When a fully developed *Enterobius vermicularis* filled with ova is seen buried in the superficial layer it produces an imprint of its irregularities on the top surface of the mucous membrane which shows a perfect replica of the shape of the edge of the worm (Fig. 11). The *Enterobius* also appears to moult (Fig. 12), leaving behind an extra keratinous cover before beginning its long journey to the anus.

Thus it appears that the appendix suffers mechanical damage on two occasions: when the larva leaves the ovum and burrows into the appendicular semi-squamous epithelial layer in search of a place to develop to adult stage in comfort, and again when the individual parasite has reached full maturation, freeing itself and emigrating, full of ova, to the anus. It seems that during these two migratory stages the organ is in great danger of infection from the intestinal flora in its lumen.

#### Frequency of Infestation in Children

The assessment of parasitosis in the appendices was studied on a histological basis and, therefore, our figures are smaller than those of other authors who have studied the presence of ova or parasites in the appendicular lumen by scraping its surface (Schenken and Moss, 1942).

Of the 691 appendices (400 in boys, 291 in girls), 52 showed positive findings (7.5%); in the 400 appendices of the boys, 19 (4.7%) were positive and in the 291 appendices of the girls 33 (11.3%) were positive. These figures demonstrate that appendicitis occurred more frequently in boys than in girls (1.3 to 1), but that enterobiasis was found to have a more than double frequency in girls than in boys (11.0% to 4.7% respectively).

It was after these results that we decided to carry out a survey of the frequency of infestation in

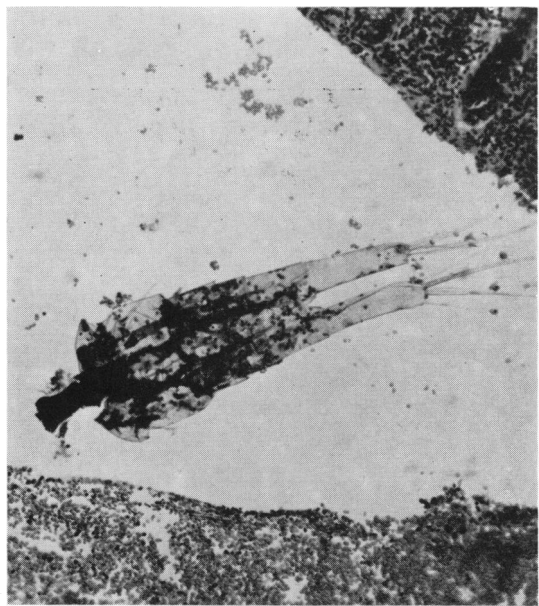


FIG. 8.

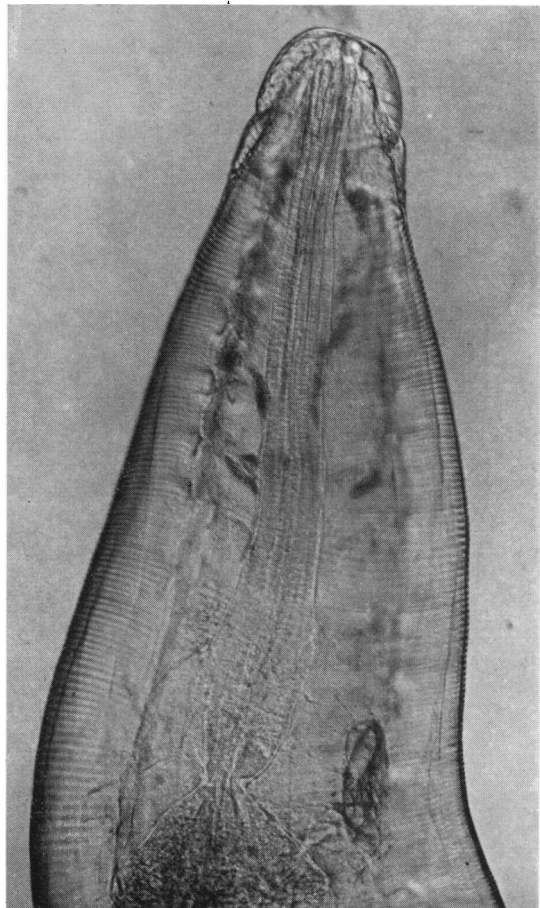


FIG. 9.

FIG. 8.—Appendix fixed by formol-vapour. Serial section of the appendix from Fig. 7 showing remnants of the skeleton (carapace) of a crustacean (*Cyclops*, fam. *Copepoda*) often found in drinking water. Haematoxylin and eosin.  $\times 150$ .

FIG. 9.—A female *Enterobius vermicularis* in fresh preparation showing its alae and keratinous body sides.  $\times 100$ .

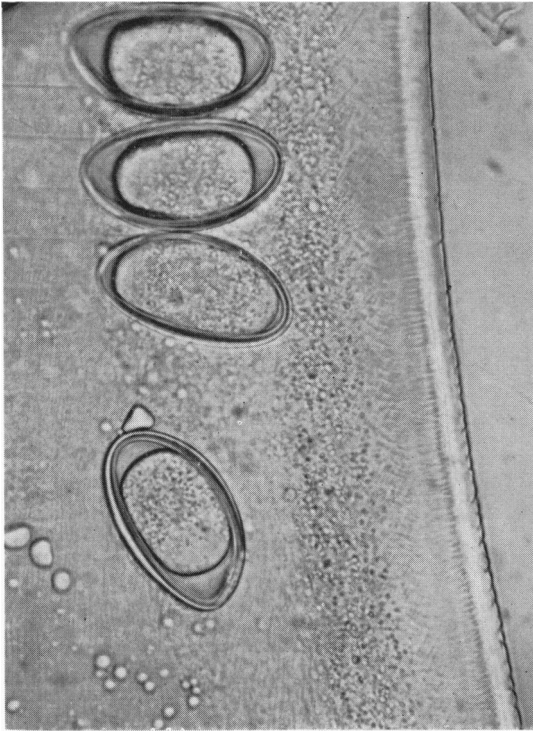


FIG. 10.—A female *Enterobius vermicularis* in fresh preparation showing the serrated aspect of the edge of its body.  $\times 230$ .

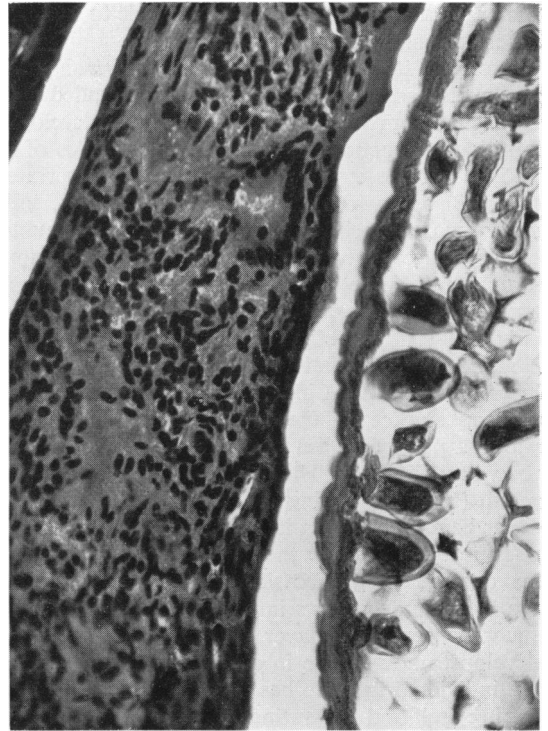


FIG. 11.—Appendix fixed by formol-vapour. Detail of the lower part of an *Enterobius vermicularis* showing the imprint of its edge in the large cellular structure surrounding it. Haematoxylin and eosin.  $\times 200$ .

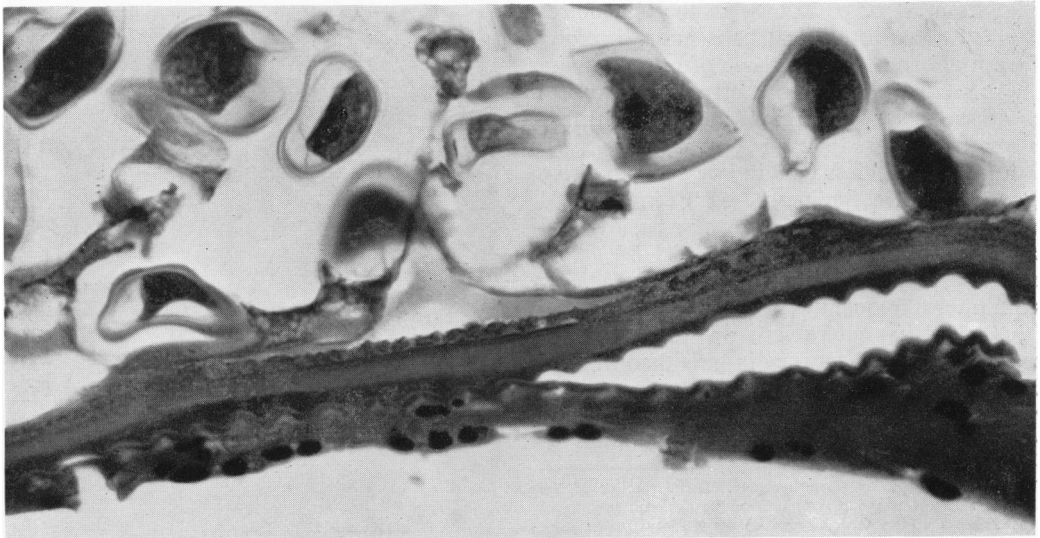


FIG. 12.—Appendix fixed by formol-vapour. Detail of the upper part of the *Enterobius vermicularis* of Fig. 11 showing the moulting of an extra keratinous cover. Notice the cellular aspect of the semi-squamous epithelial layer. Haematoxylin and eosin.  $\times 300$ .

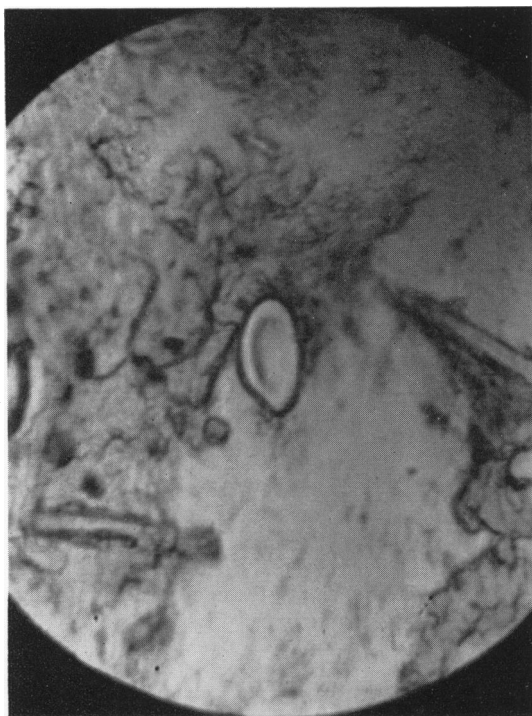


FIG. 13.—Scotch tape illuminated by a mercury vapour source of light showing the primary fluorescence of an ovum of *Enterobius vermicularis*. Wood's filter.  $\times 200$ .

children. Two hundred patients already in the wards were examined by the Scotch tape method (Hall, 1937) and later a further 100 cases were examined. Each slide was investigated using a projecting microscope against a screen of 8 in. diameter which gave us the opportunity of studying the whole of the tape adhered to the glass slide without undue fatigue. With a mercury vapour lamp as the source of illumination we found that the ova of *Enterobius vermicularis* showed a primary fluorescence which was confirmed by filtering the light with a Wood's filter, a phenomenon which eased the detection of the ova (Fig. 13). Studying the source of fluorescence in the ova by spectroscopy, it appears that it contains a chromatogen with a maximum of light absorption in the region of the violet band.

The results of the 300 examinations were as follows: boys 164, parasitized 40 (24%); girls 136, parasitized 41 (30%) (Fig. 14). In order to obtain a better understanding of the frequency of infestation in children, we divided them into three age groups: from 0 to 5 years, from 5 to 11 years and from 11 to 16 years, and these results are also shown in Fig. 14. It can be seen that during the critical school years from 5 to 11 the girls showed an increased

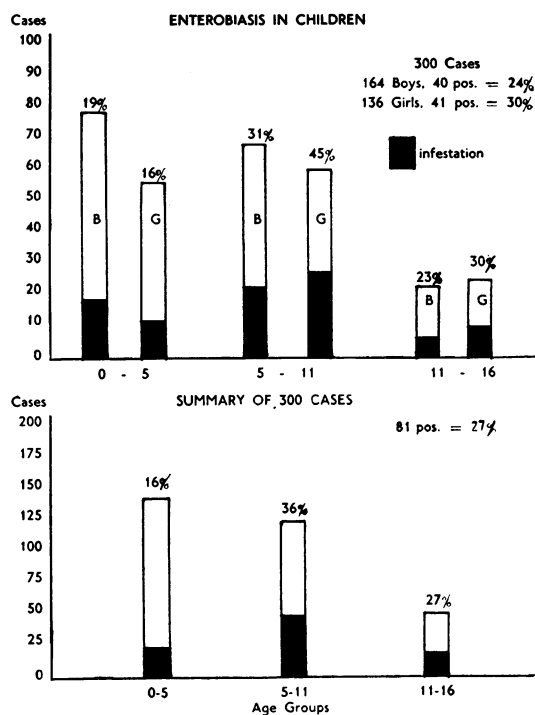


FIG. 14.

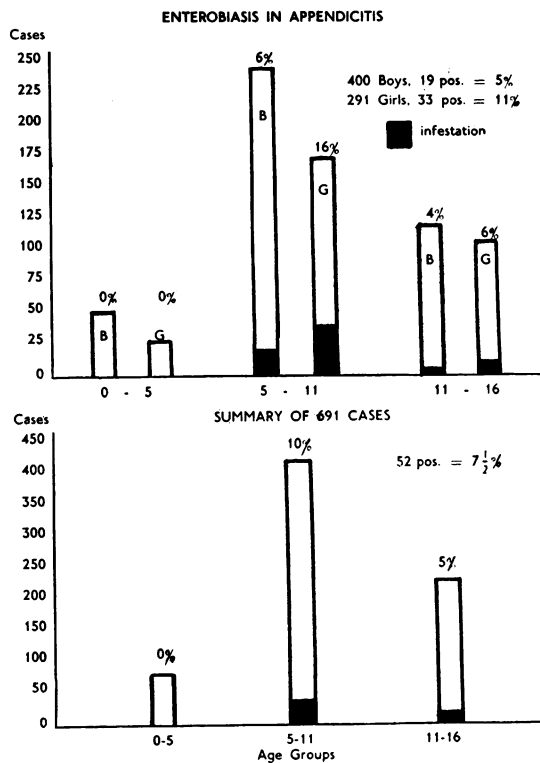


FIG. 15.

percentage of 45% as against 31% in the boys, thereby pointing to the danger held by the lavatory seat for the girls in the primary school. The total incidence of *Enterobiasis* in the 300 cases was 27%.

If the appendicectomized children are now divided into school age groups a more realistic view can be obtained (Fig. 15). No parasitosis of the appendix was found in boys and girls under 5, but in the 5-11-years group we found 237 boys with 14 positives (5.9%) and 170 girls with 27 positives (15.9%). These results correspond with the higher rate of infestation in girls, although the incidence of appendicitis is greater in boys.

### Pathology

The full length of the appendices was examined microscopically, the pathology being studied according to any abnormal change, irrespective of extension of area. Our classifications were as follows:

**Normal Appendix.** The semisquamous epithelial layer would be seen formed only by 'one cell' thickness. Normal glandular morphology and no hyperaemia or cellular infiltration in any layer of the organ.

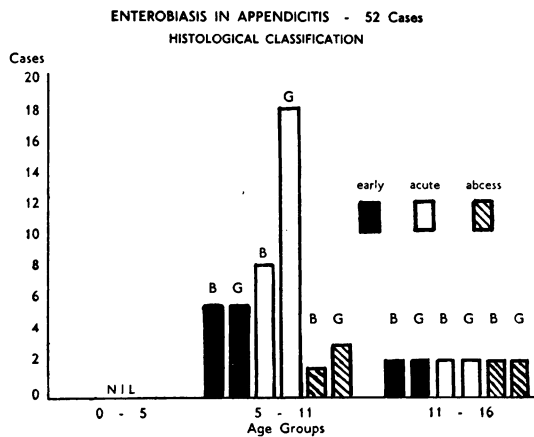
**Early Appendicitis.** In this condition there was seen a multicellular thickness epithelial layer with diapedesic cells and red blood corpuscles. The mucous membrane and other layers would sometimes show patches of interglandular hyperaemia or small haemorrhagic areas also.

**Acute Appendicitis.** A large cellular infiltration of the semisquamous epithelial layer was seen with granulocytes and red blood corpuscles, some areas of clotted plasma, congested or haemorrhagic mucous membrane infiltrated by granulocytes, with the other layers of the organ showing the same infiltration.

**Appendicular Abscess.** No semisquamous epithelial layer was present but the mucous membrane was destroyed with substitution by a large accumulation of granulocytes occupying part of the appendicular lumen, all other layers of the organ being very congested and infiltrated by granulocytes.

**Chronic Appendicitis.** The covering layer was monocellular or non-existent with patches of clotted plasma forming small ulcers in the areas where the mucous membrane had disappeared; atrophied mucous membrane formed by one layer of glandular cells; large areas of lymphocytes.

Using the above classifications no normal



appendices were found in the 52 cases with enterobiasis; 14 were classified as early appendicitis; 30 as acute appendicitis and eight as showing appendicular abscesses. The division of these results into age groups and sexes is shown in Fig. 16.

### Discussion

The problem of enterobiasis and its relationship to appendicitis is a very old one (Garrod and Fairbank, 1907). Some authors, finding the *Enterobius* burrowed in the structures of the appendix, believed that the parasite moved into them as a result of a post-operative phenomenon (Gordon, 1933), but no consideration was given to the need of having an 'untouched' appendix fixed with a technique that shows the whole structure of the organ, together with the material deposited or already existent in its lumen. Only then could it be realized that the invasion of the organ was a genuine one and not the result of faulty histological technique.

We believe that *Enterobius vermicularis* seeks cover and protection against the digestive juices and peristalsis in the appendicular structures and uses its alae to plough a burrow. Our view is supported by the fact that other *Enterobius* infesting some mammals, especially the one found in the hare (*Oxyuris ambigua*), take shelter in the intestinal wall (Penso, 1932). Other helminths which parasitize the gastro-intestinal mucosae of herbivora (cow, sheep, horse) also penetrate them. Therefore, the mechanism of human parasitosis described explains the danger to which the appendix is subjected during the double migratory life of *Enterobius vermicularis* which breaks the defences of the mucous membranes and twice opens them to infection, and it is possible that these migratory phases are manifested by

abdominal pains or by a complete appendicular syndrome.

Apart from this the histological picture of *Enterobius vermicularis* buried in the organ appears to be free of any cellular inflammatory changes as if, during its development *in situ*, it has established a perfect symbiosis.

The penetration into the intestinal wall may also explain the difficulty experienced in actually reaching the parasite with the use of anthelmintics which act locally in immediate contact with the *Enterobius* (Dowsett and Brown, 1953).

Our histological and morphological findings warrant greater consideration of the role played by *Enterobius vermicularis* in appendicitis than hitherto. In this study no normal appendix was found to be parasitized by *Enterobius vermicularis*. However, the study on the incidence of enterobiasis on the one hand and the frequency of appendicitis with its paradoxical results on the other, leaves the problem of the relationship between *Enterobius* and appendicitis still unsolved.

#### Summary

The preparation with formol-vapour fixation of 691 appendices demonstrated the relationship of *Enterobius vermicularis* with the different appendicular structures. A double migratory phase in the life cycle of *Enterobius vermicularis* is postulated—from the lumen into the organ in the larval stage,

and from the organ into the lumen when the nematode has reached full maturation after passing through the stage of moulting.

The incidence of enterobiasis in 300 in-patient children has been analysed, dividing the results into three age groups. Parasitosis was present most often in girls of primary school age. These figures were compared with the incidence of enterobiasis in appendicitis in similar age groups. As the ova of *Enterobius vermicularis* show a primary fluorescence the use of a mercury vapour lamp as a source of light can be used with advantage for their detection.

This study would not have been possible without the enthusiasm of the surgical staff of this hospital, especially Mr. A. Forman, Mr. K. H. Smith, Mr. E. J. Peterson and Mr. V. Kritzing; the collaboration of physicians for permitting the use of their patients; and the nursing staff for the collection of swabs, and especially Sister M. Foster in theatre for preparing the appendices after removal.

Thanks are also due to Mr. J. D. Joseph, A.R.I.C., F.C.S., Chief Chemist, Manchester Waterworks, for the identification of the crustacean; to my staff for the numerous sections and photographs, and to the Hospital Board of Management for a grant from the Endowment Fund towards expenses.

#### REFERENCES

- Dowsett, L. M. and Brown, A. E. (1953). *Lancet*, 1, 1070.  
 Duran-Jorda, F. (1946). *Brit. J. Surg.*, 33, 346.  
 Garrod, A. E. and Fairbank, H. A. T. (1907). *Lancet*, 2, 772.  
 Gordon, H. (1933). *Arch. Path. (Chicago)*, 16, 177.  
 Hall, M. C. (1937). *Amer. J. trop. Med.*, 17, 445.  
 Penso, G. (1932). *Ann. Parasit. num. comp.*, 10, 271.  
 Schenken, J. R. and Moss, E. S. (1942). *Amer. J. clin. Path.*, 12, 509.