

MONGOLISM IN BOTH OF TWINS OF OPPOSITE SEX

BY

DOUGLAS N. NICHOLSON and ALEX. J. KEAY

From the Royal Hospital for Sick Children, Edinburgh, and the Department of Child Life and Health, University of Edinburgh

(RECEIVED FOR PUBLICATION MARCH 14, 1957)

Mongolism in both members of a twin pair is a rarity. In all recorded cases where the twins have been considered to be monozygous both have been affected. Among dizygous pairs the great majority are discordant for mongolism but mongolism in both of twins of the same sex although considered to be dizygous has been recorded (Russell, 1933; MacKaye, 1936; Jarvis, 1943). There is no satisfactory report of monozygous twins in which only one of the pair was a mongol, neither is there a record of a pair of twins of opposite sex both of whom were mongols. The purpose of this paper is to put on record what would appear to be the first report of mongolism in both of twins of opposite sex.

Case Reports

Parents' Histories. The parents of the twins are not related. Their mother was 41 years and their father 40 years of age at the time of their birth.

The mother was one of a family of eight children, five brothers and one sister living. Her Wassermann reaction is negative. She married at the age of 25 years. The father has eight brothers and one sister, all of whom are well. He served in the army during the Second World War, but was discharged 'because of nerves'. Both parents are good looking and of normal intelligence. No history of mongolism or mental defect was discovered on enquiry into either side of the family. There is a history of twinning on the mother's side, but none in her husband's family.

Previous and Present Obstetric History. The mother had had six previous successful pregnancies, in 1939, 1940, 1941, 1945, 1947 and 1949. All these children are well with no evident congenital physical or mental abnormality. They all have a satisfactory school record.

In 1951, after an abortion at 11 weeks, a dilatation and curettage was carried out. Because of severe headache, at this time, she was examined by a hospital physician but no abnormality was found and her symptoms were attributed to an anxiety state. A further curettage was performed in October, 1952, because of chronic cervicitis. After this operation the menses were regular every three weeks, until August, 1953, when her eighth pregnancy began. At the 27th week she was admitted to hospital

because of epigastric pain which settled spontaneously. The presence of a twin pregnancy was confirmed by radiology. There was no further complication of pregnancy, the blood pressure did not rise above 150/80 mm. Hg, there was no albuminuria and only slight swelling of the ankles. There was no antepartum haemorrhage.

Labour occurred spontaneously at the 36th week. The first child, a male, was delivered by the vertex. His condition was satisfactory. The second child, a female, was delivered by forceps five hours later. This baby was limp but recovered quickly. The first placenta came away readily, but the second was adherent and had to be removed manually. Both placentas and membranes were normal. Both infants were recognized as mongols at birth.

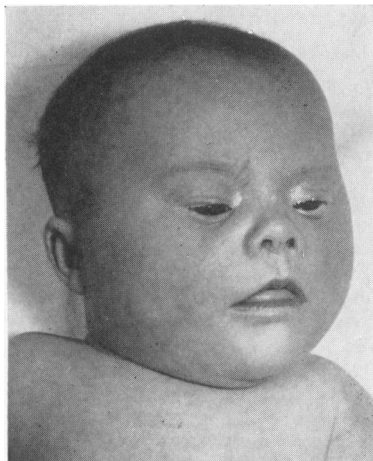


FIG. 1.—Female twin at 7 weeks.

Female Twin M.M., the girl, weighed 2.27 kg. (5 lb.) at birth. She showed the following physical stigmata suggestive of mongolism. The skull was brachycephalic, the back of the head flat, the bridge of the nose flat with forward-pointing nostrils. The palpebral fissures were slanting with small bilateral epicanthic folds. The hair was soft and brown. The irides were greyish-blue with radial white streaks. The mouth was kept open and the tongue frequently protruded. Her hands were short and

broad and both fifth fingers short and incurved. The palmar creases on the left hand were normal, but a typical four-finger line was present on the right palm.

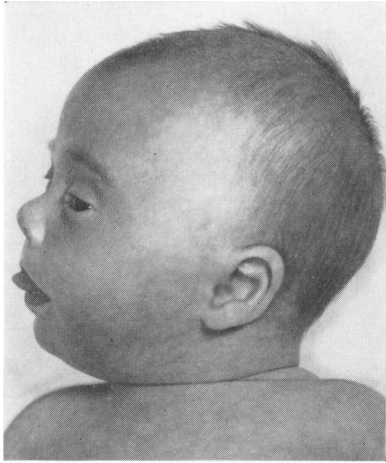

FIG. 2.—Male twin at 7 weeks.

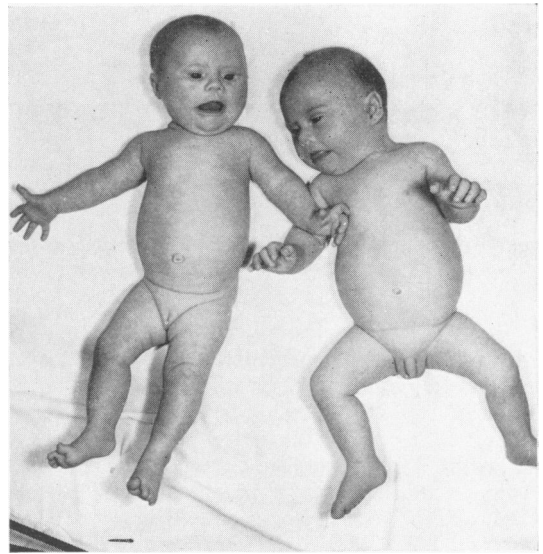


FIG. 3.—Mongol twins at 7 weeks of age.

The feet were small and clumsy, showing bilaterally a wide gap between the first and second toes, with a well defined crease. There was marked hypotonia and hyperflexibility of the joints. A nasal discharge and a mild conjunctivitis developed within a few weeks of birth. When seen at 7 weeks of age she appeared even more clearly a mongol. A radiograph of the chest and an electrocardiogram showed no abnormality. She had not smiled but is said to have done so at the age of 3 months when she had gained some control of head movement. When 5 months old she developed a cough which became progressively worse and at 6½ months she was admitted to this hospital in a critically ill state and died shortly after admission.

Male Twin. J.M. weighed 2·78 kg. (6 lb. 2 oz.) at birth and showed many of the physical features associated with mongolism similar to those of his sister. He, however, had also a precordial systolic murmur, and radiological and electrocardiographic examinations at 7 weeks showed enlargement and hypertrophy of the right side of the heart. When examined at the age of 20 months he had the typical appearance and behaviour of a mongol. His weight was 10·30 kg. (22 lb. 14 oz.). The circumference of the skull was 46·35 cm. (18½ in.) and the cephalic index 0·98. His head showed brachycephaly with a flat occiput and absence of bony prominences. His nose was flat with nostrils facing forwards. The palpebral fissures were oblique and narrow. Slight bilateral epicanthus, slight rhinitis and blepharitis were present. The irides were greyish-blue and speckled. The mouth was kept open with protruded and slightly furrowed tongue. His right ear was prominent with a poorly formed lobule. His hair was smooth and soft and reddish. The neck was short and

broad. The hands were short and broad with incurved fifth fingers. There was only one flexion crease on the right fifth finger, associated with a vestigial phalanx visible radiologically. The main transverse creases on both palms were not true four-finger lines, as they showed a slight break in the mid-portion. The feet were small and clumsy, the first and second toes being widely separated on both sides with a plantar crease. There was marked hypotonicity as well as hyperflexibility of the joints. The testicles were palpable in the scrotum. He could sit up unaided at about 1 year and began to stand with support about that time. He walked at 16 months but when seen at the age of 2 years and 3 months he could just get up off the floor into the standing position without aid. He cannot run more than a few steps without falling. He cannot crawl upstairs. He cannot feed himself. He will not play with toys, will not concentrate, has no interest in pictures and is rather destructive. He follows his mother about the house all day like a dog. Although he said 'Da-Da-Da' at 1 year, there is no increase in speech since. He cut his first teeth, which were molars, at 14 months and further dentition is delayed showing irregular sequence of eruption. Assessment of his mental state was made by the child psychologist of this hospital on two occasions using the Cattell Infant Intelligence Scale. At 1 year 7 months his mental age was about that of an 8-month child and at 2 years 2 months his mental age was about that of 9 months, which gives an I.Q. of 34. The psychologist reports: 'I am not in any doubt but that he is a mental defective, and although his I.Q. may be a little higher than 34, I would expect that he would fall into the high-grade imbecile range.' When assessed on the Vineland Social Maturity Scale, which is designed to be an assessment of the degree to which a child has

TABLE 1.
BLOOD GROUPS OF PARENTS AND OF MONGOL TWINS

	A B O	Rh Genotype	MN	S	P	Lu	Kell	Lea	Leb	Fya
Father	O	cde/cde	M	+	+	—	—	+	—	—
Mother	B	CDe/CDe	N	—	+	—	—	+	—	+
Male twin ..	B	CDe/cde	MN	—	+	—	—	+	—	+
Female twin ..	B	CDe/cde	MN	—	+	—	—	+	—	—

been socially trainable and has achieved independence, he is about the level of 1 year 5 months at the age of 2 years 2 months.

The blood groups of both mongols and their parents are shown in Table 1.

Discussion

Since 1866 when Langdon Down first recognized mongolian idiocy as a specific condition, there has been much discussion as to the probable aetiology of this abnormality. The relative importance of genetic factors within the ovum (either inherited or the result of mutation) as compared with environmental factors affecting the fertilized ovum have been debated strongly with much evidence brought forward in support of both sides. Only one fact, however, has been clearly established, namely, that the incidence of mongolism increases with increasing maternal age (Penrose, 1954a and b).

Many investigators have naturally turned to twin studies which might be expected to give useful evidence in determining the relative importance of heredity and environment by comparison of incidence in monozygous and dizygous pairs. The use of this method, however, has been hampered by the inadequate detail of many reports in which the diagnosis of either mongolism or zygosity, or both, is not supported by sufficient evidence. It has become increasingly evident how difficult it is to establish a positive diagnosis of monozygosity in twin pairs and several criteria have to be examined in each case. Assessment of single features such as placental membranes, finger prints, etc., may be misleading.

The diagnosis of dizygosity in the present pair is made clear by the difference in sex. With young infants, however, it is less easy to establish a positive

diagnosis of mongolism and this applies particularly to the proof of mental defect which is generally held to be an essential element. In the present case histories, therefore, stress has been laid on the physical features of mongolism.

In the case of the female twin, who died at the age of 6½ months, the diagnosis rests on the clinical impression of all who saw her and which we hope is conveyed in the photographs reproduced here. She was seen during life by several physicians, all of whom accepted the diagnosis. Slides of a series of photographs have been presented before a meeting of the Scottish Paediatric Society. The meeting agreed that she had the characteristic features of mongolism.

The surviving male twin was shown to the Society and again the diagnosis was unanimously accepted. He has now lived long enough for a firm diagnosis of mental defect to be established. We therefore feel justified in our assertion that these twins were of opposite sex, were therefore dizygous, and were both mongols.

Summary

The presence of mongolism in both of twins of opposite sex is recorded. There is no previous record in the literature of this occurrence.

Our thanks are due to Miss Jessie F. Reid, formerly psychologist, Department of Psychological Medicine, Royal Hospital for Sick Children, Edinburgh, for her reports.

REFERENCES

- Down, J. Langdon H. (1866). *London Hosp. Rep.*, 3, 259.
 Jarvis, G. A. (1943). *Amer. J. ment. Defic.*, 47, 364.
 MacKaye, L. (1936). *Amer. J. Dis. Child.*, 52, 141.
 Penrose, L. S. (1954a). *Lancet*, 2, 505.
 — (1954b). *Ann. N.Y. Acad. Sci.*, 57, 494.
 Russell, P. M. G. (1933). *Lancet*, 1, 802.