

HEPATIC HAEMORRHAGE IN THE NEWBORN*

BY

J. J. MASON BROWN

From the Royal Edinburgh Hospital for Sick Children

Incidence of Hepatic Haemorrhage

It has long been known that injury to the abdominal viscera may cause stillbirth or death in the first days of life. Information about bleeding from the abdominal viscera has been obtained largely from post-mortem examinations of stillborn babies and babies dying shortly after birth. The incidence of bleeding from the liver estimated in this way is shown in Table 1. Hepatic haemorrhage is, therefore, the direct cause of or a significant factor in

TABLE 1
HEPATIC HAEMORRHAGE IN STILLBIRTH
AND NEONATAL DEATH

Author	Incidence at Necropsy
Palmer (1928)	5 in 99
Cruickshank (1930)	18 in 800
Holmberg (1933)	56 in 1,000
Rogers (1934)	53 in 1,046
Potter (1940)	24 in 2,000
Henderson (1941)	47 in 1,312

determining from 1·2 to 5·6% of stillbirths and neonatal deaths. While this paper is concerned with hepatic bleeding, haemorrhage in other abdominal viscera is also important as a cause of stillbirth and neonatal death and the frequency with which the various viscera are affected is shown in Table 2.

TABLE 2
SITES OF ABDOMINAL HAEMORRHAGE IN
STILLBIRTH AND NEONATAL DEATH

Viscus	Lundquist (1930)	Henderson (1941)
Liver	19	47
Suprarenal	17	30
Renal	—	25
Gastro-intestinal	—	32
Unknown	12	—
Spleen	1	—
Other viscera	—	10

The liver is the site of 39% and 32% of the intra-abdominal haemorrhages in these two series of cases.

* A paper read at a meeting of the British Association of Paediatric Surgeons held in Edinburgh in June, 1957.

Aetiology and Pathology

Lundquist (1930) recorded 19 cases of hepatic haemorrhage; 14 were subcapsular haematomas and five showed rupture of the liver parenchyma. He believed, therefore, that trauma was not important and suggested that subcapsular haematoma was the result of asphyxia. In Henderson's (1941) 47 cases, there was rupture of the liver and intraperitoneal haemorrhage in 24. Nearly half of the cases were complicated by intracranial haemorrhage. Henderson emphasized that rupture of the liver occurred in 18 out of the 32 stillborn cases (56%) and in six of the 15 (40%) babies born alive so that trauma played a greater part in the stillborn. He suggested that bleeding arises from contusion or laceration of the liver parenchyma; the capsule is then elevated by the haematoma which may become very large. Rupture of the capsule may follow because of tension or from handling the baby. Henderson found that the incidence of hepatic haemorrhage was much greater in premature and abnormally large babies than in those in the range from 5½ to 8 lb. in weight.

Surgical interest is centred in the babies who are born alive and more particularly in those who survive long enough for the diagnosis to be made. Henderson found records of 55 such cases in the literature and only one survived longer than a week. The only recovery followed operation on a Chicago baby recorded by Rogers (1934).

Potter (1940) recorded 24 cases in babies born alive and drew attention to the undoubted fact that many appear to be normal for the first few days but die suddenly in severe shock. Arden (1951), like Henderson, was impressed by the frequency with which post-mature babies are affected.

Arden, Dique and Wrench (1955) found that the babies fare normally for 48 hours and suggest that during that time they have a subcapsular haematoma which expands and ruptures. They believe that the condition is traumatic in origin but the massive bleeding is out of all proportion to the trivial liver damage and factors such as anoxia or prothrombin deficiency are the cause of the continuing bleeding.

Prognosis

Only one of the cases in the various series quoted previously survived. Stein and Wright (1953) reported 15 cases of liver rupture in babies born alive and none survived. Henderson's series of cases from maternity hospitals in Edinburgh showed no survivors in the seven-year period ending in 1940, and I am not aware of any since that date. Arden (1946) reported the successful treatment of a 2-day-old baby by suture of the liver capsule to the parietal peritoneum and later (1951) recorded six cases encountered in seven years, in four of which the diagnosis was made on clinical grounds. Shock developed with great suddenness from 36 to 104 hours after birth. Two of the babies died within 10 minutes, two recovered following transfusion and two following transfusion and laparotomy. Five of the six babies were post-mature. Greaves (1955) reported the case of a 2-day-old baby who became pale and collapsed. Straight radiographs in the erect and lying down positions showed no abnormality although the author felt that in retrospect when the diagnosis was known the shadows were denser than normal. He was able to find only six instances of survival in the literature and his patient also recovered following laparotomy and suture of a 1 in. tear in the substance of the liver. He advocates location of the bleeding site and its control by surgery.

Bret, Jamain and Coupé (1956) record three cases of haemoperitoneum following rupture of subcapsular haematoma of the liver with one recovery.

It seems that the prognosis is better following operation, but Arden advises conservative treatment despite his surgical success because (a) blood in the peritoneal cavity appears to do no harm to the baby; (b) the wound in the liver parenchyma may be difficult to find even if the site of the bleeding is readily accessible; (c) the capsule of the liver is unable to hold sutures at this age; and (d) the site of the bleeding may not be accessible. With adequate transfusion, but not overloading, the bleeding should stop but to be successful both surgical and medical treatment are dependent on the diagnosis being made in time.

Clinical Features

The clinical features described by Arden are well shown in the following case.

Female baby (J.M.), expected date of delivery October 19, 1954. At one week intervals thereafter induction was attempted but delivery, which was spontaneous, did not occur until November 13, 1954. There was great difficulty with the shoulders, and the baby, which was said to weigh 11 lb. 4 oz. (5.1 kg.), was somewhat shocked and required resuscitation. The baby became progressively lethargic but of good colour. On the fourth day she

became very pale and quiet and would not suck. She was referred to hospital.

Examination showed a post-mature infant of 9 lb. 14½ oz. (4.5 kg.) with marked pallor and slight jaundice. Bruising of the left arm, dilated upper abdominal veins and a large ill-defined swelling in the epigastrium were noted. The abdominal mass was dull on percussion, the dullness being continuous with that of the liver. The spleen was not palpable. The abdomen also showed some general distension with dullness in the flanks. The baby vomited on the journey to hospital and this symptom persisted following admission. Blood examination, apart from 50% haemoglobin, showed no abnormality. Straight radiographs of the abdomen and left arm were taken. There was rapidly increasing pallor and abdominal distension and a surgical opinion was asked. The findings were those of a severe intraperitoneal haemorrhage. The radiographs (Fig. 1) indicated the presence of free fluid in the abdominal cavity and the clinical features were those of a hepatic haemorrhage. Rapid transfusion was begun and after 150 ml. had been given laparotomy was carried out. There were large clots and much dark blood in the peritoneal cavity. There was a very large ruptured subcapsular haematoma on the anterior surface of the liver with very active bleeding. Clots were removed and the bleeding found to be coming from a laceration of the liver parenchyma about 4 cm. long. The bleeding was controlled by suture of the liver followed by suture of the capsule. Much further clot was removed by suction and measurement of the fluid blood and clot indicated that at least 350 ml., and probably over 400 ml., of blood had been lost into the peritoneal cavity. Transfusion was continued rapidly until 400 ml. had been given.

The baby's condition was greatly improved and two days later she was feeding well, appeared to be normal and the haemoglobin was 100%.

At 2 months the baby was thriving and there was no evidence of other birth injury. The liver showed no abnormality on palpation.

From the hospital records this is the only baby in which the diagnosis has been made clinically and treatment has been successful. It is likely that rapid transfusion of a sufficient amount of blood would be successful without operation. It is certain, however, that without operation this amount of blood would not have been given over such a short period. Contrary to the view expressed by Arden the liver parenchyma held stitches well as did its capsule and the active bleeding was readily controlled.

It is difficult to accept the unqualified statement that bleeding into the peritoneal cavity does not upset the baby, for in my experience massive intraperitoneal bleeding has resulted in ileus and in our patient intestinal obstruction was suspected initially.

Quite apart from the theoretical value of the control of haemorrhage, operation may be advisable because an absolute diagnosis cannot be made without

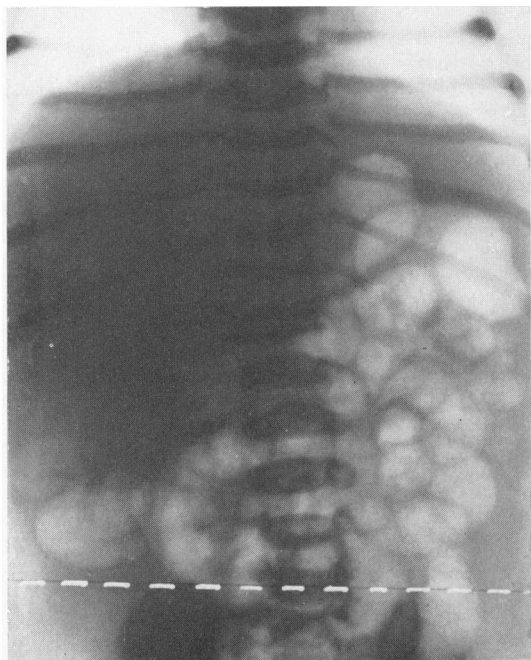


FIG. 1 (a).

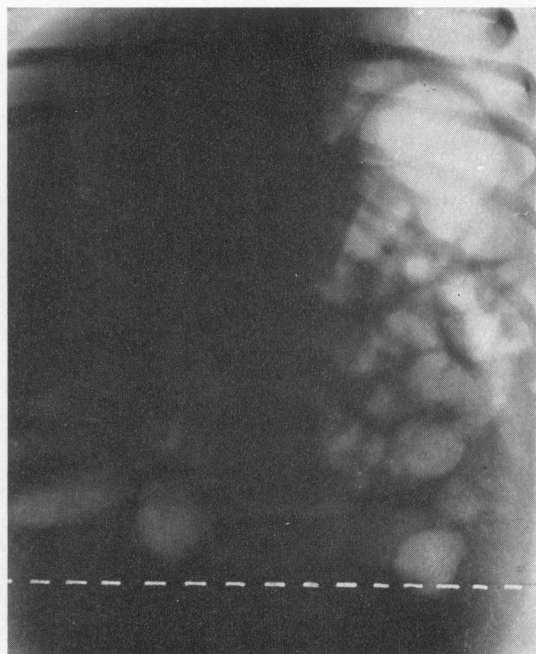


FIG. 1 (b).

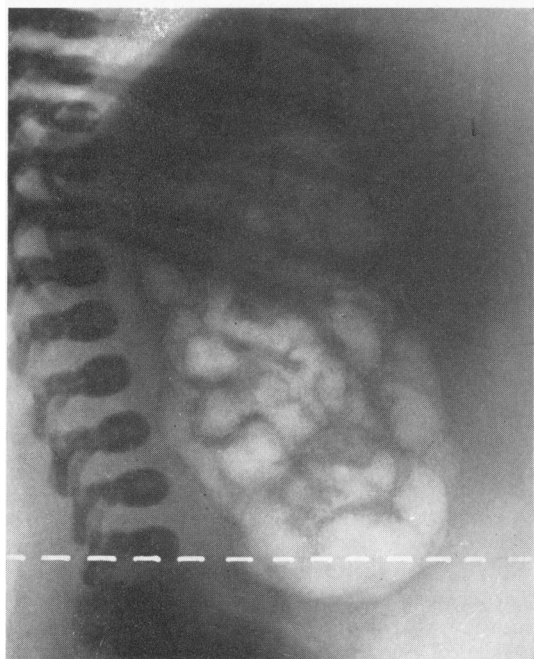


FIG. 1 (c).

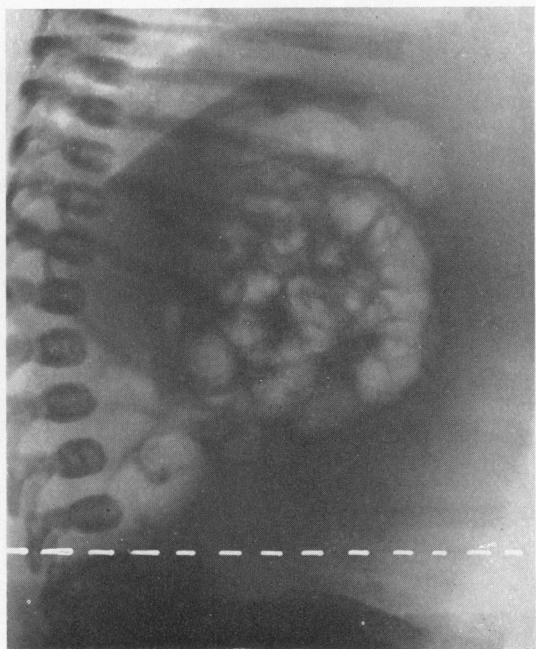

FIG. 1 (d).

FIG. 1.—Plain antero-posterior radiographs in the supine (a) and erect (b) positions. Plain lateral radiographs in the supine (c) and (d) erect positions.

Note that the assumption of the erect position has caused the intestine to rise to a higher level. This can happen only when it floats upwards on viscid free fluid such as blood. The white dotted line is at the level of the highest point of the iliac crest.

it. Dennison (1957), having treated a baby with rupture of a subcapsular haematoma of the liver by operation with success, encountered a second patient in whom the clinical diagnosis of liver haemorrhage was made but laparotomy revealed an unsuspected intussusception.

The risk of laparotomy in the newborn is now so small, the few cases of neonatal hepatic haemorrhage treated surgically have done so well and the difficulty of making a certain diagnosis without laparotomy all suggest that operation should not be lightly discarded. The presence of intraperitoneal bleeding may be indicated by the comparison of the level of the intestine in radiographs taken in the supine and erect positions.

As long as there is no method of treating an anomaly or disease its recognition is not important. Now that we can treat some cases of hepatic haemorrhage successfully greater attention must be given to the clinical features of subcapsular haematoma in the hope that the condition may be recognized before it ruptures into the peritoneal cavity.

If the diagnosis of subcapsular haematoma is made and the baby is kept under observation death may occur so rapidly that there is no time for treatment by transfusion. The treatment in such circumstances would seem to lie between immediate transfusion and the administration of vitamin K, or the same treatment plus laparotomy. Operation would be of value only if the haematoma were in an accessible situation. In his careful analysis Henderson found the site of the haemorrhage to be as follows:

SITE OF BLEEDING IN HEPATIC HAEMORRHAGE (HENDERSON, 42 CASES)		
Superficial	Anterior and antero-lateral surface right lobe	21
	Anterior surface both lobes	3
	Anterior surface left lobe	11
Deep	Visceral surface right lobe	4
	Visceral surface left lobe	1
	Visceral surface ? lobe	3
	Postero-superior surface right lobe	3

It is obvious that the majority of haematomas of the liver will be readily accessible to the surgeon. While all the recorded cases treated surgically have recovered it does not prove that operation is the best treatment, for it may be that the babies who survived were those with delayed rupture of the haematoma or with the slowest rate of blood loss into the peritoneal cavity while failure of surgical treatment may not have been recorded. The diagnosis should be suspected when there is evidence of pallor and a falling haemoglobin with otherwise normal blood findings and in all cases of sudden collapse in the first days of life. There may be also a palpable swelling in the vicinity of the liver or obviously continuous with it. If the baby is premature or post-mature additional support is given to the diagnosis.

Summary

Trauma during delivery may cause liver injury especially in premature and post-mature infants.

A subcapsular haematoma is formed and rupture of the capsule of the liver follows immediately or is delayed for a few days.

The continuing bleeding is more severe than would be expected from the damage to the liver parenchyma alone and asphyxia or prothrombin deficiency may be responsible.

Rupture of the capsule may be followed by bleeding of such severity that death occurs within minutes before treatment can be begun.

The diagnosis of subcapsular haematoma of the liver can be made clinically in some cases and should be suspected in all cases of pallor and falling haemoglobin with otherwise normal blood findings. As rupture appears to be certain treatment should be begun before the subcapsular haematoma erupts through the capsule.

Straight radiography may be of value in establishing the diagnosis of free blood in the peritoneal cavity.

Transfusion is the most important therapeutic measure. The amount of blood required is likely to be underestimated. Surgical control of the bleeding may be difficult and may be unnecessary but operation may be valuable in estimating the amount of blood loss and in excluding other conditions requiring operative treatment.

It is possible that the successes following operation have been due to the undoubted fact that the babies coming to operation have been those in whom rupture was delayed and blood loss was less rapid, giving more time for the making of the clinical diagnosis.

A case of hepatic haemorrhage is recorded in which surgical arrest of bleeding from the ruptured liver was readily secured and measurement of the blood in the peritoneal cavity was invaluable in the control of the blood replacement.

REFERENCES

- Arden, F. (1946). *Med. J. Aust.*, 1, 187.
 ——— (1951). *Ibid.*, 2, 632.
 ———, Dique, J. C. and Wrench, D. (1955). *Ibid.*, 2, 765.
 Bret, J., Jamain, B. and Coupé, C. (1956). *Arch. franç. Pédiat.*, 13, 1043.
 Cruickshank, J. N. (1930). *Spec. Rep. Ser. med. Res. Coun. (Lond.)*, No. 145, p. 60.
 Dennison, W. M. (1957). Personal communication.
 Greaves, J. L. (1955). *Lancet*, 2, 1227.
 Henderson, J. L. (1941). *J. Obstet. Gynaec. Brit. Emp.*, 48, 377.
 Holmberg, E. (1933). *Finska LäkSällsk. Handl.*, 75, 1067.
 Lundquist, B. (1930). *Acta Obstet. Gynec. scand.*, 9, 331.
 Palmer, A. C. (1928). *Spec. Rep. Ser. med. Res. Coun. (Lond.)*, 118, 67.
 Potter, E. L. (1940). *J. Amer. med. Ass.*, 115, 996.
 Rogers, G. (1934). *Amer. J. Obstet. Gynec.*, 27, 841.
 Stein, F. E. and Wright, L. T. (1953). *Harlem Hosp. Bull.*, 6, 32.
 Quoted in *Yearbook of Pediatrics*, 1954-1955, p. 26.