

CONGENITAL ABSENCE OF THE INTRAHEPATIC BILE DUCTS

BY

LEONARD HAAS and RICHARD H. DOBBS
From the Children's Department, The London Hospital

(RECEIVED FOR PUBLICATION MARCH 24, 1958)

Routine histological examination of the liver during the acute stages of neonatal obstructive jaundice, whether of biopsy or of autopsy specimens, reveals a variety of different pathological conditions.

Congenital absence of the intrahepatic bile ducts appears to be a rare cause of obstructive jaundice in the newborn. The purpose of this paper is to draw attention to the condition by reporting two cases, and by discussing its main clinical and pathological features in the light of these two and eight other cases that have been found in the medical literature. One of the present cases was previously shown at a clinical meeting (Smythe and Dobbs, 1949) as a case of xanthomatosis, and later included in a monograph on this subject by Ahrens, Harris and MacMahon (1951) who considered the underlying pathology to be intrahepatic biliary atresia.

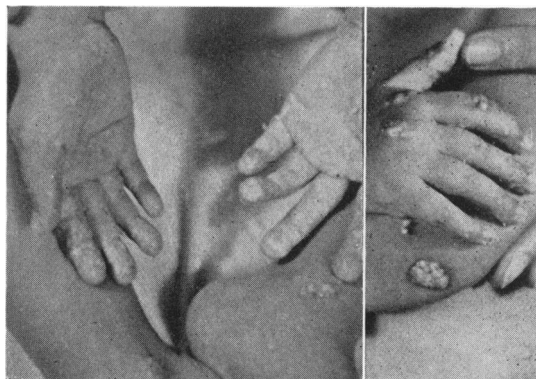
Neonatal obstructive jaundice with pale stools and dark urine has been common to all described cases, and in no way differed from that found in, for instance, congenital extrahepatic obstruction of the bile ducts or neonatal hepatitis. But, though the diagnosis was arrived at histologically in seven out of the 10 cases only after the age of 2 years, certain features common to the post-neonatal course of all of them appear to make the condition a recognizable clinical entity at least before the end of the first year of life.

Case Descriptions

Case 1. E.H., female, died aged 2 years 9 months. (Previously reported by Smythe and Dobbs, 1949; Ahrens *et al.*, 1951). She was the second child of healthy parents. The mother suffered from toxæmia in both pregnancies. The first child is alive and well. The birth was normal, the infant weighed 6½ lb. and was apparently healthy. Jaundice was noted on the second day of life and rapidly deepened. The serum bilirubin was not estimated at this stage. The stools became clay coloured and remained so for the first two months, after

which they became yellow and sometimes brown. The urine is alleged not to have contained bile pigments during the neonatal phase of the disease though from the age of 5 months onwards tests for bilirubin were always positive. Pruritus was a troublesome symptom from the first few days of life: persistent scratching often led to excoriations and bleeding, and the child was always unhappy and fretful. Nevertheless feeds were taken well and she gained weight slowly. At the age of 20 months widespread deposits of yellow material appeared in the skin. At the same time pruritus became more marked and scratching was mainly aimed at these deposits which frequently bled freely.

The child's condition remained stationary and in September, 1948, at 2½ years of age, she was admitted to The London Hospital for investigation. She was then found to be a thin, undersized and unhappy child, 21 lb. in weight and 32 inches in height. There was moderate generalized jaundice of the skin and the conjunctivæ. The body was covered with innumerable yellow, raised xanthomatous deposits, especially marked over the hands, elbows, ankles and legs (Figs. 1 and 2). Miliary xanthomata were found on the palms and soles and longitudinal yellow streaks in the creases of the skin and along the gum margins. Both liver and spleen were enlarged and palpable 1 inch below the costal margin, the liver edge



FIGS. 1 AND 2.—Case 1. Skin xanthomata.

being firm and smooth. A systolic murmur was audible over the praecordium.

The relevant investigations at this time were as follows: liver function tests: serum bilirubin, 4.5 mg. per 100 ml.; alkaline phosphatase, 36 units; serum proteins, 6.3 g. per 100 ml. (albumin, 4.1; globulin, 2.2); thymol turbidity, 2.5 units; cephalin and colloidal gold tests were negative. Apart from the raised serum bilirubin these tests were compatible with normal hepatic function. Serum cholesterol was 1,200 mg. per 100 ml. Urobilin and urobilinogen as well as a trace of bile were present in the urine. Stercobilin was present in the stools. A skin biopsy confirmed that the deposits in the subcutis were cholesterol.

No change in the clinical picture was observed during her stay in hospital. She was considered to be suffering from an incomplete or partial obstructive jaundice associated with generalized xanthomatosis. This was believed to be the primary abnormality and as such she was presented at the Royal Society of Medicine (Smythe and Dobbs, 1949).

The child died three months after discharge from hospital at the age of 2 years and 9 months. Just before death she became deeply jaundiced with a bilirubin of 13.6 mg. per 100 ml. Autopsy revealed a bilateral acute pyelonephritis as the immediate cause of death*. Xanthomatous deposits were found in the endocardium and the subintima of the great vessels, as well as on the posterior surface of the epiglottis and the epiglottic folds. The liver was enlarged and jaundiced. The gall bladder contained a moderate amount of brownish bile which could be easily expressed along the main cystic and hepatic ducts which appeared to be patent. The spleen was enlarged and firm but showed no definite abnormality.

The microscopy of the liver has been described in detail by Ahrens *et al.* (1951), and will be discussed later.

Case 2. S.P., female, was 5 years old in May, 1958. She was born of a healthy mother after a normal pregnancy and there have been no other siblings (1958). The father is not known. The child was delivered by forceps, weighed 6 lb. 2 oz. and was apparently healthy. Jaundice was noted on the fourth day of life and this rapidly increased in severity. The stools became pale and the urine dark. A congenital obstruction to the flow of bile was suspected, and a laparotomy was performed on the sixteenth day of life. At operation the gall bladder was found to be empty and deeply buried in the fissure. The cystic duct was traced to where the common bile duct should have been, but the latter could not be identified with certainty. There was no extra-hepatic distension of the bile ducts and aspiration of the liver did not locate any collection of bile. An unfavourable prognosis was given. However, though the child remained thin and jaundiced her general condition did not deteriorate.

She was re-examined at the age of 8 months when her complexion was described as pale olive. Her serum bilirubin was 1.5 mg. per 100 ml., and stercobilin was identified in the stools. Since then there has been no

* (Autopsy no. 5/42. General Hospital, Southend, Essex.)

increase in the degree of clinical jaundice and her general health has also remained relatively good.

She was admitted to The London Hospital in June, 1956, at the age of 3 years 1 month. She was then a stunted child, 27 lb. in weight and 30 inches in height. There was very slight generalized jaundice. The liver was enlarged, its edge was smooth, firm and palpable three and three-quarter inches below the costal margin. The tip of the spleen was just palpable. There was a systolic cardiac murmur audible over the praecordium.

The relevant investigations at this time were as follows: liver function tests: serum bilirubin, 4.5 mg. per 100 ml.; alkaline phosphatase, 54 units; thymol turbidity, 0.8 units; thymol flocculation, 0; zinc sulphate test, 3.5 units; serum proteins, 7 mg. per 100 ml. (albumin, 5.1; globulin, 1.9). Apart from the raised serum bilirubin and the slightly raised alkaline phosphatase these tests were compatible with normal hepatic function. Cholesterol was 1,600 mg. per 100 ml.; total lipids, 3,800 mg. per 100 ml.; and lipo-proteins, 1,300 mg. per 100 ml. The urine contained bilirubin, and urobilinogen within normal limits. Stercobilin was present in normal quantities in the stools. The bone age was within normal limits.

The child's general health remained good. She was cheerful and happy in spite of continued pruritus which caused a great deal of scratching. A sparse papular eruption first noted one month after admission was soon followed by the appearance of numerous yellow shiny xanthomatous deposits in the skin flexures and over the buttocks (Fig. 3). No skin biopsy was done. She grew two and a half inches within the course of nine months but failed to gain any significant amount of weight.

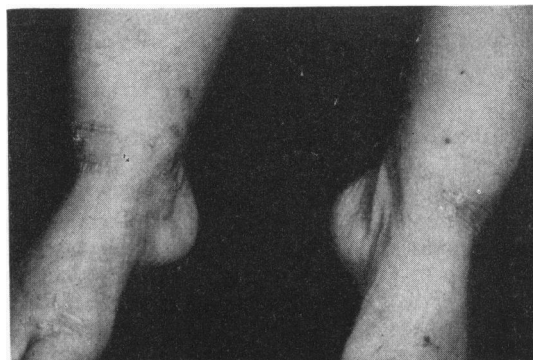

FIG. 3. Case 2. Skin xanthomata.

This clinical picture reminded us of Case 1, and of the histological description by Ahrens, to whom autopsy material had been sent. A tentative diagnosis of intrahepatic biliary atresia was made, and a drill biopsy of the liver was performed. This showed a histological pattern almost identical with that of Case 1, for a description of which the monograph by Ahrens and his colleagues should be consulted (Ahrens *et al.*, 1951)

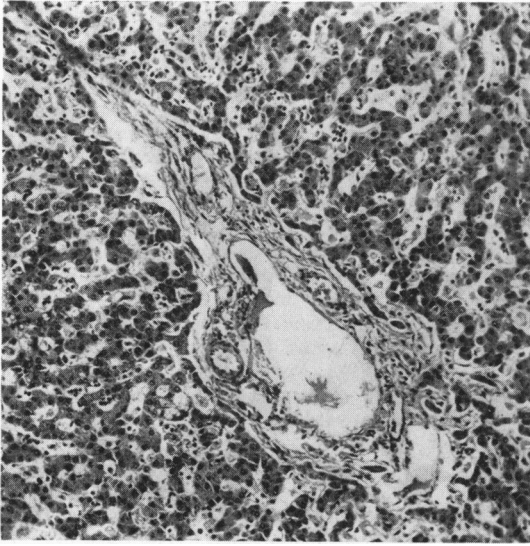


FIG. 4.—Case 1. Section of liver showing portal tract containing portal vein and hepatic artery but no bile duct. H. and E. $\times 110$.

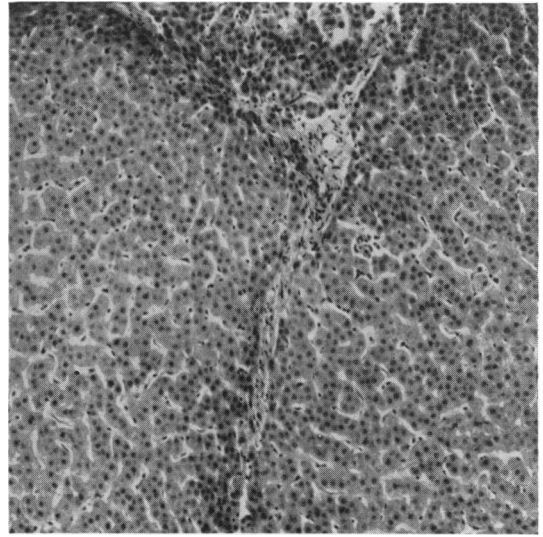


FIG. 5.—Case 2. Section of liver from biopsy specimen showing single thin fibrous band in otherwise normal parenchyma. H. and E. $\times 105$.

(Figs. 4, 5 and 6). Briefly the most important and apparently essential abnormality in both cases was found in the portal tracts: portal veins and normal hepatic arteries were present but the accompanying bile ducts were absent. In contrast the intralobular canaliculi were present in both cases, and contained inspissated bile casts in Case 1 but not in Case 2. The portal tracts were infiltrated with small round cells in both cases, more marked in Case 1, in which a slight excess of extralobular fibrous tissue was also present. The liver cells looked normal. The Kupffer cells in Case 1 were large and contained lipoid material. The architecture of the lobules was still normal and there was no evidence of cirrhosis.

Discussion

Ahrens *et al.* (1951) were the first to describe this condition in detail. They reported two cases of their own as well as two others, one of which was Case 1 above. They also collected nine further cases from the literature which they thought comparable, though in seven of these the clinical and pathological details appear to us insufficient to be sure that they belong to the same group. The two remaining cases, however, Case 2 reported by Dahl-Iversen and Gormsen (1944), and the one reported by Sacrez, Fruhling and Rohmer (1946), are clearly the same condition on clinical as well as histological grounds. We have been able to find three more cases which have been fully described since then (MacMahon and Thannhauser, 1952; Moyson, Gillet and Richard, 1953; Sass-Kortsak,

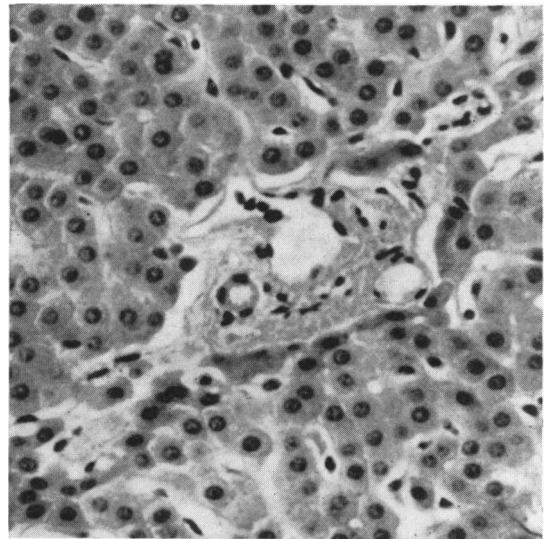


FIG. 6.—High power view of same section as Fig. 5 showing portal tract with absent bile duct. H. and E. $\times 325$.

Bowden and Brown, 1956) and brief references to three others in which clinical details are not given (MacMahon and Thannhauser, 1952; Redo, 1954; Kiesewetter, Koop and Farquahr, 1955).

There are, therefore, now 10 well-documented cases of this condition, two male and eight female.

The important features of these 10 cases are summarized in Table 1. Four of the children, including Case 2 of this report, were alive and relatively well at the time of reporting. Two of them, the only two boys in the series, are known to have reached the ages of 10 and 12 respectively (MacMahon and Thannhauser, 1952; Harris, 1957). Apart from the infant who died at birth all these children have certain features in common: (1) They suffered from obstructive jaundice in the first week of life. As they lived on, their jaundice became less intense and bile pigment reappeared in the faeces. (2) The extrahepatic biliary system, either at laparotomy or at autopsy, was found to be patent in nine of the 10 patients. In one (Ahrens *et al.*, 1951: Case 3), although the gall-bladder was found to contain bile at autopsy, the cystic duct was patent for only 1 cm. and then became a thick fibrous cord which extended to the ampulla of Vater. The hepatic ducts in this case were not identified. (3) Elevation of the serum lipids was found in all seven cases in which this estimation was carried out. The serum cholesterol levels were often very high and well above 500 mg. per 100 ml. except in one case in which the readings varied between 212 and 300 mg. per 100 ml. between the ages of 7 weeks and 3 months at which age she died (Sass-Kortsak *et al.*, 1956). (4) Xanthomatous cutaneous deposits were present in all but four cases. The youngest recorded appearance of these was at the age of 1 year 3 months (Ahrens *et al.*, 1951: Case 3), and the oldest at approximately the age of 6 (McMahon and Thannhauser, 1952). In all these cases pruritus preceded the appearance of xanthomata by several months. (5) The microscopical changes of the liver in all cases showed essentially the same abnormalities as described above. These consisted of absence of the bile ducts in the portal tracts, slight infiltration of portal tracts with lymphocytes, plasma cells and polymorphs, normal looking liver cells and absence of any distortion of lobular architecture or significant increase of fibrous tissue in the portal tracts even in late stages of the disease.

The more frequent causes of neonatal obstructive jaundice differ both clinically and pathologically from this syndrome. In extrahepatic biliary atresia in which the site of obstruction may be anywhere between the portal tracts and the ampulla of Vater, the jaundice persists until the infant dies. During the neonatal period there is marked proliferation of peribiliary bile ducts with gross dilatation in places of the larger bile ducts in the portal tracts and many of them are plugged by inspissated bile. Even in the early stages there is increase of fibrous tissue in the portal tracts which becomes very marked in

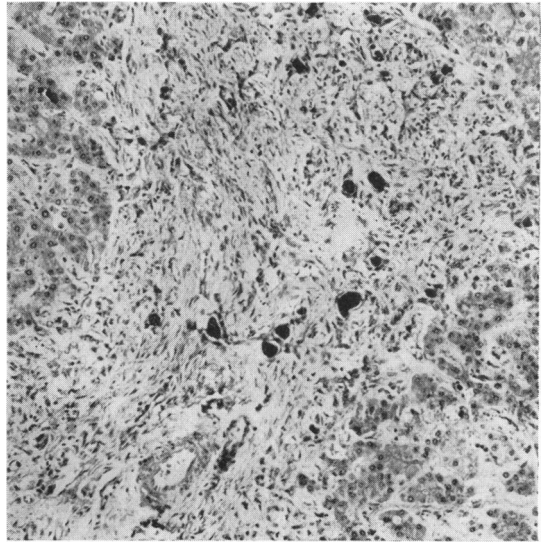


FIG. 7.—Section of post-mortem specimen of liver from patient with extrahepatic biliary atresia, showing wide fibrous tissue bands in portal region. Numerous portal bile ducts with inspissated bile casts. H. and E. $\times 105$.

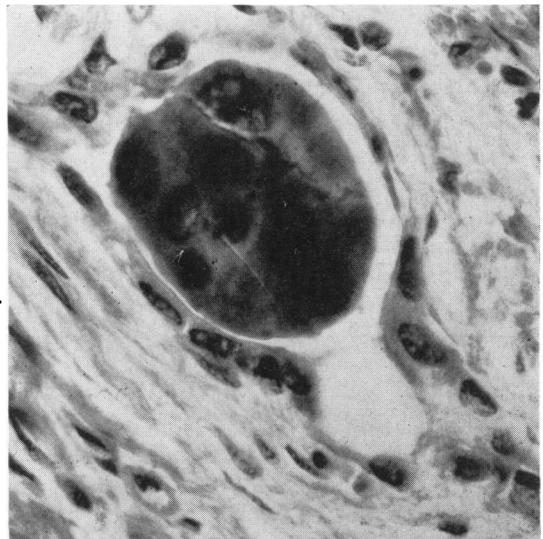


FIG. 8.—High power view of same case showing presence of portal bile duct surrounding inspissated bile cast. H. and E. $\times 830$.

those infants surviving more than a few months. The liver cells are often swollen and contain bile pigment. In the course of time true cirrhosis may ensue (Figs. 7 and 8).

In neonatal hepatitis the jaundice may persist for a number of weeks but is followed in the majority

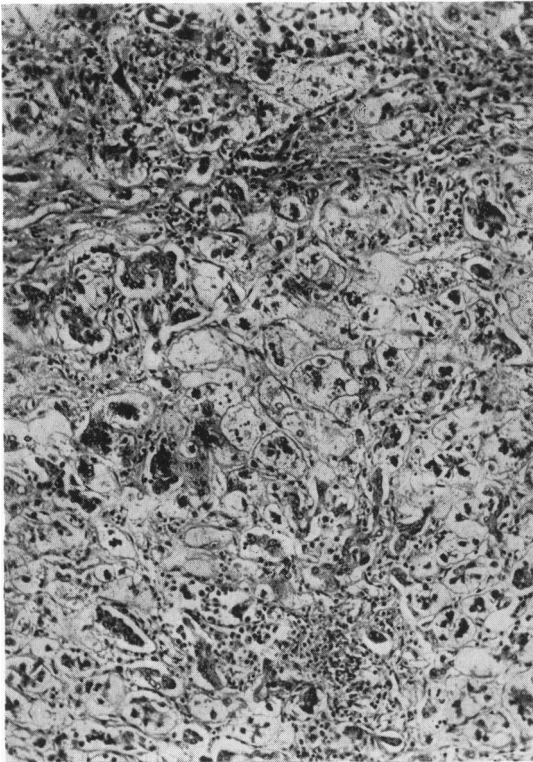


FIG. 9.—Section of post-mortem specimen of liver from child with neonatal hepatitis, showing large multinucleate parenchymal cells.

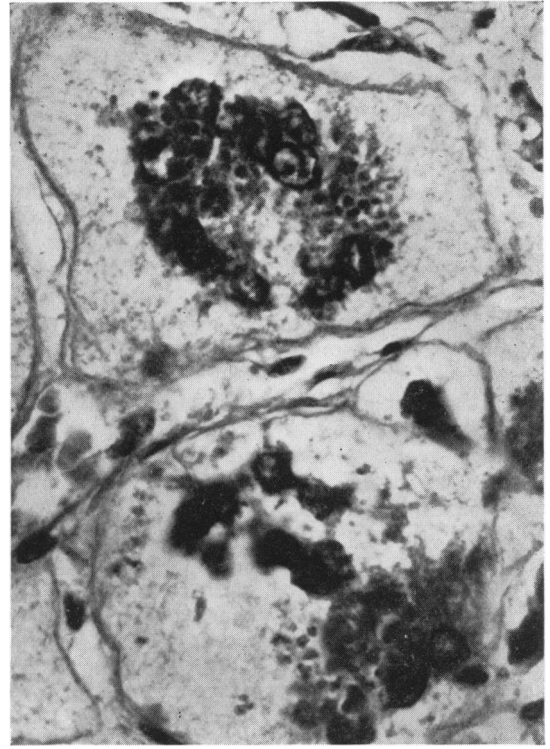


FIG. 10.—High power of same section.

of cases by a complete recovery. There is, however, a mortality rate of 20% and a further 10% of patients develop cirrhosis of the liver (Gellis, Craig and Hsia, 1954). The microscopical picture during the

neonatal stage shows marked variation in the size of the liver cells, with distorted multinucleated giant cells scattered throughout the liver substance (Craig and Landing, 1952; Bodian and News, 1953). In

TABLE

Author	Dahl-Iversen and Gormsen (1944)	Sacrez <i>et al.</i> (1946)	Case 1	Ahrens Case 2
Age of reported onset of jaundice	Birth	8 d.	1 w.	2 d.
Age of appearance of xanthomata	—	—	1 yr. 9 mth.	3½ yr.
Age of first reported hyperlipaemia	—	—	1 yr.	3 yr. 9 mth.
Highest and lowest recorded serum cholesterol levels in mg./100 ml.	—	—	1,816 149	1,020 687
Age of onset of pruritus	—	—	1½ yr.	3 yr.
Age of reporting	Birth	2 yr. 7 mth.	3½ yr.	6½ yr.
Age of liver histology	Birth	2 yr. 7 mth.	1 yr. 1 mth.	3 yr. 9 mth.
Age of death	Birth	2 yr. 7 mth.	3 yr. 6 mth.	—
Cause of death	'Lethargy'	Meningitis	Liver failure	—
Extrahepatic biliary system	Normal	Normal	Normal	Normal

the chronic stage of the disease the lobular architecture is distorted by fibrous tissue and a true cirrhosis may follow (Figs. 9 and 10) (Bodian and News, 1953; Dible, Hunt, Pugh, Steingold and Wood, 1954).

In the bile-impaction syndrome of Lightwood and Bodian (1946) prolonged haemolytic jaundice due to Rhesus incompatibility became complicated by biliary obstruction; this they showed histologically to be associated with inspissation of bile in the canaliculi.

A variety of other conditions occasionally cause liver damage associated with jaundice, pale stools and dark urine in the newborn. Inclusion-body disease was reviewed by France (1951); umbilical sepsis with generalized septicaemia, toxoplasmosis, congenital syphilis and herpes simplex, by Sherlock (1955). The clinical course of all these diseases is short and acute and totally unlike the condition under discussion.

It seems that in no other neonatal condition, particularly not in the later stages of either extrahepatic bile duct atresia or neonatal hepatitis, do hypercholesterolaemia or xanthomatosis occur. The association of liver disease with chronic jaundice and deposits in the skin has been known for more than a century (Addison and Gull, 1851). More recently Ahrens and others (Ahrens and Kunkel, 1949; MacMahon and Thannhauser, 1949; Ahrens, Payne, Kunkel, Eisenmenger and Blondheim, 1950), in their comprehensive monographs have fully discussed this relationship; briefly, elevation of the serum lipids is found in chronic biliary obstruction from any cause of sufficient duration provided liver cell function remains normal. When the serum cholesterol remains above a level of about 1,800 mg.

per 100 ml. for longer than a few months, xanthomatous deposits begin to appear in the skin.

Aetiology and Treatment

Ahrens *et al.* (1951) consider the absence of the intrahepatic bile ducts to be a developmental anomaly and, indeed, the typical histological picture was seen in one newborn infant as well as in another 3 months of age. At present treatment is entirely symptomatic. Pruritus may be relieved by the administration of methyl testosterone (Lloyd-Thomas and Sherlock, 1952) and, in Case 2, stenediol, 10 mg. on alternate days, was tried with good effect. An attempt was made to lower the circulating lipids by giving a diet devoid of all animal and saturated vegetable fats (Bronte-Stewart, Antonis, Eales and Brock, 1956) for two periods of two months each and one of one month, with intervening periods of a month. The result was disappointing, there being neither appreciable reduction of the serum lipid levels nor any regression of the xanthomata.

Summary

Two cases of congenital absence of intrahepatic bile ducts are described.

Together with eight other similar cases from the literature, their clinical and pathological features are discussed and are contrasted with those of other causes of neonatal obstructive jaundice.

Though some of these other conditions appear very similar during the neonatal period, the clinical course of intrahepatic atresia is sufficiently characteristic during the next nine to 12 months for a diagnosis

1

<i>et al.</i> (1951) Case 3	MacMahon and Thannhauser (1952)	Moysen <i>et al.</i> (1953)	Sass-Kortsak <i>et al.</i> (1956)	Present paper	
				Case 1†	Case 2
1 w.	8 d.	3 mth.	3 d.	2 d.	4 d.
1 yr. 3 mth.	6 yr.	—	—	1 yr. 8 mth.	3 yr. 2 mth.
—	12 yr.	9 mth.	7 w.	2 yr. 6 mth.	3 yr. 1 mth.
—	1,686	300 212	922 362	1,200 1,081	1,600 500
1 yr. 1 mth.	Uncertain	—	—	5 mth.	3 yr. 1 mth.
3½ yr.	10 yr.	11¼ mth.	7 w.	2½ yr.	3 yr. 1 mth.
3 yr. 3 mth.	10 yr.	11½ mth.	3½ mth.	2 yr. 9 mth.	3 yr. 3 mth.
3 yr. 3 mth.	—	—	3 yr. 6 mth.	2 yr. 9 mth.	—
Pharyngitis, liver failure	—	—	Staphylococcal pneumonia	Pyelonephritis	—
Fibrotic cystic and common bile ducts	Normal	Normal	Normal	Normal	? Normal

† Also Ahrens *et al.* (1951).

to be made, whilst probably at any time a liver biopsy will be pathognomonic.

We would like to express our thanks to Dr. Kenneth Tallerman for permission to allow us to report our second case, to Dr. Preedy for performing the liver biopsy and also to Dr. Weinbren for his histological reports.

REFERENCES

- Addison, T. and Gull, W. (1851). *Guy's Hosp. Rep.*, 7, 265.
- Ahrens, E. H. Jr., Harris, R. C. and MacMahon, H. E. (1951). *Pediatrics*, 8, 628.
- and Kunkel, H. G. (1949). *J. clin. Invest.*, 28, 1565.
- , Payne, M. A., Kunkel, H. G., Eisenmenger, W. J. and Blondheim, S. H. (1950). *Medicine (Baltimore)*, 29, 299.
- Bodian, M. and Newns, G. H. (1953). *Arch. franç. Pédiat.*, 10, 169.
- Bronte-Stewart, B., Antonis, A., Eales, L. and Brock, J. F. (1956). *Lancet*, 1, 521.
- Craig, J. M. and Landing, B. H. (1952). *Arch. Path. (Chicago)*, 54, 321.
- Dahl-Iversen, E. and Gormsen, H. (1944). *Acta chir. scand.*, 89, 333.
- Dible, J. H., Hunt, W. E., Pugh, V. W., Steingold, L. and Wood, J. H. F. (1954). *J. Path. Bact.*, 67, 195.
- France, N. E. (1951). *Arch. Dis. Childh.*, 26, 588.
- Gellis, S. S., Craig, J. M. and Hsia, D. Y. Y. (1954). *Amer. J. Dis Child.*, 88, 285.
- Harris, R. C. (1957). Personal Communication.
- Kiesewetter, W. B., Koop, C. E. and Farquahr, J. D. (1955). *Pediatrics*, 15, 149.
- Lightwood, R. and Bodian, M. (1946). *Arch. Dis. Childh.*, 21, 209.
- Lloyd-Thomas, H. G. L. and Sherlock, S. (1952). *Brit. med. J.*, 2, 1289.
- MacMahon, H. E. and Thannhauser, S. J. (1949). *Ann. intern. Med.*, 30, 121.
- , — (1952). *Gastroenterology*, 21, 488.
- Moynson, F., Gillet, P. and Richard, J. (1953). *Helv. paediat. Acta*, 8, 281.
- Redo, S. F. (1954). *Arch. Surg. (Chicago)*, 69, 886.
- Sacrez, R., Fruhling, L. and Rohmer, J. A. (1946). *Arch. franç. Pédiat.*, 3, 78.
- Sass-Kortsak, A., Bowden, D. H. and Brown, R. J. K. (1956). *Pediatrics*, 17, 383.
- Sherlock, S. (1955). *Diseases of the Liver and Biliary System*. Oxford.
- Smythe, P. M. and Dobbs, R. H. (1949). *Proc. roy. Soc. Med.*, 42, 86.