

DEFICIENCY OF VITAMIN B₁₂ AFTER EXTENSIVE RESECTION OF THE DISTAL SMALL INTESTINE IN AN INFANT

BY

A. C. L. CLARK and C. C. BOOTH

*From The Hospital for Sick Children, Great Ormond Street, and Department of Medicine,
Postgraduate Medical School of London*

(RECEIVED FOR PUBLICATION MARCH 2, 1960)

Man may survive resection of surprisingly large amounts of the small intestine. As little as 7 in. of jejunum and ileum may be sufficient to support life, at least for a time (Jackson, Linder and Berman, 1951), and a large number of patients have survived less extensive resections and have remained well (Flint, 1912; Haymond, 1935; West, Montague and Judy, 1938; Althausen, Uyeyama and Simpson, 1949). These observations have been made in adults and the results of extensive resections in children during the growing period are less certain. Such operations are infrequently carried out and there is a high immediate postoperative mortality (Benson and Sharpe, 1950). Children may, however, survive resection of large amounts of the small intestine (Blayney, 1901; Flint, 1912), and two infants have recently been recorded whose growth and development were normal after resection of all but 26 to 28 cm. of jejunum and ileum (Pilling and Cresson, 1957).

The purpose of this paper is to describe a child who had an extensive resection of the distal small intestine soon after birth. She later developed a mild megaloblastic anaemia associated with severe B₁₂ deficiency and required treatment with vitamin B₁₂. Her growth and development have been otherwise normal up to the age of 2½ years.

Materials and Methods

Haematological methods were those described by Dacie (1956); serum vitamin B₁₂ levels were measured by microbiological assay using the Z strain of *Euglena gracilis*, according to the method described by Hutner, Bach and Ross (1956); glucose tolerance tests were carried out as described by King and Wootton (1956).

Fat balances were carried out over a continuous nine-day period. The child was given a diet containing approximately 30 g. of fat daily. After a preliminary period of three days, the stools were collected over successive three-day periods and the fat content was

estimated by the method of Van de Kamer, Huinink and Weyers (1949).

Absorption of radioactive vitamin B₁₂ was measured by the modified faecal excretion technique described by Booth and Mollin (1956). The test dose of vitamin B₁₂ was 1 µg. and was given with 50 mg. of a potent intrinsic factor concentrate.

Case Report

V.R., a female infant, was born at term on March 31, 1957, after a normal pregnancy (birth weight 7 lb. 5 oz.). Soon afterwards she developed signs of intestinal obstruction and was admitted to West Herts Hospital under the care of Dr. M. E. Edmunds. Laparotomy was performed on the 20th day of life and revealed congenital malrotation of the gut with volvulus and extensive gangrene of the small intestine. Approximately four-fifths of the distal small intestine were thought to have been removed, end-to-side anastomosis being performed between the jejunal stump and the mid-transverse colon. The terminal ileum was closed just proximal to the ileocaecal valve. After an initial period of severe vomiting and diarrhoea, she recovered from the operation, breast feeding was established and she gained weight.

At the age of 3 months she attended The Hospital for Sick Children, Great Ormond Street. At this time she was passing two to five bulky fluid stools daily. She weighed 9 lb. 4 oz., and apart from some abdominal distension, no abnormality was found on examination. She continued with breast feeding and supplements of vitamins A, C and D by mouth. By the age of 6 months her weight (15 lb.) was above the 10th percentile level. Although she continued to have diarrhoea, her weight increased at a normal rate until she was 10 months old, when she weighed 19 lb. (Fig. 1). During the 11th month, however, there was a gradual diminution in the frequency of her stools; she began to vomit after her feeds and she lost weight. She was then admitted to The Hospital for Sick Children at the age of 11 months under the care of Dr. P. R. Evans.

Clinical Examination. This revealed a thin child (weight 16 lb. 10 oz.) with generalized abdominal

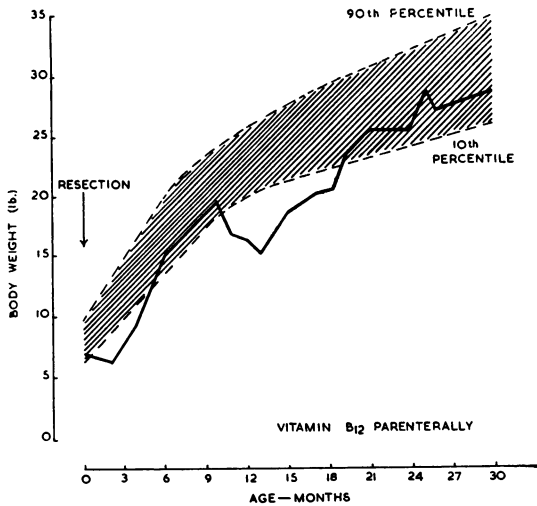


FIG. 1.—Weight chart of patient V.R. after extensive resection of the distal small intestine. Vitamin B₁₂ was given parenterally after the thirteenth month. The lines representing the 10th and 90th percentile are also shown (Tanner, 1958).

distension. No peristalsis was visible. There was no glossitis nor angular stomatitis. The skin was normal and the central nervous system showed no abnormalities.

Investigations. These revealed Hb 12.1 g. % and R.B.C. 4.0 M. per c.mm.; serum electrolytes: Na 140, K 4.2, Cl 102 and HCO₃ 26 mEq./litre. Stool cultures were repeatedly negative for pathogenic organisms. Plain radiographs of abdomen showed gross gaseous distension with fluid levels in both colon and small intestine.

Treatment and Progress. She was first given oral neomycin (20 mg./lb. body weight in divided doses), but without improvement in her condition. The vomiting, periods of constipation and the radiological evidence of fluid levels in the bowel suggested a diagnosis of subacute intestinal obstruction. A further laparotomy was therefore performed on March 19, 1958, but although the whole of the large bowel and the jejunum immediately proximal to the anastomosis appeared dilated, no organic obstruction was found. The remaining small intestine consisted of the duodenum and approximately 30 in. of jejunum, the end of the jejunum being anastomosed to the middle of the transverse colon, thereby short circuiting the caecum, ascending colon and proximal half of the transverse colon. Nothing further was done and the abdomen was closed.

Her condition continued to deteriorate after this operation. Her weight fell steadily (Fig. 1), vomiting continued intermittently and her stools were bulky and irregular. However, barium meal showed the small intestine to be normal, the barium passing into the colon in one and a half hours. A barium enema outlined the dilated colon but some of the barium remained for five

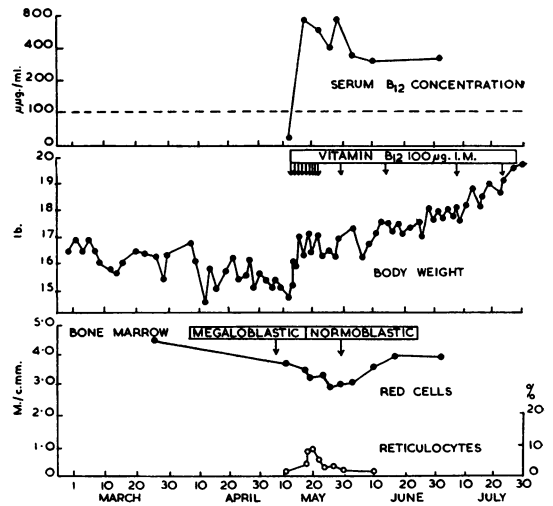


FIG. 2.—Serum B₁₂ concentration, body weight, red cells and reticulocytes before and after treatment with vitamin B₁₂.

days in the short-circuited ascending colon and caecum, indicating stasis in this loop.

By May 1958, at the age of 13 months, her weight had fallen to 15 lb. (Figs. 1 and 2). Haematological investigations now revealed a mild macrocytic anaemia (Hb 11.0 g. %; R.B.C. 3.7 M. per c.mm.) and the bone marrow was megaloblastic. Her serum B₁₂ concentration was 25 µg. per ml. (normal range 140 to 900 µg. per ml.). Intestinal function tests were carried out at this time and are shown in Fig. 3. Her absorption of glucose was normal but she had steatorrhoea (mean fat absorption 82% on diet of 30 g. per day) and she was unable to absorb any of the test dose of vitamin B₁₂ (Fig. 3).

Response to Vitamin B₁₂. She was treated with intramuscular injections of vitamin B₁₂ (100 µg. daily for nine days, then 100 µg. every two weeks). Her initial response to this treatment is shown in Fig. 2. Vomiting ceased within 24 hours of the first injection and her weight began to increase. Her reticulocytes rose to 9% on the sixth day and the marrow became normoblastic. Although her red cell count fell at first, possibly as a result of rehydration, it then rose to normal levels without other treatment (Fig. 2).

Further investigations revealed no evidence of other deficiencies. Her total serum proteins were 7.0 g. %, serum Ca 8.8 mg. %, inorganic phosphate 5.6 mg. %, and alkaline phosphatase 24 King-Armstrong units. Skeletal radiographs revealed no evidence of rickets. Prothrombin time was normal. Intestinal function studies were repeated after oral chlortetracycline (20 mg./lb. in divided doses for six days). There was no improvement in absorption of either fat or B₁₂ following this treatment (Fig. 3).

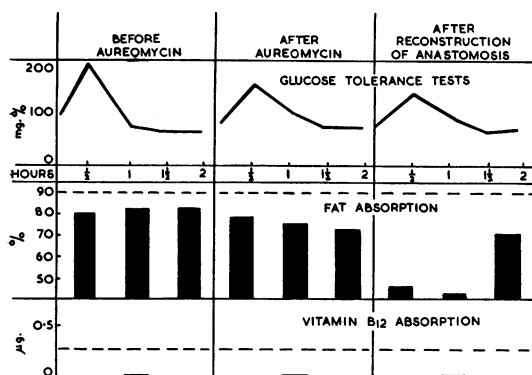


FIG. 3.—Intestinal function tests before and after chlortetracycline (aureomycin) and after refashioning of the jejunocolic anastomosis. The figures for fat absorption represent the mean absorption per day over successive three-day periods. Normal fat absorption should be greater than 90%. The lower limit of the absorption of radioactive B₁₂ by control subjects is indicated by the interrupted line.

Her weight increased steadily, although her stools were unchanged, and she weighed 19 lb. after two months' treatment with vitamin B₁₂ (Fig. 2). A further laparotomy was performed on July 30, 1958 (Mr. G. H. Macnab). The jejunotransverse anastomosis was undone, and an end-to-end anastomosis was made to the caecum. During this procedure many adhesions around the jejunum were broken down. The jejunum appeared slightly hypertrophied immediately proximal to the anastomosis, but the remaining small bowel was of normal calibre. A biopsy taken from the lower end of the jejunum showed normal mucosa, but some hypertrophy of the muscle coats.

She recovered well from this procedure and continued to improve, although a fat balance revealed more marked steatorrhoea than before the operation (mean fat absorption 52% on diet of 30 g. per day). Her glucose absorption remained normal, but she was still unable to absorb vitamin B₁₂ (Fig. 3).

After this operation she received a diet usual for her age with restriction of fat to 30 g. per day, together with oral supplements of vitamins A (7,000 units daily), B (Becosym 1 dram daily) and D (1,000 units daily). She was also given vitamin B₁₂ intramuscularly (100 µg. every two weeks). Her subsequent progress is shown in Fig. 1. By 20 months her weight was above the 10th percentile and her development has continued normally. Now, at the age of 2½ years, she weighs 28.5 lb., a normal weight for her age. Her Hb is 10.9 g. % and she remains well, although she still passes three bulky stools daily.

Discussion

Estimations of the amount of small intestine remaining after resection are notoriously inaccurate (Flint, 1912). At our patient's first operation, it was considered that four-fifths of the small intestine had been removed. The remaining intestine was

measured at a later laparotomy and was found to consist of approximately 30 in. of jejunum. The exact length of the small intestine in an infant is not certain and the proportion of the bowel remaining in this patient is therefore not known, but in this case 30 in. may possibly represent between a quarter and a third of the total small intestine.

The type of malabsorption from which she suffered was characteristic of an extensive resection of the distal small intestine (Booth, 1958). Since some of her proximal intestine remained, she absorbed glucose normally, for glucose is rapidly absorbed from the upper small intestine (Verzár and MacDougall, 1936). Her remaining intestine was apparently only sufficient to absorb between 52 and 82% of her dietary fat and she therefore had steatorrhoea, suggesting that fat is normally absorbed more distally than glucose in the small intestine. Her inability to absorb vitamin B₁₂ is in keeping with the resection of the distal small intestine, for B₁₂ is absorbed in the ileum in man (Booth and Mollin, 1959).

Stagnant loops of bowel may sometimes play a part in causing malabsorption (Cameron, Watson and Witts, 1949; McIntyre, Sachs, Krevans and Conley, 1956; Halsted, Lewis and Gasster, 1956), but do not appear to have been a factor in this case. In patients with such loops, malabsorption is frequently improved by a course of oral broad spectrum antibiotics (Mollin and Baker, 1955; McIntyre *et al.*, 1956; Halsted *et al.*, 1956; Booth and Mollin, 1957) or by operations which remove or correct the loop (McIntyre *et al.*, 1956). Our patient's absorption defects were not improved by antibiotics, nor by the removal of the short circuit at her last operation, and it seems unlikely that the short-circuited area of colon contributed to her malabsorption. The reason for her deterioration in fat absorption after this operation is uncertain, but it may be that the breaking down of adhesions around the lower jejunum resulted in more rapid passage of food through the remaining small intestine.

For the first 10 months of life her growth was normal, suggesting that she was able to absorb or derive from tissue stores sufficient nutrients to maintain normal development during this time. Since she was unable to absorb vitamin B₁₂, it is not surprising that she ultimately developed B₁₂ deficiency. The delay in onset of this deficiency was presumably due to the time required to exhaust the stores of vitamin B₁₂ in liver and other tissues, a situation which is analogous to the delayed development of B₁₂ deficiency after total gastrectomy (Pitney and Beard, 1955). The symptoms and

signs in our patient were different from those usually found in adult patients with Addisonian pernicious anaemia. She had vomiting, constipation and signs suggestive of intestinal obstruction, and she lost weight steadily. There were no neurological signs suggesting subacute combined degeneration of the cord or peripheral neuritis. Despite her very low serum B₁₂ level, she was not markedly anaemic, her red cells never falling below 3.0 M. per c.mm., although her sternal marrow was megaloblastic.

Her full and complete response to parenteral injections of vitamin B₁₂ suggests that although she had marked steatorrhoea, the only deficiency state she had developed was B₁₂ deficiency. This observation is supported by the absence of hypoproteinaemia, her normal prothrombin time and the lack of evidence of rickets. Since she has continued to grow normally whilst receiving only vitamin B₁₂ parenterally, she appears to be absorbing the other nutrient factors required for growth and development. These factors, including the vitamins other than B₁₂, must therefore be absorbed in the proximal small intestine or colon.

It is not certain whether there is any compensatory improvement in intestinal function in children after extensive resections, although adults may show a progressive increase in absorptive capacity following such operations (Althausen, Doig, Uyeyama and Weiden, 1950). It is said that the mucosa and muscle of the remaining gut typically hypertrophies (Flint, 1912; Jackson, 1958), but this does not always occur (Shonyo and Jackson, 1950; Shelton and Blaine, 1954) and in animals the site of the resection may play a part in determining whether there is hypertrophy of the remaining small bowel (Booth, Evans, Menzies and Street, 1959). In our patient, the barium follow-through showed no evidence of hypertrophy of the small intestine, but at laparotomy the lower jejunum was found to be hypertrophied. It is uncertain whether this was due to partial obstruction by the many adhesions found in this area at her last operation, or whether there has been hypertrophy which was compensatory to the loss of intestinal length. It seems unlikely that she will recover the ability to absorb vitamin B₁₂ and treatment with vitamin B₁₂ by injection is to be continued indefinitely.

The observations in this patient illustrate the importance of the distal intestine in the absorption of vitamin B₁₂. They also support the conclusion that patients who have undergone resection of the ileum should either be kept under close haematological supervision or be treated with prophylactic injections of vitamin B₁₂.

Summary

Extensive resection of the distal small intestine was performed in a child soon after birth. Her growth was normal until she was 10 months old when she began to vomit and lose weight. At the age of 13 months she was found to have a mild megaloblastic anaemia and her serum B₁₂ concentration was very low. She improved dramatically after treatment with parenteral B₁₂ and her growth and development have been normal to the age of 2½ years.

We wish to thank Dr. P. R. Evans and Mr. G. H. Macnab for permission to record details of this patient who was under their care in The Hospital for Sick Children, Great Ormond Street; we are also indebted to Dr. D. L. Mollin for his encouragement and advice, and for permission to quote the results of vitamin B₁₂ studies carried out in his laboratory at the Postgraduate Medical School.

REFERENCES

- Althausen, T. L., Uyeyama, K. and Simpson, R. G. (1949). Digestion and absorption after massive resection of the small intestine: I. Utilization of food from a 'natural' versus a 'synthetic' diet and a comparison of intestinal absorption tests with nutritional balance studies in a patient with only 45 cm. of small intestine. *Gastroenterology*, 12, 795.
- , Doig, R. K., Uyeyama, K. and Weiden, S. (1950). Digestion and absorption after massive resection of the small intestine: II. Recovery of the absorptive function as shown by intestinal absorption tests in two patients and a consideration of compensatory mechanisms. *Ibid.*, 16, 126.
- Benson, C. D. and Sharpe, H. R., Jr. (1950). Recent experiences with intestinal resection in infants and children. *Arch. Surg. (Chicago)*, 61, 822.
- Blayne, A. (1901). On the removal of great lengths of intestine. *Brit. med. J.*, 2, 1456.
- Booth, C. C. (1958). A clinical and experimental study of the intestinal absorption of vitamin B₁₂. M.D. Thesis, St. Andrew's University.
- , Evans, K. T., Menzies, T., and Street, D. F. (1959). Intestinal hypertrophy following partial resection of the small bowel in the rat. *Brit. J. Surg.*, 46, 403.
- and Mollin, D. L. (1956). Plasma, tissue and urinary radioactivity after oral administration of ⁵⁶Co-labelled B₁₂. *Brit. J. Haemat.*, 2, 223.
- (1957). The importance of the ileum in the absorption of vitamin B₁₂. *Lancet*, 2, 1007.
- (1959). The site of absorption of vitamin B₁₂ in man. *Ibid.*, 1, 18.
- Cameron, D. G., Watson, G. M. and Witts, L. J. (1949). The clinical association of macrocytic anemia with intestinal stricture and anastomosis. *Blood*, 4, 793.
- Dacie, J. V. (1956). *Practical Haematology*. 2nd ed. Churchill, London.
- Flint, J. M. (1912). The effect of extensive resections of the small intestine. *Bull. Johns Hopk. Hosp.*, 23, 127.
- Halsted, J. A., Lewis, P. M. and Gasster, M. (1956). Absorption of radioactive vitamin B₁₂ in the syndrome of megaloblastic anemia associated with intestinal stricture or anastomosis. *Amer. J. Med.*, 20, 42.
- Haymond, H. E. (1935). Massive resection of the small intestine; analysis of 257 collected cases. *Surg. Gynec. Obstet.*, 61, 693.
- Hutner, S. H., Bach, M. K. and Ross, G. I. M. (1956). A sugar-containing basal medium for vitamin B₁₂ assay with *Euglena*; application to body fluids. *J. Protozool.*, 3, 101.
- Jackson, W. P. U. (1958). Massive resection of the small intestine. In *Modern Trends in Gastroenterology*, ed. F. Avery Jones. 2nd series, p. 243. Butterworth, London.
- , Linder, G. C. and Berman, S. (1951). Small gut insufficiency following intestinal surgery. *S. Afr. J. clin. Sci.*, 2, 70.
- King, E. J. and Wootton, I. D. P. (1956). *Micro-analysis in Medical Biochemistry*. Churchill, London.
- McIntyre, P. A., Sachs, M. V., Krevans, J. R. and Conley, C. L. (1956). Pathogenesis and treatment of macrocytic anemia. *A.M.A. Arch. intern. Med.*, 98, 541.

- Mollin, D. L. and Baker, S. J. (1955). *The Absorption and Excretion of Vitamin B₁₂ in Man*. Biochem. Soc. Symp., No. 13, p. 52. Cambridge University Press.
- Pilling, G. P. and Cresson, S. L. (1957). Massive resection of the small intestine in the neonatal period. *Pediatrics*, 19, 940.
- Pitney, W. R. and Beard, M. F. (1955). Vitamin B₁₂ deficiency following total gastrectomy. *Arch. intern. Med.*, 95, 591.
- Shelton, E. L. and Blaine, M. H. (1954). Massive small bowel resection in post-gastrectomy patient: Report of two cases. *Tex. St. J. Med.*, 50, 96.
- Shonyo, E. S. and Jackson, J. A. (1950). Massive resection of the small intestine. *Arch. Surg., Chicago*. 61, 123.
- Tanner, J. M. (1958). The evaluation of physical growth and development. In *Modern Trends in Paediatrics*. ed. A. Holzel and J. P. M. Tizard. 2nd series. Butterworth, London.
- Van de Kamer, J. H., Huinink, H. Ten Bokkel and Weyers, H. A. (1949). A rapid method for the determination of fat in feces. *J. biol. Chem.*, 177, 347.
- Verzár, F. and MacDougall, E. J. (1936). *Absorption from the Intestine*. Longmans, Green, London.
- West, E. S., Montague, J. R. and Judy, F. R. (1938). Digestion and absorption in a man with 3 feet of small intestine. *Amer. J. dig. Dis*, 5, 690.